



ELSEVIER

Contents lists available at ScienceDirect

## International Journal of Infectious Diseases

journal homepage: [www.elsevier.com/locate/ijid](http://www.elsevier.com/locate/ijid)

## Review

## HIV enteropathy and ‘Slim disease’: Historical and current perspectives

Moses Silungwe Kapembwa<sup>1,\*</sup>, Philip Anthony Batman<sup>2</sup>, Simon Charles Fleming<sup>3</sup>, George Edward Griffin<sup>4</sup><sup>1</sup> London Northwest Teaching Hospitals NHS Trust & Imperial College of Medicine, Northwick Park & St Mark's Hospitals, Harrow, UK<sup>2</sup> Department of Histopathology, Bradford Hospitals NHS Trust, Bradford Royal Infirmary, Bradford, UK<sup>3</sup> Department of Clinical Chemistry, Royal Cornwall Hospital, Truro, UK<sup>4</sup> Department of Cellular and Molecular Sciences, St George's Hospital Medical School, Cranmer Terrace, London, UK

## ARTICLE INFO

## Article history:

Received 19 August 2023

Revised 28 November 2023

Accepted 28 November 2023

## Keywords:

HIV enteropathy

Slim disease

Immunopathogenesis

Highly active antiretroviral therapy

## ABSTRACT

**Objectives:** Chronic diarrhoea and severe wasting associated with HIV infection were first described in East African patients as slim disease (SD) in 1985. The main histological features are flattening of the villi (villous atrophy) and crypt hyperplasia (elongated crypts), i.e., HIV enteropathy (HIVE). Selective loss of mucosal clusters of differentiation 4 (CD4)<sup>+</sup> T helper (Th)17<sup>+</sup> lymphocytes is the immunological hallmark of HIVE. This review explores (i) the historical background of HIVE and SD, (ii) the relationship between gut mucosal CD4<sup>+</sup> Th17<sup>+</sup> and intestinal-resident intra-epithelial gamma delta (IRIE) T lymphocytes in pathogenesis of HIVE, (iii) the role of cytokines in regulation of intestinal epithelial proliferation, and (iv) the role of antiretroviral therapy in HIVE.

**Methods:** Recent studies have highlighted the role of IRIE T lymphocytes, mostly CD8<sup>+</sup>, in regulating gut epithelial regeneration. CD4<sup>+</sup>Th17<sup>+</sup> and IRIE T cells are necessary to maintain intestinal barrier integrity and mucosal antimicrobial immune defence. However, the immunological cross-talk between such lymphocyte sub-sets culminating in HIVE is uncertain. We undertook a narrative literature review under the headings ‘HIVE’, ‘SD’, and ‘Highly active antiretroviral therapy (HAART)’. Relevant studies were located using the electronic search engines Google Scholar and PubMed from 1984 to 2022.

**Results:** Depletion of Th17<sup>+</sup> cells in the lamina propria, attributed to low-level viraemia, is accompanied by concomitant increase in the density of gut mucosal IRIE T lymphocytes in AIDS. The latter express a broad range of cytokines (interferon-gamma, tumor necrosis factor-alpha, interleukin-17) and chemokines e.g., keratinocyte growth factor, post exposure to HIV-infected cells. Keratinocyte growth factor induces epithelial proliferation mainly in the crypts, leading to functional immaturity of enterocytes, reduced gut absorptive surface area and malabsorption in animal experiments. Of note, the absence of IRIE T cells is associated with a reduction in epithelial cell turnover. Patients with HIVE receiving early HAART show enhanced expression of mucosal repair genes and improvement of gut symptoms.

**Conclusion:** Multiple lines of enquiry suggest HIVE is directly related to HIV infection and is a consequence of perturbations in mucosal CD4<sup>+</sup>Th17<sup>+</sup> and IRIE T lymphocytes. The pathological result is enterocyte immaturity and dysfunction. SD whose main features are malabsorption, diarrhoea and weight loss, is a severe clinical expression of HIVE. A better understanding of immuno-pathogenesis of HIVE opens a window of opportunity for the potential use of immunotherapy in HIV disease and other T cell-mediated enteropathies.

© 2023 The Author(s). Published by Elsevier Ltd on behalf of International Society for Infectious Diseases.

This is an open access article under the CC BY-NC-ND license (<http://creativecommons.org/licenses/by-nc-nd/4.0/>)

\* Corresponding author.

E-mail address: [m.kapembwa@ic.ac.uk](mailto:m.kapembwa@ic.ac.uk) (M.S. Kapembwa).

## Introduction

The emergence of the HIV epidemic in Africa was first reported among patients originating from Central Africa presenting with severe wasting symptoms resembling marasmus in 1983. The illness was associated commonly with chronic, and often life-threatening diarrhoea [1]. There was no evidence of an underlying immunosuppressive disease, no history of blood-product transfusion, homosexuality, or intravenous-drug abuse and the disease appeared to affect females as frequently as males. A similar illness was described in a cohort of Haitian patients in 1984. Stool evaluation was remarkable for the absence of detectable entero-pathogens in one third of such patients. This observation together with the poor response in the course of diarrhoea to treatable potential pathogens in the remainder gave rise to the hypothesis that HIV itself was responsible for the chronic diarrhoea-wasting illness.

Donald Kotler subsequently coined the term ‘HIV enteropathy’ (HIVE) in 1984 [2] to describe the syndrome of chronic diarrhoea in HIV-infected patients in the absence of enteric pathogens. He reported the histological small bowel biopsy appearances of partial villous atrophy with crypt hyperplasia and increased numbers of intraepithelial lymphocytes. The locals in rural Uganda where the disease was also highly prevalent named the condition ‘Slim disease’ (SD) in recognition of the severity of weight loss [3]. The majority (89%, 84% respectively) of archived serum samples from patients with SD in the Rakai district of Uganda and Zaire when tested in 1985 were subsequently found to be sero-positive for antibodies to HIV-1.

The description of SD in African patients and its absence from the Centers for Disease Control (CDC) clinical case surveillance definition of the acquired immunodeficiency syndrome prompted the World Health Organisation to propose a clinical case definition of AIDS for use in developing countries in 1986 [4]. Thus, persistence of diarrhoea for more than 1 month with unexplained weight loss of at least 10% of the premorbid weight was included as an AIDS-defining condition.

The causes of diarrhoea in HIV/AIDS are multifactorial, however, and it has not always been clear from publications on SD what additional factors contribute to wasting in these patients. Intensive studies of SD patients carried out in 1988 and subsequently in resource-rich countries revealed the presence of enteric pathogens in up to 85% of such patients [5] of which *Cryptosporidium*, *Isospora belli*, *Microsporidia*, *Mycobacterium avium* complex and *Cytomegalovirus* were the most common. Thus, SD refers to the severe manifestations of HIVE perhaps reflecting increased bacterial translocation, immune activation and opportunistic gut infection. Also, since the first description of HIVE, confusion has arisen regarding the meaning of the term. Some authors have extended the definition to include patients with acute diarrhoea related to early HIV infection, and others to patients presenting with antiretroviral treatment-related diarrhoea. Another compounding factor for the clinical investigator is that weight loss of varying severity accompanies chronic HIV infection in almost all reported studies with and without diarrhoea, and malnutrition is a regular feature of late-stage HIV disease. For example, wasting and malnutrition in the absence of chronic diarrhoea or other AIDS-defining diagnosis were reported in 7% of patients in one study. However, such wasting is not always a continuous process; some patients may experience alternating periods of relative weight stability and body wasting.

Other contributory causes of diarrhoea include opportunistic entero-coccidial micro-organisms (*cryptosporidium* sp., *Isospora belli*, *microsporidium* sp.), small intestinal bacterial overgrowth and dysregulation of the enteric immune system, highlighted in 2017. Anorexia is a feature of chronic HIV infection and may also be encountered as a side effect of medication used in treatment of

intercurrent infection in patients with AIDS, as may impaired food intake because of dysphagia and/or odynophagia.

Given the complexity of the task, it is not surprising that the underlying pathogenetic links between villous atrophy, crypt cell hyperplasia, intestinal intraepithelial lymphocytes, malabsorption, opportunistic gut pathogens and HIV infection remain elusive despite several decades of investigation, (Figure 1).

## Aims and methods

The aims of this review are to explore (i) the historical background leading to the discovery of HIVE and SD (ii) the relationship between gut mucosal clusters of differentiation 4 (CD4)+ T helper (Th)17+ and intestinal-resident intra-epithelial (IRIE)  $\gamma\delta$  T lymphocytes in pathogenesis of HIVE. (iii) the role of cytokines in regulation of intestinal epithelial proliferation and repair; (iv) the effect of antiretroviral therapy on HIVE.

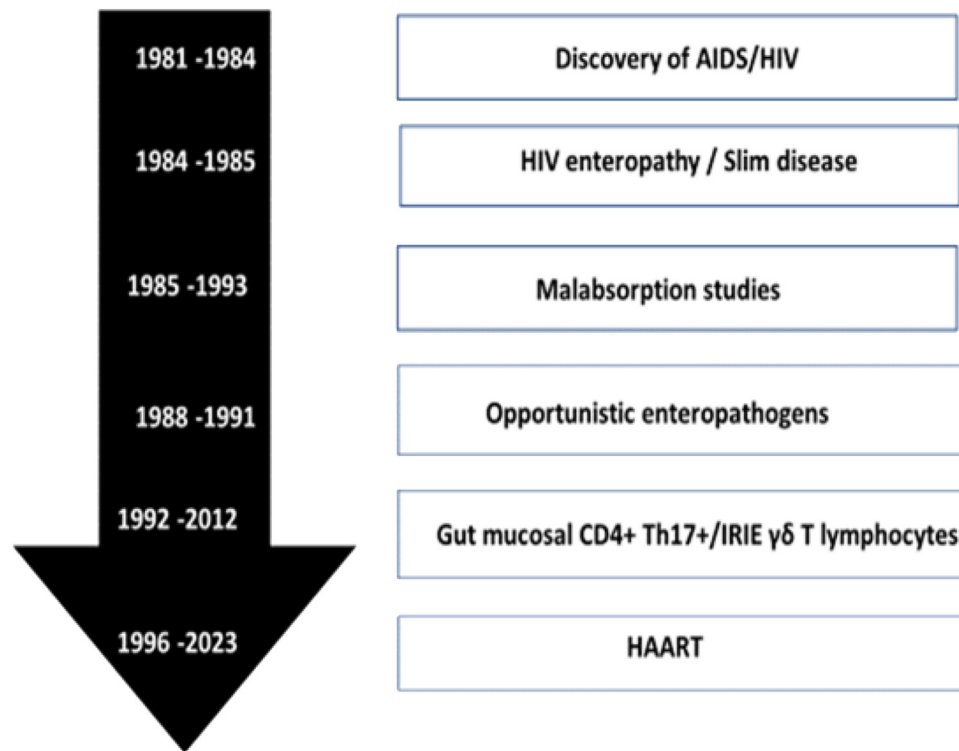
Most research on HIVE has focused on studies of patients during the chronic phase of HIV infection. This is largely because the distinctive nature of the clinical syndrome, i.e., persistent diarrhoea and profound weight loss, renders such patients more readily to systematic investigation.

We, therefore, conducted a narrative review of the literature under the headings ‘HIVE’, ‘SD’ and ‘Highly active antiretroviral therapy’ (HAART). Relevant studies were located using the electronic search engines Google Scholar and PubMed. Pivotal descriptions of HIVE, SD, HAART, gut immuno-pathology and mucosal cytokine profiles were tracked from 1984 to 2022. Studies published in languages other than English were excluded. Titles and Abstracts were examined for relevance to the topic and selected full publications with the highest level of evidence critically analysed.

### *HIV enteropathy as a malabsorption and nutritional deficiency syndrome*

Nutrient malabsorption has been found in most patients with HIVE. Evidence of impaired fat absorption was demonstrated early in the investigations into this syndrome by several authors and the degree of fat malabsorption correlated with the severity of jejunal villous atrophy [6]. The pathogenesis of fat malabsorption has remained elusive. Ultra-structural studies of jejunal mucosa from HIV-infected patients have shown lipid accumulation in cytoplasm, within the basolateral membrane spaces, and in the lamina propria. Proliferation of the smooth endoplasmic reticulum and mitochondrial damage have also been reported. These observations suggest two possible mechanisms for fat malabsorption, namely metabolic derangements within the villous enterocytes leading to impaired triglyceride synthesis, and/or lymphatic obstruction.

Other functional abnormalities affecting the digestive system in patients with HIV disease were investigated in the early 1990s, including lactase deficiency and exocrine pancreatic insufficiency [7]. Bile acid and vitamin B12 malabsorption have been described suggesting distal ileal dysfunction. Impaired absorption of both nutrients was first shown in a clinical study of HIV+ patients with jejunal villous atrophy and co-incidental entero-coccidial infection. Significant sugar malabsorption was observed in AIDS-wasting syndrome in 1992, and altered small intestinal permeability was subsequently reported in Caucasian white male homosexual and African heterosexual patients residing in the United Kingdom and Uganda [8]. Increased intestinal permeability measured by decreased absorption of mannitol was demonstrated in patients with AIDS or AIDS-Related Complex (ARC) irrespective of the presence or absence of diarrhoea. The reduced absorption of mannitol suggested that the functional absorptive surface of the intestine declines as HIV disease progresses. Increased intestinal permeability in AIDS patients was shown to correlate significantly with CD4



**Figure 1.** HIV enteropathy and Slim Disease: Diagram depicting the chronology of events from the first descriptions of the AIDS in 1981 to 2023.

Key: CD, clusters of differentiation; Th, T helper. IRIE  $\gamma\delta$  T lymphocytes – intestinal-resident intra-epithelial gamma-delta T lymphocytes. HAART – Highly active antiretroviral therapy.

counts and body mass index. The aetiology of weight loss in HIV infection also includes failure to utilise nutritional substrates.

#### *Significance of mucosal CD4<sup>+</sup> CD17<sup>+</sup> T-helper lymphocytes and Cytokines*

Immunological changes in the gastrointestinal tract were recognised early in the epidemic as features of both acute and chronic HIV infection. The major and most consistent immunological feature in the intestinal mucosa in both phases of infection is the selective depletion of the memory subset of CD4<sup>+</sup> T-helper lymphocytes [9]. It is estimated that during acute infection, up to one quarter of the CD4<sup>+</sup> T-lymphocytes are depleted from the intestinal mucosa coinciding with the intense viral replication that occurs during the first few weeks of HIV infection. Similar depletion of small bowel mucosal CD4<sup>+</sup> T-lymphocytes is observed within days of acute simian immunodeficiency syndrome (SIV) infection, a disease of macaques that closely mimics the pathogenesis, immunology, and pathology of HIV-induced disease in humans.

During untreated chronic HIV infection, there is a relentless decline in the memory CD4<sup>+</sup> T-lymphocyte population, which ultimately leaves affected individuals highly susceptible to opportunistic infections. The partial restoration of CD4<sup>+</sup> T-lymphocytes observed during recovery from acute HIV infection does not persist into the chronic stage. One study showed that before depleting CD4<sup>+</sup> T cells in the gut, acute HIV infection induces infiltration of the mucosa with activated effector memory CD4<sup>+</sup> and CD8<sup>+</sup> T cells. One explanation for this controversial finding is that there may simply be re-distribution of T-lymphocytes rather than local proliferation of such cells in the gut. The chronic decline in CD4<sup>+</sup> T cells is more pronounced in the small bowel mucosa than in peripheral blood as patients progress to AIDS suggesting differential impact of HIV between the two compartments. In subsequent studies, it was shown that most of the CD4<sup>+</sup> T cells

depleted from the gut during progressive HIV and SIV infection belong to the Interleukin-17 (IL-17)-producing Th17<sup>+</sup> lymphocyte subset first identified in 2005 [10].

Th 17<sup>+</sup> cells, like other T-helper lymphocyte subsets, are of the memory phenotype. They differentiate from naive CD4<sup>+</sup> T cells after T-cell receptor (TCR) stimulation and co-stimulation by antigen-presenting cells in the presence of Th17 promoting cytokines. In healthy individuals, the highest frequencies of CD4<sup>+</sup> Th17<sup>+</sup> cells are found in the gastro-intestinal tract compared with all other anatomic sites [11]. These cells are mediators of cellular immunity and play a critical role in the activation of other immune cells such as B-cells and cytotoxic T-cells. They regulate innate intestinal immunity via production of interleukin (IL)-17, IL-21 and IL-22. IL-17 promotes tight junction formation at mucosal surfaces through the upregulation of claudin-1, claudin-2, and zona occludens-1 expression, which are all key proteins essential for maintenance of epithelial barrier integrity. IL-21 and IL-22 synergize with IL-17 to enhance the expression of antimicrobial peptides in mucosal tissues. Of note, IL-22 has also been shown to regulate intestinal epithelial regeneration and proliferation through the modulation of stem cells [12].

Interestingly, subjects with long term HIV-1-infection who are ‘non-progressors’ appear to preserve their gut mucosal Th 17<sup>+</sup> cells well and maintain IL-17 expression that is no different from that of HIV-uninfected controls [13]. Similarly, non-human primates with non-pathogenic SIV infection maintain high levels of CD4<sup>+</sup> Th 17<sup>+</sup> cells and develop neither enteropathy nor progress to AIDS. Thus, the loss of gut-derived CD4<sup>+</sup> Th 17<sup>+</sup> lymphocytes, and by inference, loss of essential cytokines such as IL-22 play a key role in the pathogenesis of chronic HIV.

Gut-associated lymphoid tissue (GALT) constitutes the largest pool of T lymphocytes in the body and is, therefore, an important reservoir for HIV-1. The rapid destruction of CD4<sup>+</sup> T cells is matched by downregulation of genes in GALT responsi-

ble for controlling mucosal growth, maintenance, and repair. Of note, CD4+ T-lymphocyte depletion in the terminal ileum, including Peyer's patches, may be accompanied by extensive collagen deposition. The ensuing architectural change might disrupt the ability of GALT to support normal cell-cell interactions, trafficking, and survival.

#### *The role of intestinal-resident intra-epithelial gamma delta T lymphocytes*

Several mechanisms have been proposed to explain the loss of CD4+ T cells during HIV infection. They include killing of infected cells directly by HIV, natural killer cells or cytotoxic T cells (CTL) and/or by immune activation resulting in by-stander cell death. Research has also focussed on intestinal-resident intra-epithelial (IRIE) T lymphocytes, a minor subset of T cells [14] that are long-lived resident effector cells interspersed between epithelial cells along the entire length of the intestine. They are mostly CD8+, in contrast to gamma delta T lymphocytes in the lamina propria which are predominantly CD4- CD8-, i.e., double negative. The disappearance of Th17+ cells in the lamina propria is accompanied by a concomitant increase in the density of IRIE T lymphocytes in the duodenum of AIDS patients both of which were shown to persist following antiretroviral therapy [15]. The striking expansion in the total number of IRIE T lymphocytes despite significant reduction of mucosal CD4+ T lymphocytes bears a striking resemblance to that observed in coeliac disease. Although the exact functions and behaviour of IRIE T lymphocytes remain elusive at present, their primary role seems to be in regulating gut epithelial turnover and repair. For example, IRIE T cells were shown to modulate epithelial growth in a mouse model of villus atrophy via secretion of the epithelial cell mitogen, keratinocyte growth factor (KGF). The mitogen induced epithelial proliferation mainly in the crypts, and to a lesser degree in the upper region of villi [16]. Furthermore, the absence of IRIE T cells was associated with a reduction in epithelial cell turnover [17]. These observations provide evidence that KGF secreted by IRIE T cells is an important factor for maintenance of intestinal epithelial cell proliferation and villus growth. The nature of the cross-talk between the IRIE T lymphocytes, the classical and much better known CD4+ helper T cells and CD8+ cytotoxic T cells is currently unknown. However, a possible link might be via cytokines since IRIE T cells are known to display a broad range of cytokines (interferon- $\gamma$ , tumor necrosis factor [TNF]- $\alpha$ , IL-17) and chemokines (RANTES, IP-10, lymphotactin) following recognition of HIV-infected or transformed cells.

#### *The role of perforin*

Under normal physiological conditions, the structure of the intestinal mucosa is maintained by a delicate balance between 'programmed cell death' apoptosis and cellular regeneration. Perforin, a glycoprotein expressed by antigen-exposed mucosal cytotoxic CD8+ T lymphocytes and Natural killer (NK) cells, is responsible for punching holes in enterocyte cell membranes ('pore' formation), through which granzymes can enter and initiate apoptosis. CD4+ T lymphocytes are critical for maintenance of cytotoxic CD8+ T cells. However, CD4-positive T-cells are also able to express a low amount of perforin, when classic cytotoxicity is ineffective or disturbed.

An important pathological manifestation of intestinal disease during acute HIV infection recognised in 2008 is accelerated apoptosis [18]. In one histological study of HIV-infected patients, perforin-expressing mucosal cytotoxic CD8+ T-lymphocytes were increased and there was a positive correlation between the number of mucosal (lamina propria and intra-epithelial) perforin-expressing CD8+ T cells and apoptotic loss of enterocytes. In ad-

dition, there was clustering of apoptotic epithelial cells at the villous tips coinciding with a high density of intra-epithelial perforin-positive CD8+ T cells [19]. This observation is in agreement with data showing accumulation of perforin-expressing CD8+ T cells in the gut mucosa during acute SIV infection. Surprisingly, mucosal perforin expression is lost in the late stages of both HIV and SIV infections despite persistently increased numbers of mucosal CD8+ T cells. It is assumed that this decline is linked to the loss of CD4+ T-cells that occurs later in infection. Increased concentration of perforin-expressing CD8-positive T cells in the gut mucosa has also been documented in coeliac disease, a T-cell mediated enteropathy induced by ingesting dietary gluten. In the context of HIV disease, apoptosis provides a mechanism by which the body might effectively lyse cells without the requirement that each depleted cell be infected with HIV. Other factors of HIV infection may play a role in the induction and regulation of epithelial cell apoptosis. These include TNF-alpha and nitric oxide which are produced as components of a pro-inflammatory response during acute HIV infection, as well as viral protein R (Vpr) of HIV-1, an 'accessory' protein that serves many functions in the viral life cycle.

#### *Villus and crypt architectural abnormalities in HIV enteropathy*

Considerable circumstantial evidence began to accrue from the 1980s for an immunological basis for HIVE when a striking resemblance with other T-lymphocyte-mediated enteropathies such as untreated coeliac disease, graft-vs-host disease and in children with small intestinal disease secondary to impaired cell-mediated immunity was recognised. The most characteristic change to villous architecture in the small intestine of such patients was found to be blunting of villus height, i.e., villous atrophy. Data on crypt cell kinetics associated with villous atrophy in HIVE are contradictory, however, with various authors reporting crypt hyperplasia, crypt hypoplasia, and crypts of normal length. Evidence from human foetal intestinal explants maintained in culture under sterile conditions and subsequently exposed to HIV *in vitro* in 1994 showed crypt cell hyperproliferation compared with non-exposed explants; crypt hyperplasia was thus confirmed as the main driver of villous atrophy, the pressure of proliferation forcing crypt cells onto the sides of villi, pushing the crypt-villus junction in a luminal direction, and effectively reducing the absorptive villous surface area [20]. Presently, it is unclear what mechanisms drive the crypt hyperplastic response in HIV infection. However, it has been speculated that HIV infection of lymphoid cells in the lamina propria stimulates T-cell activation resulting in release of cytokines which, in turn, induce crypt epithelial cell proliferation [21].

Histological evaluation of the distribution of villous atrophy based on gut mucosal biopsies obtained via capsule endoscopy and functional studies suggest that HIVE is disproportionately expressed in the proximal small bowel mucosa, suggesting a differential impact of HIV infection along the intestine. Crypt hyperplastic villous atrophy may be exacerbated further by opportunistic intracellular gut pathogens, e.g., *Enterocytozoon bienersi* (microsporidiosis). A consequence of such entero-protozoal infections in immunocompromised patients might be to worsen and extend the enteropathy to involve the entire small intestine.

Changes within the lamina propria of the small bowel of HIV-infected patients were described at the outset of the study of HIVE, including infiltration by lymphocytes, eosinophils, plasma and mast cells. HIV colitis was described subsequently. The detection of HIV proteins and nuclear acids in various cell types of the gut in 1989, namely epithelial cells, lymphocytes, and macrophages, suggested that structural changes may be related directly to local HIV infection and there emerged evidence of HIV

infection of lymphoid cells in the lamina propria of the gut [22]. Only a minority of studies suggested that enterocytes themselves become infected by the virus. Several hypotheses have been put forward to account for the morphological damage to villous enterocytes including a 'virotoxic' effect of HIV *per se*, supported by the finding of HIV in proximity to abnormally differentiated enlarged enterocytes, enteric microtubule depolymerization and increased intestinal fatty acid binding protein, (a marker released into the bloodstream upon enterocyte damage) among chronically HIV-infected patients compared to HIV elite controllers i.e., long term non-progressors. Interestingly, despite the presence of such biomarkers of enterocyte damage and cytotoxic T lymphocytes, there is no evidence in the literature of gut mucosal necrosis or ulceration in patients with HIVE.

#### Molecular basis of diarrhoea

Several explanations have been advanced as molecular mechanisms of diarrhoea in HIVE, supported to a variable degree by experimental evidence. *In vitro* studies in 1995 demonstrated that gp120, an envelope protein of HIV, induces microtubule disruption, decreasing trans-epithelial resistance, promoting calcium signalling within the cell and altering intracellular architecture. HIV-1 *Tat* ('Trans-Activator of Transcription'), a regulatory protein encoded for by the *Tat* gene, impairs intestinal glucose absorption and induces calcium-dependent chloride ion secretion in human intestinal epithelial cells. HIV-1 *Tat* may also activate oxidative stress pathways, leading to disruption of the actin cytoskeleton, an ultra-microscopic feature associated with HIVE, decrease sodium-dependent glucose absorption, and increase intercellular permeability. Such ultrastructural epithelial damage allows leakage of microbial products (e.g., lipopolysaccharide) into plasma leading to systemic immune activation and poor long-term outcome in HIV-infected patients.

#### Response to antiretroviral therapy

Conventionally anti-retroviral treatment protocols of HIV-infected individuals involve the use of three anti-retroviral drugs that inhibit different enzymes involved in HIV replication. The current recommended regimen, namely highly active anti-retroviral therapy (HAART), consists of a backbone of two drugs from one class that inhibits the enzyme, nucleoside reverse transcriptase, so called nucleoside reverse transcriptase inhibitors plus either, an integrase inhibitor or boosted protease inhibitor (PI) as the third drug [23]. In fully adherent patients, HAART maximally and durably suppresses HIV in plasma resulting in significant increase in the levels of CD4+ Th17+ T-cells in the gut mucosa and decline of T-cell activation. However, regardless of the level of immune reconstitution with suppressive HAART, mucosal CD4+ Th17+ cells remain depleted when compared with HIV-uninfected control subjects despite immune reconstitution in the peripheral blood. The decline of CD4+ Th17+ cells in the lamina propria has been attributed to low-level viraemia evidenced by persistent HIV-1 proviral DNA and RNA in gut mucosa. Such incomplete suppression of viral replication despite HAART [24] could be explained in part by low intracellular concentrations of antiretroviral drugs preventing complete HIV suppression in this reservoir compartment. Additional studies suggest HIV concentrations are higher along the entire gastrointestinal tract when compared with blood HIV levels in patients treated with ART. The causes of the differential viral burden between the two compartments are likely to be multifactorial. One pharmacologic explanation is that the expression of drug-metabolizing enzymes and transporters is not uniform along the gastrointestinal tract. For example, there exists considerable

variation in cytochrome P450 (CYP) enzyme, including CYP3A, expression along the length of the gastrointestinal tract, with the majority of CYP expression occurring in the proximal section of the gut [25]. Furthermore, human studies show significant differences in expression of efflux transporters including Breast Cancer Resistance Protein (BCRP), multi-drug resistant protein (MRP) 2, and P-glycoprotein (P-gp), among patients and different sections of the gut. Finally, a well-described complication of HIV infection is autonomic neuropathy [26], which might lead to faster intestinal transit times and possible antiretroviral drug malabsorption. Autonomic neuropathy has been associated with chronic diarrhoea in other diseases.

The above physiological differences would, therefore, be expected to give rise to regional differences in antiretroviral concentrations in the gut and, thus provide the virus some degree of protection from antiretroviral suppression. In addition, the extensive collagen deposition and fibrosis observed in gut-associated lymphoid tissue (GALT) including Peyer's patches in chronic HIV infection may irreparably damage the ability of the remaining lymphoid tissue to support significant CD4 T-cell restoration.

The data on gut cytokines in response to HAART are conflicting. The results from a recent systematic review of twenty-eight studies suggest HAART stimulates the production of pro-inflammatory cytokines (significantly IL-6 and TNF- $\alpha$ ) when viral load is high. However, following HAART-induced viral suppression, the pro-inflammatory cytokines decline towards normal [27]. Another documented effect of long-term suppressive ART is regeneration of gut epithelial barrier function [28] and restoration of normal crypt structure in patients receiving HAART. The latter is supported by evidence showing inhibition of HIV-driven stem cell hyperproliferation at the crypt bases [29] and data showing regeneration of the mucosal epithelium following early anti-retroviral therapy with coincidental enhanced expression of mucosal repair and regeneration genes [30]. In addition, most treated patients experience dramatic reversal of the pathogen-negative diarrhoeal disease. Overall, HAART has led to significant reduction in mortality for patients with HIV/AIDS with life expectancy of adults approaching that of individuals without HIV infection.

#### Conclusion

Taken together, the occurrence of HIVE at any stage of HIV infection among all age groups, apparent absence of identifiable entero-pathogens, and evidence of regeneration of the mucosal epithelium and dramatic improvement of gut symptoms following HAART suggest a direct pathogenetic role for HIV in HIVE. Perturbations in mucosal CD4+ Th17+ and IRIE T lymphocytes lead to mucosal cytokine changes, crypt epithelial cell proliferation, and encroachment of crypt stem cells onto villi resulting in villous atrophy.

This review has inherent limitations which might impact the validity of our main conclusions. The variable quantitative assessment techniques used by different investigators confounds interpretation of the small bowel histological findings especially those relating to crypt morphology. In addition, many of the clinical studies carried variable levels of bias attributed to heterogeneous study design, misclassification of diagnostic status, and patient selection.

Further well-designed studies are required to determine whether HAART sustainably restores normal gut mucosal morphology and function.

#### Declarations of competing interest

The authors have no competing interests to declare.

## Funding

This research did not receive any specific grant from funding agencies in the public, commercial, or not-for-profit sectors.

## Author contributions

MK came up with the original concept. MK and PB drafted the initial manuscript. SF and GEG revised further drafts. All authors reviewed and approved the final manuscript.

## References

- Clumeck N, Sonnet J, Taelman H, Mascart-Lemone F, De Bruyere M, Vandepierre P, et al. Acquired immunodeficiency syndrome in African patients. *N Engl J Med* 1984;**310**:492–7. doi:10.1056/NEJM198402233100804.
- Kotler DP, Gaetz HP, Lange M, Klein EB, Holt PR. Enteropathy associated with the Acquired Immunodeficiency Syndrome. *Ann Intern Med* 1984;**101**:421–8. doi:10.7326/0003-4819-101-4-421.
- Serwadda D, Sewankambo NK, Carswell JW, Bayley AC, Tedder RS, Weiss RA, et al. SD: a new disease in Uganda and its association with HTLV-III infection. *Lancet* 1985;**2**:849–52. doi:10.1016/S0140-6736(85)90122-9.
- World Health Organization WHO clinical case definition for AIDS. *Wkly Epidemiol Rec* 1986;**61**:72.
- Smith PD, Lane HC, Gill VJ, Manischewitz JF, Quinman GV, Fauci AS, et al. Intestinal infections in patients with the acquired immunodeficiency syndrome (AIDS). Etiology and response to therapy. *Ann Intern Med* 1988;**108**:328–33. doi:10.7326/0003-4819-108-3-328.
- Miller ARO, Griffin GE, Batman P, Farquar C, Forster SM, Pinching AJ, et al. Jejunal mucosal architecture and fat absorption in male homosexuals infected with human immunodeficiency virus. *Q J Med* 1988;**69**:1009–19.
- Kapembwa MS, Fleming SC, Griffin GE, Caun K, Pinching AJ, Harris JRW. Fat absorption and exocrine pancreatic function in human immunodeficiency virus infection. *Q J Med* 1990;**74**:49–56.
- Kapembwa MS, Fleming SC, Sewankambo N, Serwadda D, Lucas S, Moody A, et al. Altered small-intestinal permeability associated with diarrhoea in human immunodeficiency virus-infected Caucasian and African subjects. *Clin Sci (Lond)* 1991;**81**:327–34. doi:10.1042/cs0810327.
- Brenchley JM, Schacker TW, Ruff LE, Price DA, Taylor JH, Beilman GJ, et al. CD4+ T cell depletion during all stages of HIV disease occurs predominantly in the gastrointestinal tract. *J Exp Med* 2004;**200**:749–59. doi:10.1084/jem.20040874.
- Brenchley JM, Paiardini M, Knox KS, Asher AI, Cervasi B, Asher TE, et al. Differential Th17 CD4 T-cell depletion in pathogenic and nonpathogenic lentiviral infections. *Blood* 2008;**112**:2826–35. doi:10.1182/blood-2008-05-159301.
- Tesmer LA, Lundy SK, Sarkar S, Fox DA. Th17 cells in human disease. *Immunol Rev* 2008;**223**:87–113.
- Lindemans CA, Calafiore M, Mertelsmann AM, O'Connor MH, Dudakov JA, Jenq RR, et al. Interleukin-22 promotes intestinal-stem-cell-mediated epithelial regeneration. *Nature* 2015;**528**:560–4. doi:10.1038/nature16460.
- Cicccone EJ, Greenwald JH, Lee PI, Biancotto A, Read SW, Yao MA, et al. CD4+ T cells, including Th17 and cycling subsets, are intact in the gut mucosa of HIV-1-infected Long-Term non-progressors. *J Virol* 2011;**85**:5880–8. doi:10.1128/JVI.02643-10.
- Garcillán B, Marin AVM, Jiménez-Reinoso A, Briones AC, Muñoz-Ruiz M, García-León MJ, et al.  $\gamma\delta$  T lymphocytes in the diagnosis of human T cell receptor immunodeficiencies. *Front Immunol* 2015;**6**:1–4. doi:10.3389/fimmu.2015.00020.
- Nilssen DE, Brandtzaeg P. Intraepithelial  $\gamma\delta$  T cells remain increased in the duodenum of AIDS patients despite antiretroviral treatment. *PLoS One* 2012;**7**:e29066. doi:10.1371/journal.pone.0029066.
- Yang H, Antony PA, Wildhaber BE, Teitelbaum DH. Intestinal intraepithelial lymphocyte gamma delta-T cell-derived keratinocyte growth factor modulates epithelial growth in the mouse. *J Immunol* 2004;**172**:4151–8. doi:10.4049/jimmunol.172.7.4151.
- Komano H, Fujiura Y, Kawaguchi M, Matsumoto S, Hashimoto Y, Obana S, et al. Homeostatic regulation of intestinal epithelia by intraepithelial  $\gamma\delta$  T cells. *Proc Natl Acad Sci U S A* 1995;**92**:6147–51. doi:10.1073/pnas.92.13.6147.
- Li Q, Estes JD, Duan L, Jessurun J, Pambuccian S, Forster C, et al. Simian immunodeficiency virus-induced intestinal cell apoptosis is the underlying mechanism of the regenerative enteropathy of early infection. *J Infect Dis* 2008;**197**:420–9. doi:10.1086/525046.
- Epple HJ, Allers K, Tröger H, Kühl A, Erben U, Fromm M, et al. Acute HIV Infection induces mucosal infiltration with CD4+ and CD8+ T cells, epithelial apoptosis, and a mucosal barrier defect. *Gastroenterology* 2010;**139**:1289–300. doi:10.1053/j.gastro.2010.06.065.
- Fleming SC, Kapembwa MS, MacDonald TT, Griffin GE. Direct in vitro infection of human intestine with HIV-1. *AIDS* 1992;**6**:1099–104. doi:10.1097/00002030-199210000-00006.
- Batman PA, Fleming SC, Sedgwick PM, MacDonald TT, Griffin GE. HIV infection of human fetal intestinal explant cultures induces epithelial cell proliferation. *AIDS* 1994;**8**:161–7. doi:10.1097/00002030-199402000-00004.
- Fox CH, Kotler D, Tierney A, Wilson CS, Fauci AS. Detection of HIV-1 RNA in the lamina propria of patients with AIDS and gastrointestinal disease. *J Infect Dis* 1989;**159**:467–71. doi:10.1093/infdis/159.3.467.
- British HIV Association BHIVA guidelines on antiretroviral treatment for adults living with HIV-1. Letchworth Garden City: British HIV Association; 2022.
- Renault C, Veyrenche N, Mennechet F, Bedin AS, Routy JP, Van de Perre P, et al. Th17 CD4+ T-cell as a preferential target for HIV reservoirs. *Front Immunol* 2022;**13**:822576 Article. doi:10.3389/fimmu.2022.822576.
- Zhang QY, Dunbar D, Ostrowska A, Zeisloft S, Yang J, Kaminsky LS, et al. Characterization of human small intestinal cytochromes P-450. *Drug Metab Dispos* 1999;**27**:804–9.
- Batman PA, Miller ARO, Sedgwick PM, Griffin GE. Autonomic denervation in jejunal mucosa of homosexual men infected with HIV. *AIDS* 1991;**5**:1247–52. doi:10.1097/00002030-199110000-00015.
- Amoani B, Sakyi SA, Barnie PA, Pomeyie K, Aniagyei W, Opoku S, et al. Effect of ART on cytokine Profile among HIV Patients: A Systematic Review and Meta-Analysis. *Focus Med Sci J* 2021;**7**:1–10.
- Epple HJ, Schneider T, Troeger H, Kunkel D, Allers K, Moos V, et al. Impairment of the intestinal barrier is evident in untreated but absent in suppressively treated HIV-infected patients. *Gut* 2009;**58**:220–7. doi:10.1136/gut.2008.150425.
- Batman PA, Kapembwa MS, Belmonte L, Tudor G, Kotler DP, Potten CS, et al. HIV enteropathy: HAART reduces HIV-induced stem cell hyperproliferation and crypt hypertrophy to normal in jejunal mucosa. *J Clin Pathol* 2014;**67**:14–18. doi:10.1136/jclinpath-2012-201289.
- Guadalupe M, Sankaran S, George MD, Reay E, Verhoeven D, Shacklett BL, et al. Viral suppression and immune restoration in the gastrointestinal mucosa of human immunodeficiency virus type 1-infected patients initiating therapy during primary or chronic infection. *J Virol* 2006;**80**:8236–47. doi:10.1128/JVI.00120-06.