

Mario Rašić<sup>1</sup>, Matija Mamić<sup>2</sup>, Josip Biočić<sup>3</sup>, Ivica Lukšić<sup>2</sup>

## Intranasal supernumerary tooth: two case reports and review of the literature

### Intranazalni prekobrojni zub: prikaz dvaju slučajeva i pregled literature

<sup>1</sup> University Hospital Centre "Sestre milosrdnice", Clinic for tumors, Ilica 197, 10000 Zagreb, Croatia  
*Klinika za tumore KBC-a Sestre milosrdnice, Zagreb, Hrvatska*

<sup>2</sup> University of Zagreb School of Medicine, Department of Maxillofacial and Oral Surgery, University Hospital Dubrava, Avenue Gojko Susak 6, 10000 Zagreb, Croatia  
*KB Dubrava – Klinika za maksilofacijalnu i oralnu kirurgiju Medicinskog fakulteta Sveučilišta u Zagrebu, Hrvatska*

<sup>3</sup> University of Zagreb School of Dental Medicine, Department of Maxillofacial and Oral Surgery, University Hospital Dubrava, Avenue Gojko Susak 6, 10000 Zagreb, Croatia  
*KB Dubrava – Klinika za maksilofacijalnu i oralnu kirurgiju Stomatološkog fakulteta Sveučilišta u Zagrebu, Hrvatska*

#### Abstract

The presence of supernumerary tooth (SNT) in the nasal cavity is a rare condition with limited literature data. We report two cases with a history of nasal obstruction and difficulty breathing. In both cases, clinical and radiological examination confirmed intranasal SNT. Extractions were executed in general anesthesia using Rochester-Pean instruments transnasally. In addition, a literature review of intranasal SNT was performed. The database search retrieved a total number of 50 cases in time period from 1970. to 2020. Mean age of patients was 22.5 years. Most common symptoms were unilateral obstruction of breathing and headache. Surgical extraction of intranasal SNT is recommended to eliminate the symptoms.

**Received:** September 7, 2023

**Accepted:** November 2, 2023

#### Address for correspondence

Mario Rašić, MD  
Clinic for tumors  
University Hospital Centre "Sestre milosrdnice"  
Ilica 197, 10000 Zagreb, Croatia  
Phone: +385 919335166  
mario.rasic8@gmail.com

**MeSH Terms:** Supernumerary Tooth; Nasal Cavity; Natural Orifice Endoscopic Surgery; Odontogenesis

**Author Keywords:** Tooth, Supernumerary; Nasal Cavity; Odontogenesis; Surgical Removal

Mario Rašić: 0000-0002-3402-2123  
Matija Mamić: 0000-0002-3117-2943

Josip Biočić: 0000-0002-8459-5042  
Ivica Lukšić: 0000-0002-9138-2037

## Introduction

The presence of the tooth in the nasal cavity is an uncommon clinical finding. Because of its rare occurrence, the literature is limited, usually based on individual case reports or small case series. The cause of this rare anomaly may be either an aberration of the regular dentition or a supernumerary tooth (SNT) (1). Different theories about the intranasal SNT exist, but none have been proven to date (2). It usually deviates morphologically from the biologically normal teeth presenting most frequently as a conical form.

The prevalence of the SNT in the general population is 0.1-1%, without sex and age related predilection (2). It is most commonly found on routine examination as a random finding. The true occurrence of intranasal SNT is difficult to predict because of its relative indolent and asymptomatic course. Its anatomical position in the nasal cavity may

## Uvod

Prisutnost zuba u nosnoj šupljini rijedak je klinički nalaz. Zbog toga što je to rijetka pojava, podatci u literaturi su ograničeni i obično se temelje na pojedinačnim prikazima slučajeva ili malim serijama slučajeva. Uzrok za tu rijetku anomaliju može biti ili aberacija pravilne denticije ili prekobrojni zub (1). Postoje različite teorije o intranazalnom prekobrojnom zubu, ali ni jedna do danas nije dokazana (2). Morfološki obično odstupa od biološki normalnih zuba te je najčešće stožastog oblika.

Prevalencija prekobrojnog zuba u općoj populaciji iznosi od 0,1 do 1 %, bez spolno-dobne sklonosti (2). Najčešće se nalazi slučajno tijekom rutinskog pregleda. Pravu pojavu intranazalnog prekobrojnog zuba teško je predvidjeti zbog razmjerno indolentnog i asimptomatskog tijeka. Njegov anatomski položaj u nosnoj šupljini može stisnuti okolne struk-

compress surrounding structures and consequently produce symptoms. The most common symptoms are the unilateral obstruction of breathing, the appearance of unpleasant nasal odors, nasal bleeding and infection, headache, middle-face pain and crusting of nasal mucosa (3). Diagnostic procedures sufficient to set up the diagnosis and to determine the extension of intranasal process include inspection and radiological examination. Differential diagnosis could potentially include foreign body in the nasal cavity, calcifying tumors, cysts and rhinoliths (4).

Different therapeutic methods in the treatment of the intranasal SNT have been noted (5-9). Recent reports put emphasis on endoscopic treatment as an effective replacement of traditional surgery (2). The aims of this paper were to report two new cases of the intranasal SNT and to make a literature review on the existing subject.

## Clinical Case Reports

### Case report 1

A 46-year-old male presented to our institution with a difficulty in nasal breathing. He reported minor, undefined disturbances in the right nasal cavity which had persisted for several years. His medical history included soft tissue facial trauma in a childhood without any systemic diseases. Family history revealed that his daughter was several times surgically treated for a SNT but insufficient medical documentation was provided for an assessment. The patient had a fixed partial denture in the anterior maxilla for 5 years. MSCT examination revealed SNT extending from the right osseous nasal floor to the area of right nasal cavity. The tooth was surrounded by radio-opaque material. It was decided to treat the patient in general anesthesia. Extraction was performed transnasally using simple instruments (Rochester-Pean forceps) (Figure 1). The postoperative period passed without surgical complications with a full relief of symptoms. A three-year follow-up period was uneventful.

### Case report 2

A 60-year-old male presented to our institution with difficult left-sided nasal breathing which persisted for two months. His medical history excluded trauma and his family history was unsuspecting. His dentition was clinically normal, without prosthetic rehabilitation or any other dental treatment. MSCT examination revealed a diagonally positioned SNT in the lower nasal corridor. The tooth was surrounded by thick mucosa and multiple calcified, nodular, sharply bound radio-opaque materials. The nasal septum slightly deviated to the left side. It was decided to treat the patient in general anesthesia. Extraction was performed transnasally using simple instruments (Rochester-Pean forceps) (Figure 2). The postoperative period passed without surgical complications with a full recovery. A three-year follow-up period was uneventful.

ture i posljedično prouzročiti simptome, a najčešći su jednastrana opstrukcija disanja, pojava neugodnih mirisa iz nosa, krvarenje iz nosa i infekcija, glavobolja, bol u srednjem dijelu lica i krusta nosne sluznice (3). Inspekcija i radiografski pregled dovoljni su dijagnostički postupci za postavljanje dijagnoze i utvrđivanje proširenosti intranasalnog procesa. Diferencijalna dijagnoza potencijalno može uključivati strano tijelo u nosnoj šupljini, kalcificirajuće tumore, ciste i rinolite (4).

Uočene su različite terapijske metode u liječenju intranasalnog prekobrojnog zuba (5 – 9). U novijim izvješćima autori ističu endoskopsko liječenje kao učinkovitu zamjenu za tradicionalni kirurški postupak (2). Svrha ovoga rada jest prikazati dva nova slučaja intranasalnog prekobrojnog zuba i pregledati literaturu o toj temi.

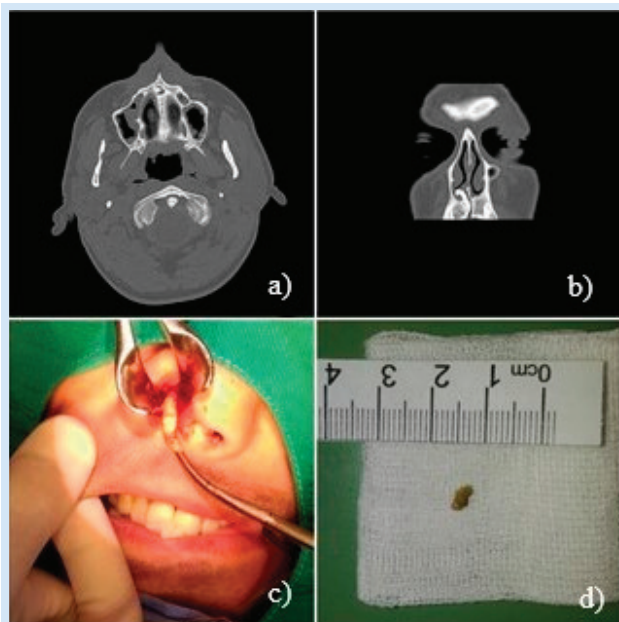
## Prikazi kliničkih slučajeva

### Prikaz slučaja 1

Muškarac u dobi od 46 godina došao je u našu ustanovu zbog otežanog disanja na nos. Već nekoliko godina žalio se na manje, nedefinirane smetnje u desnoj nosnoj šupljini. U njegovoj povijesti bolesti zabilježena je trauma mekoga tkiva lica u djetinjstvu, bez ikakvih sistemskih bolesti. Obiteljska povijest otkrila je da je njegova kći nekoliko puta kirurški liječena zbog prekobrojnog zuba, ali nije dostavljeno dovoljno medicinske dokumentacije za procjenu. Pacijent je pet godina nosio fiksnu parcijalnu protezu na gornjoj čeljusti. MSCT pregledom utvrđeno je postojanje prekobrojnog zuba koji se proteže od desnoga koštanog dna nosa do područja desne nosne šupljine. Zub je bio okružen radionepropusnim materijalom. Terapija izbora bila je kirurško liječenje u općoj anesteziji. Ekstrakcija je obavljena transnazalno jednostavnim instrumentima (Rochester-Peanova pinceta) (slika 1.). Postoperativno razdoblje prošlo je bez kirurških komplikacija, uz potpuno ublažavanje simptoma. Trogodišnje razdoblje praćenja bilo je bez problema.

### Prikaz slučaja 2

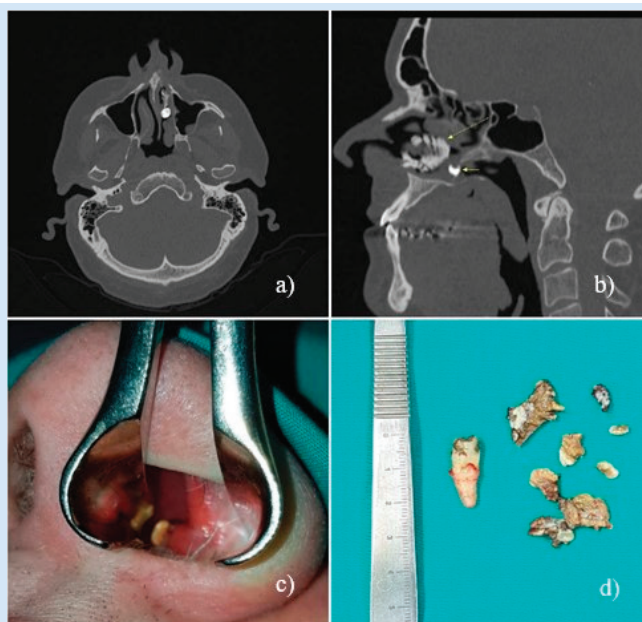
Muškarac u dobi od 60 godina došao je u našu ustanovu s otežanim lijevostranim disanjem na nos koje traje već dva mjeseca. Anamnestički je negirao traumu lica, a njegova obiteljska povijest nije bila sumnjiva. Denticija je bila klinički uredna, bez protetičke rehabilitacije, ili bilo kakvog drugog stomatološkog tretmana. MSCT pregledom otkriven je dijagonalno postavljen prekobrojni zub u donjem nosnom hodniku. Bio je okružen debelom sluznicom i višestrukim kalcificiranim, nodularnim, oštro vezanim radionepropusnim materijalima. Nosna pregrada blago je iskrivljena u lijevu stranu. Odlučeno je da će se pacijenta liječiti u općoj anesteziji pa je ekstrakcija prekobrojnog zuba obavljena transnazalno jednostavnim instrumentima (Rochester-Peanova pinceta) (slika 2.). Postoperativno razdoblje proteklo je bez kirurških komplikacija, uz potpuni oporavak. U trogodišnjem razdoblju praćenja nije bilo problema.



**Figure 1** Clinical features of Case report 1.  
a,b) MSCT showing SNT extending from the right osseous nasal floor to the area of right nasal cavity. c) Exposure provided by nasal speculum. d) SNT after removal.

**Slika 1.** Kliničke značajke slučaja 1

a, b) MSCT pokazuje intranasalni prekobrojni zub koji se proteže od desnoga koštanog dna nosa do područja desne nosne šupljine; c) prikaz s pomoću nosnog spekulum; d) prekobrojni zub poslije uklanjanja



**Figure 2** Clinical features of Case report 2.  
a,b) MSCT showing nasal tooth and slight deviation of the nasal septum c) nasal speculum examination d) Tooth and sharply bound radio-opaque material after removal.

**Slika 2.** Kliničke značajke slučaja 2

a, b) MSCT s prikazom intranasalnoga prekobrojnog zuba i blagom devijacijom nosnog septuma; c) pregled nosa spekulumom; d) zub i oštro vezani radionepropusni materijal poslije vadenja

## Literature Review

The studies and analyses examined in the present paper are a result of text mining and database searching through Medline/PubMed database, as well as individual journal search for all results retrieved by searches of general terms such as "supernumerary tooth", "inverted supernumerary tooth", "sino-nasal cavity tooth", "intranasal supernumerary tooth", "supernumerary teeth" and their combination. PubMed cross-references were used to obtain additional articles. Only English written articles reporting intranasal SNT were analyzed.

The database search retrieved a total number of 50 cases in time period from 1970 to 2020. Mean age of the patients was 22.5 years (ranging from 2 to 64 years) with male sex dominance (33/50, 66%). The majority of patients (66%) had symptoms and the most common symptom was unilateral obstruction of breathing. The nasal floor was the most frequent localization of the SNT in the nasal cavity while the most common side was the left side. Intranasal SNT had also been reported in patients with craniofacial anomalies such as cleft lip, alveolus, and palate. Clinicopathologic characteristics of included patients are presented in Table 1.

## Discussion

The presence of an intranasal tooth is a rare clinical finding. It is important to distinguish SNT from the aberrations of normal deciduous or permanent teeth which present a separate entity. As an aberration, teeth or a tooth, usual-

## Pregled literature

Pronađene studije i njihova analiza u ovom radu rezultat su pretraživanja baze podataka Medline/PubMed. Također je rezultat pretraživanja pojedinačnih časopisa s ključnim riječima: *prekobrojni zub*, *obrnuti prekobrojni zub*, *zub nosne šupljine*, *intranazalni prekobrojni zub*, *prekobrojni zubi* i njihovih kombinacija. PubMedove ukrižene referencije korisne su za dobivanje dodatnih članaka. Analizirani su samo oni na engleskome jeziku koji izvješćuju o intranasalnom prekobrojnom zubu.

Pretraživanjem baze podataka pronađeno je ukupno 50 slučajeva u razdoblju od 1970. do 2020. godine. Prosječna dob pacijenata bila je 22,5 godine (raspon od 2 do 64 godine) s dominacijom muškog spola (33/50, 66%). Većina njih (66%) imala je simptome, a najčešće je bila riječ o jednostranoj opstrukciji disanja. Dno nosa najčešća je lokalizacija prekobrojnog zuba u nosnoj šupljini, a najčešće se pojavljuje na lijevoj strani. Intranazalni prekobrojni zub također je prijavljen kod pacijenata s kraniofacijalnim anomalijama poput rascjepa usne, alveole i nepca. Klinička i patološka obilježja kod uključenih pacijenata prikazana su u tablici 1.

## Rasprava

Intranazalni prekobrojni zub rijedak je klinički nalaz. Važno je razlikovati prekobrojni zub od aberacija normalnih mliječnih ili trajnih zuba koji su zasebna cjelina. Kao aberacija, zubi ili zub, obično su prisutni u kranio-facijalnim ili

**Table 1** Clinicopathologic characteristics of revied cohort.  
**Tablica 1.** Kliničko-patološke karakteristike pregledane kohorte

Authors	Number of cases	Gender	Age	Symptoms	Approach
Kohli and Verma, 1970. <sup>5</sup>	1	Male	13	Yes	Nasal speculum
Arora et al., 1973. <sup>6</sup>	1	Male	14	Yes	Nasal speculum
Sood and Kakar, 1975. <sup>7</sup>	1 of 2	Male	28	No	Not reported
	2 of 2	Male	12	Yes	Not reported
Thawley et al., 1977. <sup>3</sup>	1	Female	25	No	Patient denied operation
Smith et al., 1979. <sup>8</sup>	1 of 2	Male	14	No	Nasal speculum
	2 of 2	Female	34	Yes	Patient denied operation
Murty et al., 1988. <sup>9</sup>	1	Male	30	Yes	Nasal speculum
Pracy et al., 1992. <sup>10</sup>	1	Male	30	Yes	Nasal speculum
Nastri et Smith, 1996. <sup>11</sup>	1	Female	18	Yes	Nasal speculum
Chamyal PC, 1997. <sup>12</sup>	1	Male	19	Yes	Maxillary approach
Chen et al., 2002. <sup>13</sup>	1	Male	8	Yes	Endoscope
Kim et al., 2003. <sup>14</sup>	1	Male	12	No	Endoscope
Kuroda et al., 2003. <sup>15</sup>	1	Male	27	Yes	Nasal Speculum
	1 of 3	Female	16	Yes	Endoscope
Lin et al., 2004. <sup>16</sup>	2 of 3	Male	21	Yes	Endoscope
	3 of 3	Female	16	Yes	Endoscope
Sokolov et al., 2004. <sup>17</sup>	1 of 2	Female	22	Yes	Not reported
	2 of 2	Female	36	Yes	Microscope
Lee, 2006. <sup>18</sup>	1	Male	61	Yes	Endoscope
Kirmeier et al., 2009. <sup>1</sup>	1	Female	49	Yes	Microscope
Janardhan et al., 2012. <sup>19</sup>	1	Male	30	Yes	Endoscope
Iwai et al., 2012. <sup>4</sup>	1	Male	27	Yes	Endoscope
Krishnans et al., 2013. <sup>20</sup>	1	Female	13	Yes	Endoscope
Mohebbi et al., 2013. <sup>21</sup>	1	Male	19	Yes	Not reported
Van Essen and Van Rijswijk, 2013. <sup>22</sup>	1	Male	26	Yes	Nasal speculum
Dhaferi et al., 2014. <sup>23</sup>	1	Male	22	Yes	Endoscope

ly present in the cranio-facial or systemic anomalies such as cleft palate, Gardner's syndrome and cleidocranial dysostosis (3, 13). There are some reports where the presence of multiple supernumerary teeth is non-syndrome associated (33,34). Early childhood orofacial trauma can also be a consequence of the intranasal tooth persistence (2). The evolutionary theories about SNT are debatable due to largely unexploited biological and genetic mechanisms. The atavistic theory that assumes the existence of the third dental lamina in the region of premaxilla is abandoned because there have not been any pathological and clinical confirmations (35). Some authors consider the hypothesis that a possible etiological factor for the development of a SNT might entail origination from an additional local splinting or independent hyperactivity of the dental lamina (3). The inverted *mesiodens* that has erupted in nasal cavity as a SNT was discussed by some authors (36, 37). There are reports presenting the embryonic theory of lagging in the migration of the fronto-nasal neural crest cells before the end of the fifth embryonic week causing ectopic development of tooth germs in premaxilla (38, 39). Our first case report suggests, through the family history, that hereditary factors could be involved. A similar consideration was reported by Shafer, W.C., Hine, M.K. and Levy, B. M as well as by Anthonappa RP, King NM, Rabie AB (38, 39).

sistemskim anomalijama kao što su rascjep nepca, Gardnerov sindrom i kleidokranijalna displazija (lat. *dysostosis cleidocranialis*) (3,13). Postoje i izvješća u kojima pojava višestrukih prekobrojnih zuba nije povezana sa sindromima (33, 34). Orofacijalna trauma u ranom djetinjstvu također može biti uzrok za pojavu intranazalnog zuba (2). Evolucijske teorije o prekobrojnim zubima predmet su rasprava uglavnom zbog neistraženih bioloških i genetskih mehanizama. Atavistička teorija koja pretpostavlja postojanje treće dentalne lamine u predjelu premaksile odbačena je jer nije bilo patološke i kliničke potvrde (35). Neki autori smatraju da bi etiološki čimbenik za pojavu prekobrojnog zuba mogao biti lokalno dijeljenje i neovisna hiperaktivnost dentalne lamine (3). Također postoji rasprava o invertiranom meziodensu koji je izbio u nosnu šupljinu kao prekobrojni zub (36, 37). Nadalje, pojedini autori ističu teoriju o embrionalnom zaostajanju u migraciji stanica fronto-nazalnoga neuralnog grebena prije kraja petog embrionalnog tjedna, što uzrokuje ektopični razvoj zubnih stanica u premaksili (38, 39). Naš prvi prikaz slučaja sugerira, promatrajući obiteljsku povijest, da bi u pojavu prekobrojnoga intranazalnog zuba mogli biti uključeni nasljedni čimbenici, što smatraju i pojedini autori (38, 39).

Marshal je 1886. godine prvi opisao tipične simptome za intranazalni prekobrojni zub kao što su začepljenost nosa i jaka glavobolja (40). U međuvremenu su prijavljeni različiti

In 1886, Marshal was the first to describe typical symptoms of an intranasal tooth such as nasal obstruction and strong headache (40). Meanwhile, different symptoms and signs indicating the presence of supernumerary teeth had been reported, including unilateral obstruction, chronic nasal discharge, crusting of nasal mucosa, nasal pain, epistaxis, facial pain and headache, perforation of nasal septum (17, 19, 23). However, intranasal SNT may be asymptomatic and only incidentally recognized during routine clinical or radiologic examination. Differential diagnoses of an intranasal dense radiopaque shadow include a foreign body, bony sequestrum, neoplasm, exostosis and rhinolith.

The diagnosis of nasal tooth is mainly based on clinical examination and imaging methods. Considering an optimal time for SNT removal, it seems reasonable to do it when the roots of the permanent tooth have completely formed in order to avoid their injury. While surgical extraction of SNT is a standard method of treatment, no recommendations exist regarding optimal surgical approach. The most frequent approach described in literature is extraction of the tooth transnasally with a speculum or with an endoscopic assistance. Some authors advocate extraction of intranasal SNT endoscopically as a standard procedure because the endoscope enables a clear visualization of the tooth's insertion and allows a precise dissection (2, 29, 31).

In conclusion, intranasal SNT is a rare condition with headache and nasal obstruction as leading symptoms. A differential diagnosis is important to exclude possible temporary nasal obstacles and neoplasms. Clinical examination and radiography are sufficient diagnostic methods. Minimally invasive surgical extraction with an endoscopic assistance transnasally is an optimal method in the treatment of intranasal SNT.

### Funding

No author received any material or financial gain or personal advancement in the production of this manuscript.

### Competing Interests

Authors have no competing interests.

### Ethical Approval

The Ethics Board of University Hospital Dubrava have decided that a special ethical approval is not needed because all individuals involved in this study signed written patient consent.

### Patient Consent

Written patient consent has been obtained.

**Author's Contribution:** M. R. - conceived the presented idea, developed the theory, performed the sample gathering and drafted the manuscript; M. M. - manuscript and data research; J. B. - provided critical feedback and helped shape the paper; I. L. - supervised the work and were in charge of overall direction and planning

ti simptomi i znakovi prekobrojnog zuba, uključujući jednostranu opstrukciju, kronični iscjedak iz nosa, stvaranje krusta na nosnoj sluznici, bol u nosu, epistaksu, bol lica i glavobolju i perforaciju nosnog septuma (17, 19, 23). No intranasalni prekobrojni zub može biti asimptomatski i tek slučajno pronađen tijekom rutinske kliničke ili radiološke pretrage. Diferencijalna dijagnoza intranasalne guste radionepropusne sjene uključuje strano tijelo, koštani sekvstrum, neoplazmu, egzostozu i rinolit.

Dijagnoza intranasalnog prekobrojnog zuba uglavnom se temelji na kliničkom pregledu i slikovnim metodama. Smatramo da je optimalno vrijeme za kirurško liječenje intranasalnog prekobrojnog zuba kada su korijeni potpuno formirani kako bi se izbjegla njihova moguća ozljeda. Dok je kirurška ekstrakcija standardna metoda liječenja, ne postoje preporuke o optimalnom kirurškom pristupu. Najčešći pristup opisan u literaturi jest vađenje zuba transnazalno spekulomom ili uz endoskopsku pomoć. Neki autori zagovaraju kao standardni postupak ekstrakciju intranasalnoga prekobrojnog zuba endoskopski jer endoskop omogućuje jasnu vizualizaciju insercije zuba i preciznu disekciju (2, 29, 31).

Zaključno, intranasalni prekobrojni zub rijetko je stanje s glavoboljom i nazalnom opstrukcijom kao vodećim simptomima. Diferencijalna dijagnoza važna je za isključivanje mogućih privremenih nosnih začepjenja i neoplazmi. Klinički pregled i radiografske snimke dovoljne su dijagnostičke pretrage za dijagnozu prekobrojnog zuba. Smatramo da je minimalno invazivna kirurška ekstrakcija uz endoskopsku pomoć transnazalno, metoda izbora u liječenju intranasalnoga prekobrojnog zuba.

### Financiranje

Nijedan autor nije imao nikakvu materijalnu ili financijsku dobit.

### Konkurentski interesi

Autori nemaju konkurentskih interesa.

### Etičko odobrenje

Etičko povjerenstvo KB-a Dubrava odlučilo je da posebno etičko odobrenje nije potrebno jer su svi uključeni u ovo istraživanje dobili pisani pristanak pacijenata.

### Pristanak pacijenta

Pacijenti su potpisali pristanak za sudjelovanje u studiji.

**Doprinos autora:** M. R. – osmišljavanje teme, razvoj teorije, prikupljanje uzoraka i izrada preliminarne verzije rada; M. M. – pisanje teksta i istraživanje podataka; J. B. – kritičke povratne informacije i pomoć pri oblikovanju rada; I. L. – nadzor i cjelokupno usmjeravanje i planiranje

**Sažetak**

Prekobrojni zub u nosnoj šupljini rijetko je stanje o kojemu postoje ograničeni literaturni podatci. U ovom radu predstavljena su dva slučaja sa simptomima nazalne opstrukcije i otežanog disanja. U oba slučaja klinička i radiološka pretraga potvrdila je da postoji intranasalni prekobrojni zub. Ekstrakcije su obavljene transnazalno u općoj anesteziji Rochester-Peanovim instrumentima. Uz to, pregledana je literatura o prekobrojnim intranasalnim zubima. Pretragom baze podataka pronađeno je ukupno 50 slučajeva u razdoblju od 1970. do 2020. godine. Prosječna dob pacijenata bila je 22,5 godine. Najčešći simptomi bili su jednostrana opstrukcija disanja i glavobolja, a za njihovo uklanjanje preporučeno je kirurško vađenje prekobrojnoga intranasalnog zuba.

**Zaprimljen:** 7. rujan 2023.

**Prihvaćen:** 2. studeni 2023.

**Adresa za dopisivanje**

Mario Rašić, dr. med.  
Klinika za tumore  
Klinički bolnički centar Sestre  
milosrdnice  
Ilica 197, 10 000 Zagreb, Hrvatska  
mob: +385 919335166  
mario.rasic8@gmail.com

**MeSH pojmovi:** prekobrojni zub; nosna šupljina; endoskopska kirurgija kroz prirodni otvor; odontogeneza  
**Autorske ključne riječi:** prekobrojni zub, nosna šupljina, odontogeneza, kirurško uklanjanje

**References**

- Kirmeier R, Truschnegg A, Payer M, Malyk J, Daghighi S, Jakse N. The supernumerary nasal tooth. *J Oral Sci.* 2010 Dec;52(4):577-81.
- Jin K-F, Lou Z-C, Lou Z-H. The diagnosis and management of supernumerary nasal teeth. *J Laryngol Otol.* 2019 Jun;133(6):538-541.
- Thawley SE, LaFerriere KA. Supernumerary nasal tooth. *Laryngoscope* 1977; 1770-3
- Iwai T, Aoki N, Yamashita Y, Omura S, Matsui Y, Maegawa J. et al. *J Oral Maxillofac Surg.* 2012 May;70(5):1030-4.
- Kohli GS, Verma PL. Ectopic supernumerary tooth in the nasal cavity. *J Laryngol Otol.* 84:537-538.
- Arora MM, Grewal BS, Coonar HS. Dentigerous cyst from supernumerary tooth in the nasal cavity. *J Indian Dent Assoc.* 1973 Apr;45(4):85-6.
- Sood VP, Kakar PK. *Eye Ear Nose Throat Mon.* 1975 Sep;54(9):343-5.
- Smith RA, Gordon NC, De Luchi SF. Intranasal teeth. Report of two cases and review of the literature. *Oral Surg Oral Med Oral Pathol.* 1979 Feb;47(2):120-2.
- Murty PS, Hazarika P, Hebbar GK. Supernumerary nasal teeth. *J Oral Maxillofac Pathol.* 2021 May-Aug;25(2):373-374.
- Pracy JP, Williams HO, Montgomery PQ. Nasal teeth. *J Laryngol Otol.* 1992 Apr;106(4):366-7.
- Nastri AL, Smith AC. The nasal tooth. Case report. *Aust Dent J.* 1996 Jun;41(3):176-7.
- Accorona R, Colombo G, Ferrari M, Fazio E, Bolzoni-Villaret A. Inverted Supernumerary Intranasal Teeth as Unusual Indications of Endoscopic Surgery. *Iran J Otorhinolaryngol.* 2020;32(110):181-186. doi: 10.22038/ijorl.2019.38918.2284.
- Chen A, Huang JK, Cheng SJ, Sheu CY. Nasal teeth: report of three cases. *AJNR Am J Neuroradiol.* 2002 Apr;23(4):671-3.
- Kim DH, Kim JM, Chae SW, Hwang SJ, Lee SH, Lee HM. Endoscopic removal of an intranasal ectopic tooth. *Indian J Otolaryngol Head Neck Surg.* 2019 Nov;71(Suppl 3):2036-2038.
- Kuroda H, Tsutsumi K, Tomisawa H, Koizuka I. A case of an inverted tooth in the nasal cavity. *Auris Nasus Larynx.* 2003 Feb;30 Suppl:S127-9.
- Lin IH, Hwang CF, Su CY, Kao YF, Peng JP. Intranasal tooth: report of three cases. *Chang Gung Med J.* 2004 May;27(5):385-9.
- Sokolov M, Jecker P, Roth Y. Nasal teeth associated with rhinosinusitis. *Rhinology.* 2004 Jun;42(2):107-10.
- Lee JH. A nasal tooth associated with septal perforation: a rare occurrence. *Eur Arch Otorhinolaryngol.* 2006 Nov;263(11):1055-6.
- Janardhan N, Kumar SR, Raghavendra Reddy R, Aruna Kumar C. Rhinolithiasis due to supernumerary ectopic tooth: very rare case. *Indian J Otolaryngol Head Neck Surg.* 2013 Dec;65(4):383-4.
- Krishnan B, Parida PK, Gopalakrishnan S, Satyparakash MV. An unusual cause of epistaxis in a young patient: the supernumerary nasal tooth. *Oral Maxillofac Surg.* 2013 Dec;17(4):315-7.
- Mohebbi S, Salehi O, Ebrahimipour S. Ectopic supernumerary tooth in nasal septum: a case study. *Iran J Otorhinolaryngol.* 2013 Jun;25(72):183-6.
- Van Essen TA, Van Rijswijk JB. 'Intranasal toothache': case report. *J Laryngol Otol.* 127:321-322.
- Al Dhaferi HO, Kavarodi A, Al Shaikh K, Bukhari A, Al Hussain O, El Baramawy A. Recurrent epistaxis caused by an intranasal supernumerary tooth in a young adult. *Am J Case Rep.* 2014 Jul 5:15:291-3.
- Sakat MSS, Kilic K, Gozeler MS, Ucuncu H, Kuduban O. An incidentally discovered nasal supernumerary tooth. *J Craniofac Surg.* 2015 Sep;26(6):2024-5.
- Sukegawa S, Kanno T, Kawakami K, Shibata A, Takahashi Y, Furuiki Y. Use of a piezosurgery technique to remove a deeply impacted supernumerary tooth in the anterior maxilla. *Case Rep Dent.* 2015:2015:974169.
- Ogane S, Watanabe A, Takano N, Shibahara T. Case of inverted supernumerary tooth in nasal cavity. *Bull Tokyo Dent Coll.* 2017;58(4):255-258.
- Hauer L, Hrusak D, Jambura J, Gencur J, Hosticka L, Andrlje P, et al. *J Craniomaxillofac Surg.* 2019 Jan;47(1):1-5.
- Costa SM, de Jesus AO, Silveira RL, Amaral MBF. Supernumerary nasal tooth removed with a modified maxillary vestibular approach: case report and literature review. *Oral Maxillofac Surg.* 2019 Jun;23(2):247-252.
- Indeewar H, Dutt SN. *Indian J Otolaryngol Head Neck Surg.* 2019 Nov;71(Suppl 3):2036-2038.
- Hoang MD, Saha A, McMillan B. Chronic odontogenic nasal discharge: report of two cases. *Aust Dent J.* 2021 Jun;66(2):201-204.
- Accorona R, Colombo G, Ferrari M, Fazio E, Bolzoni-Villaret A. *Iran J Otorhinolaryngol.* 2020 May;32(110):181-186.
- Kumar V, Bhaskar A, Kapoor R, Malik P. *BMJ Case Rep.* 2020 Jul 28;13.
- Dzemidzic V, Filipović M, Tiro A, Nakas E, Šalaga S. Multiple supernumerary teeth not associated with complex syndromes: A case report. *Acta Stomatologica Croatica.* 2009;43. 248-255.
- Meric U, Amila B, Nihan A, Vakur O. Supernumerary Teeth Associated with Third Molar Impaction: a Case Report. *Acta Stomatologica Croatica* 2010; 44(2):123-127.
- Liu JF. Characteristics of premaxillary supernumerary teeth: a survey of 112 cases. *ASDC J Dent Child.* 1995 Jul-Aug;62(4):262-5.
- Chopra SS, Joshi MR. Mesiodens erupted in the nasal cavity. Report of a case. *Oral Surg Oral Med Oral Pathol.* 1969 Dec;28(6):856-8.
- Quinn JH, Lewis M. Bilateral inverted supernumerary central incisors penetrating nasal cavity: report of case. *J Oral Surg Anesth Hosp Dent Serv.* 1959 Nov;17:61-2.
- Shafer WC, Hine MK, Levy BM. *Textbook of Oral Pathology.* W.B Saunders Co: Philadelphia; 1974. pp. 42-44.
- Anthonappa RP, King NM, Rabie AB. Aetiology of supernumerary teeth: A literature review. *Eur Arch Paediatr Dent.* 2013 Oct;14(5):279-88.
- Marshall JS. A superior wisdom tooth discharged from the nasal passages with remarks. *Am J Dent Sci.* 1887 Jan;20(9):408-411.