

# CLINICAL AND MORPHOLOGICAL CHARACTERISTICS AND EVALUATION OF TORUS TUBARIUS IN CHILDREN WITH PHARYNGEAL TONSIL HYPERTROPHY

Kateryna V. Liakh<sup>1,2</sup>, Serhii P. Luhovskyi<sup>3</sup>, Anatoliy L. Kosakovskiy<sup>2</sup>, Yaroslav V. Shkorbotun<sup>1</sup>, Mykola A. Skoryk<sup>4</sup>

1 – State Institution of Science «Research and Practical Center of Preventive and Clinical Medicine» State Administrative Department, Kyiv, Ukraine

2 – Shupyk National University of Healthcare of Ukraine., Kyiv, Ukraine

3 – Dmitry F. Chebotarev Institute of Gerontology of the National Academy of Medical Sciences of Ukraine, Kyiv, Ukraine

4 – G.V. Kurdyumov Institute for Metal Physics of the National Academy of Sciences of Ukraine, Kyiv, Ukraine

## Summary

**Introduction:** Among children with hypertrophy of pharyngeal tonsils undergoing adenoidectomy, 31.3 % of cases show hypertrophy of the torus tubarius, even in the absence of middle ear pathology. However, the nature of the changes in this anatomical area in these children has not been described.

**The aim of the study:** to investigate and evaluate morphological changes of pharyngeal tonsil and torus tubarius in children with hypertrophy of pharyngeal tonsil.

**Materials and methods:** histological investigation and scanning electron microscopy were performed on fragments of pharyngeal tonsil and torus tubarius, obtained during adenoidectomy of 12 children with nasal breathing disturbances (Group 1) and 13 children with concomitant inflammatory diseases of the upper respiratory tract (Group 2).

**Results:** In patients of Group 2, changes in the pharyngeal tonsil were more pronounced, showing inflammatory alterations such as infiltration by polymorphonuclear leukocytes in the covering epithelium and subepithelial layer, as well as lymphocytes in the covering epithelium, along with the presence of fibrosis compared to patients of Group 1. Additionally, samples covered by biofilms were significantly more frequently identified in Group 2 compared to Group 1 (53.8 % vs. 16.6 %,  $p < 0.05$ ). The mucosal changes in the torus tubarius corresponded to the nature of the changes observed in the pharyngeal tonsil in the respective group. Biofilms in the torus tubarius samples were found in 38.5 % of cases in Group 2 and 8.3 % of cases in Group 1 ( $p < 0.05$ ).

**Conclusions:** 1. In children with hypertrophy of pharyngeal tonsil and torus tubarius, the morphological characteristics of the mucous membrane of torus tubarius are similar to those observed in the mucous membrane of pharyngeal tonsil of the respective group. 2. Biofilms were reliably more frequently identified on the surface of pharyngeal tonsil and torus tubarius in children with upper respiratory tract infections than in patients with nasal breathing disturbances. 3. The detected changes provide a basis for revising the therapeutic approach to hypertrophic torus tubarius in children with pharyngeal tonsil hypertrophy.

**Key words:** torus tubarius, lymphoid tissue, morphology, fibrosis, biofilms, inflammatory diseases of the upper respiratory tract, tonsil

## INTRODUCTION

The pathology of the pharyngeal lymphoid ring takes a leading position among ENT disorders in children [13]. Primarily, this is associated with the peak

development of lymphoid tissue during this life period [6], which is a response to the high antigenic load during the formation of acquired immunity [11]. Hypertrophy of the pharyngeal tonsils (PT) is characterized by a wide range of symptoms related to mechanical obstruction

of the airways and often accompanied by chronic inflammation of the mucous membrane (MM) of PT, as well as inflammation of the paranasal sinuses and middle ear, often requiring adenoidectomy. However, lymphoid tissue (LT) of the nasopharynx, in addition to PT, is also represented by tubal tonsils and clusters of LT on the torus tubarius (TT). Moreover, these anatomical structures are frequently overlooked by medical professionals [9]. Given the localization of these anatomical formations, they are most commonly the focus of researchers in patients with middle ear pathology [8] or in children with insufficient clinical efficacy of adenoidectomy manifested as nasal breathing disturbances and sleep apnea [8, 16]. In the latter case, the enlargement of LT on TT, often considered part of the tubal tonsil in publications [3, 10], is regarded as a compensatory reaction to the absence of PT after adenoidectomy [8]. However, in our previous study, it was found that 31.3 % of patients requiring adenoidectomy had hypertrophy of TT [9]. This prompted us to further investigate this anatomical area.

### THE AIM OF THE STUDY

To investigate the morphological features of PT and TT in children with hypertrophy of PT, depending on the primary pathogenetic symptom (airway obstruction or recurrent inflammatory diseases).

### THE TASK OF THE ARTICLE

To examine the histological and ultramicroscopic characteristics of PT and MM of TT in children with hypertrophy of PT, depending on the primary pathogenetic syndrome (airway obstruction or recurrent inflammatory diseases), and to conduct a comparative analysis of these features.

### MATERIALS AND METHODS

A cross-sectional study involved 25 children aged 2-12 years, who underwent endoscopic modified power-assisted adenoidectomy at children's hospital of the State Institution of Science «Research and Practical Center of Preventive and Clinical Medicine» State Administration Department. Informed consent for the research was obtained from the parents of the patients. The inclusion criteria for the study were the presence of concomitant TT hypertrophy, absence of middle ear pathology, and no history of adenoidectomy or tonsillectomy. Depending on the indications for adenoidectomy, all patients were divided into 2 groups. Group 1 included 12 children (mean age  $5.75 \pm 2.37$  years, 5 girls/7 boys) with PT hypertrophy, where the intervention was indicated by significant nasal breathing disturbances, snoring, and apnea. Group 2 involved 13 children (mean age  $5.38 \pm 2.29$  years, 6 girls/7 boys) with PT hypertrophy and concomitant inflammatory diseases of the upper

respiratory tract (chronic nasopharyngitis, chronic and recurrent rhinosinusitis). The study objects were tissue fragments of PT and MM of TT removed during the surgery, which were subsequently used for histological investigation and electron microscopy using a light microscope (Axioskop 40 with Carl Zeiss AxioCam MRc5) and scanning electron microscope (SEM; Tescan MIRA3, Tesla). Tissue sample preparation for histological investigation and electron microscopy was conducted according to widely accepted methods and protocols [1, 5]. Histological specimens were stained using hematoxylin and eosin, Periodic acid-Schiff and Masson's trichrome staining. The quantitative assessment of identified morphological changes was conducted using the method of precise calculation of the significance of differences in proportions (%) of Fisher's angular transformation ( $\phi$ ) at a significance level of  $\alpha=0.05$ .

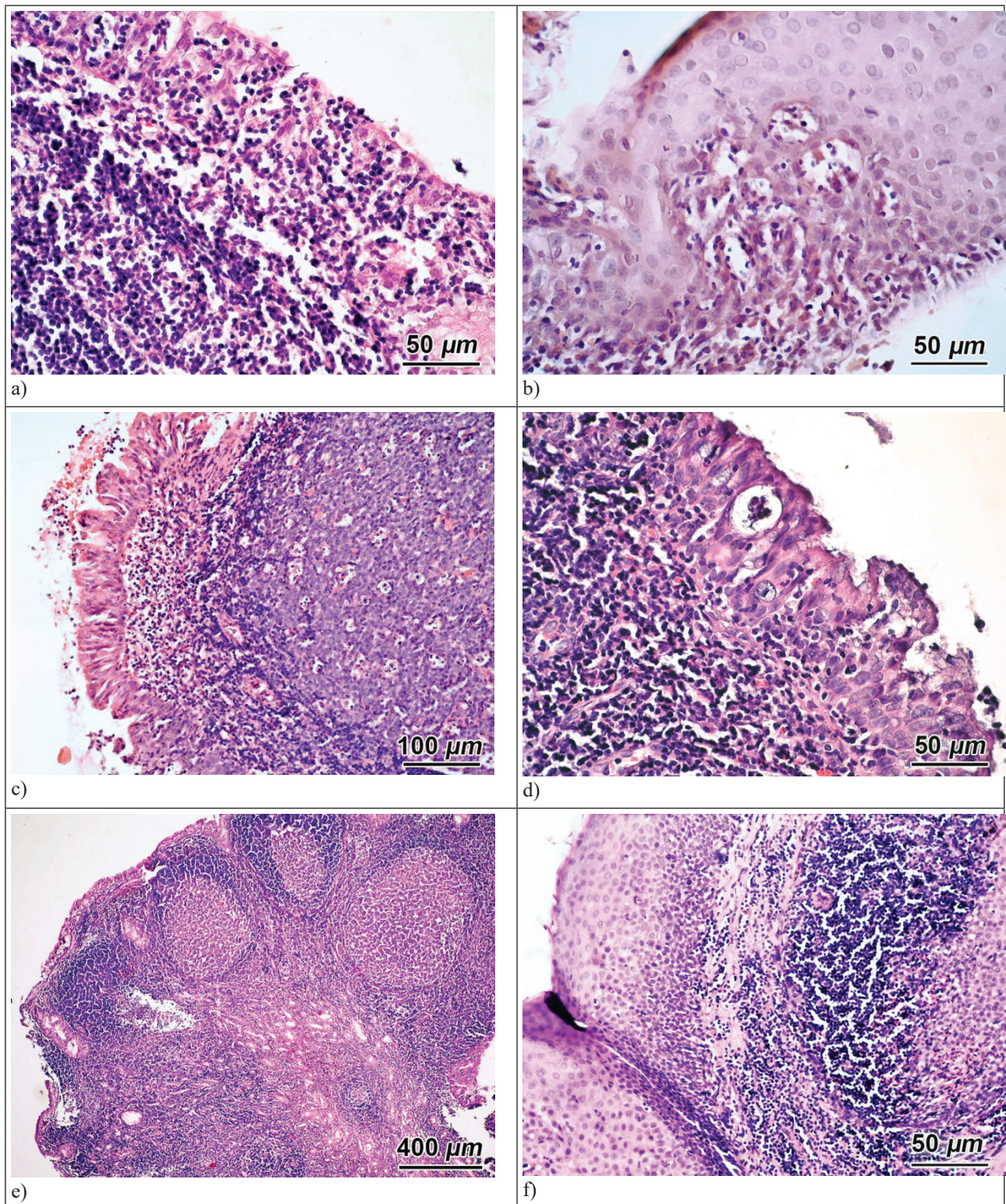
### RESULTS OF THE RESEARCH AND DISCUSSION

During the histological examination of PT and TT in children of Groups 1 and 2, moderate infiltration of the covering epithelium (CE) by lymphocytes (Lph) (Fig. 1a) was observed. In some cases, a reticulation of the epithelium (Fig. 1b) was detected, interpreted as a manifestation of reactive changes in response to external factors. Against the background of such changes, dystrophic-destructive and inflammatory changes in MM of PT and TT were often observed, characterized by pronounced infiltration of the subepithelial area by polymorphonuclear leukocytes (PMNL) (Fig. 1c) and the formation of Ugras's abscess (Fig. 1d) [14], along with small cavities. Along with the changes in MM, moderate to pronounced hyperplasia of LT was noted, which in PT, unlike TT, was characterized by an increase in the number and size of lymph nodes (LN; Fig. 1e, 1f). In some cases, infiltration of intrafollicular areas of PMNL and focal fibrosis were observed. These morphological features are typical for MM of PT [2, 13] in patients with its hypertrophy. TT is covered by epithelium extending from PT [10], accordingly, the morphological characteristics of MM in both of these areas are similar.

Based on the results of histological studies and literature data [12, 14, 15], the assessment of inflammatory and dystrophic-destructive changes in CE of PT and TT, as well as LT associated with MM in patients of Groups 1 and 2, was conducted using the following criteria: 1) infiltration of CE by lymphocytes, characterized as moderate (3-5 lymphocytes) and pronounced (5 lymphocytes and more); 2) reticulation of CE and its destruction in the form of Ugras's abscess or small cavities; 3) infiltration by PMNL in CE layer or subepithelial area; 4) hyperplasia of LT, characterized as moderate and pronounced. In PT, it was characterized by the number of lymphocytes (moderate – less than 3, pronounced – more than 3), and in TT – the area of LT it occupies under MM

in the microscope field at x200 magnification (moderate – less than ½, pronounced – more than ½); 5) infiltration

of PMNL in subepithelial and/or interfollicular areas of LT; 6) fibrosis.



**Fig. 1. Representative histological changes of PT (a, c, d, e) and TT (b, f) in patients of group I (a, c, d, e) and group II (b, f): a) – pronounced infiltration of CE by lymphocytes; b) – reticulation of pavement CE in metaplasia; c) – infiltration of the subepithelial zone of Lph and PMNL; d) – Ugras's abscess in the CE layer; e) – hyperplasia of LT PT; f) – Lph infiltration of the subepithelial zone of the TT and hyperplasia of the LT. Hematoxylin and eosin.**

According to the results of studying the frequency of histological changes, it was established that in children of Group 2, compared to Group 1, the frequency of morphological manifestations characterizing the development of inflammatory changes in TT significantly increased ( $p < 0.05$ ) against the background of reactive changes in PT (Table 1). At the same time, the frequency of histological changes in TT, determining the development of destructive-dystrophic and inflammatory

changes in MM of TT, as well as hyperplasia of LT as a reaction to inflammation, did not significantly differ from the frequency of similar changes in PT ( $p > 0.05$ ). This may indicate that the development of inflammatory changes in PT can extend to the structures of MM and submucosa of TT, including LT associated with MM, often manifested by its pronounced hyperplasia. Subsequently, inflammatory changes in TT can affect the clinical outcome in patients after adenoidectomy.

Table 1

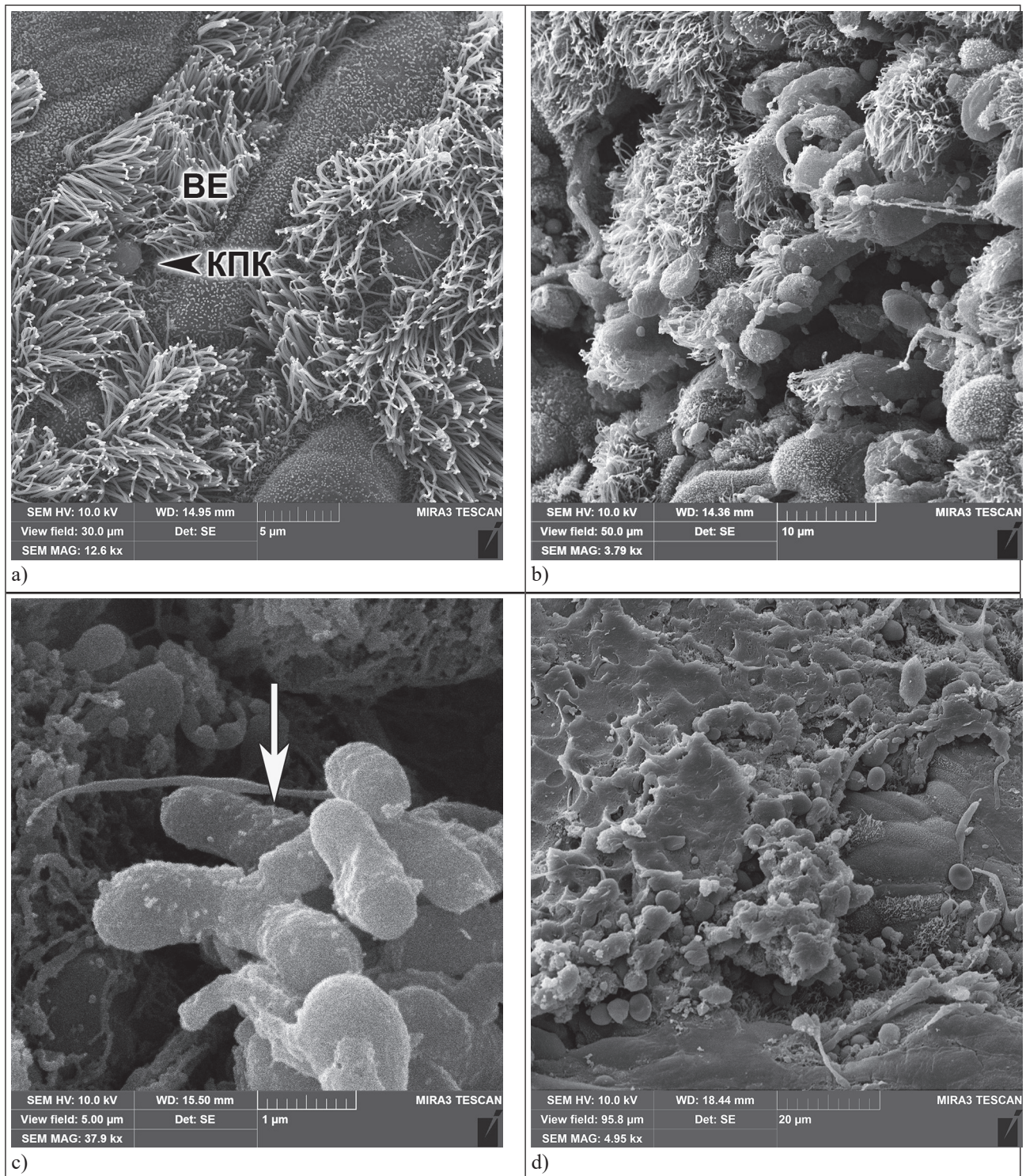
**Evaluation of morphological changes of PT and TT in patients of Groups 1 and 2 based on the frequency of detected changes**

Morphological changes	Group 1 (n=12), %		Group 2 (n=13), %	
	PT	TT	PT	TT
Histological changes				
1. infiltration of CE by lymphocytes – moderate	8 (66.6 %)	4 (33.3 %) $p_{1-2} < 0.05$	2 (15.4 %) $p_{1-3} < 0.01$	4 (30.7 %) $p_{2-4} > 0.05$ $p_{3-4} > 0.05$
– pronounced	4 (33.3 %)	1 (8.3 %), $p_{1-2} > 0.05$	11 (84.6 %) $p_{1-3} < 0.01$	7 (53.8 %) $p_{2-4} < 0.05$ $p_{3-4} > 0.05$
2. Reticulation of CE and its destruction	5 (41.6 %)	5 (41.6 %), $p_{1-2} > 0.05$	7 (53.8 %) $p_{1-3} > 0.05$	9 (69.2 %) $p_{2-4} > 0.05$ $p_{3-4} > 0.05$
3. Infiltration by PMNL in CE layer and subepithelial area	1 (8.3 %)	Н/В	6 (46.1 %) $p_{1-3} < 0.01$	8 (61.5 %) $p_{3-4} > 0.05$
4. LT hyperplasia – moderate (grade 1)	2 (16.6 %)	3 (25 %), $p_{1-2} > 0.05$	4 (30.7 %) $p_{1-3} > 0.05$	3 (23.7 %) $p_{2-4} > 0.05$ $p_{3-4} > 0.05$
– pronounced (grade 2)	10 (83.3 %)	5 (41.6 %), $p_{1-2} < 0.01$	9 (69.2 %) $p_{1-3} > 0.05$	8 (61.5 %) $p_{2-4} > 0.05$ $p_{3-4} > 0.05$
5. Infiltration by PMNL in subepithelial/interfollicular areas	2 (16.6 %)	2 (16.6 %), $p_{1-2} > 0.05$	8 (61.5 %) $p_{1-3} < 0.01$	5 (38.4 %) $p_{2-4} > 0.05$ $p_{3-4} > 0.05$
6. Fibrosis	1 (8.3 %)	Н/В	5 (38.4 %) $p_{1-3} < 0.01$	4 (30.7 %) $p_{3-4} > 0.05$
Ultrastructural changes in the surface of MM				
7. Destructive-dystrophic changes in CE	4 (33.3 %)	2 (16.6 %) $p_{1-2} > 0.05$	5 (38.4 %) $p_{1-3} > 0.05$	3 (23.1 %) $p_{2-4} > 0.05$ $p_{3-4} > 0.05$
8. Accumulation of microbial planktons on CE	5 (41.6 %)	3 (25.0 %) $p_{1-2} > 0.05$	8 (61.5 %) $p_{1-3} > 0.05$	6 (46.1 %) $p_{2-4} > 0.05$ $p_{3-4} > 0.05$
9. Biofilm formation	2 (16.6 %)	1 (8.3 %) $p_{1-2} > 0.05$	7 (53.8 %) $p_{1-3} < 0.05$	5 (38.5 %) $p_{2-3} < 0.05$ $p_{3-4} > 0.05$

–  $p < 0.05$  with a critical  $\phi^*$  value  $\leq 1.64$ ;  
–  $p < 0.01$  with a critical  $\phi^*$  value  $\leq 2.31$ .

The SEM results showed that in children of Group 2, compared to those of Group 1, the surface of MM of PT and TT often exhibited not only dystrophic-destructive changes in ciliated epithelium (CECs), hyperplasia and hypertrophy of goblet cells (GC), as well as dense accumulations of mucus, numerous sloughed dystrophic epitheliocytes, lymphocytes and occasional erythrocytes (Fig. 2a, 2b), but also accumulation of microbial planktons,

represented by rod-shaped and coccoid forms, which often formed conglomerates of microorganisms and/or small colonies (Fig. 2c). However, in the areas of MM of PT and TT, where areas of squamous metaplasia of ciliated epithelium with signs of keratinization were often observed, the formation of biofilms was frequently noted. These biofilms consisted of organized conglomerates of microorganisms, typically cocci, covered with a thin mantle.



**Fig. 2.** Ultrastructural changes on the surface of the PT (a, b) and TT (c, d) – a) – the area of the MM PT, where the CE (BE) is represented by ciliated epithelial cells (CECs) (КПК) and goblet cells (GC); b) – dystrophic changes in the CE and its infiltration by Lph; c) – planktonic forms of microorganisms on the surface of the MM TT (↓); d) – the area of the MM covered with biofilms. SEM.

This suggests that the frequency of identified microbial planktons on the surface of MM of PT in children of Group 2 correlated with the frequency of biofilm detection ( $r=0.64$ ; Table 1). A similar pattern was observed in children of Group 2 when studying MM of TT.

The revealed characteristics of the epithelium of PT and TT in children of Group 1 are typical of the normal structure of the tonsils [2]. The surface of MM in most patients is composed of respiratory ciliated epithelium with GC, a small number of accumulations of microbial planktons and mucus.

In children of Group 2, histological examination of MM of PT and TT predominantly revealed infiltration by PMNL and lymphocytes. These characteristics are typical of PT structure in children with concomitant inflammatory diseases of the middle ear and are predictors of biofilm formation on the tonsil surface [13]. A significantly higher frequency of biofilm identification on the surface of PT in patients of Group 2, compared to Group 1, was noted – 53.8 % and 16.6 %, respectively ( $p < 0.05$ ). These findings correlate with literature describing patients with PT hypertrophy and concomitant chronic nasopharyngitis and paranasal sinus pathology [4, 7]. Similar results were obtained in SEM studies of MM of TT – biofilms were more frequently identified in patients of Group 2 (38.5 %) compared to Group 1 (8.3 %) ( $p < 0.05$ ).

### CONCLUSIONS

1. In children with hypertrophy of PT, where the leading symptom is nasal breathing disturbance, histological examination reveals a predominance of infiltration of MM and submucosal layer by lymphocytes. In cases where symptoms of inflammatory diseases of the upper respiratory tract prevail, there is infiltration by PMNL and lymphocytes in CE and subepithelial area, as well as the formation of microabscesses and fibrosis.

2. In cases of hypertrophy of PT and TT, the morphological characteristics of MM of TT are similar to those observed in the pharyngeal tonsil and depend on the primary clinical symptom, such as obstruction or inflammatory diseases of the upper respiratory tract.

3. In children with frequent inflammatory diseases of the upper respiratory tract, there is a significant increase in the frequency of biofilm formation on the surface of MM of PT – 53.8 % and TT – 38.5 %, compared to the group of children with nasal breathing disturbance: PT – 16.6 % and TT – 8.3 %.

4. The identified morphological characteristics of PT and TT in children should be considered when planning the scope of surgical treatment for PT hypertrophy to determine the advisability of TT correction.

**PROSPECTS FOR FURTHER RESEARCH:** based on the obtained data, it is advisable to conduct correction of hypertrophied TT in children with PT hypertrophy. Research on the effectiveness and safety of this type of correction is necessary.

### COMPLIANCE WITH ETHICAL REQUIREMENTS

The study was conducted in accordance with the principles of the Helsinki Declaration of the World Medical Association «Ethical principles of medical research involving a person as an object of research». All study participants provided informed consent in writing to participate in the study.

### FUNDING AND CONFLICT OF INTEREST

Data on the relationship of funding for the development by certain institutions, foundations, organisations, grants: The article was performed within the framework of the research work No of state registration 0121U100124. The authors declare that there is no conflict of interest.

### LITERATURE

1. Багрій М. М., Діброва В. А., Попадинець О. Г., Гришук М. І. Методика морфологічних досліджень: Монографія. Вінниця. Нова книга, 2016. 328с. Available from: [https://www.researchgate.net/publication/327149901\\_Review\\_Bagriy\\_MM\\_Dibrova\\_VA\\_Popadynets\\_OG\\_Grischuk\\_MI\\_authors\\_Bagriy\\_MM\\_Dibrova\\_VA\\_editors\\_Methods\\_of\\_morphological\\_research\\_Vinnitsa\\_New\\_book\\_2016\\_328\\_p\\_Ukrainian](https://www.researchgate.net/publication/327149901_Review_Bagriy_MM_Dibrova_VA_Popadynets_OG_Grischuk_MI_authors_Bagriy_MM_Dibrova_VA_editors_Methods_of_morphological_research_Vinnitsa_New_book_2016_328_p_Ukrainian)
2. Лайко А. А. та спів. Гіпертрофія глоткового мигдалика. Київ. Лого, 2010. 168с. Available from: [https://www.lorlife.kiev.ua/rhinology/2012/2012\\_2\\_68.pdf](https://www.lorlife.kiev.ua/rhinology/2012/2012_2_68.pdf)
3. Acar G. Surgical anatomy of the Tonsils. p.30 in Oral and Maxillofacial Surgery. 2021. London. Available from: [https://www.researchgate.net/publication/342735111\\_Surgical\\_Anatomy\\_of\\_the\\_Tonsils#fullTextFileContent](https://www.researchgate.net/publication/342735111_Surgical_Anatomy_of_the_Tonsils#fullTextFileContent)
4. Cotichia J et al. Biofilm Surface Area in the Pediatric Nasopharynx: Chronic Rhinosinusitis vs Obstructive Sleep Apnea. Arch Otolaryngol Head Neck Surg. 2007. Vol. 133(2). P. 110-114. doi:10.1001/archotol.133.2.110 Available from: <https://jamanetwork.com/journals/jamaotolaryngology/article-abstract/484650>
5. Goldstein JI Scanning electron microscopy and X-Ray microanalysis New York: Springer, 2018. 554p. <http://dx.doi.org/10.1007/978-1-4939-6676-9>. Available from: <https://link.springer.com/book/10.1007/978-1-4939-6676-9/>
6. Ishida T et al. Patterns of adenoid and tonsil growth in Japanese children and adolescents: A longitudinal study. Sci Rep. 2018. Vol. 20(8).17088. doi: 10.1038/s41598-018-35272-z. PMID: 30459413; PMCID: PMC6244207 Available from: <https://www.ncbi.nlm.nih.gov/pmc/articles/PMC6244207/>
7. Kania R. et al. Bacterial biofilm in adenoids of children with chronic otitis media. Part I: a case control study of prevalence of biofilms in adenoids, risk factors and

- middle ear biofilms. *Acta Oto-Laryngologica*. 2019. Vol.139. P. 345–350. doi:10.1080/00016489.2019.1571282 Available from: <https://www.tandfonline.com/doi/full/10.1080/00016489.2019.1571282>
8. Kim JW, Rhee CS, Jung HJ. Partial resection of hypertrophic torus tubarius for recurred snoring: Case series. *Medicine (Baltimore)*. 2020. Vol. 99(10). e19329. doi: 10.1097/MD.00000000000019329. PMID: 32150069; PMCID: PMC7478779 Available from: <https://www.ncbi.nlm.nih.gov/pmc/articles/PMC7478779/>
  9. Liakh KV, Kosakovskiy AL, Shkorbotun Ya V. Assessment the impact of the torus tubarius correction by power-assisted technique on the equipressor eustachian tube function. *Modern pediatrics. Ukraine*. 2023. Vol. 5(133). P. 80-84. doi 10.15574/SP.2023.133.80. Available from: <https://med-expert.com.ua/journals/wp-content/uploads/2023/10/13.pdf>
  10. Mansour S, Magnan J, Ahmad HH, Nicolas K, Louryan S. The eustachian tube. In: comprehensive and clinical anatomy of the middle ear. Springer, Cham, 2019. P. 197-219. [https://doi.org/10.1007/978-3-030-15363-2\\_7](https://doi.org/10.1007/978-3-030-15363-2_7). Available from: [https://link.springer.com/chapter/10.1007/978-3-030-15363-2\\_7](https://link.springer.com/chapter/10.1007/978-3-030-15363-2_7)
  11. Marazzato M. et al. 16S Metagenomics reveals dysbiosis of nasal core microbiota in children with chronic nasal inflammation: role of adenoid hypertrophy and allergic rhinitis *Frontiers in cellular and infection microbiology*. 2020. Vol.10: doi:10.3389/fcimb.2020.00458 Available from: <https://www.frontiersin.org/articles/10.3389/fcimb.2020.00458>
  12. Reis LGV et al. Tonsillar hyperplasia and recurrent tonsillitis: clinical-histological correlation. *Braz J Otorhinolaryngol*. 2013. Vol. 79(5). P. 603-608. doi: 10.5935/1808-8694.20130108 Available from: <https://www.ncbi.nlm.nih.gov/pmc/articles/PMC9442398/>
  13. Szalmás A et al. «Microbiological Profile of Adenoid Hypertrophy Correlates to Clinical Diagnosis in Children», *BioMed Research International*, Vol. 2013, Article ID 629607, 10 pages, 2013. Available from: <https://doi.org/10.1155/2013/> <https://downloads.hindawi.com/journals/bmri/2013/629607.pdf>
  14. Uğraş S, Kutluhan A. Chronic tonsillitis can be diagnosed with histopathologic findings. *Eur J Gen Med*. 2008. Vol. 5(2). P. 95-103. Available from: <http://www.bioline.org.br/pdf?gm08018>
  15. Vintilescu ŞB et al. Comparative clinicopathological aspects of chronic tonsillitis and adenoiditis in children. *Rom J Morphol Embryol*. 2020. Vol. 61(3). P. 895-904. doi: 10.47162/RJME.61.3.28. Available from: <https://rjme.ro/RJME/resources/files/610320895904.pdf>
  16. Yang SZ et al. [Preliminary experience of surgical treatment for torus tubarius hypertrophy in children]. *Zhonghua er bi yan hou tou jing wai ke za zhi. Chinese Journal of Otorhinolaryngology Head and Neck Surgery*. 2022. Vol. 57(4). P. 505-509. DOI: 10.3760/cma.j.cn115330-20210412-00196. PMID: 35527449 Available from: <https://rs.yiigle.com/cmaid/1374700>

## REFERENCES

1. Bagrii M. M., Dibrova V. A., Popadynets O. G., Hryshchuk M. I. (2016) *Metodyka morfolohichnykh doslidzhen': Monohrafiya*. [Methods of morphological research: Monograph.] Vinnitsa. New book, 328. Available from: [https://www.researchgate.net/publication/327149901\\_Review\\_Bagriy\\_MM\\_Dibrova\\_VA\\_Popadynets\\_OG\\_Grischuk\\_MI\\_authors\\_Bagriy\\_MM\\_Dibrova\\_VA\\_editors\\_Methods\\_of\\_morphological\\_research\\_Vinnitsa\\_New\\_book\\_2016\\_328\\_p\\_Ukrainian](https://www.researchgate.net/publication/327149901_Review_Bagriy_MM_Dibrova_VA_Popadynets_OG_Grischuk_MI_authors_Bagriy_MM_Dibrova_VA_editors_Methods_of_morphological_research_Vinnitsa_New_book_2016_328_p_Ukrainian)
2. Laiko A. A. (2010) *Hipertrofiya hlotkovoho myhdalyka*. [Hypertrophy of the pharyngeal tonsil]. Kyiv, Logos, 168. Available from: [https://www.lorlife.kiev.ua/rhinology/2012/2012\\_2\\_68.pdf](https://www.lorlife.kiev.ua/rhinology/2012/2012_2_68.pdf)
3. Acar G. (2021) *Surgical anatomy of the Tonsils*. p.30 in *Oral and Maxillofacial Surgery*. London. Available from: [https://www.researchgate.net/publication/342735111\\_Surgical\\_Anatomy\\_of\\_the\\_Tonsils#fullTextFileContent](https://www.researchgate.net/publication/342735111_Surgical_Anatomy_of_the_Tonsils#fullTextFileContent)
4. Coticchia J, Zuliani G, Coleman C, Carron M, Gurrola J 2nd, Hauptert M, Berk R (2007) *Biofilm Surface Area in the Pediatric Nasopharynx: Chronic Rhinosinusitis vs Obstructive Sleep Apnea*. *Arch Otolaryngol Head Neck Surg*;133(2),110-114. doi:10.1001/archotol.133.2.110 Available from: <https://jamanetwork.com/journals/jamaotolaryngology/article-abstract/484650>
5. Goldstein JI (2018) *Scanning electron microscopy and X-Ray microanalysis* New York: Springer,554. <http://dx.doi.org/10.1007/978-1-4939-6676-9>. Available from: <https://link.springer.com/book/10.1007/978-1-4939-6676-9>
6. Ishida T, Manabe A, Yang SS, Yoon HS, Kanda E, Ono T. (2018) Patterns of adenoid and tonsil growth in Japanese children and adolescents: A longitudinal study. *Sci Rep*,8(1),17088. doi: 10.1038/s41598-018-35272-z. PMID: 30459413; PMCID: PMC6244207 Available from: <https://www.ncbi.nlm.nih.gov/pmc/articles/PMC6244207/>
7. Kania R, Vironneau P, Dang H, Bercot B, Cambau E, Verillaud B, Camous D, Lamers G, Herman P, Vicaut E, Tessier N, Van Den Abbeele T (2019) *Bacterial biofilm in adenoids of children with chronic otitis media. Part I: a case control study of prevalence*

- of biofilms in adenoids, risk factors and middle ear biofilms. *Acta Oto-Laryngologica*, 139, 345-350. doi:10.1080/00016489.2019.1571282 Available from: <https://www.tandfonline.com/doi/full/10.1080/00016489.2019.1571282>
8. Kim JW, Rhee CS, Jung HJ. (2020) Partial resection of hypertrophic torus tubarius for recurred snoring: Case series. *Medicine (Baltimore)*, 99(10), e19329. doi: 10.1097/MD.00000000000019329. PMID: 32150069; PMCID: PMC7478779 <https://www.ncbi.nlm.nih.gov/pmc/articles/PMC7478779/>
9. Liakh KV, Kosakovskiy AL, Shkorbotun Ya V. (2023). Assessment the impact of the torus tubarius correction by power-assisted technique on the equipressor eustachian tube function. *Modern pediatrics. Ukraine*, 5(133), 80-84. doi 10.15574/SP.2023.133.80. Available from: <https://med-expert.com.ua/journals/wp-content/uploads/2023/10/13.pdf>
10. Mansour S, Magnan J, Ahmad HH, Nicolas K, Louryan S. (2019). The eustachian tube. In: comprehensive and clinical anatomy of the middle ear. Springer, Cham. [https://doi.org/10.1007/978-3-030-15363-2\\_7](https://doi.org/10.1007/978-3-030-15363-2_7). Available from: [https://link.springer.com/chapter/10.1007/978-3-030-15363-2\\_7](https://link.springer.com/chapter/10.1007/978-3-030-15363-2_7)
11. Marazzato M, Zicari AM, Aleandri M, Conte AL, Longhi C, Vitanza L, Bolognino V, Zagaglia C, De Castro G, Brindisi G, Schiavi L, De Vittori V, Reddel S, Quagliariello A, Del Chierico F, Putignani L, Duse M, Palamara AT, Conte MP. (2020) 16S Metagenomics reveals dysbiosis of nasal core microbiota in children with chronic nasal inflammation: role of adenoid hypertrophy and allergic rhinitis *Frontiers in cellular and infection microbiology*;10. doi:10.3389/fcimb.2020.00458 Available from: <https://www.frontiersin.org/articles/10.3389/fcimb.2020.00458>
12. Reis LG, Almeida EC, da Silva JC, Pereira Gde A, Barbosa Vde F, Etchebehere RM. (2013) Tonsillar hyperplasia and recurrent tonsillitis: clinical-histological correlation. *Braz J Otorhinolaryngol*, 79(5), 603-608. doi: 10.5935/1808-8694.20130108 Available from: <https://www.ncbi.nlm.nih.gov/pmc/articles/PMC9442398/>
13. Szalmás A, Papp Z, Csomor P, Kónya J, Sziklai I, Szekanecz Z, Karosi T (2013) «Microbiological Profile of Adenoid Hypertrophy Correlates to Clinical Diagnosis in Children», *BioMed Research International*, 2013, Article ID 629607, 10 pages, 2013. <https://doi.org/10.1155/2013/> Available from: <https://downloads.hindawi.com/journals/bmri/2013/629607.pdf>
14. Uğraş S, Kutluhan A. Diagnosis of chronic tonsillitis can be made with histopathologic findings. *Eur J Gen Med*. 2008. Vol. 5(2). P. 95-103. Available at: <http://www.bioline.org.br/pdf?gm08018>
15. Vintilescu ŞB, Ioniţă E, Stepan AE, Simionescu CE, Matei M, Stepan MD, Becheanu CA, Niculescu EC (2020) Comparative clinicopathological aspects of chronic tonsillitis and adenoiditis in children. *Rom J Morphol Embryol.*, 61(3), 895-904. doi: 10.47162/RJME.61.3.28. Available from: <https://rjme.ro/RJME/resources/files/610320895904.pdf>
16. Yang SZ, Zhou CY, Wang ZL, Han BC, Sun WHH, Wan Y, Shen GJ, Zhang J, Zhang J. (2022) [Preliminary experience of surgical treatment for torus tubarius hypertrophy in children]. *Zhonghua er bi yan hou tou Jing wai ke za zhi. Chinese Journal of Otorhinolaryngology Head and Neck Surgery*, 57(4), 505-509. DOI: 10.3760/cma.j.cn115330-20210412-00196. PMID: 35527449 Available from: <https://rs.yiigle.com/cmaid/1374700>



## Резюме

### КЛІНІКО-МОРФОЛОГІЧНА ХАРАКТЕРИСТИКА ТА ОЦІНКА ТРУБНИХ ВАЛИКІВ У ДІТЕЙ ІЗ ГІПЕРТРОФІЄЮ ГЛОТКОВОГО МИГДАЛИКА

Катерина В. Лях<sup>1,2</sup>, Сергій П. Луговський<sup>3</sup>, Анатолій Л. Косаковський<sup>1</sup>, Ярослав В. Шкорботун<sup>1,2</sup>, Микола А. Скорик<sup>4</sup>

1 – Національний університет охорони здоров'я України імені П. Л. Шупика, м. Київ, Україна

2 – Державна наукова установа «Науково-практичний центр профілактичної та клінічної медицини» Державного управління справами, м. Київ, Україна

3 – Державна установа «Інститут геронтології імені Д. Ф. Чеботарьова Національної академії медичних наук України», м. Київ, Україна

4 – Інститут металофізики ім. Г. В. Курдюмова Національної академії наук України, м. Київ, Україна

**Вступ:** Серед дітей із гіпертрофією глоткового мигдалика, яким виконується аденотомія у 31,3 % випадків відмічається гіпертрофія трубного валика, навіть при відсутності патології середнього вуха. Проте характер змін даної анатомічної ділянки у цієї категорії дітей не описаний.

**Мета дослідження:** Вивчення та оцінка морфологічних змін глоткового мигдалика і трубного валика у дітей із гіпертрофією глоткового мигдалика.

**Матеріали та методи:** виконано гістологічне дослідження та скануючу електронну мікроскопію фрагментів глоткового мигдалика та трубного валика, взятого при виконанні аденотомії у 12 дітей із порушенням носового дихання (І група) та 13 – із супутньою запальною патологією верхніх дихальних шляхів (ІІ група).

**Результати:** у пацієнтів ІІ групи зміни глоткового мигдалика мали більш виражені запальні зміни – інфільтрація поліморфноядерними лейкоцитами покривного епітелію та субепітеліального шару, та лімфоцитами покривного епітелію, наявність фіброзу у порівнянні із пацієнтами І групи. Також достовірно частіше ідентифікувались зразки, вкриті біоплівками (53,8 % у ІІ та 16,6 % у І групах ( $p < 0,05$ )). Зміни слизової оболонки трубного валика відповідали характеру змін глоткового мигдалика у відповідній групі. Біоплівки у зразках трубного валика зустрічались у 38,5 % ІІ та 8,3 % І груп ( $p < 0,05$ ).

**Висновки:** 1. У дітей із гіпертрофією глоткового мигдалика та гіпертрофією трубного валика морфологічні характеристики слизової оболонки останнього відповідали таким у слизовій оболонці глоткового мигдалика відповідної групи. 2. Біоплівки достовірно частіше ідентифікувались на поверхні глоткового мигдалика та трубного валика у дітей із запальними захворюваннями верхніх дихальних шляхів, ніж у пацієнтів лише із порушенням носового дихання. 3. Виявлені зміни є підґрунтям для перегляду лікувальної тактики по відношенню до гіпертрофованого трубного валика у дітей із гіпертрофією глоткового мигдалика.

**Ключові слова:** трубний валик, лімфоїдна тканина, морфологія, фіброз, біоплівки, запальні захворювання верхніх дихальних шляхів, мигдалик