

ORIGINAL ARTICLE

Assessment of conjunctival, episcleral and scleral thickness in healthy individuals using anterior segment optical coherence tomography

G. J. Teeuw¹ | D. P. C. Vergouwen^{1,2}  | W. D. Ramdas¹  | L. Sanchez-Brea^{1,3}  |
D. Andrade De Jesus^{1,3} | A. Rothova¹  | J. R. Vingerling¹ | J. C. Ten Berge¹ 

¹Department of Ophthalmology, Erasmus MC, University Medical Center Rotterdam, Rotterdam, The Netherlands

²Department of Immunology, Erasmus MC, University Medical Center Rotterdam, Rotterdam, The Netherlands

³Department of Radiology & Nuclear Medicine, Erasmus MC, University Medical Center Rotterdam, Rotterdam, The Netherlands

Correspondence

D. P. C. Vergouwen, Department of Ophthalmology, Erasmus MC, University Medical Center Rotterdam, Dr. Molewaterplein 40, 3015GD Rotterdam, The Netherlands.
Email: d.vergouwen@erasmusmc.nl

Funding information

Stichting Lijf en Leven, Grant/Award Number: L&L/mon/19-007

Abstract

Purpose: To determine the thickness of the conjunctiva, episclera and sclera in healthy individuals using anterior segment optical coherence tomography (AS-OCT).

Methods: We prospectively included 107 healthy individuals of different age groups (18–39 years, 40–54 years, 55–69 years and ≥70 years). For each eye, AS-OCT scans of four quadrants (temporal, nasal, superior and inferior) were acquired. The thickness of the conjunctiva, episclera and sclera was measured for each scan. In addition, the axial length of both eyes was measured, and general characteristics, including smoking, allergies and contact lens use, were collected.

Results: The mean conjunctival thickness was significantly different between the nasal and superior quadrants ($87 \pm 30 \mu\text{m}$ vs. $77 \pm 16 \mu\text{m}$; $p < 0.001$), as well as the superior and inferior quadrants ($77 \pm 16 \mu\text{m}$ vs. $86 \pm 19 \mu\text{m}$; $p = 0.001$). The mean episcleral thickness was larger in the superior ($174 \pm 54 \mu\text{m}$) and inferior ($141 \pm 43 \mu\text{m}$) quadrants, compared to the nasal ($83 \pm 38 \mu\text{m}$) and temporal quadrants ($90 \pm 44 \mu\text{m}$). The mean scleral thickness of the inferior quadrant was the largest ($596 \pm 64 \mu\text{m}$), followed by the nasal ($567 \pm 76 \mu\text{m}$), temporal ($516 \pm 67 \mu\text{m}$) and superior ($467 \pm 52 \mu\text{m}$) quadrants (all $p < 0.001$). The averaged scleral thickness increased $0.96 \mu\text{m}$ per age year (0.41 – $1.47 \mu\text{m}$, $p < 0.001$).

Conclusions: This study provides an assessment of the thickness of scleral and adjacent superficial layers in healthy individuals determined on AS-OCT, which could enable future research into the use of AS-OCT in diseases affecting the anterior eye wall.

KEYWORDS

anterior segment, imaging, optical coherence tomography, sclera, scleral thickness

1 | INTRODUCTION

The sclera and adjacent structures are a crucial part of the eye, forming around 85% of the outer tunic of the human eyeball. These layers have multiple functions that are critical for good vision; most importantly, they provide protection against external influences, give strength to the eyeball and maintain stable eye pressure (Boote et al., 2020; Vergouwen et al., 2020; Watson & Young, 2004). Various incident ocular disorders affect

either the sclera, the episclera, the conjunctiva or the limbus, such as conjunctival pathology, glaucoma, myopia and (epi)scleritis (Jonas & Xu, 2014; Liang et al., 2020; Mohamed-Noor et al., 2009; Nanji et al., 2015; Okhravi et al., 2005; Sung et al., 2021). Also, bulbar conjunctival thickness has been linked to bleb functionality after glaucoma surgery (Singh et al., 2009).

Despite the importance of anterior scleral and adjacent structures in clinical care, limited imaging techniques are available for analysing the conjunctiva,

G. J. Teeuw and D. P. C. Vergouwen contributed equally to this study.

This is an open access article under the terms of the [Creative Commons Attribution-NonCommercial-NoDerivs](https://creativecommons.org/licenses/by-nc-nd/4.0/) License, which permits use and distribution in any medium, provided the original work is properly cited, the use is non-commercial and no modifications or adaptations are made.

© 2023 The Authors. *Acta Ophthalmologica* published by John Wiley & Sons Ltd on behalf of Acta Ophthalmologica Scandinavica Foundation.

episclera or sclera. Ultrasound biomicroscopy is scarcely being used to examine the anterior segment, mainly in research settings (Heiligenhaus et al., 1998; Nolan, 2008). This method requires direct contact with the eye, and it should be done by an experienced examiner (Oliveira et al., 2006). These disadvantages can be overcome with optical coherence tomography (OCT) (Lim, 2015), as OCT is an imaging technique that is easy to perform, minimally invasive and able to provide high-resolution cross-sectional images. Posterior segment OCT is widely used to evaluate the macula and its retinal layers (Podoleanu, 2012). The anterior segment can also be accurately imaged (Lim, 2015); however, this is not yet widely used in clinical or research settings. A lack of knowledge about the normal reference values of the anterior eye wall on AS-OCT withholds proper interpretation of findings and implementation (Fernandez-Vigo et al., 2021).

A comprehensive overview of healthy scleral and adjacent structure measures on AS-OCT would highly advance research into the role of scleral tissue in severe ocular disorders, such as scleritis, and the implementation of this imaging technique in clinical settings. Therefore, the aim of this study is to report on the thickness of the conjunctiva, episclera and sclera in healthy individuals using AS-OCT and provide a reference for further studies on AS-OCT in diseased eyes.

2 | METHODS

2.1 | Participants

In this prospective imaging study, healthy volunteers of various age groups (18–39, 40–54, 55–69 and ≥70 years old) were included. Volunteers were recruited at the Erasmus MC, Rotterdam, The Netherlands, and were mostly attendants of patients from the ophthalmology department. Exclusion criteria for this study were age < 18 years, presence of relevant ocular disorder or high myopia/hyperopia (axial length < 20.4 or > 26.5 mm). The study was conducted according to the principles of the Declaration of Helsinki (64th WMA General Assembly, Fortaleza, Brazil, October 2013), the Medical Research Involving Human Subjects Act (WMO, 's-Gravenhage, 26 February 1998) and the ICH Good Clinical Practice guidelines. The Medical Ethics Research Committee of the Erasmus MC, Rotterdam, had granted approval for the study (MEC-2021-0116). All volunteers gave informed consent prior to image acquisition.

2.2 | AS-OCT imaging and measurement

Both eyes were imaged using a Spectralis OCT (Heidelberg Engineering GmbH, Heidelberg, Germany) with the anterior segment module and lens. Image acquisition settings were standardised as follows: volume scans with nine sections were made with an image acquisition angle of 30° and an automatic real time (ART) level of 6. The images had a resolution of 1024 × 496 pixels. The enhanced-depth imaging mode was on. AS-OCT scans

were performed of four quadrants of each eye (temporal, nasal, superior and inferior). Volunteers were asked to gaze in the opposite direction to the examined quadrant to maintain the perpendicularity of the OCT beam at the surface of the targeted tissue. The axial length of both eyes was measured using an IOL Master 700 (Carl Zeiss Meditec AG, Jena, Germany).

2.3 | Data collection and analysis

Data regarding age, gender, presence of ocular and systemic disorders, use of eye drops, smoking, allergies and contact lens use were gathered by the researcher through a questionnaire. The volume section with the best quality was selected, and conjunctival, episcleral and scleral thickness were manually measured using the Heidelberg Eye Explorer (version 1.10.4.0). The AS-OCT scans were analysed by a researcher (GT), which manually measured the thickness of the conjunctival, episcleral and scleral layers. All measurements were audited for correctness by a second researcher (DV). In a subset of 30 individuals, the measurements of the inferior quadrant were repeated to show the intra- and interobserver variability of measurements. For the temporal and nasal quadrants, thickness was measured at 2 mm from the limbus. For the superior and inferior quadrants, thickness was measured above or below the corneal centre at least 1 mm from the limbus. Conjunctival thickness was measured from the lower limit of the tear film (a thin hyper-reflective line) until the superficial episcleral vasculature (an intermittent hypo-reflective 'line'). The latter is the upper border of the episclera; the lower border is the deep episcleral vasculature, also seen as an intermittent hyporeflective 'line'. The scleral thickness was measured from the deep episcleral vasculature until the inner scleral border, clearly visible against the hyporeflective ciliary body tissue. Scans were excluded for thickness measurements in case scleral margins were unclear and/or if the thickness was not measurable due to insufficient contrast. In cases of conjunctival abnormalities (pterygia or pinguecula), conjunctival and episcleral thickness measurements were excluded from analyses. The methodological procedure is shown in Figure 1.

2.4 | Statistical analysis

Categorical data were shown as number and percentage, while continuous data were noted as mean ± standard deviation, unless specifically stated otherwise. Differences in continuous variables were analysed using the appropriate statistical test (independent sample *t*-test, paired sample *t*-test or one way ANOVA), whereas categorical data were analysed using a Chi-square test. First, we assessed whether there were significant differences between both eyes. Next, the correlation between scleral thickness and axial length was analysed calculating the Pearson *r*. A linear regression model was used to determine the association between age and gender on conjunctival, episcleral and scleral thickness corrected for general characteristics (axial length, smoking, allergies and contact lens use).

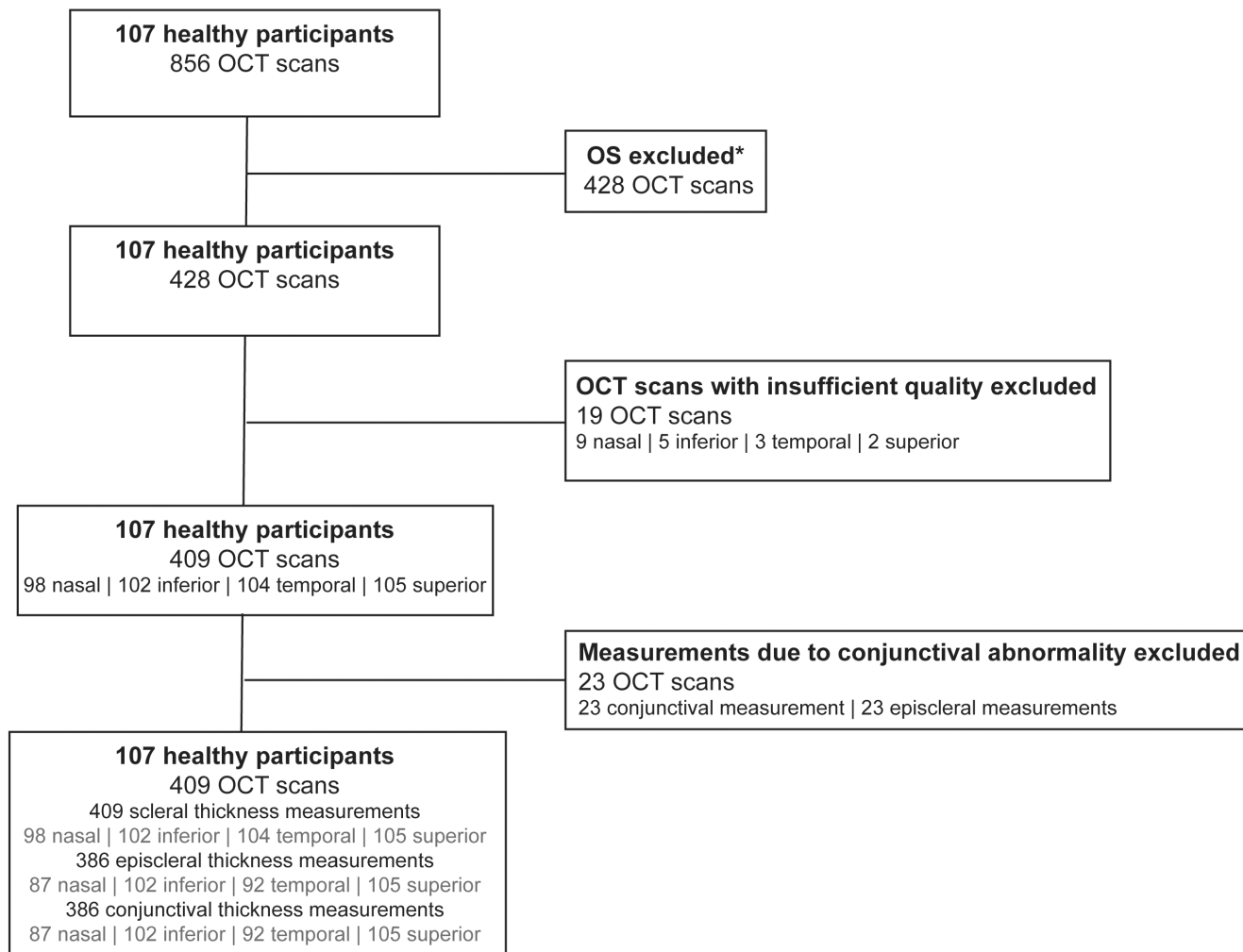


FIGURE 1 Methodological procedure. *The left eye (OS) was excluded because no differences were found between measurements of the right eye (OD) and OS regarding axial length and thickness measurements.

Intraclass correlation coefficients (ICC) were used to calculate the reproducibility of measurements; further, scatterplots and Bland-Altman plots are shown. All statistical analyses were performed using SPSS version 25.0 (SPSS Inc., Chicago, United States). A p -value threshold of <0.05 was considered statistically significant.

3 | RESULTS

Both eyes of 107 healthy volunteers were imaged, resulting in 856 OCT scans (all quadrants taken together). No statistically significant differences were found between measurements of the right eye (OD) and the left eye (OS): the mean axial length (24 ± 1 mm for both eyes; $p=0.11$), the mean conjunctival thickness ($83 \pm 15 \mu\text{m}$ for OD vs. $85 \pm 15 \mu\text{m}$ for OS; $p=0.20$), the mean episcleral thickness ($127 \pm 35 \mu\text{m}$ for OD vs. $130 \pm 36 \mu\text{m}$ for OS; $p=0.43$) and the mean scleral thickness ($536 \pm 52 \mu\text{m}$ for OD vs. $538 \pm 48 \mu\text{m}$ for OS; $p=0.47$) were similar for both eyes. Therefore, only data of OD were used for further analyses. Of the remaining 428 OCT scans, 19 (4.4%; 16 patients) were excluded for the thickness measurements (Figure 1), mainly in the oldest age group (50%; $p<0.001$). The mean was 51.6 ± 18.5 years, and 45% were male (Table 1). Eight out

of 107 (8%) used lubricants in one or both eyes, however, not directly before analysis. Inferior and superior scan measurements were taken at a mean distance to the limbus of $2564 \pm 863 \mu\text{m}$ and $2967 \pm 1142 \mu\text{m}$, respectively. No correlation was seen between distance to the limbus and conjunctival (pearson $r=0.12$; $p=0.22$), episcleral (pearson $r=-0.17$; $p=0.08$) and scleral thickness (pearson $r=-0.49$; $p=0.62$) for the inferior quadrant, as well as the superior quadrant (conjunctiva: pearson $r=-0.14$; $p=0.17$; episclera: pearson $r=0.003$; $p=0.97$; sclera: pearson $r=-0.09$; $p=0.39$).

3.1 | Conjunctival, episcleral and scleral thicknesses between quadrants

Mean conjunctival, episcleral and scleral thickness per quadrant are shown in Figure 2. The mean conjunctival thickness ranged from 38 to 200, 51 to 210, 43 to 127 and 45 to $128 \mu\text{m}$ for respectively the temporal, nasal, inferior and superior quadrants. The mean episcleral thickness ranged from 22 to 195, 26 to 181, 61 to 258 and 63 to $345 \mu\text{m}$ for respectively the temporal, nasal, inferior and superior quadrants. Mean scleral thickness ranged from 394 to 693, 430 to 750, 423 to 774 and 340 to $631 \mu\text{m}$ for the temporal, nasal, inferior and superior quadrants,

TABLE 1 General characteristics of healthy volunteers of various ages.

	Age 18–39 (<i>n</i> = 31)	Age 40–54 (<i>n</i> = 25)	Age 55–69 (<i>n</i> = 31)	Age ≥70 (<i>n</i> = 20)	Total (<i>n</i> = 107)	<i>p</i> -value
Male, <i>N</i> (%)	10 (32)	12 (48)	17 (55)	9 (45)	48 (45)	0.34
Age (years)	27.4±4.1	49±4.4	62.0±4.3	76.2±6.3	51.6±18.5	<0.001
Axial length OD (mm)	24.0±1.1	23.8±0.8	23.8±1.2	24.0±1.2	24.0±1.1	0.82
Contact lens use, <i>N</i> (%)	13 (42)	5 (20)	6 (19)	2 (10)	26 (24)	0.043
Smoking, <i>N</i> (%)	2 (7)	4 (17)	8 (26)	0 (0)	14 (13)	0.032
Allergies, <i>N</i> (%)	11 (36)	8 (32)	7 (23)	2 (10)	28 (26)	0.19
OCT scans excluded ^a , <i>N</i> (%)	1 (3)	1 (3)	4 (13)	10 (50)	16 (15)	<0.001
Conjunctival abnormality, <i>N</i> (%)	3 (9)	4 (16)	7 (22)	4 (20)	18 (16)	0.54

Note: Presented as mean±standard deviation, unless stated otherwise.

Abbreviations: OC, optical coherence tomography; OD, oculus dextra.

^aOCT scan excluded of one or more quadrants of OD per person.

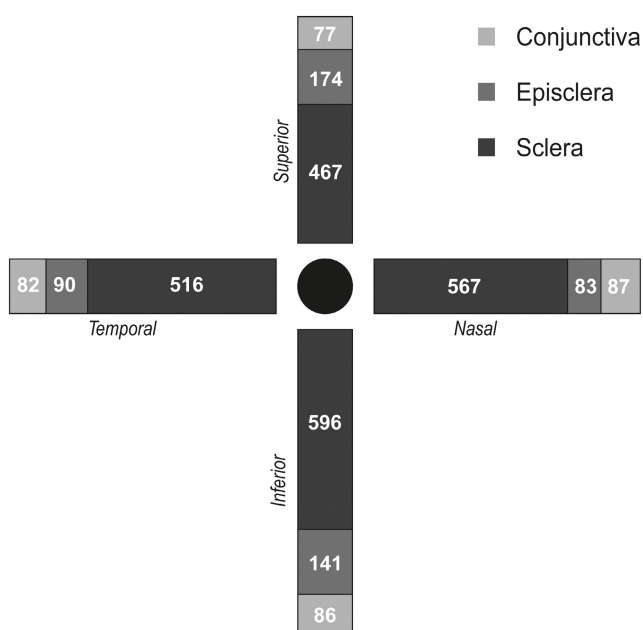


FIGURE 2 Mean conjunctival, episcleral and scleral thickness per quadrant (µm). Conjunctival thickness differed only significantly between the nasal vs. the superior quadrant ($87 \pm 30 \mu\text{m}$ vs. $77 \pm 16 \mu\text{m}$; $p < 0.001$), and the superior vs. the inferior quadrant ($77 \pm 16 \mu\text{m}$ vs. $86 \pm 19 \mu\text{m}$; $p = 0.001$). Nasal vs. temporal ($87 \pm 30 \mu\text{m}$ vs. $82 \pm 32 \mu\text{m}$; $p = 0.13$), nasal vs. inferior ($87 \pm 30 \mu\text{m}$ vs. $86 \pm 19 \mu\text{m}$; $p = 0.58$), temporal vs. superior ($82 \pm 32 \mu\text{m}$ vs. $77 \pm 16 \mu\text{m}$; $p = 0.17$), temporal vs. inferior ($82 \pm 32 \mu\text{m}$ vs. $86 \pm 19 \mu\text{m}$; $p = 0.38$). Episcleral thickness differs significantly between all except one comparison. Nasal vs. temporal ($83 \pm 38 \mu\text{m}$ vs. $90 \pm 44 \mu\text{m}$; $p = 0.20$), nasal vs. superior ($83 \pm 38 \mu\text{m}$ vs. $174 \pm 54 \mu\text{m}$; $p < 0.001$), nasal vs. inferior ($83 \pm 38 \mu\text{m}$ vs. $141 \pm 43 \mu\text{m}$; $p < 0.001$), temporal vs. superior ($90 \pm 44 \mu\text{m}$ vs. $174 \pm 54 \mu\text{m}$; $p < 0.001$), temporal vs. inferior ($90 \pm 44 \mu\text{m}$ vs. $141 \pm 43 \mu\text{m}$; $p < 0.001$), superior vs. inferior ($174 \pm 54 \mu\text{m}$ vs. $141 \pm 43 \mu\text{m}$; $p < 0.001$). Scleral thickness differs significantly between all quadrants. Nasal vs. temporal ($567 \pm 76 \mu\text{m}$ vs. $516 \pm 67 \mu\text{m}$; $p < 0.001$), nasal vs. superior ($567 \pm 76 \mu\text{m}$ vs. $466 \pm 52 \mu\text{m}$; $p < 0.001$), nasal vs. inferior ($567 \pm 76 \mu\text{m}$ vs. $596 \pm 65 \mu\text{m}$; $p < 0.001$), temporal vs. superior ($516 \pm 67 \mu\text{m}$ vs. $467 \pm 52 \mu\text{m}$; $p < 0.001$), temporal vs. inferior ($516 \pm 67 \mu\text{m}$ vs. $596 \pm 64 \mu\text{m}$; $p < 0.001$), superior versus inferior ($467 \pm 52 \mu\text{m}$ vs. $596 \pm 65 \mu\text{m}$; $p < 0.001$). A paired-samples *t*-test was used for all comparisons.

respectively. The conjunctiva was significantly thinner in the superior compared to the nasal and inferior quadrants ($p \leq 0.001$). In the superior as well as the inferior quadrants, a thicker episclera was seen compared

to the nasal and temporal quadrants ($174 \mu\text{m}$ and $141 \mu\text{m}$ vs. $83 \mu\text{m}$ and $90 \mu\text{m}$; all $p < 0.001$). Scleral thickness differed significantly between each quadrant (all $p < 0.001$), with the inferior quadrant having the thickest sclera $596 \pm 65 \mu\text{m}$. Examples of OCT scans per quadrant are shown in Figure 3a–d.

3.2 | Conjunctival, episcleral and scleral thickness between age groups

Figure 4 shows the mean conjunctival, episcleral and scleral thickness in the different age groups. The mean conjunctival thickness was $83 \pm 15 \mu\text{m}$, which did not differ significantly between age groups ($p = 0.47$). Episcleral thickness was also similar between age groups ($127 \pm 35 \mu\text{m}$; $p = 0.78$). No association between age and conjunctival- and episcleral thickness was found in the multivariate linear regression analysis (adjusted for axial length, gender, allergies, smoking and contact lens use), with respectively betas (95% confidence interval) of -0.05 (-0.22 – 0.12 ; $p = 0.57$) μm per year increase in age and -0.34 (-0.7 – 0.03 ; $p = 0.07$) μm per year increase in age. The scleral thickness varied between age groups (mean 535 ; $p < 0.001$). It increased with age, ranging from $513 \pm 47 \mu\text{m}$ in the youngest age group (18–39 years) to $563 \pm 51 \mu\text{m}$ in the oldest age group (≥ 70 years). Scleral thickness differs significantly between age groups in all quadrants ($p < 0.001$), except for the inferior quadrant ($p = 0.35$; see Table 2). In the multivariate linear regression analyses (adjusted for axial length, gender, allergies, smoking and contact lens use), the association between age and scleral thickness remained significant with a beta (95% confidence interval) of 0.94 (0.41 – 1.47 ; $p < 0.001$) μm per year increase in age. The mean scleral thickness was shown to be higher in males than in females ($552 \pm 57 \mu\text{m}$ vs. $524 \pm 44 \mu\text{m}$; $p = 0.021$ (adjusted for age, axial length, allergies, smoking and contact lens use)).

3.3 | Correlations

In the temporal quadrant, there was a significant negative correlation ($r = -0.22$; $p = 0.032$) between episcleral

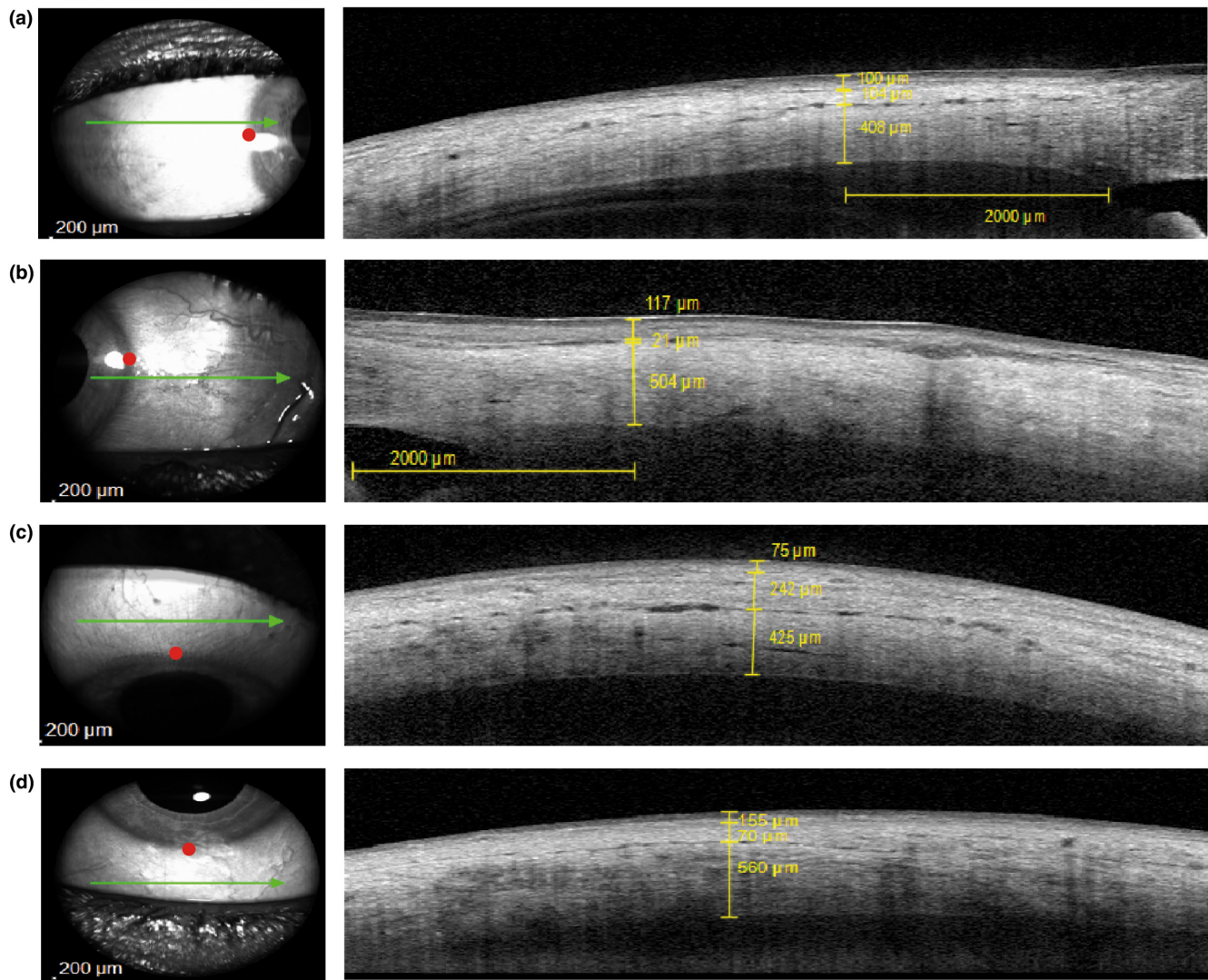


FIGURE 3 Example of an anterior segment OCT scan of the temporal, nasal, inferior and superior quadrants. (a) Example of a temporal anterior segment OCT scan and the measurements of the conjunctival, episcleral and scleral thickness at 2mm from the limbus (marked with a red dot). At first, we encounter the tear film, which is seen on the OCT scan as a thin hyperreflective line of only a few microns width. The conjunctiva is measured from the lower limit of the tear film until the superficial episcleral vasculature, an intermittent hyporefective 'line'. This is the upper border of the episclera; the lower border is the deep episcleral vasculature, also seen as an intermittent hyporefective 'line'. (b) shows a nasal scan, which is comparable to the temporal scan. In (c), a superior quadrant OCT scan is seen, in which generally the episclera is wider, which is also the case in (d), the inferior quadrant OCT scan.

thickness and scleral thickness, indicating that an increase in episcleral thickness is associated with a decreasing scleral thickness in this quadrant. In the nasal ($r=-0.17$; $p=0.12$), superior ($r=-0.01$; $p=0.96$) and inferior ($r=-0.17$; $p=0.083$) quadrants, no significant correlation was seen. No correlation was found between the axial length and thickness of the measured layers (all $p>0.05$).

3.4 | Reproducibility

Scatter plots and Bland-Altman plots of intra- and interobserver variability of conjunctival, episcleral and scleral measurements of the inferior quadrant are shown in [Figures S1A–F](#) and [S2A–F](#). The intra-observer variability was moderate for conjunctival and episcleral measurements, with ICC of 0.65 and 0.60, respectively. While an ICC of 0.84 was reached for scleral measurements. Interobserver variability was moderate as well for

conjunctival and episcleral measurements (ICC 0.46 and 0.54, respectively), while again, good repeatability was found for the scleral measurements (ICC 0.82).

4 | DISCUSSION

Our results revealed significant differences in anterior scleral thickness among the four quadrants of the eye. Specifically, we found that the inferior quadrant had the thickest sclera, followed by the nasal, temporal and superior quadrants. In addition, we found a larger scleral thickness in the older group compared to the younger age group. In this comprehensive prospective imaging study, we experienced the usability of AS-OCT scans for measurements of the thickness of the different layers of the eye wall, specifically the sclera.

Only a few studies have reported on the features of the anterior sclera and adjacent layers on OCT scans (Ebnetter et al., 2015; Fernandez-Vigo et al., 2021). While

reference values for anterior conjunctival, episcleral and scleral thicknesses are of importance in a number of ocular disorders (Jonas & Xu, 2014; Mohamed-Noor et al., 2009; Nanji et al., 2015; Okhravi et al., 2005; Sung et al., 2021). The diagnosis and disease monitoring of specific conjunctival pathology, for example anterior ocular surface masquerades, as well as episcleritis and scleritis, could be assisted by AS-OCT, in case normal ranges are known (Okhravi et al., 2005; Theotoka et al., 2022). Whether a correlation between the development of scleritis or scleral necrosis as a complication of scleritis (Vergouwen et al., 2020; Wakefield et al., 2013) is more prevalent in thinner or thicker anterior sclera is subject to further studies. Further, the anterior sclera seems to play a role in the pathogenesis of diseases such as glaucoma and myopia (Sung et al., 2021; Yoo et al., 2011). However, its exact role and value as a biomarker are yet unknown.

Thereby, uncertainty remains in the definitions of episcleral and conjunctival layers on OCT images. While some propose that the conjunctiva and episclera are distinguishable on the OCT scan, others state the impossibility of measuring these layers individually (Feng & Simpson, 2008; Fernandez-Vigo et al., 2021; Prakash et al., 2015). We were able to measure the conjunctiva apart from the episclera; however, the

reproducibility of conjunctival and episcleral measurements was moderate. Studies by Read et al. and Fernandez-Vigo et al. found a thicker conjunctiva (or conjunctiva and episclera) in the nasal compared to the temporal quadrant (Fernandez-Vigo et al., 2021; Read et al., 2016). Although a slight difference was found in our study, this was not significant. We did notice a thicker nasal conjunctiva compared to the superior conjunctiva. Multiple studies report a decreasing conjunctival thickness with age. Although we find a trend towards decreasing episclera with age, we could not reproduce this finding (Howlett et al., 2014; Read et al., 2016; Zhang et al., 2013). All studies, however, defined the conjunctiva as the layer covering the scleral stroma, which we have further divided into conjunctiva and episclera. Thereby, Zhang et al. and Howlett et al. have used different instruments and have imaged a slightly different location. Therefore, we have not included children in our study.

Regarding the scleral thickness, Ebnetter et al., who used the same device as the current study, reported that the inferior sclera compared to the superior part was thicker, which is entirely in line with our findings. However, the quadrants were defined otherwise (inferotemporal, inferonasal, superotemporal and superonasal), which makes additional comparisons more difficult (Ebnetter et al., 2015). Fernandez-Vigo recently published a large study on the dimensions of the limbus-ciliary sulcus region using swept-source OCT. They found a larger scleral thickness in the temporal compared to the nasal quadrant, in agreement with our findings. In addition, they found that scleral thickness was significantly lower further away from the limbus (Fernandez-Vigo et al., 2022). Hypothetically, a factor influencing the scleral thickness variation between quadrants may be the distance from the muscle insertion. Regarding the spiral of Tillaux, the nasal part is described as having the smallest distance from the limbus to muscle insertion, with increasing distance in a circle, followed by the inferior, temporal and superior parts (Dahlmann-Noor & Tillaux, 2008). Vurgese et al. (2012) found that scleral thickness decreased from the limbus to the ora serrata, where the muscle is inserted nearby. One might expect that the scleral thickness is lowest at the nasal quadrant and would be increasing following the spiral of Tillaux; however, we found a notably increased inferior scleral thickness. Gravity might explain a higher pressure on the inferior sclera and thereby, a higher power required inferiorly to maintain the eye ball structure.

The larger scleral thickness in higher age groups suggests an increasing scleral thickness with age, although

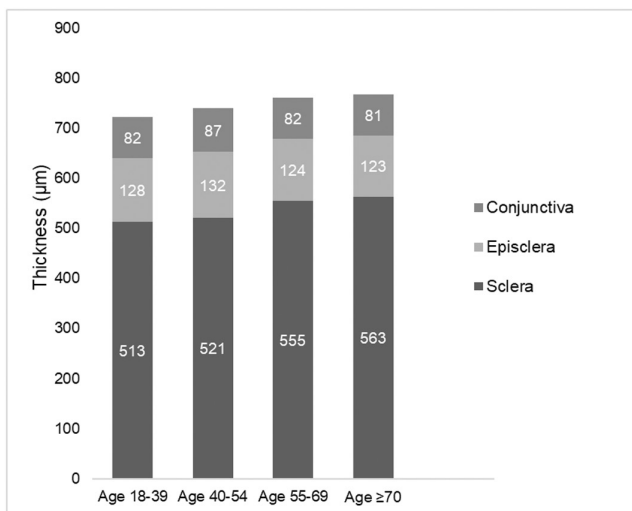


FIGURE 4 Mean conjunctival, episcleral and scleral thickness per age group (μm). OD data were used for this analysis. Conjunctival and episcleral thicknesses are similar between age groups (respectively, $p=0.47$ and $p=0.78$). Scleral thickness is significantly higher in the age group 55–69 years versus age group 18–39 years ($554 \pm 48 \mu\text{m}$ vs. $511 \pm 49 \mu\text{m}$; $p=0.004$), and in the oldest age group ≥ 70 years versus age group 40–54 years ($563 \pm 51 \mu\text{m}$ vs. $521 \pm 46 \mu\text{m}$; $p=0.02$) and versus age group 18–39 years ($563 \pm 51 \mu\text{m}$ vs. $511 \pm 49 \mu\text{m}$; $p=0.002$). A one-way ANOVA with Tukey's post-hoc test was used to test significance between age groups.

TABLE 2 Association between age group and scleral thickness per quadrant.

	Age 18–39	Age 40–54	Age 55–69	Age ≥ 70	Total	<i>p</i> -value
Temporal	492 \pm 64	492 \pm 58	534 \pm 58	559 \pm 73	516 \pm 67	<0.001
Nasal	533 \pm 63	539 \pm 79	601 \pm 64	614 \pm 71	567 \pm 76	<0.001
Superior	436 \pm 45	466 \pm 46	484 \pm 50	494 \pm 50	467 \pm 52	<0.001
Inferior	589 \pm 58	583 \pm 56	612 \pm 66	603 \pm 83	596 \pm 65	0.35

Note: Presented as mean \pm standard deviation.

a longitudinal study would be required to confirm this. Previous studies also reported a positive correlation between scleral thickness and age (Ebnetter et al., 2015; Fernandez-Vigo et al., 2021). This finding contrasts with other tissue measurements, such as muscle and skin tissue, wherein atrophy takes place with increasing age (Faulkner et al., 2007; Fukada & Kajija, 2020). It might be explained by a decrease in the collagen fibre alignment and a larger matrix stiffness of older sclerae that were noticed in a study by Coudrillier et al., who studied scleral biomechanical properties (Coudrillier et al., 2015). Although this study focused on the peripapillary region of the sclera, this might be extrapolated to the entire sclera.

It is known that the subfoveal scleral thickness decreases with higher myopia (Deng et al., 2019). Remarkably, we did not find a correlation between anterior scleral thickness and axial length. This is in accordance with a number of previous studies (Buckhurst et al., 2015; Fernandez-Vigo et al., 2021; Pekel et al., 2015; Read et al., 2016). However, it should be noted that patients with high myopia were excluded in some of these studies.

In our study, we noticed that image acquisition was more challenging for older volunteers. Eye movements due to poor fixation in the elderly and changes in conjunctival tissue, possibly due to phototoxic effects during life, might have caused a more blurry OCT scan (Cullen, 2002). This phenomenon might explain the decreased quality of the scans in the older age group, possibly impairing reproducibility of measurements. Another limitation is the fact that we have used spectral-domain OCT scanning, while swept-source OCT, used by Fernandez-Vigo et al. might be slightly beneficial in terms of image sensitivity (Fernandez-Vigo et al., 2021; Fernandez-Vigo et al., 2022). Heidelberg has recently delivered the 'Anterion', an anterior segment-specific swept-source OCT device that would be a better option. In our study, we used SD-OCT and experienced low intra- and inter-observer variability for scleral measurements, but moderate ICC for conjunctival and episcleral measurements. Improvement of the ICC might be reached by the use of swept-source OCT and expanded experience in the measurement of different layers on AS-OCT scans (Buckhurst et al., 2015; Fernandez-Vigo et al., 2021). Lastly, we have evaluated a considerable number of healthy volunteers in our study; however, the vast majority were Caucasian, and this data could not be directly extrapolated for all races (Yoo et al., 2011).

In summary, AS-OCT is a very useful method to measure conjunctival, episcleral and scleral thickness. Our study provides a comprehensive overview of thickness measures of the anterior eye wall in various age groups in healthy individuals. Scleral thickness varies between the quadrants of the eye and increases with age. The results of our study enable future research into the use of AS-OCT in diseases affecting the anterior eye wall.

ACKNOWLEDGEMENTS

This study was funded by Stichting Lijf en Leven under Grant (number L&L/mon/19-007).

DATA AVAILABILITY STATEMENT


The data that support the findings of this study are available from the corresponding author upon reasonable request.

ORCID

D. P. C. Vergouwen  <https://orcid.org/0000-0002-3872-1431>

W. D. Ramdas  <https://orcid.org/0000-0002-1780-5281>

L. Sanchez-Brea  <https://orcid.org/0000-0002-4061-4846>

A. Rothova  <https://orcid.org/0000-0002-3324-5034>

J. C. Ten Berge  <https://orcid.org/0000-0003-4610-4991>

J. C. Ten Berge  <https://orcid.org/0000-0003-4610-4991>

J. C. Ten Berge  <https://orcid.org/0000-0003-4610-4991>

J. C. Ten Berge  <https://orcid.org/0000-0003-4610-4991>

REFERENCES

- Boote, C., Sigal, I.A., Grytz, R., Hua, Y., Nguyen, T.D. & Girard, M.J.A. (2020) Scleral structure and biomechanics. *Progress in Retinal and Eye Research*, 74, 100773.
- Buckhurst, H.D., Gilmartin, B., Cubbage, R.P. & Logan, N.S. (2015) Measurement of scleral thickness in humans using anterior segment optical coherence tomography. *PLoS ONE*, 10, e0132902.
- Coudrillier, B., Pijanka, J., Jefferys, J., Sorensen, T., Quigley, H.A., Boote, C. et al. (2015) Collagen structure and mechanical properties of the human sclera: analysis for the effects of age. *Journal of Biomechanical Engineering*, 137, 041006.
- Cullen, A.P. (2002) Photokeratitis and other phototoxic effects on the cornea and conjunctiva. *International Journal of Toxicology*, 21, 455–464.
- Dahlmann-Noor, A.H. & Tillaux, P.J. (2008) P. J. Tillaux: of the way the muscles insert onto the sclera. 1877. *Strabismus*, 16, 174–175.
- Deng, J., Jin, J., Lv, M., Jiang, W., Sun, S., Yao, C. et al. (2019) Distribution of scleral thickness and associated factors in 810 Chinese children and adolescents: a swept-source optical coherence tomography study. *Acta Ophthalmologica*, 97, e410–e418.
- Ebnetter, A., Haner, N.U. & Zinkernagel, M.S. (2015) Metrics of the normal anterior sclera: imaging with optical coherence tomography. *Graefes' Archive for Clinical and Experimental Ophthalmology*, 253, 1575–1580.
- Faulkner, J.A., Larkin, L.M., Claflin, D.R. & Brooks, S.V. (2007) Age-related changes in the structure and function of skeletal muscles. *Clinical and Experimental Pharmacology & Physiology*, 34, 1091–1096.
- Feng, Y. & Simpson, T.L. (2008) Corneal, limbal, and conjunctival epithelial thickness from optical coherence tomography. *Optometry and Vision Science*, 85, E880–E883.
- Fernandez-Vigo, J.I., Shi, H., Burgos-Blasco, B., De-Pablo-Gomez-de-Liano, L., Almorin-Fernandez-Vigo, I., Kudsieh, B. et al. (2021) Impact of age, sex and refractive error on conjunctival and Tenon's capsule thickness dimensions by swept-source optical coherence tomography in a large population. *International Ophthalmology*, 41, 3687–3698.
- Fernandez-Vigo, J.I., Shi, H., Burgos-Blasco, B., Fernandez-Aragon, S., De-Pablo-Gomez-de-Liano, L., Kudsieh, B. et al. (2022) Anterior scleral thickness dimensions by swept-source optical coherence tomography. *Clinical & Experimental Optometry*, 105, 13–19.
- Fukada, K. & Kajija, K. (2020) Age-related structural alterations of skeletal muscles and associated capillaries. *Angiogenesis*, 23, 79–82.
- Heiligenhaus, A., Schilling, M., Lung, E. & Steuhl, K.P. (1998) Ultrasound biomicroscopy in scleritis. *Ophthalmology*, 105, 527–534.
- Howlett, J., Vahdani, K. & Rossiter, J. (2014) Bulbar conjunctival and Tenon's layer thickness measurement using optical coherence tomography. *Journal of Current Glaucoma Practice*, 8, 63–66.
- Jonas, J.B. & Xu, L. (2014) Histological changes of high axial myopia. *Eye (London, England)*, 28, 113–117.
- Liang, Q., Le, Q., Cordova, D.W., Tseng, C.H. & Deng, S.X. (2020) Corneal epithelial thickness measured using anterior segment optical coherence tomography as a diagnostic parameter for

- limbal stem cell deficiency. *American Journal of Ophthalmology*, 216, 132–139.
- Lim, S.H. (2015) Clinical applications of anterior segment optical coherence tomography. *Journal of Ophthalmology*, 2015, 605729.
- Mohamed-Noor, J., Bochmann, F., Siddiqui, M.A., Atta, H.R., Leslie, T., Maharajan, P. et al. (2009) Correlation between corneal and scleral thickness in glaucoma. *Journal of Glaucoma*, 18, 32–36.
- Nanji, A.A., Sayyad, F.E., Galor, A., Dubovy, S. & Karp, C.L. (2015) High-resolution optical coherence tomography as an adjunctive tool in the diagnosis of corneal and conjunctival pathology. *The Ocular Surface*, 13, 226–235.
- Nolan, W. (2008) Anterior segment imaging: ultrasound biomicroscopy and anterior segment optical coherence tomography. *Current Opinion in Ophthalmology*, 19, 115–121.
- Okhravi, N., Odufuwa, B., McCluskey, P. & Lightman, S. (2005) Scleritis. *Survey of Ophthalmology*, 50, 351–363.
- Oliveira, C., Tello, C., Liebmann, J. & Ritch, R. (2006) Central corneal thickness is not related to anterior scleral thickness or axial length. *Journal of Glaucoma*, 15, 190–194.
- Pekel, G., Yagci, R., Acer, S., Ongun, G.T., Cetin, E.N. & Simavli, H. (2015) Comparison of corneal layers and anterior sclera in emmetropic and myopic eyes. *Cornea*, 34, 786–790.
- Podoleanu, A.G. (2012) Optical coherence tomography. *Journal of Microscopy*, 247, 209–219.
- Prakash, G., Avadhani, K., Philip, R. & Bacero, R. (2015) Spectral domain OCT-based evaluation of the sclera and its adjacent layers. *Cornea*, 34, e25–e26.
- Read, S.A., Alonso-Caneiro, D., Vincent, S.J., Bremner, A., Fothergill, A., Ismail, B. et al. (2016) Anterior eye tissue morphology: scleral and conjunctival thickness in children and young adults. *Scientific Reports*, 6, 33796.
- Singh, M., See, J.L., Aquino, M.C., Thean, L.S. & Chew, P.T. (2009) High-definition imaging of trabeculectomy blebs using spectral domain optical coherence tomography adapted for the anterior segment. *Clinical & Experimental Ophthalmology*, 37, 345–351.
- Sung, M.S., Ji, Y.S., Moon, H.S., Heo, H. & Park, S.W. (2021) Anterior scleral thickness in myopic eyes and its association with ocular parameters. *Ophthalmic Research*, 64, 567–576.
- Theotoka, D., Wall, S., Galor, A., Sripawadkul, W., Khzam, R.A., Tang, V. et al. (2022) The use of high resolution optical coherence tomography (HR-OCT) in the diagnosis of ocular surface masqueraders. *The Ocular Surface*, 24, 74–82.
- Vergouwen, D.P.C., Rothova, A., Berge, J.C.T., Verdijk, R.M., van Laar, J.A.M., Vingerling, J.R. et al. (2020) Current insights in the pathogenesis of scleritis. *Experimental Eye Research*, 108078, 108078.
- Vurgese, S., Panda-Jonas, S. & Jonas, J.B. (2012) Scleral thickness in human eyes. *PLoS ONE*, 7, e29692.
- Wakefield, D., Di Girolamo, N., Thureau, S., Wildner, G. & McCluskey, P. (2013) Scleritis: challenges in immunopathogenesis and treatment. *Discovery Medicine*, 16, 153–157.
- Watson, P.G. & Young, R.D. (2004) Scleral structure, organisation and disease. A review. *Experimental Eye Research*, 78, 609–623.
- Yoo, C., Eom, Y.S., Suh, Y.W. & Kim, Y.Y. (2011) Central corneal thickness and anterior scleral thickness in Korean patients with open-angle glaucoma: an anterior segment optical coherence tomography study. *Journal of Glaucoma*, 20, 95–99.
- Zhang, X., Li, Q., Xiang, M., Zou, H., Liu, B., Zhou, H. et al. (2013) Bulbar conjunctival thickness measurements with optical coherence tomography in healthy chinese subjects. *Investigative Ophthalmology & Visual Science*, 54, 4705–4709.

SUPPORTING INFORMATION

Additional supporting information can be found online in the Supporting Information section at the end of this article.

How to cite this article: Teeuw, G.J., Vergouwen, D.P.C., Ramdas, W.D., Sanchez-Brea, L., Andrade De Jesus, D., Rothova, A. et al. (2023) Assessment of conjunctival, episcleral and scleral thickness in healthy individuals using anterior segment optical coherence tomography. *Acta Ophthalmologica*, 00, 1–8. Available from: <https://doi.org/10.1111/aos.16606>