



## Original Contribution



# A comparison of ultrafast and conventional spectral Doppler ultrasound to measure cerebral blood flow velocity during inguinal hernia repair in infants

Mathies Rondagh<sup>a,1</sup>, Anna J. Kortenbout<sup>b,1</sup>, Sophie de Munck<sup>c</sup>, Gerbrich E. van den Bosch, MD, PhD<sup>d</sup>, Jeroen Dudink, MD, PhD<sup>e</sup>, Hendrik J. Vos, PhD<sup>b</sup>, Johan G. Bosch, PhD<sup>b</sup>, Jurgen C. de Graaff, MD, PhD<sup>a,f,g,\*</sup>

<sup>a</sup> Department of Anesthesiology, Erasmus MC University Medical Centre Rotterdam, Rotterdam, the Netherlands

<sup>b</sup> Department of Biomedical Engineering, Erasmus MC University Medical Centre Rotterdam, Rotterdam, the Netherlands

<sup>c</sup> Department of Surgery, Erasmus MC University Medical Centre Rotterdam, Rotterdam, the Netherlands

<sup>d</sup> Department of Neonatology, Erasmus MC University Medical Centre Rotterdam, Rotterdam, the Netherlands

<sup>e</sup> Department of Neonatology, UMC Utrecht University Medical Centre Utrecht, Utrecht, the Netherlands

<sup>f</sup> Department of Anesthesiology, Adz – Erasmus MC, Goes, the Netherlands

<sup>g</sup> Department of Anesthesiology, Weill Cornell Medicine, New York, NY, United States of America

## HIGHLIGHTS

- Novel application of cerebral ultrafast Doppler in perioperative infant care.
- Simultaneous quantification and visualization of blood flow with ultrafast Doppler.
- Ultrafast Doppler results comparable to conventional spectral Doppler.
- Evaluation of the useability and practical considerations with ultrafast Doppler.

## ARTICLE INFO

## Keywords:

Cerebral blood flow velocity  
Doppler ultrasound  
Ultrafast Doppler ultrasound  
Pediatric anesthesia  
Perioperative brain monitoring

## ABSTRACT

**Background:** Ultrafast cerebral Doppler ultrasound enables simultaneous quantification and visualization of cerebral blood flow velocity. The aim of this study is to compare the use of conventional and ultrafast spectral Doppler during anesthesia and their potential to show the effect of anesthesiologic procedures on cerebral blood flow velocities, in relation to blood pressure and cerebral oxygenation in infants undergoing inguinal hernia repair.

**Methods:** A single-center prospective observational cohort study in infants up to six months of age. We evaluated conventional and ultrafast spectral Doppler cerebral ultrasound measurements in terms of number of successful measurements during the induction of anesthesia, after sevoflurane induction, administration of caudal analgesia, a fluid bolus and emergence of anesthesia. Cerebral blood flow velocity was quantified in pial arteries using conventional spectral Doppler and in the cerebral cortex using ultrafast Doppler by peak systolic velocity, end diastolic velocity and resistivity index.

**Results:** Twenty infants were included with useable conventional spectral Doppler images in 72/100 measurements and ultrafast Doppler images in 51/100 measurements. Intraoperatively, the success rates were 53/60 (88.3%) and 41/60 (68.3%), respectively. Cerebral blood flow velocity increased after emergence for both conventional (end diastolic velocity, from 2.01 to 2.75 cm/s,  $p < 0.001$ ) and ultrafast spectral Doppler (end diastolic velocity, from 0.59 to 0.94 cm/s), whereas cerebral oxygenation showed a reverse pattern with a decrease after the emergence of the infant (85% to 68%,  $p < 0.001$ ).

**Conclusion:** It is possible to quantify cortical blood flow velocity during general anesthesia using conventional and ultrafast spectral Doppler cerebral ultrasound. Cerebral blood flow velocity and blood pressure decreased,

\* Corresponding author at: Department of Anesthesiology, Erasmus MC University Medical Centre Rotterdam, Rotterdam, the Netherlands.

E-mail address: [j.degraaff@erasmusmc.nl](mailto:j.degraaff@erasmusmc.nl) (J.C. de Graaff).

<sup>1</sup> Both authors contribute equally.

while regional cerebral oxygenation increased during general anesthesia. Ultrafast spectral Doppler ultrasound offers novel insights into perfusion within the cerebral cortex, unattainable through conventional spectral ultrasound. Yet, ultrafast Doppler is curtailed by a lower success rate and a more rigorous learning curve compared to conventional method.

## 1. Introduction

Over the past 20 years, several case reports of infants with severe forms of encephalopathy after non-cardiac surgery have been published. [1–3] Despite alleged uneventful anesthesia these infants presented with new-onset seizures within 25 h after administration of anesthesia in combination with predominant cerebral pathology, including supratentorial watershed infarction in the border zones between the anterior, middle, and posterior cerebral arteries on magnetic resonance imaging. [1–3] These perioperative brain lesions are associated with suboptimal neurodevelopmental outcomes. [4,5] It has been suggested that postoperative encephalopathy might arise from local cerebral ischemia caused by disturbances in autoregulation and cerebral perfusion in the perioperative phase. [1,4,6] Standard monitoring techniques for tracking vital parameters such as heart rate and blood pressure lack sensitivity to detect altered cerebral perfusion. [7] Adequate perioperative blood pressure does not warrant sufficient cerebral perfusion as postoperative encephalopathy may occur in apparently uncomplicated anesthesia with adequate blood pressure. [1–3]

Conventional Doppler ultrasound, characterized by a low frame rate (10–100 frames/s), allows for 2D visualization of vessels, and represents either mean blood flow velocity (“colour Doppler”), total blood flow (“power Doppler”), or total blood flow and its direction (“directional power Doppler”). [8] The cerebral blood flow velocity acts as a surrogate of cerebral perfusion. Another mode, conventional spectral Doppler, is a well-established and user-friendly technique that can measure the local blood flow velocity spectrum within a sample volume placed over a vessel by the sonographer and also the time trace of the maximum velocity within the sample, by estimating the envelope of the spectral signal. [8] Spectral Doppler provides much more detailed velocity information than colour Doppler but is limited to one single sample location. [8] However, conventional modes are limited because of the low frame rate, which restricts the measurement to either qualitative or quantitative data, but not both. For instance, spectral Doppler provides detailed velocity information but is limited to one sample location, serving as a significant drawback.

On the other hand, ultrafast Doppler ultrasound, which utilizes a high frame rate of >500 frames per second, offers a more comprehensive approach. It enables the simultaneous utilization of power Doppler, colour Doppler, and spectral Doppler in every pixel of the imaging plane using the same dataset. [9] Moreover, since we have spectral Doppler traces for each pixel, we can calculate quantitative parameters for each blood flow pixel in the imaging plane through the implementation of an automatic envelope detection (spectral Doppler tracing). [10] Ultrafast Doppler compared to conventional spectral Doppler measurements provides an overview of cerebral cortex perfusion. This approach provides the advantage of obtaining all the desired parameters for the whole image in a single two second ultrafast ultrasound acquisition, potentially enhancing efficiency and accuracy.

Therefore, this study aims to evaluate and compare the use of conventional and ultrafast spectral Doppler cerebral ultrasound in the various stages of perioperative phase in neonates. Furthermore, we used these techniques to study the influence of anesthesia on cerebral blood flow velocity in otherwise healthy infants undergoing inguinal hernia repair with a standardized anesthesia protocol.

## 2. Patients and methods

### 2.1. Study design

This single-center prospective observational cohort study was approved by the Medical Ethical Review Committee of the Erasmus MC university Medical Centre, Rotterdam (MEC-2021-0187). The trial is registered under the number NL9749 (<https://onderzoekmetmensen.nl/en/trial/19965>). Patients were included in the study after obtaining written informed consent from both parents or caregivers.

### 2.2. Patients

Otherwise healthy infants (aged 0 to 6 months) with a unilateral or bilateral inguinal hernia, scheduled for open surgery between 20 September 2021 and 1 March 2022 were eligible for inclusion. Exclusion criteria were extreme preterm birth (<28 weeks), requirement of emergency surgery for incarcerated inguinal hernia, presence of a genetic syndrome.

### 2.3. Anesthesia and measurement protocol

All infants were operated on according to standard local practice for open surgical inguinal hernia repair. Infants were allowed to drink glucose until call for surgery and milk up to 4 h before the scheduled procedure.

The induction of anesthesia took place using sevoflurane (InSevo 8% in 80% O<sub>2</sub> and 20% room air), after intravenous access was applied. A laryngeal mask was placed, striving for spontaneous breathing (zero positive end-expiratory pressure, without pressure support). The end-tidal sevoflurane (EtSev) target concentration was 2.0–3.3% (in 40% O<sub>2</sub> with room air). Next, perioperative analgesia was provided with caudal analgesia using 1.0–1.2 ml/kg ropivacaine (2 mg/ml, without additives). Preferably no opiates were administered to maintain spontaneous ventilation. Thereafter, 10 ml/kg fluid bolus of a balanced pediatric electrolyte solution with glucose 10 g/l (Kidalyte, Fresenius Kabi, The Netherlands) or a Ringer's lactate solution was administered in 10 min.

The method of laryngeal mask removal (deep or awake) was left to the discretion of the attending anesthesiologists. Administration of oxygen administration in the recovery room was only applied on indication (saturation < 92%) and was not applied during the measurements (T5). Monitoring of vital parameters took place, as described in more detail in the ‘Data collection’ section.

For postoperative management of pain, 15 mg/kg intravenous paracetamol (Perfalgan, Fresenius Kabi, Huis ter Heide, Netherlands) was administered in combination with 0.5 mg/kg intravenous diclofenac (Sandoz Novartis, Basel, Swiss) if the infant was older than 4 months. At the recovery, the infant was allowed to drink glucose water, formula or breast milk. Deviation from this standardized anesthesia protocol was possible on indication of the anesthesiologist (e.g., rescue medication could be administered) and subsequently these participants were excluded.

The cerebral ultrasound measurements took place at 5 moments perioperatively: (T1) awake at the operating room before induction of anesthesia, (T2) after induction of anesthesia, (T3) after administration of caudal anesthesia, (T4) during surgery after administration of the standard fluid bolus and (T5) after emergence of anesthesia in the recovery room (Fig. 1).

#### 2.4. Data collection

Patient characteristics were collected from the electronic patient database HiX (version 6.1 Erasmus MC, Chipsoft, Amsterdam, The Netherlands). The following standard monitoring parameters: non-invasive blood pressure measurements (non-invasive blood pressure, in mmHg), heart rate (HR, in beats per minute), peripheral oxygen saturation (SpO<sub>2</sub>, in %), end tidal carbon dioxide (EtCO<sub>2</sub>, in kPa) and end tidal sevoflurane concentration (EtSev, in %) during the surgery were obtained through the Dräger Infinity Network (Primus, Dräger, Luebeck, Germany). The cerebral regional oxygen saturation (in %) was measured with near infrared spectroscopy (INVOS™ 5100C, Covidien, Boulder, Colorado, United States). All parameters were continuously recorded per second, except non-invasive blood pressure. The non-invasive blood pressure was measured every 5 min and the non-invasive blood pressure-measurement closest to the cerebral ultrasound measurement was used for analysis. Median values were determined for the pulse rate, EtCO<sub>2</sub>, EtSev and SpO<sub>2</sub> and regional oxygen saturation for two minutes before and after the five measurement moments.

Details of the measurement setup for the conventional spectral Doppler ultrasound measurements have been described in detail before (Fig. 1). [11] In short, cerebral ultrasound was performed with a Zonare ZS3 clinical ultrasound machine (Mindray Medical International, Hoevelaken, The Netherlands) with a high frequency linear probe (L20–5). The ultrasound probe was placed sagittal on the infant's anterior fontanel and the area adjacent to the lateral ventricle was located. Patients were excluded if the acoustic window was too small, because of a closing fontanel. Conventional directional power Doppler was used to visualize the cerebral vasculature. One recognizable pial artery was located for a spectral Doppler measurement (Fig. 1). The settings for the conventional directional power Doppler measurements were a frequency of 11 MHz, the lowest pulse repetition frequency setting possible for maximum sensitivity to low flow velocities (257 Hz), and a medium wall filter. The conventional spectral Doppler was performed at 8 MHz with a velocity range optimized for the individual pial artery flow and the wall filter set to low, no angle correction was performed. After these measurements, the probe was kept in position and the ultrasound machine was switched to an ultrafast mode to record 2000 frames with a median framerate of 658 Hz (range 588–674 Hz).

Conventional spectral Doppler images were included if they met the following criteria: sufficient signal, recognizable anatomical hallmarks (V-shape, branch vasculature and 2nd or 3rd branch of the anterior cerebral artery), same direction of flow and in the same pial artery. Images were excluded when movement artefacts occurred. The ultrafast Doppler cerebral ultrasound measurements have been performed in the same plane and were included if they met the following criteria: anatomical structures corresponding to conventional spectral Doppler, signal-to-noise ratio of ultrafast Doppler sufficient; no significant motion artefacts obstructed the processing and at least 1000 frames available for processing.

#### 2.5. Outcome measures and data analysis

The primary outcome was the number of successful measurements with both conventional and ultrafast spectral Doppler cerebral ultrasound during various phases of standard anesthesiologic procedures. The secondary outcome measures were the cerebral blood flow velocities expressed in peak systolic velocity, end diastolic velocity and resistivity index using conventional and ultrafast spectral Doppler cerebral ultrasound during various phases of standard anesthesiologic procedures. The peak systolic velocity corresponds with each heart cycle's maximum in the envelope of the conventional spectral Doppler. The end diastolic velocity corresponds with the minimum in the envelope for each cardiac cycle. The resistivity index is calculated as (peak systolic velocity - end diastolic velocity)/peak systolic velocity and represents an

index of pulsatile blood flow that reflects resistance to blood flow, caused by the microvascular bed distal to the measurement site. [12]

For the conventional spectral Doppler, peak systolic velocity, end diastolic velocity and resistivity index of the selected pial artery were recorded as determined automatically by the ultrasound system's spectral envelope detection. The outcome was visually assessed to ensure that the tracings were accurate with expected ultrasound parameters. The ultrafast frames per measurements were analyzed offline in a custom-developed MATLAB processing script (R2022a, Mathworks, Natick, MA, USA). First, stationary tissue was removed with a singular value decomposition filter to create a power Doppler image, where an automatic selection determined all pixels with significant blood flow velocity. For those pixels, a spectrogram was calculated and processed to automatically detect the envelope of this spectrogram, representing the local blood velocity at each timepoint. The envelope allowed for calculation of pixel-wise end diastolic velocity, peak systolic velocity and resistivity index. Peak systolic velocity and end diastolic velocity were calculated by finding a maximum and minimum per heartbeat in the envelope and averaging the corresponding velocity values over all heartbeats. This resulted in 2D maps of peak systolic velocity, end diastolic velocity and resistivity index. [12] As the ultrafast Doppler cerebral ultrasound technique is relatively new and therefore lacks established validation methods in the literature, we compared the direction and amplitude of the changes measured with both techniques at each time point.

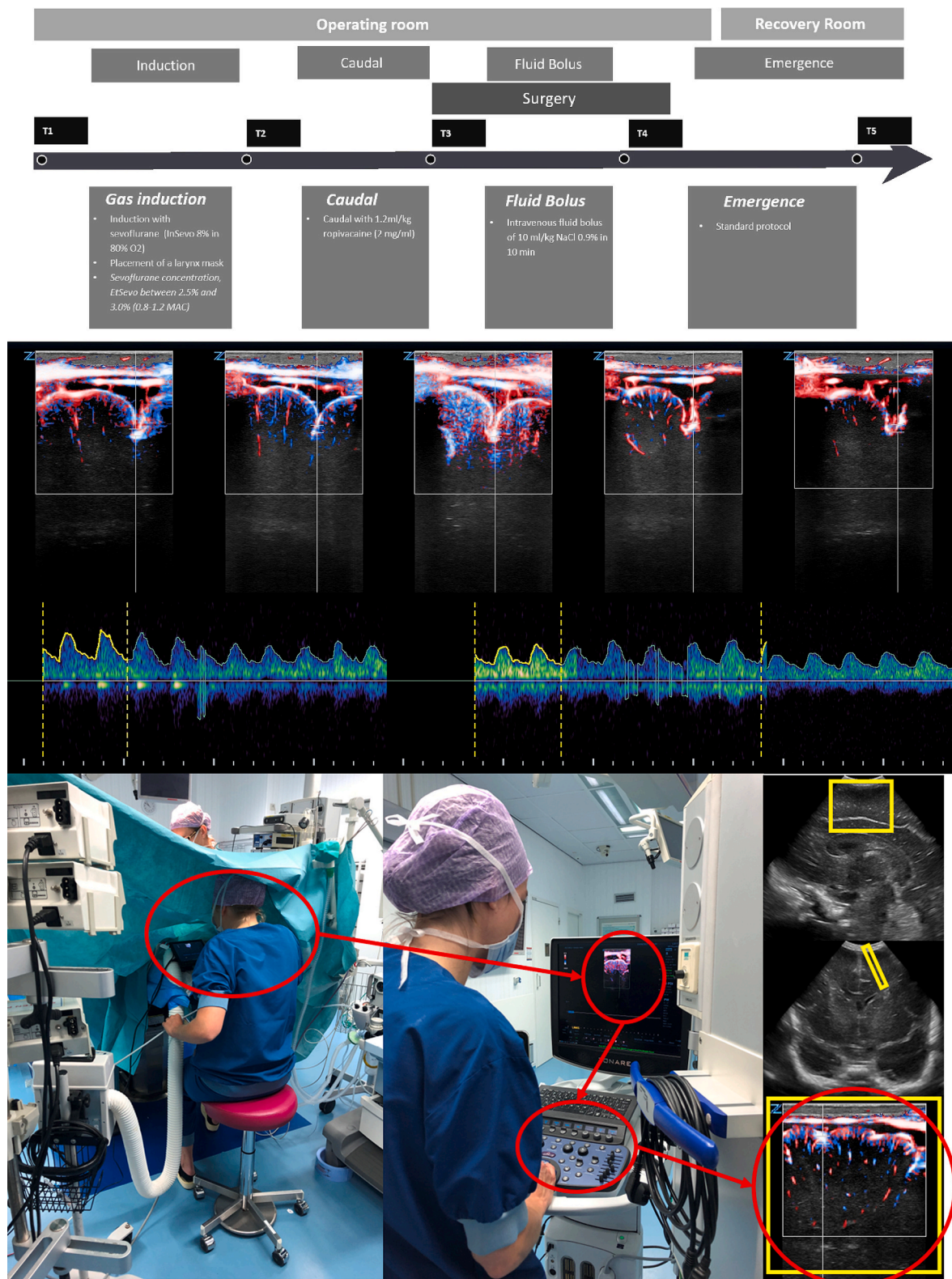
#### 2.6. Statistical analysis and sample size

Continuous data are presented as median with interquartile ranges (IQR) and categorical data as number (n) or in percentages (%). Median values of all valid blood flow pixels in the 2D ultrafast maps were taken for end diastolic velocity, peak systolic velocity and resistivity index. Differences in cerebral blood flow velocity and vital parameters using conventional and ultrafast spectral Doppler cerebral ultrasound between the five phases of anesthesia were investigated by linear mixed model (LMM) analyses. Phase of anesthesia was included as independent factor, the ultrasound parameters as dependent variable, and patient as random effect in the analyses. Statistical analyses were performed in SPSS (version 28.0.1.0, IBM Corporation, Chicago, Illinois, United States). A sample size calculation was not performed for this study as insufficient information is available about the cerebral blood flow velocities of ultrafast Doppler cerebral ultrasound in humans. Therefore, an arbitrary sample size of valid measurements in 20 patients was chosen.

### 3. Results

Out of 66 infants assessed for eligibility, 20 were included in the analyses. Infants were excluded for comorbidities, absence of informed consent, logistical and technical reasons (Fig. 2). The postmenstrual age of infants on the day of surgery was 50 weeks and 6 days (45 weeks and 1 day – 57 weeks and 4 days). The weight at surgery was 5300 (4890–5740) grams. Participants were fasted of fluids for surgery 4h30m (4 h – 5h30m) before anesthesia (Table 1).

Measurements with conventional spectral Doppler cerebral ultrasound were successful in respectively 7 (35%), 16 (80%), 20 (100%), 17 (85%) and 12 (60%) infants for the 5 measurement phases (72/100). Conventional spectral Doppler cerebral ultrasound measurements were excluded due to different anatomy ( $n = 7$ ), aberrant flow direction ( $n = 9$ ) and agitation of the infant ( $n = 12$ ). Conventional spectral Doppler achieved successful measurements in 53/60 (88.3%) during anesthesia (T2, T3 and T4) and 19/40 (47.5%) in the pre- and postoperative phase (T1 and T5). Ultrafast spectral Doppler measurements were successful in respectively 6 (30%), 14 (70%), 15 (75%), 12 (60%) and 4 (20%) infants for the 5 measurement phases (51/100). 49 ultrafast Doppler cerebral ultrasound measurements were excluded due to movement artefacts



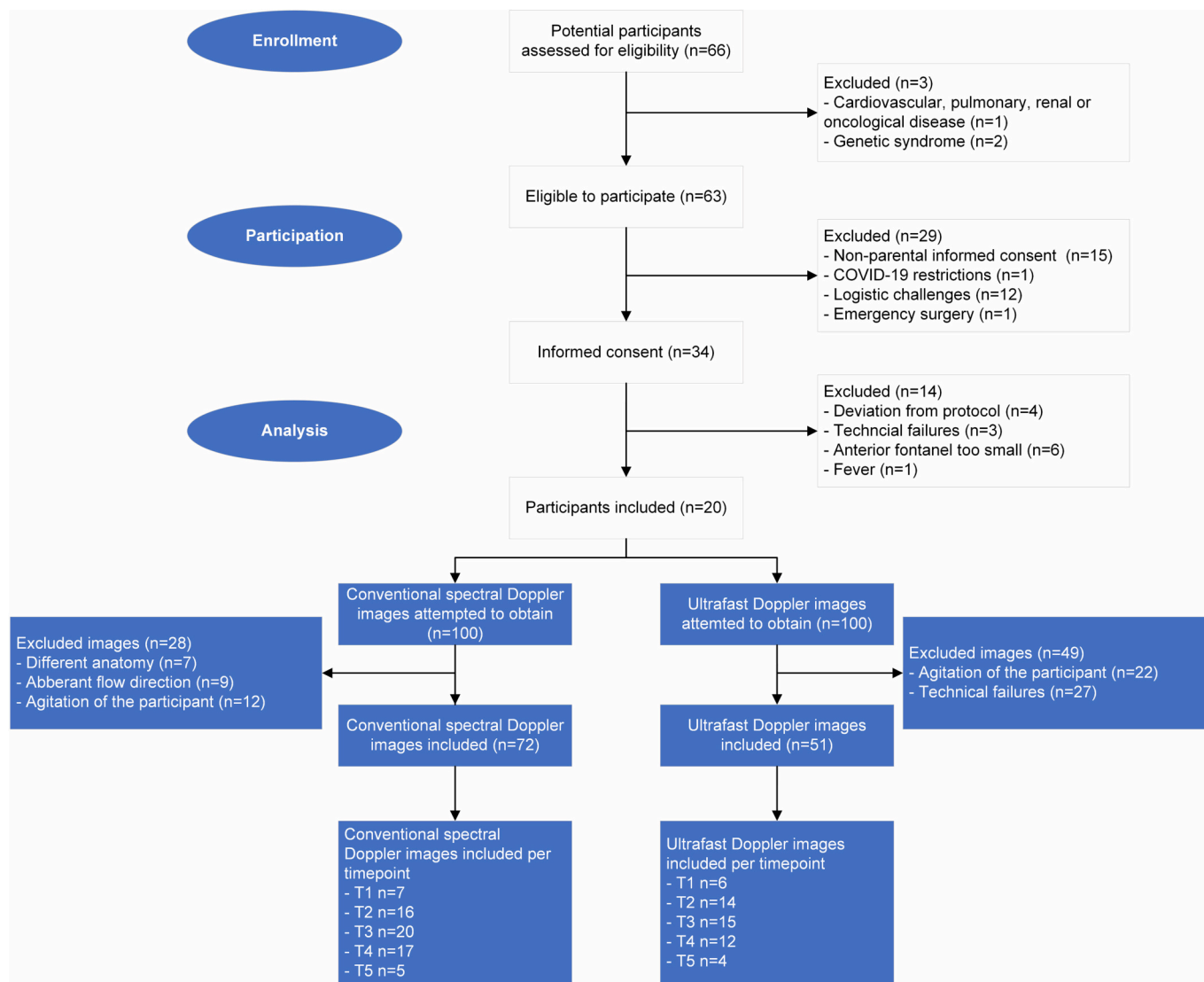


Fig. 2. Inclusion chart.

An overview of the inclusion and feasibility of conventional Doppler measurements and ultrafast Doppler measurements for every measurement phase. Parental informed consent was obtained for 48 infants. 14 infants were excluded due to logistical reasons (e.g., emergency surgery, Sars-Cov-2 restrictions). Of the 34 remaining infants, 14 infants were excluded due to inadequate measurements because of insufficient size of the anterior fontanel ( $n = 6$ ), a deviation from the anesthesiologic protocol ( $n = 4$ ), fever ( $n = 1$ ) or a technical failure of the equipment ( $n = 3$ ).

Table 1

Patient and procedure characteristics.

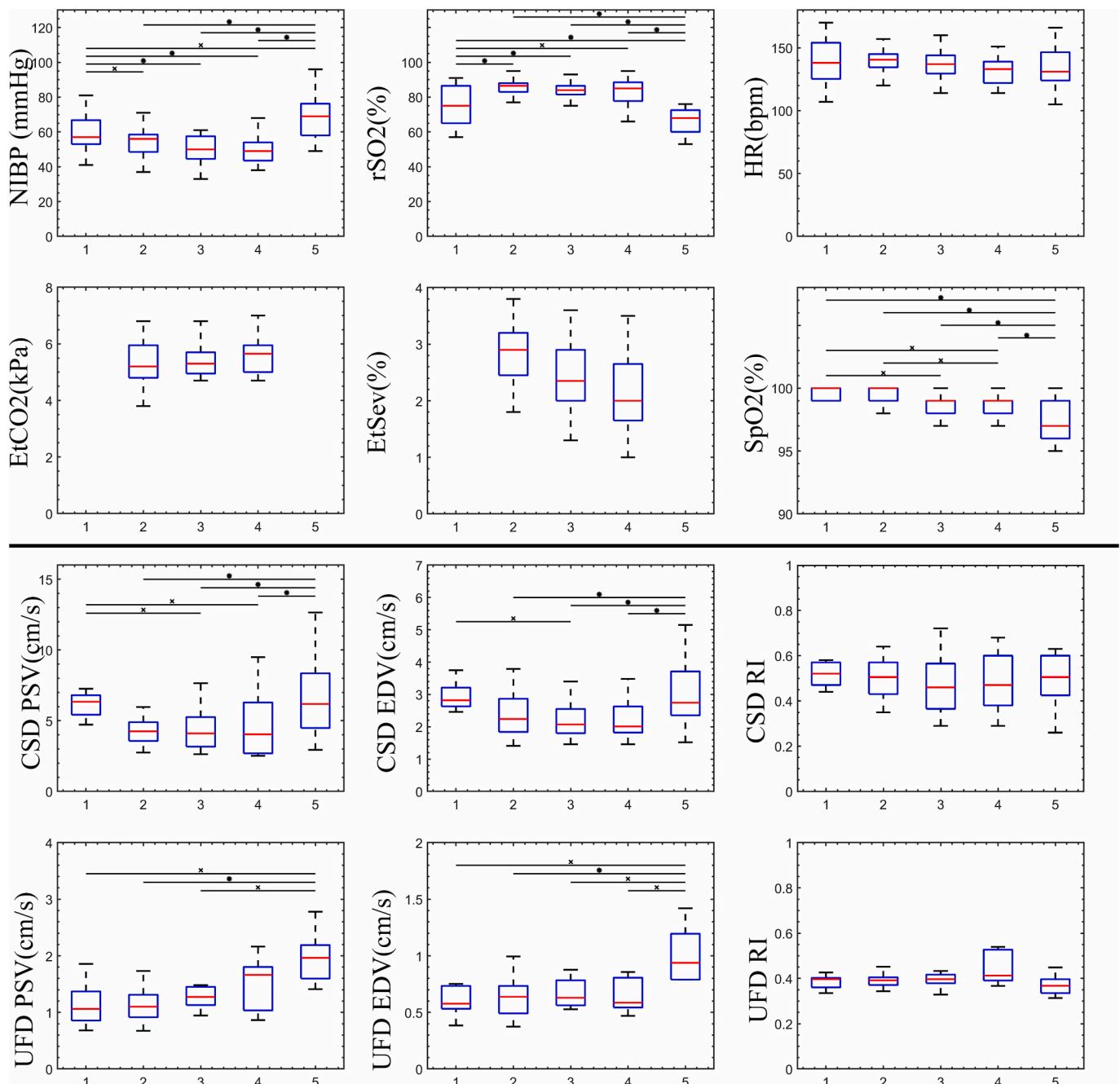
Characteristics	Patients (n = 20)
Sex Male / Female	18/2
Gestational age (weeks + days)	36 + 4 (33 + 4–38 + 5)
Age at surgery (weeks + days)	14 + 2 (11 + 4–18 + 6)
Postmenstrual age (weeks + days)	50 + 6 (45 + 1–57 + 4)
Birth weight (grams)	2389 (1750–3175)
Weight at surgery (grams)	5300 (4890–5740)
Hernia Type: left / right / bilateral	9 / 10 / 1
ASA Classification: I / II	8 / 12
Last oral fluid intake (hours + minutes)	4h30min (4 h00–5h30min)
Ropivacaine (ml/kg)	1.1 (1.0–1.2)
Intraoperative fluid administration (ml/kg)	23.9 (14.2–30.0)
Anesthesia duration (minutes)	57 m (52min30s–62 min)
Surgery duration (minutes)	22 m (16 min–29min30s)

Data are presented in numbers or as median with interquartile range.

caused by agitation of the infant before or after anesthesia ( $n = 22$ ) and technical failures ( $n = 27$ ). Ultrafast spectral Doppler achieved successful measurements in 41/60 (68.3%) during anesthesia and 10/40 (25%) in the pre- and postoperative phase.

The median duration of anesthesia was 57 min (52min30s–62 min) and surgery was 22 min (16 min–29min30sec). During anesthesia, a total of 23.9 ml/kg (14.2–30.1) fluid was administered. The end-tidal sevoflurane concentration after induction was 2.9% (2.5–3.2) and during surgery 2.4% (2.0–2.9). EtCO<sub>2</sub> during the surgery was 5.4 kPa (4.90–5.80). 3 infants were given a dose of 2.06 µg/kg (0.88–2.10) of fentanyl after the surgery (T4). In the recovery room 8 infants received a dose of 0.04 mg/kg (0.03–0.06) morphine before T5 occurred. The non-invasive blood pressure decreased significantly at T2 ( $p = 0.006$ ) and increased significantly at T5 ( $p < 0.001$ , Fig. 3, Supplementary Table 1). The regional oxygen saturation increased significantly at T2 and decreased at T5 (both  $p < 0.001$ ).

In the conventional spectral Doppler measurement, peak systolic velocity and end diastolic velocity decreased significantly at T3 compared to T1. The peak systolic velocity also decreased significantly

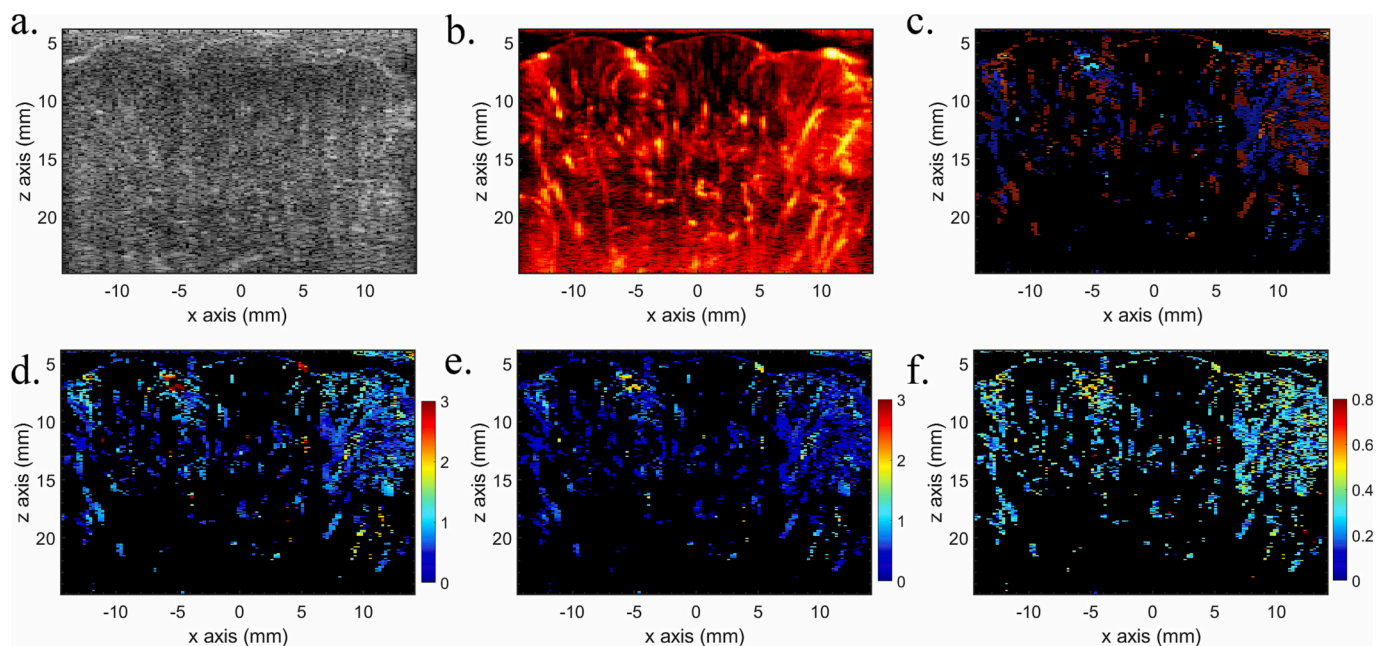


**Fig. 3.** Overview of ultrasound parameters and vital parameters.

Boxplots showing median with interquartile range (25 and 75%) and minimum and maximum (error bars) of the vital parameters and ultrasound parameters for the different measurement moments: awake at the operating room before induction of anesthesia (T1), after induction of anesthesia (T2), after administration of caudal anesthesia (T3), during surgery after administration of the standard fluid bolus (T4) and after emergence of anesthesia in the recovery room (T5). x:  $p < 0.05$ , \*:  $p \leq 0.001$ . EDV = end diastolic velocity, PSV = peak systolic velocity, RI = resistivity index, CSD = conventional spectral Doppler, UFD = ultrafast Doppler

at T4 compared to T1. After the emergence (T5), peak systolic velocity (4.04 cm/s at T4 to 6.18 cm/s at T5,  $p < 0.001$ ) and end diastolic velocity (2.01 cm/s at T4 to 2.75 cm/s at T5,  $p < 0.001$ ) were significantly higher than T2-T4 (Fig. 3). An example of an ultrafast measurement is shown in Fig. 4. In the ultrafast measurements, the peak systolic velocity and end diastolic velocity were both significantly higher at T5 compared to T2-3. In the case of end diastolic velocity, there was also a significant difference (0.59 cm/s at T4 to 0.94 cm/s at T5,  $p < 0.001$ ) between T4 and T5. The peak systolic velocity and end diastolic velocity measured with both conventional and ultrafast spectral Doppler cerebral ultrasound were found to be significantly higher at T5 than at T2-T3, similar

to the non-invasive blood pressure measurements. Regional oxygen saturation has a reversed pattern compared to peak systolic velocity, end diastolic velocity and non-invasive blood pressure with significantly lower values at T5 compared to T2-4. Only peak systolic velocity measured with conventional spectral Doppler cerebral ultrasound was significantly correlated with one of the vital parameters (regional oxygen saturation,  $p = 0.025$ ). Although the absolute values obtained from the two techniques were in different ranges, there was a consistent trend in the direction of change over time. This similarity in trend suggests a promising alignment between the two techniques, even though direct comparison in terms of percentage change might not be feasible due to



**Fig. 4.** Overview of the ultrafast Doppler cerebral ultrasound parameter maps.

Example of the parameter maps for one of the measurement moments. The B-mode image (A), Power Doppler image (B), Directional power Doppler image (C) are shown as an example. The corresponding parameter maps of respectively peak systolic velocity (D) with colormap in cm/s, end diastolic velocity (E) with colormap in cm/s and resistivity index (F) are shown. Median values of all valid blood flow pixels in the 2D ultrafast maps were taken for end diastolic velocity, peak systolic velocity and resistivity index calculations. Note that the values of cerebral blood flow velocity are lower in the ultrafast Doppler measurements, since these measurements are from both veins and arteries, where in the conventional spectral Doppler measurements only a single artery is selected.

the differing ranges of the measurements. The potential of the conventional and ultrafast spectral Doppler is presented as an example in Fig. 5 which shows the effect of the administration of caudal anesthesia and initiation of norepinephrine infusion on conventional and ultrafast spectral Doppler parameters. The patient was excluded from the analyses because of the initiation of norepinephrine. This example demonstrates the potential use of conventional and ultrafast Doppler to directly observe effects of anesthesiologic interventions on cerebral blood flow velocities.

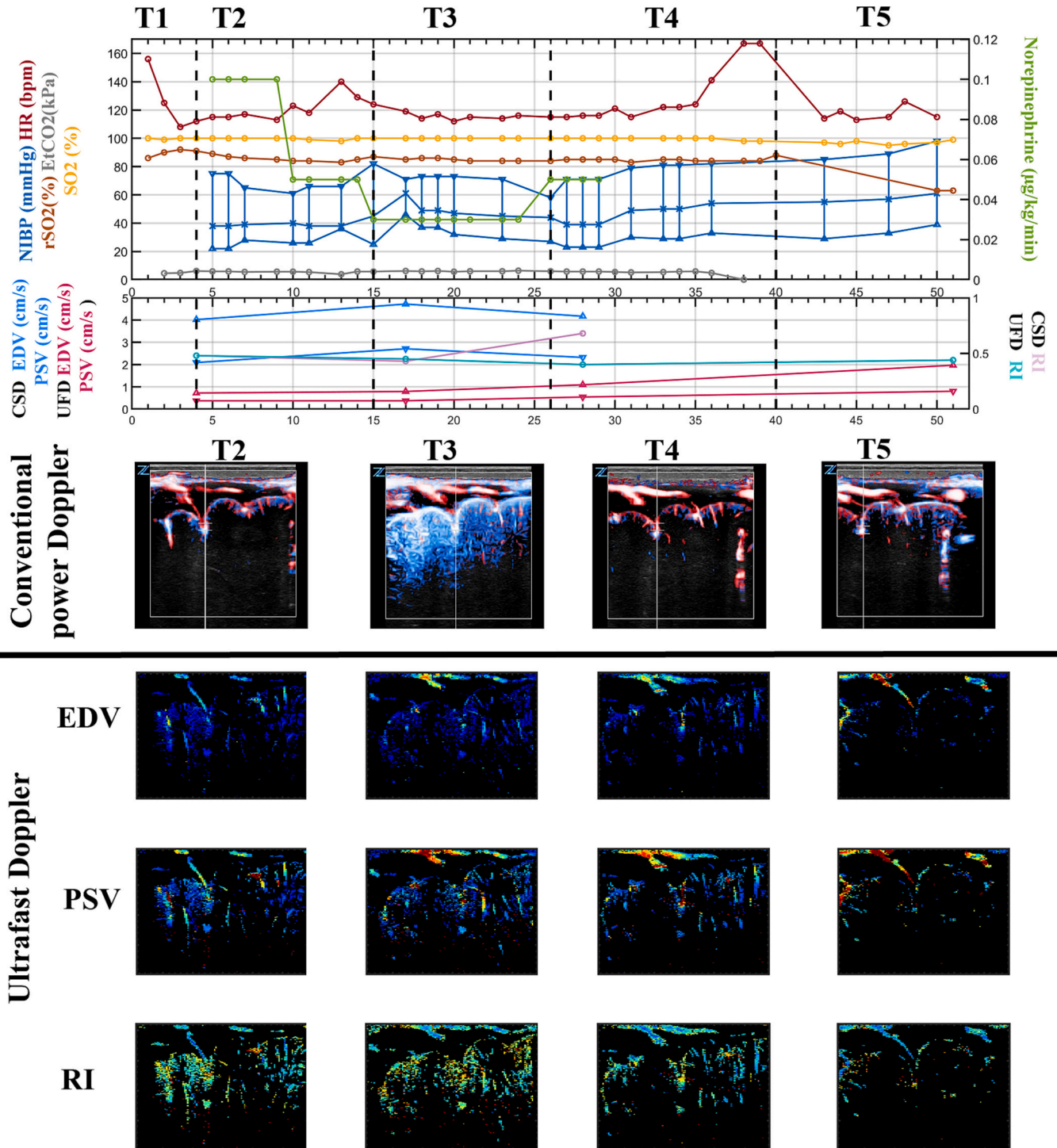
#### 4. Discussion

The present study shows that it was possible to evaluate the changes in cerebral blood flow velocity in pial arteries measured with conventional spectral Doppler and in the cerebral cortex with ultrafast Doppler between various phases of standard anesthesiologic procedures in infants undergoing inguinal hernia repair. The present setup shows that intraoperative conventional spectral Doppler cerebral ultrasound had a success rate of 88.3% (53/60 sequences successfully recorded) while ultrafast spectral Doppler cerebral ultrasound had a success rate of 68.3% (41/60). The last technique is in its early stages of development and these first results show that it has potential for further improvements and evaluation for monitoring. In awake infants, the success rate was still too low for monitoring purposes in clinical practice. As expected, the cerebral blood flow velocity and non-invasive blood pressure during anesthesia (T2-T4) were both lower than after recovery (T5) and showed a reversed pattern with regional oxygen saturation which showed an increase at T2-T4. The clinical relevance of these changes in cerebral blood flow velocity deserve further studies. This study provides unique information of the cerebral perfusion in infants undergoing general anesthesia in both a single pial artery with conventional spectral Doppler as well as the pial cortical vessels in the whole plane with ultrafast Doppler cerebral ultrasound.

#### 4.1. Strength and limitations

The success rate of ultrafast Doppler measurements during anesthesia is encouraging. This technique has a learning curve, indicating that the success rate could potentially increase with a larger sample size. Expertise is required to properly position and hold the probe steady during the measurement process. The high failure rate pre- and postoperatively was due to the high number of motion artefacts in the awake infants which made offline analysis impossible. This imaging technique therefore does not seem suitable for pre- and postoperative measurements without substantial improvements. The measurement setup did not cause any inconvenience for the anesthesiologists nor the operating room staff, despite the busy environment of the operating room. The ultrasound device was small enough to not interfere with the workspaces of the anesthesiologists and surgeons, also due to the mobility of the device and probe.

Due to the challenging organization and technical factors, a relatively small number of patients was included in this study. The ultrafast processing pipeline is quite sensitive to motion artefacts and in 49% the image quality was unsatisfactory. In awake infants it can be difficult to minimize motion. The use of a small probe with dedicated probe holder in a head cap might improve the feasibility of the ultrafast measurements in the perioperative setting without interfering with the surgical procedure. This would also ease relocating the same ultrasound plane. In future research, this would enable conducting more reliable measurements and gain a comprehensive understanding of the extent of fluctuations in cerebral blood flow velocities over time during surgery. An example of a wearable single-element ultrasound probe is the Neo-Doppler probe. [13] This probe measures cerebral blood flow velocity continuously in a cylindrical region below the anterior fontanelle covering several large vessels. [13] This probe however does not provide 2D information, but only a general Doppler signal per depth. The advantage of ultrafast Doppler cerebral ultrasound is that it measures the cerebral perfusion of all the pial cortical vessels in a whole plane,



(caption on next page)



**Fig. 5.** Example of using the various forms of Doppler Ultrasound in clinical practice.

Example of various forms of Doppler Ultrasound in a boy neonate operated at post menstrual age of 47 weeks with weight of 4.3 kg, born at 26 weeks gestational age with birthweight of 840 g. The graph presents the measurements before induction of anesthesia (T1), after induction of anesthesia with inhalation of sevoflurane and start of infusion of norepinephrine at mcg/kg/min (flow rate 2.6 ml/h) (T2), after caudal anesthesia with 1.2 ml/kg ropivacaine 2 mg/ml (T3), after 10 ml/kg bolus infusion of NaCl during surgery (T4) and after emergence of anesthesia at recovery room (T5).

The upper panel presents the vital parameters including systolic (mm Hg left axis, blue ▽), diastolic (blue △) and mean blood pressure (blue İ), peripheral oxygen saturation (% left axis, yellow ○), heart rate (left axis, red ○), end tidal CO<sub>2</sub> (kPa left axis, grey ○), regional cerebral oxygenation left (left axis, light orange ○) and right (left axis, dark orange ○), in relation to ultrasound parameters in lower panel including conventional spectral Doppler (CSD) end diastolic velocity (EDV in m/s blue ▽), peak systolic velocity (PSV in m/s blue △) and resistivity index (RI, blue ○), and ultrafast Doppler (UFD) end diastolic velocity (EDV in m/s, purple ▽), peak systolic velocity (PSV in m/s, purple △) and resistivity index (RI, purple ○) in relation to the phase of anesthesia.

The end diastolic velocity and peak systolic velocity as measured with conventional spectral Doppler showed an increase after caudal anesthesia and start of norepinephrine infusion (T3) and a decrease after reduction of norepinephrine (T4) in accordance with the rise in blood pressure, whereas the end diastolic velocity and peak systolic velocity as measured with ultrafast spectral Doppler remained unchanged at T3; and increased at T4 and at T5. This pattern is also observed in the images (unquantified). The clinical management including initiation of norepinephrine was at the discretion of the attending physician. The actual clinical effect of norepinephrine infusion and cessation could not be determined due to the relative low flow of infusion (0.4-1 ml/h) but the blood pressure results suggests that norepinephrine was effective 10 min after start of infusion. The patient was excluded from the analyses because of the initiation of norepinephrine. This example demonstrates the potential use of conventional and ultrafast Doppler to directly observe effects of anesthesiologic interventions on cerebral blood flow velocities. (For interpretation of the references to colour in this figure legend, the reader is referred to the web version of this article.)

providing important information about places at risk for postoperative encephalopathy in a specific location. Regardless of the ultrasound window used, only a small slice of cerebral tissue is accessible. In neonates, the anterior fontanelle (mean size at 3 months: 3 cm) offers a much wider field of view compared to the temporal window. [14] This allows for extensive evaluation of intracranial structures and flow patterns. This is particularly relevant in conditions where cerebral hemodynamics are altered, as the anterior fontanelle provides broader access to vital cerebral arteries and veins. Currently, the processing of the ultrafast Doppler measurements is still time intensive and is performed offline. Another current limitation is the time consuming saving process of the measurements, which takes around 5 min. Consequently, only one ultrafast Doppler measurement per operative phase was attempted, increasing the chances of failure. Future technological developments may provide real-time ultrafast power Doppler images on the ultrasound machine, would provide with direct feedback on cerebral blood flow velocities.

#### 4.2. Cerebral blood flow velocities

A previous study of our group, which was performed in a group of patients undergoing high-risk intervention and associated large fluctuations in hemodynamics, showed that the cerebral blood flow velocities measured with conventional spectral Doppler cerebral ultrasound in patients with limited need of hemodynamic support are in accordance with blood pressure. [11] The results of the present study correspond to the results of the previous study of our group, which suggests that within normal ranges, blood pressure might be a good representative of cerebral macro- and microvascular perfusion.

A previous study demonstrated the initial findings of *in vivo* mapping of comprehensive vasculature dynamics in infants using ultrafast Doppler in awake human neonates. [10] Fourteen infants were enrolled, and ultrafast Doppler acquisitions were performed in sagittal and parasagittal planes generating resistivity maps in various locations such as the basal ganglia, thalamus, and periventricular white matter. [10] Typical resistivity values were measured from these maps. Based on the outcomes, the authors concluded that transtemporal ultrafast Doppler emerged as a viable option, providing a crucial steppingstone for the introduction of whole-brain functional imaging in pediatric populations across various clinical settings. [10]

Our results showed that ultrafast Doppler measurements exhibited a similar trend as the reference conventional spectral Doppler measurements. Ultrafast Doppler ultrasound thus has potential in the perioperative phase in a healthy population without hemodynamic support. We used an automated spectral Doppler envelope detection, which has not been previously documented in the operative phase in humans. This innovative methodology holds the potential to enhance the

visualization, analysis, and quantification of cerebral hemodynamics, differentiating our study from previous investigations.

In our study, no significant decrease in cerebral blood flow velocity was observed after the induction with sevoflurane while blood pressure also remained comparable (from 57 mmHg to 56 mmHg). A previous study showed that in children under the age of 6 months, sevoflurane caused a significant decrease of cerebral blood flow velocity in the proximal segment of the middle cerebral artery as measured with transcranial Doppler ultrasound through the temporal window as soon as the mean arterial pressure decreased by 20%. [15,16] The authors hypothesized that sevoflurane decreases cerebral blood flow velocity as a result of a decrease in blood pressure by reducing systemic vascular resistance. [15,16] However, another comparable study from a different group demonstrated that the cerebral blood flow velocity in the middle cerebral artery remains constant in healthy children at different sevoflurane minimum alveolar concentration (MAC) multiples (0.5, 1.0, 1.5 MAC). [17]

Three previous studies showed that a caudal injection of ropivacaine with 1.5 ml/kg temporarily decreases cerebral blood flow velocity in the middle cerebral artery during elective inguinal hernia repair in infants which might indicate a transient increase of the intracranial pressure. [18–20] They showed that the reduction in cerebral blood flow velocity appeared immediately after the injection and a partial reduction was still present at 5 min post-injection. [20] Also, a reduction of regional oxygen saturation was observed immediately after the end of caudal injection. [20] We observed no significant difference in both cerebral blood flow velocity measured with conventional spectral Doppler and regional oxygen saturation after the administration of caudal analgesia with 1.0 ml/kg of ropivacaine, but we observed that the cerebral blood flow velocity is significantly lower and the regional oxygen saturation is significantly higher after the combined effect of sevoflurane induction and caudal anesthesia (T3) than before these anesthesiologic procedures (T1). Given the timing of the T3 measurement and a minimum 5-min interval post-caudal injection, it's unlikely that CSF cephalad displacement during injection affected our results. The alterations in cerebral blood flow velocity could be linked to decreased blood pressure (median values: 57 to 56 and 50 to 49 mmHg). Additionally, paCO<sub>2</sub> may have a significant impact on cerebral hemodynamics. To minimize the effect of paCO<sub>2</sub>, no to only minimal opioid doses were administered throughout the anesthesia, and patients maintained spontaneous breathing during the anesthesia and measurements. The levels of EtCO<sub>2</sub>, as a reflection of paCO<sub>2</sub>, remained stable throughout the anesthesia stages (Fig. 3 and supplementary table 1) although the interpretation of EtCO<sub>2</sub> through laryngeal mask should be taken with caution. Furthermore, no correlation was found between EtCO<sub>2</sub> and cerebral blood flow velocities or blood pressure. Consequently, we posit that any notable fluctuations in paCO<sub>2</sub> are unlikely to have occurred.

The peak systolic velocity and end diastolic velocity as measured by conventional spectral Doppler were higher after emergence than intra-operatively which might be related to a higher blood pressure. Hypothetically, upon awakening the child has a higher cerebral metabolism and therefore a higher cerebral blood flow velocity. [21] The effect of emergence after anesthesia on the ultrasound parameters in infants is to our knowledge not described before.

Despite variations in peak systolic velocity, end diastolic velocity, and non-invasive blood pressure that occur during and after surgery, the resistivity index remained constant throughout the measurements. However, there was an interindividual variation, primarily attributed to the selection of different arteries in conventional spectral Doppler. The resistivity index serves as an indicator of vascular resistance and may not fluctuate during the procedure despite changes in cerebral metabolism.

Vital signs are being measured more frequently as a routine practice to mitigate the risk of cerebral damage during surgery of infants. [22] Our current and previous study showed that it is possible to measure changes in cerebral blood flow velocity caused by fluctuations in blood pressure, which could not be measured with regional oxygen saturation. [23] Velocity parameters are often used as representative of cerebral blood flow, but this might not be valid as the vessel diameter plays a significant role between blood flow and flow velocities, and the vessel diameter is regulated by the sympathetic nervous system. [24] Yet, vessel diameter is not measured with cerebral ultrasound, and hence the relationship between blood flow and flow velocities might not be linear. Previous research found a relationship between cortical cerebral blood flow velocity measured in preterm neonates in their first days of life and intraventricular hemorrhages and white matter injury. [25–27] Nevertheless, correlation between Doppler parameters and structural brain damage has not been found yet. This might be explained by the lack of frequent and continuous measurements in previous research or that the most significant parameter is not found yet. [28]

#### 4.3. Implications for clinical practice and research

Ultrafast Doppler cerebral ultrasound offers the possibility to measure cerebral blood flow velocity in every image pixel simultaneously. Multiple systems are involved to control the cerebral perfusion; cerebral autoregulation which lessens variations in brain perfusion pressure, neurovascular coupling which increases local blood flow in response to increased neuronal metabolic demand, neurogenic regulation of the cerebral blood flow with an extensive arborization of perivascular nerves, and the arterial partial pressure of oxygen and partial carbon dioxide pressure by regulating the vascular tone. [29] Ultrafast Doppler cerebral ultrasound has the potential to contribute to a better understanding of these mechanisms, with the quantification in a specific region instead of only measuring one artery at the time.

In conclusion, it was possible to evaluate cerebral blood flow velocities in the pial cortical arteries measured with conventional and ultrafast spectral Doppler cerebral ultrasound between various phases of standard anesthesiological procedures. We showed that cerebral blood flow velocities together with blood pressure decreased while regional cerebral oxygenation increased during general anesthesia. The results of ultrafast Doppler are promising, considering the technique's early stages and opportunities.

#### Prior presentations

Abstract presented at 12th European Congress for Pediatric Anesthesiology (ESPA), Lisboa, Portugal on Friday 30 September 2022.

#### Declaration of Competing Interest

The author(s) declared no potential conflicts of interest with respect to the research, authorship, and/or publication of this article.

#### Acknowledgements

Floor Smits, Jessica Barends and Carlijn Oerlemans for their collaboration in collecting data and their help in the development of the processing software of the ultrafast images.

Xavier Moors for his supervision during the data collection. Sanne Hoeks for her work on critically reviewing the statistical analyses. Hester Langeveld Benders for conceptualizing the study protocol.

Department of Anesthesiology and Department of Pediatric Surgery (Erasmus MC-Sophia Children's Hospital, Rotterdam, The Netherlands) for their collaboration and adaptability which gave us the opportunity to perform this study.

Funding by the Department of Anesthesiology and Department of Biomedical Engineering of the Erasmus Medical Centre, Rotterdam, The Netherlands. Partly funded from the project MIFFY (15293) of the OTP research program financed by the Dutch Research Council (NWO).

#### Appendix A. Supplementary data

Supplementary data to this article can be found online at <https://doi.org/10.1016/j.jclinane.2023.111312>.

#### References

- [1] McCann ME, Schouten AN, Dobija N, Munoz C, Stephenson L, Poussaint TY, et al. Infantile postoperative encephalopathy: perioperative factors as a cause for concern. *Pediatrics*. 2014;133:751–7. <https://doi.org/10.1542/peds.2012-0973>.
- [2] Lubián López SP, Zuazo Ojeda A, Jimenez Gómez G, Benavente Fernández I. Monitoring of blood pressure is not enough to avoid neonatal postoperative encephalopathy. *AJP Rep* 2018;8:192–4. <https://doi.org/10.1055/s-0038-1668565>.
- [3] Meyer P, Langlois C, Soëte S, Leydet J, Echenne B, Rivier F, et al. Unexpected neurological sequelae following propofol anesthesia in infants: three case reports. *Brain Dev* 2010;32:872–8. <https://doi.org/10.1016/j.braindev.2009.11.011>.
- [4] Stolwijk LJ, Keunen K, de Vries LS, Groenendaal F, van der Zee DC, van Herwaarden MYA, et al. Neonatal surgery for noncardiac congenital anomalies: neonates at risk of brain injury. *J Pediatr* 2017;182. <https://doi.org/10.1016/j.jpeds.2016.11.080>. 335–41.e1.
- [5] Walker K, Loughran-Fowlds A, Halliday R, Holland AJ, Stewart J, Sholler GF, et al. Developmental outcomes at 3 years of age following major non-cardiac and cardiac surgery in term infants: a population-based study. *J Paediatr Child Health* 2015;51:1221–5. <https://doi.org/10.1111/jpc.12943>.
- [6] McCann ME, Lee JK, Inder T. Beyond anesthesia toxicity: anesthetic considerations to lessen the risk of neonatal neurological injury. *Anesth Analg* 2019;129:1354–64. <https://doi.org/10.1213/ANE.0000000000004271>.
- [7] McCann ME, Schouten AN. Beyond survival; influences of blood pressure, cerebral perfusion and anesthesia on neurodevelopment. *Paediatr Anaesth* 2014;24:68–73. <https://doi.org/10.1111/pan.12310>.
- [8] Szabo TL. Chapter 11 - Doppler Modes. In: Szabo TL, editor. *Diagnostic ultrasound imaging: Inside out*. 2nd ed. Boston: Academic Press; 2014. p. 431–500.
- [9] Tanter M, Fink M. Ultrafast imaging in biomedical ultrasound. *IEEE Trans Ultrason Ferroelectr Freq Control* 2014;61:102–19. <https://doi.org/10.1109/TUFFC.2014.2882>.
- [10] Demene C, Pernet M, Biran V, Alison M, Fink M, Baud O, et al. Ultrafast Doppler reveals the mapping of cerebral vascular resistivity in neonates. *J Cereb Blood Flow Metab* 2014;34:1009–17. <https://doi.org/10.1038/jcbfm.2014.49>.
- [11] Costerus SA, Kortenbout AJ, Vos HJ, Govaert P, Tibboel D, Wijnen RMH, et al. Feasibility of Doppler ultrasound for cortical cerebral blood flow velocity monitoring during major non-cardiac surgery of newborns. *Front Pediatr* 2021;9:656806. <https://doi.org/10.3389/fped.2021.656806>.
- [12] Kortenbout AJ. Automatic high frame rate spectral envelope detection to calculate parameter maps of neonatal brain perfusion. In: *IEEE Int Ultrasonics Symposium IUS2022*; 2022.
- [13] Vik SD, Torp H, Follestad T, Støen R, Nyrnes SA. NeoDoppler: new ultrasound technology for continuous cerebral circulation monitoring in neonates. *Pediatr Res* 2020;87:95–103. <https://doi.org/10.1038/s41390-019-0535-0>.
- [14] Popich GA, Smith DW. Fontanels: range of normal size. *J Pediatr* 1972;80:749–52. [https://doi.org/10.1016/s0022-3476\(72\)80125-2](https://doi.org/10.1016/s0022-3476(72)80125-2).
- [15] Ebert TJ. Cardiovascular and autonomic effects of sevoflurane. *Acta Anaesthesiol Belg* 1996;47:15–21.
- [16] Rhondali O, Mahr A, Simonin-Lansiaux S, De Queiroz M, Rhzioual-Berrada K, Combet S, et al. Impact of sevoflurane anesthesia on cerebral blood flow in children younger than 2 years. *Paediatr Anaesth* 2013;23:946–51. <https://doi.org/10.1111/pan.12166>.
- [17] Fairgrieve R, Rowney DA, Karsli C, Bissonnette B. The effect of sevoflurane on cerebral blood flow velocity in children. *Acta Anaesthesiol Scand* 2003;47:1226–30. <https://doi.org/10.1046/j.1399-6576.2003.00248.x>.
- [18] Lee B, Koo BN, Choi YS, Kil HK, Kim MS, Lee JH. Effect of caudal block using different volumes of local anaesthetic on optic nerve sheath diameter in children: a

- prospective, randomized trial. *Br J Anaesth* 2017;118:781–7. <https://doi.org/10.1093/bja/aex078>.
- [19] Castillo P, Lundblad M, Forestier J, Eksborg S, Lönnqvist PA. Cerebral blood flow alterations associated with high volume caudal block in infants. *Br J Anaesth* 2020; 125:1064–9. <https://doi.org/10.1093/bja/aex078>.
- [20] Lundblad M, Forestier J, Marhofer D, Eksborg S, Winberg P, Lönnqvist PA. Reduction of cerebral mean blood flow velocity and oxygenation after high-volume (1.5 ml kg<sup>-1</sup>) caudal block in infants. *Br J Anaesth* 2014;113:688–94. <https://doi.org/10.1093/bja/aeu161>.
- [21] McHoney M, Eaton S, Pierro A. Metabolic response to surgery in infants and children. *Eur J Pediatr Surg* 2009;19:275–85. <https://doi.org/10.1055/s-0029-1241192>.
- [22] de Graaff JC. Intraoperative blood pressure levels in young and anaesthetised children: are we getting any closer to the truth? *Curr Opin Anaesthesiol* 2018;31: 313–9. <https://doi.org/10.1097/ACO.0000000000000594>.
- [23] Berg RM, Plovsing RR. Near-infrared spectroscopy versus transcranial Doppler ultrasound for assessing dynamic cerebral autoregulation by transfer function analysis in sepsis. *Scand J Clin Lab Invest* 2016;76:88–91. <https://doi.org/10.3109/00365513.2015.1091495>.
- [24] Bruno RM, Ghiadoni L, Seravalle G, Dell’Oro R, Taddei S, Grassi G. Sympathetic regulation of vascular function in health and disease. *Front Physiol* 2012;3:1–15. <https://doi.org/10.3389/fphys.2012.00284>.
- [25] Meek JH, Tysczuk L, Elwell CE, Wyatt JS. Low cerebral blood flow is a risk factor for severe intraventricular haemorrhage. In: *Archives of Disease in Childhood - Fetal and Neonatal Edition*. 81; 1999. <https://doi.org/10.1136/fn.81.1.f15>. F15-F8.
- [26] Jm Perlman, McMenamin JB, Volpe JJ. Fluctuating cerebral blood-flow velocity in respiratory-distress syndrome. Relation to the development of intraventricular hemorrhage. *N Engl J Med* 1983;309:204–13. <https://doi.org/10.1056/NEJM198307283090402>.
- [27] Jm Perlman, Goodman S, Kreusser KL, Volpe JJ. Reduction in intraventricular hemorrhage by elimination of fluctuating cerebral blood-flow velocity in preterm infants with respiratory distress syndrome. *N Engl J Med* 1985;312:1353–7. <https://doi.org/10.1056/NEJM198505233122104>.
- [28] Tysczuk L, Meek J, Elwell C, Wyatt JS. Cerebral blood flow is independent of mean arterial blood pressure in preterm infants undergoing intensive care. *Pediatrics*. 1998;102:337–41. <https://doi.org/10.1542/peds.102.2.337>.
- [29] Peterson EC, Wang Z, Britz G. Regulation of cerebral blood flow. *Int J Vasc Med* 2011;2011:823525. <https://doi.org/10.1155/2011/823525>.