



A Suture-specific Photo Score for Metopic Synostosis

Linda Gaillard, MD, and ERN CRANIO–Craniosynostosis Workgroup

Abstract: Head shape assessments in children with metopic synostosis are a relevant outcome measure in addition to functional measures, such as neurocognitive outcomes, behavioral outcomes, and visual functioning outcomes. However, consensus on head shape assessments in children with metopic synostosis is lacking. The aim of this study is to develop a reproducible and reliable suture-specific photo score that can be used for cross-center comparison of phenotypical severity of metopic synostosis and evaluation of esthetic outcome of treatment later in childhood. We conducted a retrospective study among nonsyndromic metopic synostosis patients aged <18 years. Preoperative and postoperative photosets of patients with metopic synostosis from 6 expert centers were included. The photo score was discussed in the group of expert craniofacial plastic surgeons and pediatric neurosurgeons. Interrater reliability was determined with modified weighted Fleiss' kappa and intraclass correlation coefficients. Correlation between individual photo score items with overall phenotype was assessed using Spearman correlation analyses. The metopic synostosis photo score contained the following items: "wedging of the forehead", "hypotelorism", "temporal hollowing", "biparietal widening," and an assessment of "overall phenotype". Items were scored on a 4-point ordinal scale ranging from normal to severe. We found moderate interrater reliability for all items, but substantial agreement for the summed scores. Correlation

with overall phenotype was lowest for biparietal widening. To conclude, although agreement on individual photo score items was suboptimal, the agreement on the summed score was substantial, which indicates there is consensus on the overall severity of the metopic synostosis phenotype.

Key Words: Esthetic, metopic synostosis, phenotype, photo score, trigonocephaly

(*J Craniofac Surg* 2024;35: 75–79)

The phenotypical severity of metopic synostosis varies considerably depending on the timing of metopic suture fusion during fetal development.¹ The phenotype can range from a clinically insignificant metopic ridge to a true trigonocephaly phenotype with a wedge-shaped forehead, hypotelorism, temporal hollowing, and an overall triangular skull shape. To assess the severity of metopic synostosis, several measures have been described previously. These include anthropometric measures on CT scans such as the interfrontal angle (angle between bilateral pterion to nasion lines), the amount of frontal stenosis (interparietal distance / intercoronal distance), and the recently developed quantitative shape severity score, as well as measures acquired through 3D imaging systems.^{2–9} However, CT scans require radiation exposure and are consequently rarely repeated postoperatively, and consensus on what constitutes the best anthropometric measure is lacking.⁸ 3D imaging systems are not easily accessible for all health care providers as they require expensive equipment and expertise in analyses of data obtained. A simple, reliable 2D photo score would therefore be valuable to assess the phenotypical severity of the metopic synostosis. Previous studies that have compared esthetic outcome or phenotypical severity often used the Whitaker score,¹⁰ which is a general score for assessing esthetic outcomes after craniosynostosis surgery.^{11–13} The main disadvantage of this score is that it only assesses general esthetic outcomes and the need for reintervention after surgery rather than the severity of phenotypical characteristics.

Adequately classifying the severity of the trigonocephaly phenotype is especially important given the ongoing debate regarding the need for surgical intervention. Historically, the standard of care has been cranial vault surgery with the aim of reducing potential mechanical brain restriction and correcting the skull contours. However, the functional indication for surgical intervention in metopic synostosis is unclear, and to what extent surgical intervention improves (long-term) esthetic outcomes compared with conservative management is unknown. To assess the severity of characteristic trigonocephaly features in metopic synostosis, we aimed to develop a suture-specific photo score and to assess its reliability in an expert group of craniofacial plastic surgeons and neurosurgeons. This photo score can potentially contribute to accurately comparing phenotypical severity at presentation and esthetic outcome from different treatment strategies across expert centers in the future.

From the Department of Plastic and Reconstructive and Hand Surgery, Dutch Craniofacial Centre, Erasmus MC, Sophia Children's Hospital, University Medical Centre Rotterdam, Rotterdam, the Netherlands.

Received April 30, 2023.

Accepted for publication August 20, 2023.

Address correspondence and reprint requests to Linda Gaillard, Department of Plastic and Reconstructive Surgery and Hand Surgery, Erasmus MC, University Medical Center, Room EE-1589, Dr. Molewaterplein 40, 3015GD, Rotterdam, P.O. Box 2040, 3000 CA Rotterdam, The Netherlands; E-mail: L.Gaillard@erasmusmc.nl, l.gaillard@erasmusmc.nl

This work is generated within the European Reference Network for rare and/or complex craniofacial anomalies and ear, nose, and throat (ENT) disorders (ERN CRANIO). ERN CRANIO is co-funded by the European Union.

The authors report no conflicts of interest.

Supplemental Digital Content is available for this article. Direct URL citations are provided in the HTML and PDF versions of this article on the journal's website, www.jcraniofacialsurgery.com.

This is an open access article distributed under the Creative Commons Attribution License 4.0 (CCBY), which permits unrestricted use, distribution, and reproduction in any medium, provided the original work is properly cited.

Copyright © 2023 The Author(s). Published by Wolters Kluwer Health, Inc. on behalf of Mutaz B. Habal, MD.

ISSN: 1049-2275

DOI: 10.1097/SCS.00000000000009773

METHODS

Study Design and Subjects

We conducted a retrospective study among nonsyndromic metopic synostosis patients. Six expert centers supplied photographs for photo score assessments: Birmingham Children’s Hospital (Birmingham, UK), Charité-Universitätsmedizin Berlin (Berlin, Germany), Erasmus Medical Center, Sophia Children’s Hospital (Rotterdam, The Netherlands), Fondazione IRCCS Istituto Neurologico Carlo Besta (Milan, Italy), Hôpital Necker-Enfants-Malades (Paris, France), Hospital 12 de Octubre (Madrid, Spain). Photosets of patients < 18 years, available in 4 directions (anterior-posterior view, both lateral views, bird’s eye view) were included. We included preoperative and post-operative photosets that were mixed randomly for scoring. A panel of expert craniofacial plastic surgeons and neurosurgeons who are members of the craniosynostosis workgroup of the European Reference Network CRANIO (ERN CRANIO) evaluated photosets independently. ERN CRANIO is a network of health care providers across the European Union and European Economic Area, focused on complex craniofacial anomalies, including craniosynostosis, and/or rare ear, nose, and throat disorders.¹⁴ To qualify as a member of the ERN CRANIO–craniosynostosis workgroup, a minimum of 20 intracranial surgeries on nonsyndromic unisutural craniosynostosis patients should be performed yearly, a multidisciplinary team is required, and national acknowledgment by the Health Authority is mandatory.

Photo Score Development and Assessments

The photo score development process was described in detail for a previous sagittal synostosis photo score in Gaillard et al 2023 (submitted). In brief, 2 meetings with experts were organized to discuss which items should be included in the photo score and to do a pilot study. After obtaining consensus on the photo score, a panel of expert craniofacial plastic surgeons and neurosurgeons used the developed photo score to evaluate new photosets independently to assess the reliability of the photo score. All participants received identical instructions and were shown example photos of patients with features considered “severe” for each item. All items in the photo score were scored according to the same 4-point scale, which ranged from normal to severe. Participants scored 2 initial practice photosets, of which results were discussed immediately to clarify any remaining uncertainties regarding the score before rating 42 study photosets. Participants were shown photosets through Microsoft Teams software, and photosets were scored using Mentimeter.

Statistical Analysis

Statistical analyses were performed using R version 4.1.1 (2021-08-10). The panel’s interrater reliability was assessed using the wlin.conc() function in the package ‘raters’ in R. We obtained a modified version of Fleiss’ kappa with linear weights and calculated 95% confidence intervals (CI) using the percentile bootstrap method with 10, 000 iterations.¹⁵ Second, pairwise weighted kappa analyses were performed for each combination of surgeons with the kappa2() function with equal weights of the package ‘irr’. In addition, the sum score of individual photo score items was calculated. The intraclass correlation coefficient (ICC) estimates for consistency and agreement for the summed scores were obtained based on single rating, 2-way random effects models. Kappa and ICC values were interpreted according to the Landis and Koch scale.¹⁶ Finally, we investigated the

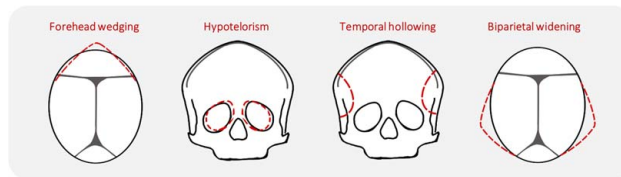


FIGURE 1. Schematic figure with characteristic trigonocephaly features indicated in the red dotted lines.

relation between each individual photo score item with “overall phenotype severity” assessments using scatter plots.

In a secondary analysis, we assessed if removing the individual item with the lowest correlation with overall phenotype affected the interrater reliability of the summed score by calculating the ICC measures as described above without the low correlation item. In addition, we obtained the interrater reliability within a single center, if multiple surgeons from a single center participated in the study to compare single-center results to our full panel of plastic surgeons and neurosurgeons using the wlin.conc() function in the package “raters” in R. Finally, the interrater reliability for high-quality photosets was calculated. Photosets were considered high quality when they met the following criteria: no hair obstructing view of craniofacial features, optimal angle of photo, and optimal lighting.

RESULTS

Photo Score Development

We obtained consensus on a photo score that contains 4 characteristic trigonocephaly features as well as an assessment of the severity of the ‘Overall phenotype’ (Supplemental Table 1, Supplemental Digital Content 1, <http://links.lww.com/SCS/F551>, Fig. 1). We used an ordinal 4-point scale with “0” indicating a normal feature, “1” indicating a mild deformity, “2” indicating moderate deformity, and “3” indicating a severe deformity. How often each category was scored is shown in Fig. 2.

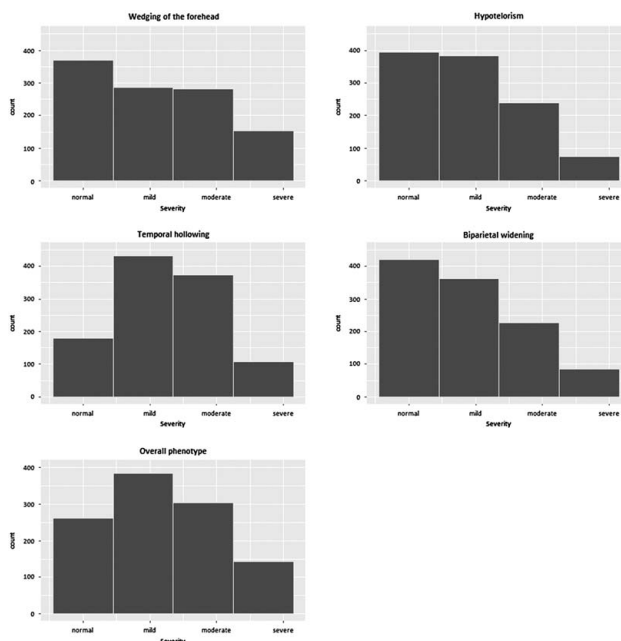


FIGURE 2. Total scores for each category.

Photo Score Assessments Interrater Reliability

Forty-two photosets were scored by 26 surgeons. Interrater reliability was moderate for all items and was highest for the “wedging of the forehead” and “overall phenotype” (Supplemental Table 2, Supplemental Digital Content 1, <http://links.lww.com/SCS/F551>). Interrater reliability was higher when using the summed score with an agreement ICC estimate of 0.67 (CI 0.57, 0.77), indicating substantial agreement. Pairwise kappa analyses for each set of raters indicate substantial variation with agreement strength ranging from poor agreement to almost perfect agreement. The variation in interrater reliability was especially large for “hypotelorism” (κ min = -0.11, κ max = 0.70), “temporal hollowing” (κ min = 0.01, κ max = 0.72), and “biparietal widening” (κ min = 0.04, κ max = 0.78) (Fig. 3). Interrater reliability for 10 high-quality photographs was similar to interrater reliability of all photosets (Supplemental Table 3, Supplemental Digital Content 1, <http://links.lww.com/SCS/F551>).

Relation Between Subitems and Overall Phenotype Assessment

In line with the variation in pairwise kappa analyses, the correlation between individual items and the “overall phenotype” assessments also varied considerably between raters. “Biparietal widening” had the lowest correlation with overall phenotype.

This is shown in Fig. 4, which shows scatter plots indicating the relation between individual items and the overall severity. The figure indicates a strong relation between “Wedging of the forehead” and “Overall phenotype,” and the weakest relation between “Biparietal widening” and “Overall phenotype”. The interrater reliability for the summed score without the “Biparietal widening” item was substantial [ICC agreement: 0.68 (95% CI 0.58, 0.78), ICC consistency 0.74 (95% CI 0.65, 0.82)].

Single Center Interrater Reliability

In 5 centers, multiple surgeons from the same center scored the photo sets independently (in 1 center 4 surgeons participated and in 4 centers 2 surgeons participated). Interrater reliability was similar or higher to the total group interrater reliability for most items in 4 centers. In these centers, the minimum agreement type ICC for the summed score was 0.69 (95% CI: 0.49, 0.82) and maximum agreement type ICC was 0.81 (95% CI 0.67, 0.89). For the fifth center, the agreement type ICC of the summed score was lower [0.29 (95% CI: -0.07, 0.59)] than the total group ICC. Modified Fleiss’ kappa statistics for individual items showed similar variation to pairwise kappa analyses and ranged from poor agreement to substantial agreement.

DISCUSSION

We aimed to develop a photo score that can be used by experts to assess the severity of characteristic trigonocephaly features in metopic synostosis patients. Our study indicates disagreement between experts on the interpretation of specific photo score items despite consensus on the photo score itself.

Several studies have investigated photo scores to assess the esthetic outcome of metopic synostosis surgery.^{11–13,17–21} However, many scores are not applicable preoperatively as they assess the effect of surgical intervention on esthetic outcome and the need for reintervention or only focus on specific features of the trigonocephaly phenotype.^{11,12,18,13,20,22} In addition, 2 studies investigated if parents were satisfied with results from either conservative management or surgical intervention.^{19,21} To our knowledge, only 1 previous study used a 2D photo score that assesses true phenotypical severity of the metopic synostosis phenotype.¹⁷ A junior plastic surgeon and medical student scored photographs on the shape of the forehead, hypotelorism,

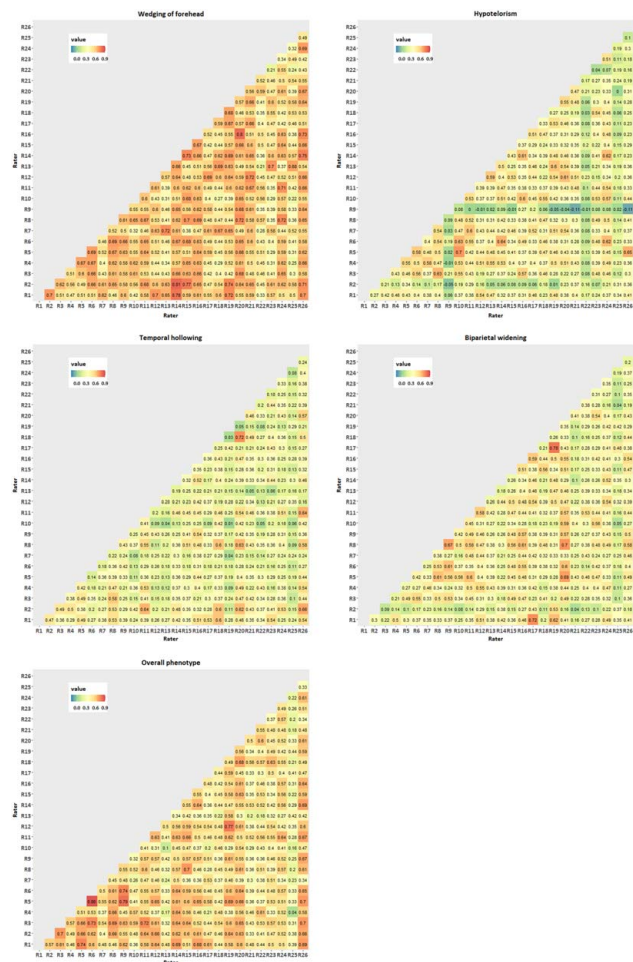


FIGURE 3. Pairwise kappa.

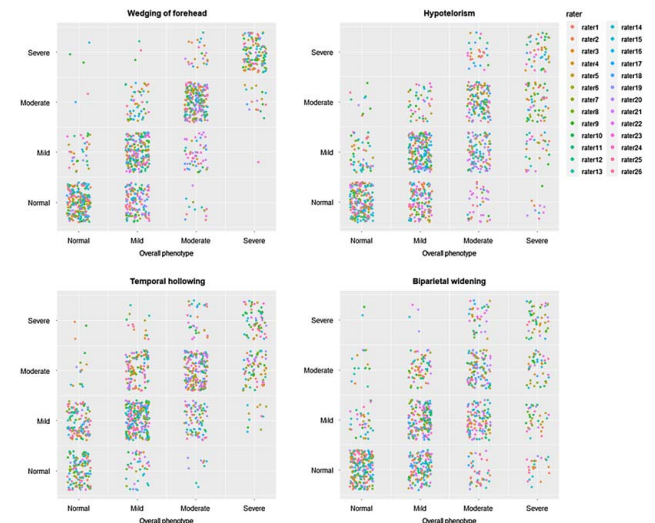


FIGURE 4. Correlation between individual photo score items and overall phenotype.

Downloaded from <http://journals.lww.com/craniofacialsurgery> by BNDMfsePHKav1ZEoum1tQIN4a+kJLIEZbSI Ho4XMH0hCjwvCX1AWmVQpII0RHd33DD0dFy7TTSFAQ3AVC4/OAVyDDd8KKGKAV0Vmy+78= on 01/12/2024

and temporal depression on a 3-point scale. The authors report substantial to almost perfect interrater reliability on the Landis and Koch scale for each item (κ statistic ranging from 0.65 (temporal depression) to 0.89 (shape of forehead). Similarly, we found substantial agreement for the summed score. However, both the total group interrater reliability, as well as the interrater reliability of centers in which multiple surgeons participated in our study, is lower for similar individual photo score items. The difference in interrater reliability, even in a single center setting, may be explained by different rating scales. In the current study, photographs were scored on a 4-point scale. Although a 4–4-point scale is more informative to communicate the direction of the severity of the phenotype, the elimination of the neutral middle choice likely negatively impacts the interrater reliability measures. Although some photosets were of sub-optimal quality, the moderate interrater reliability reflects a true difference in the interpretation of the photo score items by experts, as a subanalysis of high-quality photos did not improve interrater reliability. These findings highlight the subjective nature of esthetic assessments, even if assessments are made by expert raters. Although a subanalysis of high-quality photosets did not improve interrater reliability, consistent, uniform photographs may facilitate easier and more uniform scoring, and standardized photograph-taking should ideally be implemented across participating centers. In addition, an educational program for participants could be implemented using data and examples from our current study.

Although all individual items had moderate interrater reliability. “Biparietal widening” correlated least with the overall phenotype. Therefore, we recommend the final score includes the following individual items: “Wedging of the forehead”, “Hypotelorism” and “Temporal hollowing”. Biparietal widening likely correlated less with overall phenotype as it can be difficult to assess on photographs of patients with hair.

To accurately compare different treatment strategies between expert centers, a consistent rating and analysis of both pre-operative phenotypical severity and postoperative esthetic outcome is needed as the severity of the phenotype at presentation likely predicts esthetic outcome after treatment. Recent studies have shown the potential of 3D photogrammetry as a radiation-free alternative to CT in assessing the severity of metopic synostosis and for morphometric follow-up.^{3,23–26} 3D shape analyses will likely provide more information on phenotypical severity and the effect of treatment on head shape, especially if 3D photogrammetry can be analyzed objectively and consistently through the use of artificial intelligence. Combining objective 3D photogrammetry shape analyses with the current photo score would allow us to validate and improve the 2D photo score further. In contrast to 3D photogrammetry, which can be difficult to access due to the required expensive equipment and expertise in analysis, 2D photographs are highly accessible to all clinicians. As the 2D photographs are easily obtained by clinicians, the 2D photo score could be widely used throughout expert centers and allow for benchmarking of esthetic results after different treatment strategies. Combined with studies on neurocognitive outcomes, behavioral outcomes, visual functioning, as well as the quality of life of patients and their parents, a widely-used reliable photo score will contribute to developing an optimized treatment protocol tailored to the severity of metopic synostosis if necessary.

CONCLUSION

Agreement on the overall phenotype determined by the summed score of individual photo score items was substantial despite moderate agreement on individual photo score items, indicating

that despite disagreement between experts on the interpretation of individual photo score items, experts agree on the overall phenotypical severity of metopic synostosis.

ERN CRANIO–CRANIOSYNOSTOSIS WORKGROUP

I.M.J. Mathijssen, Coordinator ERN CRANIO: Department of Plastic and Reconstructive Surgery and Hand Surgery, Erasmus MC-Sophia Children’s Hospital, University Medical Center, Rotterdam, The Netherlands. S. Versnel: Department of Plastic and Reconstructive Surgery and Hand Surgery, Erasmus MC-Sophia Children’s Hospital, University Medical Center, Rotterdam, The Netherlands. M. Pleumeekers: Department of Plastic and Reconstructive Surgery and Hand Surgery, Erasmus MC-Sophia Children’s Hospital, University Medical Center, Rotterdam, The Netherlands. M.L.C. Van Veelen: Department of Neurosurgery, Erasmus MC-Sophia Children’s Hospital, University Medical Center, Rotterdam, The Netherlands. H. Delye: Department of Neurosurgery, Radboudumc, Nijmegen, The Netherlands. S. Haber: Unité Fonctionnelle de Chirurgie Craniofaciale, Service de Neurochirurgie, Hôpital Necker-Enfants-Malades, Assistance Publique, Hôpitaux de Paris; Centre de Référence Craniosténoses et Malformations Craniofaciales CRANIOST, Filière Maladies Rares TeteCou; Université de Paris, Paris, France. M. Evans: Department of Craniofacial Surgery, Birmingham Children’s Hospital, Birmingham, UK. C. Parks: Department of Pediatric Neurosurgery/Craniofacial Surgery, Alder Hey Children’s NHS Foundation Trust, Liverpool, UK. L. Kölby: Department of Plastic Surgery, Institute for Clinical Sciences, Sahlgrenska Academy, Gothenburg University, Sahlgrenska University Hospital, Gothenburg, Sweden. D. Nowinski: Department of Surgical Sciences, Plastic Surgery, Uppsala University, Uppsala, Sweden. L. Valentini: Department of Neurosurgery, Fondazione IRCCS Istituto Neurologico “Carlo Besta”, Milan, Italy. G. Tamburrini: Department of Pediatric Neurosurgery, Institute of Neurosurgery, Fondazione Policlinico Gemelli, IRCCS, Università Cattolica del Sacro Cuore, Rome, Italy. U.W. Thomale: Department of Pediatric Neurosurgery, Charité-Universitätsmedizin Berlin, Freie Universität Berlin, Humboldt-Universität Zu Berlin, Berlin Institute of Health, Berlin, Germany. M. Schulz: Department of Pediatric Neurosurgery, Charité-Universitätsmedizin Berlin, Freie Universität Berlin, Humboldt-Universität Zu Berlin, Berlin Institute of Health, Berlin, Germany. P. Vuola: Department of Plastic Surgery, Cleft and Craniofacial Center Husuke, Helsinki University Hospital, Helsinki, Finland. C.C. Faria: Department of Neurosurgery, Centro Hospitalar Universitário Lisboa Norte (CHULN), Faculdade de Medicina, Universidade de Lisboa, Lisboa, Portugal. F. Di Rocco: Department of Pediatric Neurosurgery, French Referral Center for Craniosynostosis Hôpital Femme Mère-Enfant Hospices Civils de Lyon University of Lyon, Lyon, France. M. Vinchon: Department of Pediatric Neurosurgery, French Referral Center for Craniosynostosis Hôpital Femme Mère-Enfant Hospices Civils de Lyon University of Lyon, Lyon, France. J. Hinojosa Mena-Bernal: Unit for Craniofacial Surgery, Paediatric Neurosurgical Department, Hospital de Sant Joan de Déu, Barcelona, Spain. D. Larysz: Department of Head and Neck Surgery for Children and Adolescents, University of Warmia and Mazury in Olsztyn; Prof. St. Popowski Regional Specialized Children’s Hospital, Olsztyn, Poland. P. Larysz: Department of Head and Neck Surgery for Children and Adolescents, University of Warmia and Mazury in

Olsztyn; Prof. St. Popowski Regional Specialized Children's Hospital, Olsztyn, Poland. B. Spacca: Department of Pediatric Neurosurgery, Meyer Children's Hospital IRCCS, Florence, Italy. B.J. Due-Tønnessen: The Norwegian National Unit for Craniofacial Surgery, Oslo University Hospital, NO 0424 Oslo Norway. P.M. Munarriz: Department of Neurosurgery, Hospital Universitario 12 de Octubre, Madrid, Spain. K. Rosas: Department of Neurosurgery, Vall d'Hebron, Barcelona, Spain. D.F.L. Bermeo: Department of Neurosurgery, Vall d'Hebron, Barcelona, Spain

REFERENCES

- Mathijssen IM, van Splunder J, Vermeij-Keers C, et al. Tracing craniosynostosis to its developmental stage through bone center displacement. *J Craniofac Genet Dev Biol* 1999;19:57–63
- Kellogg R, Allori AC, Rogers GF, et al. Interfrontal angle for characterization of trigonocephaly: part 1: development and validation of a tool for diagnosis of metopic synostosis. *J Craniofac Surg* 2012;23:799–804
- Linden OE, Baratta VM, Gonzalez JA, et al. Surgical correction of metopic craniosynostosis: a 3-D photogrammetric analysis of cranial vault outcomes. *Cleft Palate Craniofac J* 2019;56:231–235
- Bottero L, Lajeunie E, Arnaud E, et al. Functional outcome after surgery for trigonocephaly. *Plast Reconstr Surg* 1998;102:952–958; discussion 9-60
- Posnick JC, Lin KY, Chen P, et al. Metopic synostosis: quantitative assessment of presenting deformity and surgical results based on CT scans. *Plast Reconstr Surg* 1994;93:16–24
- Wang JY, Dorafshar AH, Liu A, et al. The metopic index: an anthropometric index for the quantitative assessment of trigonocephaly from metopic synostosis. *J Neurosurg Pediatr* 2016;18:275–280
- Svalina A, Vuollo V, Serlo W, et al. Craniofacial characteristics and cosmetic satisfaction of patients with sagittal and metopic synostosis: a case-control study using 3D photogrammetric imaging. *Childs Nerv Syst* 2022;38:781–788
- Sisti A, Bassiri Gharb B, Papay F, et al. Anthropometric cranial measurements in metopic craniosynostosis/trigonocephaly: Diagnostic criteria, classification of severity and indications for surgery. *J Craniofac Surg* 2022;33:161–167
- Anstadt EE, Tao W, Guo E, et al. Quantifying the severity of metopic craniosynostosis using unsupervised machine learning. *Plast Reconstr Surg* 2023;151:396–403
- Whitaker LA, Bartlett SP, Schut L, et al. Craniosynostosis: an analysis of the timing, treatment, and complications in 164 consecutive patients. *Plast Reconstr Surg* 1987;80:195–212
- Badiee RK, Popowitz E, Mark IT, et al. Superior long-term appearance of strip craniectomy compared with cranial vault reconstruction in metopic craniosynostosis. *Plast Reconstr Surg Glob Open* 2022;10:e4097
- Aryan HE, Jandial R, Ozgur BM, et al. Surgical correction of metopic synostosis. *Childs Nerv Syst* 2005;21:392–398
- Kampf S, Micko A, Schwartz E, et al. Clinical and aesthetic outcome analysis of a case series of trigonocephaly patients after early fronto-orbital advancement. *Int J Oral Maxillofac Surg* 2020;49:1115–1121
- Accessed 10-12-2021, 2021, at <https://ern-cranio.eu/>
- Marasini D, Quatto P, Ripamonti E. Assessing the inter-rater agreement for ordinal data through weighted indexes. *Stat Methods Med Res* 2016;25:2611–2633
- Landis JR, Koch GG. The measurement of observer agreement for categorical data. *Biometrics* 1977;33:159–174
- Hilling DE, Mathijssen IM, Vaandrager JM. Aesthetic results of fronto-orbital correction in trigonocephaly. *J Craniofac Surg* 2006;17:1167–1174
- Julie CP, Pierre-Aurelien B, Mathieu D, et al. Is computer-assisted design and manufacturing technology useful in the surgical management of trigonocephaly? *J Craniomaxillofac Surg* 2021;49:993–999
- Kunz M, Lehner M, Heger A, et al. Neurodevelopmental and esthetic results in children after surgical correction of metopic suture synostosis: a single institutional experience. *Childs Nerv Syst* 2014;30:1075–1082
- Metzler P, Zemann W, Jacobsen C, et al. Assessing aesthetic outcomes after trigonocephaly correction. *Oral Maxillofac Surg* 2014;18:181–186
- Kelleher MO, Murray DJ, McGillivray A, et al. Non-syndromic trigonocephaly: surgical decision making and long-term cosmetic results. *Childs Nerv Syst* 2007;23:1285–1289
- van der Meulen JJ, Willemsen J, van der Vlugt J, et al. On the origin of bitemporal hollowing. *J Craniofac Surg* 2009;20:752–756
- Bruce MK, Tao W, Beiriger J, et al. 3D photography to quantify the severity of metopic craniosynostosis. *Cleft Palate Craniofac J* 2023;60:971–979
- Kuehle R, Ewerbeck N, Ruckschloss T, et al. Photogrammetric evaluation of corrective surgery for trigonocephaly. *Int J Oral Maxillofac Surg* 2022;51:70–77
- de Jong G, Tolhuisen M, Meulstee J, et al. Radiation-free 3D head shape and volume evaluation after endoscopically assisted strip craniectomy followed by helmet therapy for trigonocephaly. *J Craniomaxillofac Surg* 2017;45:661–671
- Martini M, Schulz M, Rohrig A, et al. A 3D morphometric follow-up analysis after frontoorbital advancement in non-syndromic craniosynostosis. *J Craniomaxillofac Surg* 2015;43:1428–1437