

Possibilities and limitations of computed tomography in diagnosis of thoracic organs

Šerif Bešlić, F. Dalagija, A. Lovrinčević, M. Ibralić, Z. Merhemić

University Medical Center, Institute of Radiology and Oncology, Sarajevo, Bosnia and Hercegovina

During a period of 6 years and based on own material and experience with 1012 examined patients, the authors have presented the contribution of computed tomography (CT). The examinations were performed on Somatom SF "Siemens" unit. According to the coded CT diagnoses stored at computer in the Department of Informatics, CT showed the important contribution in the diagnosis of fluid, solid, cystic and fat formations in the chest. A considerable part of the findings, about 16.5% related to the mediastinal and hilar adenopathies. The diagnostic role of CT in the analysis of vascular mediastinal structures is interesting.

Key words: thoracic radiography; tomography; x-ray computed

Introduction

CT is a new, relatively expensive diagnostic method. It changed our previous practice and algorithm of diagnostic methods and enabled improved analysis of the mediastinum, lung parenchyma, pleura and phrenico-costal sinuses. Since the end of 1978, it has been performed at our Institute. On the basis of our clinic material and data from literature, we tried to present the pathology which can be proved by this method, as well as the problems related to this diagnostics.

Material and method

Clinical material

From the end of 1986 to January 1, 1992, we investigated 1012 patients. Out of this number, the clinicians requested the examination in:

- 686 cases – CT of lungs,
- 227 cases – CT of mediastinum,
- 78 cases – CT of thorax,
- 28 cases – CT of other chest organs,
- 12 cases – CT of the heart etc.

The analysis included patients of all ages and both sexes.

Method of work

Since 1978, we have worked on the third generation Somatom SF "Siemens" scanner with 512 detectors and 2.6 and 4.8 sec. scan time, 4 and 8 mm thick slices and immediate image reconstruction. Density level is measured

Correspondence to: dr. Šerif Bešlić, Institute of Radiology and Oncology, University Medical Center, Mošć Pijade 25, 71000 Sarajevo, Bosnia and Hercegovina.

UDC: 616.2-073.756.8

according to Hounsfield: -1024 to $+1024$ HU, where water is 0. Electronic image enlargement is 2.5 times. The tube is pulsed superrotalix with graphite anode, cooled by oil. The image analysis has been performed at two levels, with the window for the analysis of mediastinum and costal pleura in one, and for the analysis of parenchyma in another. Plain images were obtained in the first series, the second after infusion of water-soluble contrast material (60 ml. i. v. in bolus and 100 ml in perfusion), for a better presentation of vascular structures.

Rarely, a reinjection of contrast material in the area of special interest was performed.

After i. v. application of contrast material fast mood scanning was performed in the following positions: decubitus, lateral decubitus and procubitus. We applied contrast material perorally (esophagus).

The thorax was investigated from the apex to the phrenicocostal sinuses (20 scans). The suspected regions required additional scans with contrast bolus.

Scanning was made after conventional radiography with possible additions.

The results were evaluated surgically, by CT-guided transthoracic biopsy, clinically and by laboratory data.

Results

Out of the total number of examined patients CT findings showed as follows:

The most of our CT diagnoses related to pleural exudations (25%), mediastinal and hilar adenopathies (16.5%), lung tumors (12.5%), thymus diseases (2.47%), esophageal neoplasms (1.97%), solitary metastases, infiltrations and echinococcal lung cysts (1.9%), fat deposits in mediastinum and retrosternal struma (1.48%) etc.

In those cases, CT made the decisive contribution. Our results are presented on Tables 1 and 2, showing that besides the mentioned pathology, CT enabled the diagnosing of cysts and pulmonary abscesses, pericardial effusions diaphragmatic hernia, pleural tumors, tracheal

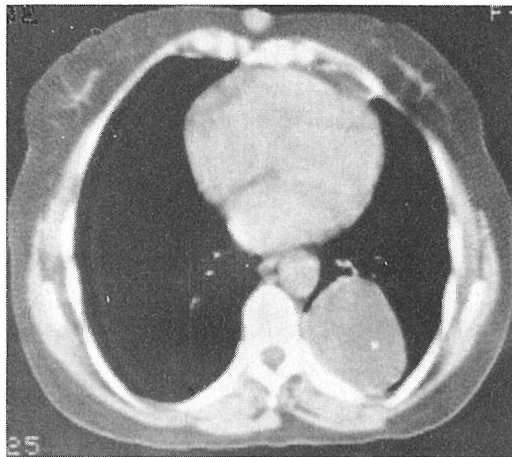


Figure 1. Echinococcus cyst left (density level $+14$ HU).

neoplasms, congenital vascular malformations and aortic aneurysms.

Discussion

The analysed material shows that CT offers special possibilities in the analysis of all thoracic structures (ribs, spine, mediastinum, lung parenchyma etc.) in the transversal plane.

It is possible to analyse bony and muscular structures of the chest (meta changes in ribs), with the advantage in the presentation of normally radiotransparent structures, as in lesions of the chondrosternal joint (abscess).¹⁻⁴

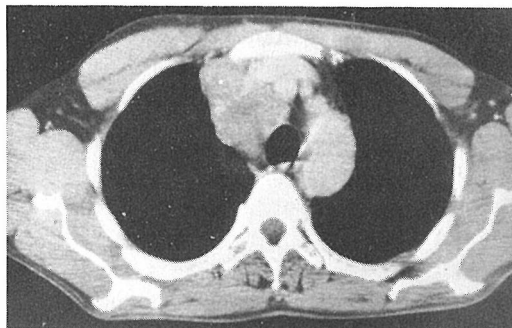


Figure 2. The solid expansive process of the superior mediastinum (density level $+53$ HU).

Transversal scans enable a good analysis of lung parenchyma with confirmed solid, cystic and liquid metastatic formations.^{1,2,5-10} (Figure 1,2).

Our material includes mediastinal and hilar adenopathies in 16.5%, solitary meta of the lungs (1-2 metastases) in 1.9%, pulmonary tumors in 12.5%, pulmonary cysts in 3.08% (out of that echinococcal cysts in 1.9%), whereas pleural effusions were diagnosed most frequently – in 25%, in the total material. This shows the CT sensitivity which depends on the type of pathologic changes.

In the changed anatomic relations in the thorax, CT improves the explanation of the conventional radiography, eliminating the superposition.^{1,2}

CT enables a precise evaluation of the expansive process border, with possible analysis of its relation with the surrounding, especially vascular structures.^{1,9,11} It enables the evaluation of loco-regional (skin metastases) and metastatic expansion of the malignant process in the mediastinum, with good presentation of the retrosternal, retrocaval (Barety lounge), subcarinal, back retrobronchial, posteroinferior mediastinal space (sign “ice hill” Felson), azygosophageal recessus and phrenicocostal sinuses.^{1,2,11-15}

Our material includes: thymus pathology in 2.47% retrosternal struma 1.48%, esophageal neoplasms 1.97%, fat collections in mediasti-

num 1.48%, diaphragmatic hernia 0.39% (Figure 3). An adequate analysis of pleura and pleural cavity is possible.^{12,16,17} Pleural effusions are found in 25%, and pleural tumors in 0.29% of the total material.

After intravenous application of contrast material, CT shows the vascular nature of tumorous formations in the mediastinum found by conventional radiography.^{18,19}

Aortic aneurysms were found in 6 cases (0.59%), and aberrant right subclavian artery in one case (Figure 4).

It is also possible to check the graft and endarterectomized vascular segment, and to analyse the pericard and heart, as well as to measure heart dimensions.^{18,20} Pericardial exudations were presented in 0.49% of the cases.

The scanner enables a supreme visualization of calcifications, invisible by the conventional radiography.^{1,18}

In some cases CT is suggestive of the tumor type histology (fat, liquid, vascular, convolute etc.).^{2,9,12-14,18} It simplifies the diagnostic procedures by making some investigations optional (angiography, tomography, endoscopy).^{1,13,14,18,19}

CT helps the surgeon in the selection of surgical approach and technique, and offers additional possibility of the therapeutic follow-

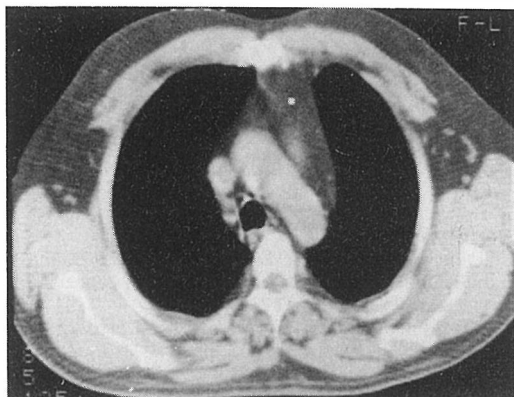


Figure 3. Fat collections of the superior mediastinum (density level – 92 HU).

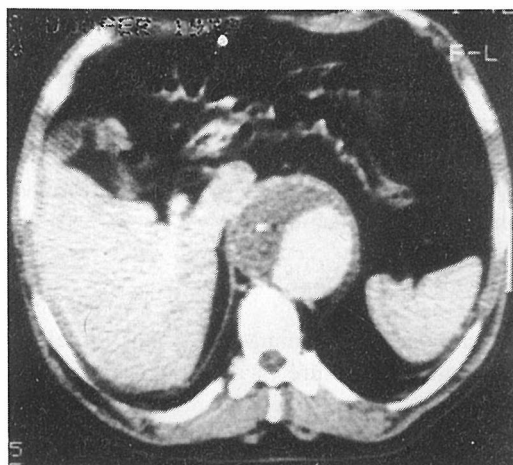


Figure 4. Thrombotic descending aortic aneurysm (after contrast medium application).

Table 1. Distribution of positive and normal CT findings

No of positive CT findings	731	72.2 %
Normal CT findings	281	27.8 %
Total	1012	100.0 %

Table 2. Distribution of positive CT findings by diagnoses

Ordinal numeral	CT diagnosis	No. of examined patients	Percentage %
1	Pleural effusions	253	25
2	Mediastinal and hilar adenopathies	167	16.5
3	Pulmonary tumors	127	12.5
4	Thymoma and thymus hyperplasia	25	2.47
5	Esophageal neoplasms	20	1.97
6	Solitary meta of the lung (1 to 2)	19	1.9
7	Pulmonary infiltration	19	1.9
8	Pulmonary echinococcosis	19	1.9
9	Fat deposits in mediastinum	15	1.48
10	Retrosternal struma	15	1.48
11	Pulmonary cysts	12	1.18
12	Pulmonary tuberculosis	11	1.08
13	Pulmonary abscess	7	0.69
14	Aortic aneurysm	6	0.59
15	Pericardial exudation	5	0.49
16	Diaphragmatic hernia	4	0.39
17	Pleural tumor	3	0.49
18	Tracheal neoplasms	1	0.098
19	Aortic dextroposition	1	0.098
20	Aberrant right subclavian artery	1	0.098
21	Cystic teratoma		0.098
Total		731	72.2

up.^{1,11} Transthoracic biopsy is also performed under the guidance of CT.^{1,2}

Diagnostic limitations

Besides various advantages, CT fails to define the pathologic nature of the lesion (benign or malignant), but enables the prediction of this possibility (lypoma, cyst, lung sequestration)^{1,6,13,14,19} CT is unable to define the structures (lymphnodes) or diffuse infiltrations of organs (liver, spleen).^{1,12}

It is difficult to differentiate tumors from the near adenopathies (skin metastasis).^{1,11} The evaluation of bacillosis, pneumoconiosis or pulmonary infarction is still performed by the conventional radiography, whereas analysis by CT has been discussed (the expensiveness of CT).¹

During its first phase prehernial lypoma can be misinterpreted for intrathoracic fat collections.¹⁴ It is impossible to differentiate between a primary and a secondary pleural tumor.^{9,16,17}

There is a possibility of false positive and false negative results (cervical lymphnode considered as parathyroid adenoma; undetected tuberculoma and metastasis under 1 cm of size, due to the lack of axial cross-section).¹

There are limitations of the technical nature (impossibility of apnea, thin patients and children, metallic prostheses, partial volume effect etc.) which can change the image quality and densitometric values.^{1,5,18}

Conclusion

CT is a non-invasive technique indispensable in the modern diagnostics. It is frequently the method of choice in the diagnosis of pulmonary and mediastinal diseases, especially in the regions traditionally inaccessible by the conventional radiography. It simplifies the diagnostic procedure (excluding the angiographies and tomographies). Without CT, diagnostics becomes more complex, which is the best defence for this technique.

CT does not replace conventional radiography or other techniques, but it is complementary.

References

1. Treut A, Guibert JL, Dilhuydy MH. Les bonnes indications de la tomodensitometrie en cancerologie. *Rev Prat* 1987; **37** (36): 2153.
2. Chalaoui J, Barral V, Simard P, Lefebvre R, Sylvestre J. Mesotheliome pleural: trois forms evolutives. *Ann Radiol* 1982; **25** (3): 191-4.
3. Frija J, Lardc D, Katz M, Vasile N, Vadrot D, Utzmann O. Le diagnostic tomodensitometrique des anomalies des arcs chez l'adulte. *J Radiol* 1982; **63** (3): 159-65.

4. Smoger BR, Rosenberg HK, Koss J, et al. La recherche de metastases pulmonaires en pediatrie: la tomodesnitometrie face aux techniques radiologiques conventionnelles. *Ann Radiol* 1982; **25** (1): 47-53.
5. Spiro S, Edwards D, Harper PG, et al. Computed tomography of the thorax in the diagnosis and management of malignant disease. *Br J Dis Ches* 1982; **76** (3): 209-22.
6. Belloir C, Larde D, Vasile N, Frija J, Ferrane J. Apport de la tomodesnitometrie dans le diagnostic et le bilan des anevrysmes de l'aorte. *J. Radiol* 1980; **61** (8-9): 521-6.
7. Frija J, Abadie E, Fisch A, et al. Le diagnostic des hematomes de la paroi du tronc par la tomodesnitometrie. *Ann Radiol* 1982; **25** (8): 528-31.
8. Kalifa G, Lalande G, Larde D, Bennet J, Kalifa C. Les fibromes desmoides chez l'enfant. *Ann Radiol* 1982; **25** (1): 25-33.
9. Collard M, Brasseur P, Sukkarieh F. Les indications et les limites de la tomodesnitometrie thoracique. *Ann Radiol* 1980; **23** (8): 629-38.
10. Tschappeler H, Vock P. Computed tomography and bone tumors in children. *Ann Radiol* 1982; **25** (1): 19-24.
11. Browu RL, Muhm JR. Computed Tomography of the Thorax Current Perspectives. *Chest* 1983; **83** (5): 806-8.
12. Tschappeler H. Computed tomography (CT) and lymphoma in children. *Ann Radiol* 1980; **23** (2): 87-91.
13. Caron-Poitreau C, Mainchain HN, Rieux D, Vialle M, Caron J. Examen Tomodesnitometrique des piliers du diaphragme. Apport a l'etude du mediastin postero-inferieur. *J Radiol* 1980; **61** (1): 1-11.
14. Caron-Poitreau C, Delumeau J, Dabouis G, Petitier H, Rieux D. Apport de la Tomodesnitometrie a l'etude des tumeurs primitives de la plevre. *Ann Radiol* 1981; **24** (4): 247-53.
15. Frija J. Principes de la tomodesnitometrie. *Rev Prat* 1987; **7**: 30.
16. Coulomb M, Terraube Ph, Vincent J, Lebas JF. Les amas graissieux du mediastin. A propos de 21 observations, dont 16 avec tomodesnitometrie. *J Radiol* 1980; **61** (1): 13-26.
17. Coulomb M, Terraube Ph, Lebas JF, Chouteau H, Geindre M. Amas graissieux intra-thoraciques symptomatiques d'une hernie diaphragmatique chez l'adulte. A propos de 11 observations avec etude tomodesnitometrique. *J Radiol* 1981; **62** (2): 85-95.
18. Coulomb M, Spinelli G, Lebas JF, Terraube Ph, Sarrazin R, Geindre M. Apport de la tomodesnitometrie au diagnostic des kystes dermoides. A propos de 5 observations. *J Radiol* 1982; **63** (12): 729-37.
19. Coulomb M, Lebas JF, Sarrazin R, Geindre M. L'apport de la tomodesnitometrie au bilan d'extension des cancers de l'oesophage. Incidences therapeutiques. A propos de 40 observations. *J Radiol* 1981; **62** (10): 475-87.