

## CASE REPORT

# A case of successful treatment with eltrombopag for severe immune-related thrombocytopenia induced by atezolizumab : Case report

Saki Harada<sup>1</sup>, Takeshi Imakura<sup>1</sup>, Seidai Sato<sup>1</sup>, Hiroshi Nokihara<sup>1</sup>, and Yasuhiko Nishioka<sup>1,2</sup>

<sup>1</sup>Department of Respiratory Medicine and Rheumatology, Graduate School of Biomedical Sciences, Tokushima University, Tokushima, Japan,

<sup>2</sup>Department of Community Medicine for Rheumatology, Graduate School of Biomedical Sciences, Tokushima University, Tokushima, Japan

**Abstract :** Immune checkpoint inhibitors (ICIs) have shown impressive anti-tumor effects against multiple types of malignancies. Among the wide variety of immune-related adverse events (irAEs), immune-related thrombocytopenia (ITP) is relatively rare but often clinically significant and life-threatening. However, the appropriate treatment for severe ITP has not been determined. We herein report an 82-year-old male patient with non-small-cell lung cancer who developed severe ITP three weeks after starting the third course of atezolizumab. The initial combination therapy with high-dose prednisolone, intravenous immunoglobulin and platelet transfusion was ineffective. However, additional treatment with eltrombopag, a thrombopoietin receptor agonist, resulted in remarkable improvement in the thrombocytopenia. *J. Med. Invest.* 70 : 516-520, August, 2023

**Keywords :** non-small-cell lung cancer, atezolizumab, immune-related thrombocytopenia, eltrombopag

## INTRODUCTION

Immune checkpoint inhibitors (ICIs) are a promising therapeutic strategy for a wide variety of malignancies. These ICIs are generally better tolerated than conventional cytotoxic chemotherapy. However, such treatment is often complicated with adverse events mimicking autoimmune and inflammatory diseases, known as immune-related adverse events (irAEs).

Hematological irAEs induced by ICIs reportedly account for approximately 3.6% to 3.7% of all irAEs (1, 2). Immune-related thrombocytopenia (ITP) is one of the most common types of hematological irAEs (1) and is potentially life-threatening. Nevertheless, little has been reported on intractable ICI-induced ITP after initial treatment fails. Only a few studies have reported that thrombopoietin receptor agonists (TPO-RAs) improve severe ITP induced by ICIs targeting programmed cell death 1 (PD-1) in patients refractory to corticosteroids or intravenous immunoglobulin (IVIG). Furthermore, no reports have explored better approaches for treating severe and refractory ITP induced by programmed cell death 1-ligand1 (PD-L1) inhibitors, such as atezolizumab.

We herein report the first case of a response to eltrombopag, a TPO-RA, in the PD-L1 inhibitor atezolizumab-induced ITP.

## CASE REPORT

An 82-year-old man was admitted to our hospital with dyspnea and purpura. He had been diagnosed with right lower lobe lung adenocarcinoma (cT2aN0M0 stage IB) three years prior to this admission. PD-L1 immunohistochemistry showed a tumor proportion score of 0%. Because surgical resection was difficult due to his poor pulmonary function, radiation monotherapy

(60 Gy/20 Fr) was performed according to the patient's wishes. One year after the radiation therapy, the cancer recurred, and a total of 13 courses of Tegafur/Gimeracil/Osteracil Potassium monotherapy were administered. Two years later, the chemotherapy regimen was changed to atezolizumab (1200 mg/body, every 3 weeks). Three weeks after starting the third course of atezolizumab, the patient presented to our clinic with dyspnea and purpura.

A physical examination revealed conjunctival pallor, diffuse purpura on the extremities and decreased breath sounds in the right lung field. His blood test showed severe thrombocytopenia (4000/ $\mu$ L) with an elevated level of C-reactive protein (CRP ; 9.46 mg/dL). Platelet-associated IgG (PA-IgG) was abnormally elevated (11673.7 ng/10<sup>7</sup>cells), and the prothrombin time-international normalized ratio (PT-INR), the activated partial thromboplastin time (APTT), fibrinogen, and D-dimer values were mildly elevated (Table 1). Collagen disease-related autoantibodies and antiplatelet antibody were negative (Table 1). (1,3)- $\beta$ -D-glucan, IgG antibodies to *Helicobacter pylori*, IgM antibodies to viral capsid antigen (anti-VCA IgM) of Epstein-Barr virus (EBV), and cytomegalovirus antigen/antibodies were also negative (Table 1). Two sets of blood cultures were negative (Table 1).

Chest computed tomography (CT) revealed an increasing tumor size of the right lower lobe, right pneumothorax, and right pleural effusion. A bone marrow aspiration showed mild hyperplasia but no malignant invasion or megakaryocytopenia (Figure 1). Because there were no signs of infection or autoimmune diseases causing secondary thrombocytopenia and no episodes of initiation of new drugs other than atezolizumab, we made a diagnosis of ITP induced by atezolizumab.

Following pulse corticosteroid therapy with 1000 mg of methylprednisolone (mPSL) for 3 days, we treated the patient with 60 mg/day (1 mg/kg) of prednisolone (PSL). In addition, we administered 24 g (400 mg/kg) of IVIG for 5 days plus platelet transfusions. However, despite these combination therapies, the platelet counts only temporarily increased slightly. Given previous reports of the efficacy of TPO-RA in ICI-induced ITP (3, 4), oral eltrombopag (12.5 mg daily) as a TPO-RA was started. Cyclosporine was also started to reduce the dose of PSL. Surprisingly,

Received for publication February 22, 2023 ; accepted August 1, 2023.

Address correspondence and reprint requests to Yasuhiko Nishioka, MD, PhD, Department of Respiratory Medicine and Rheumatology, Graduate School of Biomedical Sciences, Tokushima University, 3-18-15, Kuramoto-cho, Tokushima 770-8503, Japan. E-mail : yasuhiko@tokushima-u.ac.jp

Table 1. Laboratory findings of the present case on admission.

【Hematology】			【Biochemistry】		
WBC	3600	/μL	TP	6.8	g/dL
Neutro.	63	%	Alb	3	g/dL
Lympho.	13	%	AST	35	U/L
Mono.	23	%	ALT	35	U/L
Eosino.	1	%	T-Bil	0.8	mg/dL
Baso.	0	%	γ-GTP	17	U/L
RBC	316×10 <sup>4</sup>	/μL	LDH	213	U/L
Hb	10.2	g/dL	BUN	21	mg/dL
Plt	4000	/μL	Cre	0.85	mg/dL
			Na	133	mEq/L
			K	3.7	mEq/L
			Ca	8.4	mg/dL
			KL-6	495	U/mL
			casual blood glucose	355	mg/dL
			HbA1c (NGSP)	6.5	%
【Coagulation】			【Microbiology】		
PT-INR	2.42		(1,3)-β-D-glucan	<6.0	pg/mL
APTT	38	sec	CMV antigenemia	(-)	
Fib	637	mg/dL	EB-EA IgG (FA)	<×10	
D-dimer	3.7	μg/mL	EB-VCA IgM (FA)	<×10	
			EB-VCA IgG (FA)	×40	
			EB-EBNA IgG (FA)	×20	
			human parvovirusB19 IgM	(-)	
			HIV antigen/antibody	(-)/(-)	
			<i>Helicobacter pylori</i> IgG	6	U/mL
			blood cultures (2set)	negative	
【Immunology】					
CRP	9.46	mg/dL			
ferritin	332	ng/mL			
PAIgG	11673.7	ng/10 <sup>7</sup> cells			
antiplatelet antibody	(-)				
direct Coombs test	(1+)				
Anti-nuclear antibody	<×40				
RF	10	IU/mL			
【Tumor markers】					
CEA	2.7	ng/mL			
CYFRA	8.5	ng/mL			

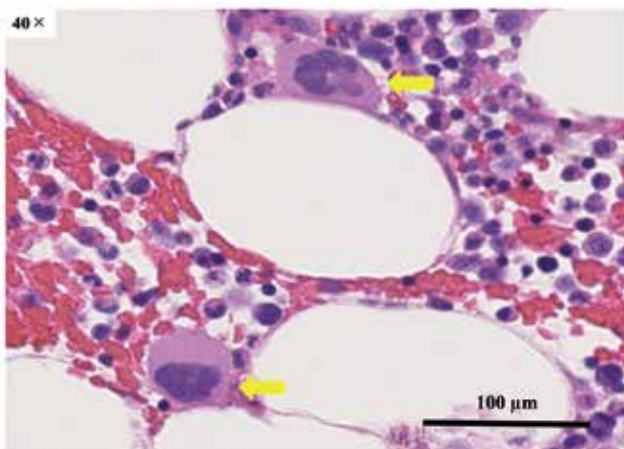


Figure 1. A bone marrow aspiration in the present case before treatment of ITP. H&E stain of a bone marrow aspiration. The bone marrow showed mild hyperplasia. The yellow arrows indicate that megakaryocytes mildly increased. There were no atypical cells suggestive of cancerous infiltration.

the platelet count started to gradually increase after the start of eltrombopag and stabilized at around 150,000/μL. Even when cyclosporine was discontinued and PSL was tapered, the platelet count did not decrease. Eltrombopag was discontinued on day 52 after its initiation, with no recurrence of the thrombocytopenia.

## DISCUSSION

With the widespread use of ICIs showing excellent efficacy against different types of cancer, various irAEs have also been reported. Delanoy *et al.* reported that hematologic irAEs occurred in 3.7% (35 of 948) and ITP in 0.9% (9 of 948) of patients treated with PD-1 or PD-L1 inhibitors (1). Michot *et al.* also reported that hematologic irAEs for all grades accounted for 3.6% (211 of 5923) of all irAEs, while grade III-IV hematologic irAEs accounted for 0.7% (41 of 5923) (2). In patients treated with atezolizumab, hematologic irAEs of all grades occurred in 4.7% (27 of 577), and those of grades III-IV occurred in 0.7% (4 of 577) (2, 5-7).

In general, patients with irAEs have been reported to respond better to ICIs than those without irAEs (8). In an analysis limited to PD-1 inhibitors in non-small-cell lung cancer (NSCLC) patients, endocrine- and skin-related irAEs were reported to

be associated with a higher overall response rate and longer progression-free survival (PFS) than in patients who did not experience endocrine- and skin-related irAEs (9). In addition, endocrine-, skin-, and gastrointestinal-related irAEs were reported to be associated with a longer overall survival (OS) (9). A previous analysis of ITP in patients treated with ICIs reported that grade 1 thrombocytopenia is associated with a longer OS (10). By contrast, it has also been reported that grade  $\geq 3$  thrombocytopenia induced by ICIs is associated with a shorter OS (11). Presumably, this is partly because severe thrombocytopenia can potentially cause bleeding, which can be fatal, and thrombocytopenia makes it difficult to continue treatments for lung cancer. However, unlike the OS, there is no reported association between the degree of thrombocytopenia and the PFS (10). It is assumed that the effect of ICIs on solid tumors may not be accurately evaluated due to pseudo-progression and other factors. In the present case, the anti-tumor effect of atezolizumab was considered to be weak because the tumor was enlarged on

CT when grade 4 thrombocytopenia induced by atezolizumab appeared. As in previous reports, there was no positive correlation between severe thrombocytopenia and antitumor efficacy. When a situation such as the present case arises, not only should ICIs be promptly discontinued, but effective thrombocytopenia management should also be implemented.

We searched the literature concerning ICI-induced ITP published after 2012 and found 29 cases. The source of our literature search was PubMed using the search items “thrombocytopenia” and “nivolumab” or “pembrolizumab”, “ipilimumab”, “avelumab”, “atezolizumab”, “durvalumab” in the period of 2012 to 2022. We excluded cases of thrombocytopenia due to drugs other than ICIs or other diagnoses, such as thrombotic thrombocytopenia or amegakaryocytic thrombocytopenia. The summarized characteristics of four atezolizumab-related cases are described in Table 2. In these four reports (12-15), two Chinese patients treated with recombinant human TPO for atezolizumab-induced ITP were reported. However, one patient died without improvement

Table 2. A comparison of previous cases of atezolizumab-induced thrombocytopenia with the present case.

References	Age	Sex	Type of carcinoma	Treatment line	Efficacy of ICI	Onset time	Grade	Treatment	Outcome
12	57	Male	NSCLC(Ad)	Third	No date	4 days	5	IL-11, corticosteroid, TPO, platelet transfusion	Died
13	76	Female	NSCLC(Ad)	Second	PR	15 days	3	Corticosteroid	Resolved
14	57	Female	NSCLC(Ad)	Third	No date	7 days	4	Corticosteroid, IVIG, platelet apheresis	Resolved
15	76	Male	NSCLC(Ad)	First	PR	about 2 years 7 months	4	IL-11, corticosteroid, TPO, IVIG, MMF, platelet transfusion, tocilizumab	Resolved
The present case	82	Male	NSCLC(Ad)	Second	PD	9 weeks	4	Corticosteroid, IVIG, platelet transfusion, cyclosporin, eltrombopag	Resolved
Median	76					15 days			

NSCLC : non-small-cell lung cancer, Ad : adenocarcinoma, PR : partial response, PD : progressive disease, IL-11 : interleukin-11, TPO : thrombopoietin, IVIG : intravenous immunoglobulin, MMF : mycophenolate mofetil

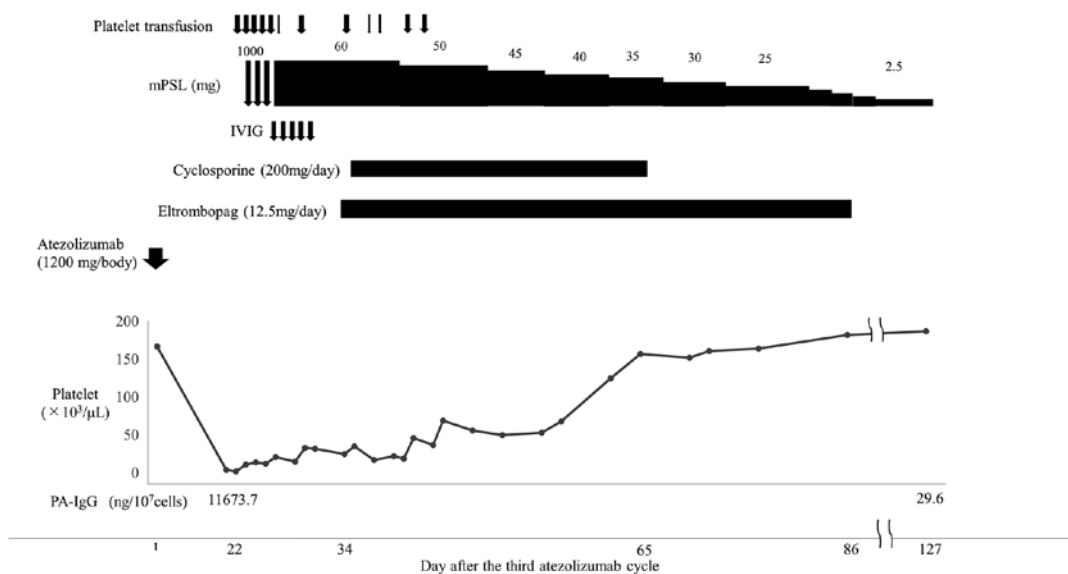


Figure 2. The clinical course and laboratory data in the present case. Thick and thin arrows for platelet transfusions indicate transfusions of 20 and 10 units, respectively ; IVIG arrows indicate 24 g (400 mg/kg) of IVIG for 5 days. mPSL : methylprednisolone, PSL : prednisolone, IVIG : intravenous immunoglobulin, PA-IgG : platelet-associated IgG.

in thrombocytopenia, and the other did not improve with TPO but did improve with an interleukin-6 inhibitor (12, 16). Although recombinant human TPO is not approved in Japan, TPO-RA is approved for the treatment of ITP. The American Society of Clinical Oncology guidelines (17) and a literature review (1, 2) of hematologic irAEs recommend administering TPO-RA or rituximab to patients with ICI-induced ITP refractory to corticosteroids and IVIG. There are previous reports that TPO-RA was effective for pembrolizumab-induced ITP (3) and nivolumab-induced ITP (4) in patients with NSCLC. However, because there have been no previous reports of the efficacy of TPO-RA in atezolizumab-induced ITP, the present case is the first report showing its efficacy.

Thrombocytopenia in ITP is thought to be caused by reduced platelet production in addition to platelet destruction (18). Therefore, in the treatment of ITP, it is important not only to suppress platelet destruction by immunosuppression but also to stimulate platelet production. Whether platelet destruction or decreased platelet production has a greater impact on thrombocytopenia is expected to vary from case to case. In the present case, the response to steroid treatment was weak, and only a mild increase in megakaryocytes was seen compared to the severity of thrombocytopenia. These findings suggest that the reduction in the platelet-producing capacity was more significant than platelet destruction. Therefore, platelet recovery may be attributed primarily to the stimulation of platelet production by eltrombopag, a TPO-RA, rather than to the suppression of platelet destruction by immunosuppressive therapy. However, cyclosporine was also used as immunosuppressive therapy to reduce the dose of PSL after the start of eltrombopag administration. Therefore, it remains possible that cyclosporine also contributed to the improvement of thrombocytopenia. However, despite cyclosporine being discontinued earlier than eltrombopag, the platelet counts did not decrease after discontinuation. These results also suggest that the restorative effect on platelet counts was mainly due to the effect of eltrombopag rather than immunosuppressive therapies, including cyclosporine; eltrombopag was therefore considered an effective treatment option in atezolizumab-induced ITP with a reduced platelet-producing capacity.

## CONCLUSION

We experienced the first case of a response to eltrombopag in atezolizumab-induced ITP, suggesting that eltrombopag may be an effective treatment option for severe ITP caused by atezolizumab.

## REFERENCES

1. Delanoy N, Michot JM, Comont T, Kramkimel N, Lazarovici J, Dupont R, Champiat S, Chahine C, Robert C, Herbaux C, Besse B, Guillemin A, Mateus C, Pautier P, Saïag P, Madonna E, Maerevoet M, Bout JC, Leduc C, Biscay P, Quere G, Nardin C, Ebbo M, Albigès L, Marret G, Lévrat V, Dujon C, Vargaftig J, Laghouati S, Croisille L, Voisin AL, Godeau B, Massard C, Ribrag V, Marabelle A, Michel M, Lambotte O : Haematological immune-related adverse events induced by anti-PD-1 or anti-PD-L1 immunotherapy : a descriptive observational study. *Lancet Haematology* 6 : e48-e57, 2019
2. Michot JM, Lazarovici J, Tieu A, Champiat S, Voisin AL, Ebbo M, Godeau B, Michel M, Ribrag V, Lambotte O : Haematological Immune-Related Adverse Events with Immune Checkpoint Inhibitors, How to Manage? *Eur. J. Cancer* 122 : 72-90, 2019
3. Ito M, Kanda S, Yoshida T, Okuma Y, Jo H, Fukuhara S, Miyagi Maeshima A, Ohe Y : Eltrombopag olamine for refractory immune-related thrombocytopenia induced by pembrolizumab in a non-small cell lung cancer patient. *Lung Cancer* 146 : 362-365, 2020
4. Bagley SJ, Kosteva JA, Evans TL, Langer CJ : Immune thrombocytopenia exacerbated by nivolumab in a patient with non-small-cell lung cancer. *Cancer Treatment Communications*. Volume 6 : 20-23, 2016
5. Fehrenbacher L, Spira A, Ballinger M, Kowanzet M, Vansteenkiste J, Mazieres J, Park K, Smith D, Artal-Cortes A, Lewanski C, Braiteh F, Waterkamp D, He P, Zou W, Chen DS, Yi J, Sandler A, Rittmeyer A ; POPLAR Study Group : Atezolizumab versus docetaxel for patients with previously treated non-small-cell lung cancer (POPLAR) : a multicentre, open-label, phase 2 randomised controlled trial. *Lancet* 387 : 1837-46, 2016
6. Balar AV, Galsky MD, Rosenberg JE, Powles T, Petrylak DP, Bellmunt J, Loriot Y, Necchi A, Hoffman-Censits J, Perez-Gracia JL, Dawson NA, van der Heijden MS, Dreicer R, Srinivas S, Retz MM, Joseph RW, Drakaki A, Vaishampayan UN, Sridhar SS, Quinn DI, Durán I, Shaffer DR, Eigl BJ, Grivas PD, Yu EY, Li S, Kadel EE 3rd, Boyd Z, Bourgon R, Hegde PS, Mariathasan S, Thåström A, Abidoye OO, Fine GD, Bajorin DF ; IMvigor210 Study Group : Atezolizumab as first-line treatment in cisplatin-ineligible patients with locally advanced and metastatic urothelial carcinoma : a single-arm, multicentre, phase 2 trial. *Lancet* 389 : 67-76, 2017
7. Rosenberg JE, Hoffman-Censits J, Powles T, van der Heijden MS, Balar AV, Necchi A, Dawson N, O'Donnell PH, Balmanoukian A, Loriot Y, Srinivas S, Retz MM, Grivas P, Joseph RW, Galsky MD, Fleming MT, Petrylak DP, Perez-Gracia JL, Burris HA, Castellano D, Canil C, Bellmunt J, Bajorin D, Nickles D, Bourgon R, Frampton GM, Cui N, Mariathasan S, Abidoye O, Fine GD, Dreicer R : Atezolizumab in patients with locally advanced and metastatic urothelial carcinoma who have progressed following treatment with platinum-based chemotherapy : a single-arm, multicentre, phase 2 trial. *Lancet* 387 : 1909-20, 2016
8. Ezponda Casajús A, Calvo Imirizaldu M, de Torres Tajés JP, García-Baizán A, Castañón Álvarez E, Cano Rafart D, Vivas Pérez I, Bastarrika Alemañ G : Immune-related adverse events as predictors of response in cancer patients undergoing immunotherapy. *Radiología (English Edition)* 62 : 131-138, 2020
9. Cortellini A, Chiari R, Ricciuti B, Metro G, Perrone F, Tiseo M, Bersanelli M, Bordi P, Santini D, Giusti R, Grassadonia A, Di Marino P, Tinari N, De Tursi M, Zoratto F, Veltri E, Malorgio F, Garufi C, Russano M, Anesi C, Zeppola T, Filetti M, Marchetti P, Berardi R, Rinaldi S, Tudini M, Silva RR, Pireddu A, Atzori F, Iacono D, Migliorino MR, Porzio G, Cannita K, Ficorella C, Buti S : Correlations Between the Immune-related Adverse Events Spectrum and Efficacy of Anti-PD1 Immunotherapy in NSCLC Patients. *Clin Lung Cancer* 20 : 237-247.e1, 2019
10. Assi HA, Asch AS, Machiorlatti M, Vesely SK, Ibrahimi S : Development of thrombocytopenia is associated with improved survival in patients treated with immunotherapy. *Future Sci OA* 6 : 581, 2020
11. Haddad TC, Zhao S, Li M, Patel SH, Johns A, Grogan M, Lopez G, Miah A, Wei L, Tinoco G, Riesenber B, Li Z, Meara A, Bertino EM, Kendra K, Otterson G, Presley CJ, Owen DH : Immune checkpoint inhibitor-related

- thrombocytopenia : incidence, risk factors and effect on survival. *Cancer Immunol Immunother* 71 : 1157-1165, 2022
12. Jia Li, Xubin Deng, Birong Wang, Weidong Li : Fatal outcome of atezolizumab in a patient with immune-mediated pneumonitis, thrombocytopenia, and cardiac dysfunction : A case report. *Int J Clin Pharmacol Ther* 57 : 607-611, 2019
  13. Tsukita Y, Miyauchi E, Fukudo M, Sasaki T, Ichinose M : Immunotherapy-related hepatitis and thrombocytopenia induced by the very low dose of only 90 mg of atezolizumab. *Eur J Cancer* 133 : 22-24, 2020
  14. Yilmaz A, Mirili C, Bilici M, Tekin SB : Possible atezolizumab-associated acute kidney injury and immune thrombocytopenia. *J Oncol Pharm Pract* 26(7) : 1791-1794, 2020
  15. Xie W, Hu N, Cao L : Immune Thrombocytopenia Induced by Immune Checkpoint Inhibitors in Lung Cancer : Case Report and Literature Review. *Front Immunol* 12 : 790051, 2021
  16. Liu X, Liang X, Liang J, Li Y, Wang J : Immune Thrombocytopenia Induced by Immune Checkpoint Inhibitors in Solid Cancer : Case Report and Literature Review. *Front Oncol* 10 : 530478, 2020
  17. Brahmer JR, Lacchetti C, Schneider BJ, Atkins MB, Brassil KJ, Caterino JM, Chau I, Ernstoff MS, Gardner JM, Ginex P, Hallmeyer S, Holter Chakrabarty J, Leighl NB, Mammen JS, McDermott DF, Naing A, Nastoupil LJ, Phillips T, Porter LD, Puzanov I, Reichner CA, Santomasso BD, Seigel C, Spira A, Suarez-Almazor ME, Wang Y, Weber JS, Wolchok JD, Thompson JA ; National Comprehensive Cancer Network : Management of Immune-Related Adverse Events in Patients Treated With Immune Checkpoint Inhibitor Therapy : American Society of Clinical Oncology Clinical Practice Guideline. *J Clin Oncol* 36 : 1714-68, 2018
  18. Cooper N, Bussell J : The pathogenesis of immune thrombocytopenic purpura. *Br J Haematol* 133 : 364-374, 2006