

CASE REPORT

A rare case of massive hepatic abscess 6 years after ERCP due to retained biliary stent

Ioannis G. Gkionis¹, Michail I. Giakoumakis¹, Ifigenia Tzartzalou¹, George Kavallaris², Pinelopi Nicolaou³, Emmanouil Vardas³, and Aggelos Laliotis¹

¹Department of General Surgery, Venizeleio General Hospital, Leoforos Knossou 44, Heraklion, Crete, Greece, ²Department of Imaging, Venizeleio General Hospital, Leoforos Knossou 44, Heraklion, Crete, Greece, ³Department of Gastroenterology, Venizeleio General Hospital, Leoforos Knossou 44, Heraklion, Crete, Greece

Abstract : Background : ERCP combined with the insertion of biliary endoprosthesis is considered a daily practice endoscopic intervention for the treatment of choledocholithiasis. Nevertheless, retained biliary stents for a prolonged period without follow up may cause serious complications. Case presentation : We present the case of a 62-year-old man who was hospitalized with symptoms of vomiting, abdominal pain, fatigue and fever. Clinical examination and laboratory results were indicative of an intra abdominal infection. Ultrasound and CT scans were performed, identifying a 17x11.3x7.7 cm. The cause of this lesion was a retained stent in the common bile duct which was placed 6 years ago via endoscopic retrograde cholangiopancreatography. The patient did not attend his follow up appointments after his initial ERCP. Patient's clinical status deteriorated, and an urgent ERCP was performed replacing the retained stent, followed by ultrasound-guided pigtail stent insertion into the hepatic abscess and administration of antibiotics intravenously. Patient's clinical condition was improved and after two months of surveillance complete resolution of the hepatic abscess was achieved. Conclusion : The insertion of biliary stents is common endoscopic technique, but close follow up is of outmost importance. *J. Med. Invest.* 70 : 508-512, August, 2023

Keywords : Pyogenic hepatic abscess, ERCP, Stent, Follow up, Case management

INTRODUCTION

Endoscopic retrograde cholangiopancreatography (ERCP) is widely accepted as the gold standard technique for the treatment of choledocholithiasis and, is usually combined with the endoscopic insertion of biliary endoprosthesis in order to establish and secure patency of the common bile duct (CBD) (1, 2). Biliary stents are tubular devices made of plastic or metal, and is recommended to be replaced or removed within 2-6 months from insertion (1-4).

Retained biliary stents for a prolonged period without follow up may cause serious, or even life-threatening, complications such as acute cholangitis, pancreatitis, internal stent migration, endoprosthesis occlusion and obstructive jaundice (3-12). In these cases, the mortality rate can reach up to 12% (3). The formation of liver abscess is a rare complication of a forgotten stent in the CBD. Only 2 cases have been described in literature to the best of our knowledge (7, 8).

We present the case of a 62 year-old male patient with liver abscess due to retained biliary stent, who was treated via ultrasound (U/S) guided drainage of the abscess and administration of antibiotics intravenously. This report aims to bring to clinicians' attention this relatively rare entity and highlight the management options.

CASE PRESENTATION

We present the case of a 62 year-old Caucasian male patient who was hospitalized with symptoms of vomiting, abdominal pain, fatigue and fever. The symptoms have begun 3 days before his admission to the hospital. His vital signs on the admission were the following : Temperature = 38.5°C, Heart rate = 95 beats/min, Respiratory rate = 23 breaths/min, Blood pressure = 110/70 mmHg. The patient was pale but with good nutrition status (Body Mass Index = 20.2 kg/m²). Moreover, his tobacco use was 30 pack-years and he did not consume alcohol.

Patient's past medical history included hypothyroidism treated with levothyroxine and CBD stent placement after an ERCP, 6 years ago, due to an episode of obstructive jaundice. A CBD stricture, related to inflammation, was identified as the cause of the jaundice. Cytological samples taken from the stricture were negative for malignancy and a plastic 10 Fr-10 cm stent was inserted. Patient did not appear on the scheduled appointments for evaluation of the biliary stent. Furthermore, there was no previous surgical history.

On inspection, he was ill-looking and had signs of dehydration. The clinical examination revealed sensitivity in the right upper quadrant of the abdomen without tenderness, whereas, the bowel sounds were normal. In addition, there was no blood or palpable mass on digital rectal examination. Furthermore, the clinical examination of cardiopulmonary and urogenital systems revealed no abnormal signs.

Abbreviations

- ERCP = Endoscopic retrograde cholangiopancreatography
- CBD = Common bile duct
- CT = Computed tomography
- U/S = Ultrasound

Received for publication December 12, 2022 ; accepted March 29, 2023.

Address correspondence and reprint requests to Aggelos Laliotis, Department of General Surgery, Venizeleio General Hospital, Leoforos Knossou 44, Heraklion, 71409, Crete, Greece and E-mail : laliotisac@gmail.com

The blood tests revealed elevated inflammatory markers, anaemia, jaundice electrolyte disorders, as well as deterioration of the liver function (Table 1). The results of all other laboratory markers were within normal range (Table 1).

Table 1. Blood test results on admission

Blood test markers	On admission	Normal range values
WBC	19.170	3.800-10.500/mL
Hct	29.5	41-53.8%
Hb	9.2	13.4-17.4 g/dL
PLT	301	150-400 K/ μ l
CRP	38.97	<0.5 mg/dL
UR	48	15-50 mg/dL
CR	0.95	0.7-1.3 mg/dL
K ⁺	3.4	3.5-5.1 mmol/L
Na ⁺	127	136-145 mmol/L
TA-BIL	2.04	0.3-1.2 mg/dL
D-BIL	1.3	0-0.5 mg/dL
SGOT	125	0-35 U/L
SGPT	116	0-55 U/L
GGT	322	0-50 U/L
ALP	348	40-150 U/L
CEA	2.64	0-5 ng/ml
AFP	0.96	0.89-8.78 ng/ml
CA 19-9	27.48	0-37 U/ml
PSA Total	0.389	0-4 ng/ml
TSH	0.3838	0.35-4.94 μ UI/mL

Note.
WBC = White blood cells, Hb = Haemoglobin, Hct = Haematocrit, PLT = Platelets, CRP = C-reactive protein, UR = Urea, Cr = Creatinine, Na⁺ = Sodium, K⁺ = Potassium, TA-BIL = total bilirubin, D-BIL = direct bilirubin, SGOT = Serum glutamic oxaloacetic transaminase, SGPT = Serum glutamic pyruvic transaminase, GGT = Gamma glutamyl transferase, ALP = alkaline phosphatase, CEA = Carcinoembryonic antigen, AFP = Alpha Fetoprotein, CA 19-9 = Cancer antigen 19-9, PSA Total = Prostate specific antigen Total, TSH = Thyroid stimulating hormone

Taking into consideration all findings from the clinical examination and the blood tests, an abdominal U/S was performed, revealing a 17x11.3x7.7 cm hypoechoic lesion with irregular borders and hyperechoic rim in the right hepatic lobe, followed by computed tomography (CT) of the abdomen. The latter confirmed the findings of U/S, and, in addition depicted a stent in CBD causing slight dilation of intra-hepatic bile ducts (Figure 1). Furthermore, the gallbladder was distended without gallstones (Figure 2). The serological tests were negative for hepatitis, HIV infection and echinococcosis, whereas the tumour markers in blood were normal (Table 1).

Due to deterioration of his clinical status with exacerbation of abdominal pain, presence of electrolyte disorders and onset of fever, the patient underwent an urgent ERCP 6 hours after his admission to the hospital and replacement of the previously inserted plastic stent with a new one plastic 7 Fr–10 cm stent. The replaced stent was partially obstructed and many small gallstones and biliary sludge were removed from the CBD. The U/S-guided pigtail stent insertion into the hepatic lesion released a substantial amount of brownish fluid which was sent for microbial and cytological analysis. The cytological examination

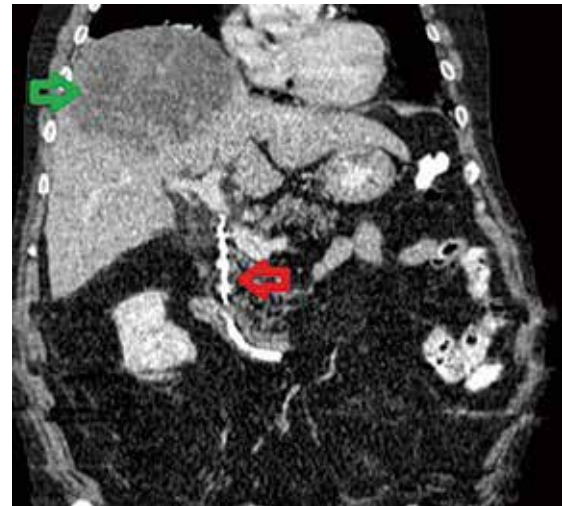


Figure 1. Hepatic abscess and stent in CBD. CT of the abdomen depicting a 17x11.3x7.7cm hepatic abscess in the right hepatic lobe and a stent in CBD causing slight dilation of intra-hepatic bile ducts. The green arrow is demonstrating the hepatic abscess, whereas the red one is depicting the stent in CBD.

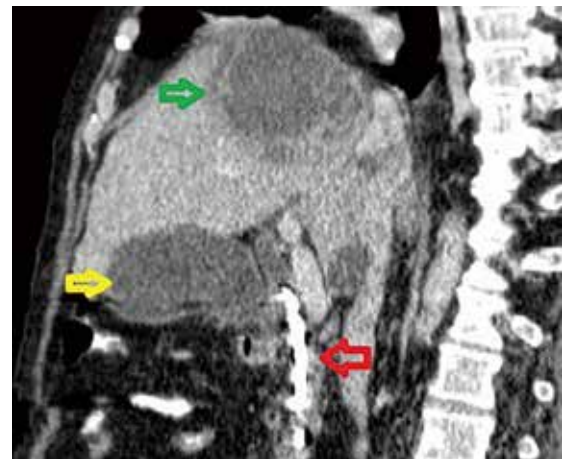

Figure 2. Hepatic abscess, stent in CBD and gallbladder. CT of the abdomen depicting the hepatic abscess, the stent in CBD and the gallbladder. The green arrow is demonstrating the hepatic abscess, the red arrow is depicting the stent in CBD and the yellow arrow is showing the gallbladder.

of the specimen was negative for malignancy, whereas the cultures revealed the growth of *Enterococcus faecalis* and *Klebsiella pneumoniae*. The initial empiric antibiotic therapy with ceftriaxone, metronidazole and gentamicin was modified according to pus cultures to ciprofloxacin and linezolid. The clinical condition of the patient was improved and an abdominal CT was performed 8 days after his admission to the hospital revealing significant decrease in the dimensions of the liver abscess (Figure 3). Nevertheless, a second pigtail stent was inserted (Figure 3). The patient received intravenously 0.8 gr Ciprofloxacin/day for 22 days and 1.2 gr Linezolid/day for 22 days. He also received 1 gr Ciprofloxacin/day and 1.2 gr Linezolid/day per os, for 30 days after his discharge.

The patient was discharged 27 days after his admission to the hospital and he underwent regular follow up meetings with clinical examination, blood tests and CT of the abdomen.

His last follow up was in November 2021, 2 months after his hospitalization, in which he was found in good clinical condition. The abdominal CT depicted complete resolution of the hepatic abscess and, both the pigtail stents in the hepatic lesion and the stent in the CBD, were removed (Figure 4).

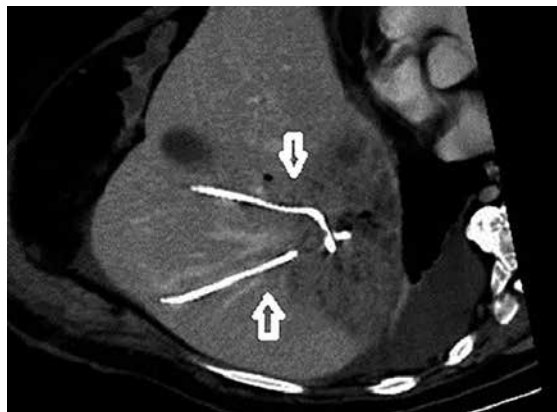


Figure 3. Insertion of pigtail stents into the hepatic abscess. CT of the abdomen showing two pigtail stents inserted into the hepatic abscess. The arrows are demonstrating the pigtail stents.

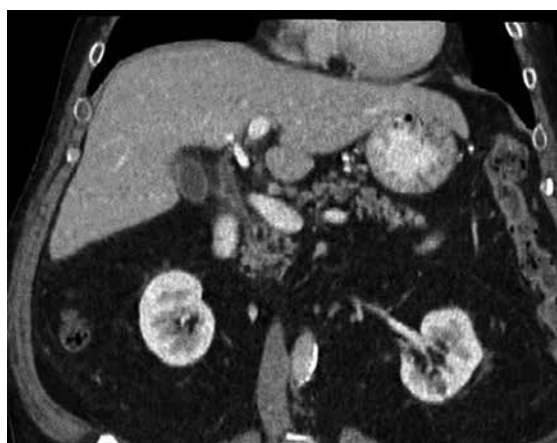

Figure 4. Complete resolution of the hepatic abscess. CT of the abdomen revealing complete resolution of the hepatic abscess.

DISCUSSION

ERCP is an extremely useful endoscopic technique used in daily practice for both diagnosis and treatment of biliary pathology. Insertion of biliary endoprosthesis during ERCP is considered the treatment of choice for patients of any age, in order to establish and maintain the bile flow in case of stone impaction in the CBD with a success rate of up to 95% (1, 2).

Biliary stents are tubes made of plastic or metal in different sizes and shapes, used to relieve obstruction in the biliary tree or to treat biliary leaks (1, 2). Plastic stents are considered a valuable option for benign biliary strictures, although they are related to a notable complication rate (36.5% for single and 20.3% for multiple plastic stents) (13, 14). Compared to uncovered metal stents (39.5% complication rate), plastic stents are cheaper and safer (13, 14). However, fully covered metal stents are related to a similar complication rate (23.8%) with the plastic stents, but at a significantly higher cost (15). Nevertheless, metal stents have higher patency rates, and for this reason are considered the mainstay treatment for hilar malignancy and inoperable malignant strictures of the common bile duct (16).

Patient's adherence to follow-up is crucial. Regular appointments should be scheduled every 2-6 months after the initial insertion of endoprosthesis, and continues until the removal of the biliary stent (1-4, 11). Biliary stents are foreign bodies and, therefore, if kept for a prolonged period they contribute to formation of stones in the CBD and bacterial proliferation (3-12). A combination of biliary stasis, bile infection and microbial translocation is considered as the most probable mechanism of hepatic abscess formation in our case. Ascending cholangitis, due to occlusion of retained biliary stents, was also considered responsible for the formation of hepatic abscesses in the other two similar cases reported in literature (7, 8) (Table 2).

In general, hepatic abscesses may vary from a small (≤ 5 cm) to giant size (> 10 cm). The majority of hepatic abscesses present with an average size between 5 cm to 10 cm, and these lesions are characterized as "large" (17). They usually present with a combination of malaise, abdominal pain, fever and obstructive jaundice (18, 19).

Early diagnosis is crucial for appropriate treatment, and abdominal imaging is pivotal in confirming the diagnosis. Abdominal U/S and CT are the most commonly used diagnostic modalities while further imaging with MRI is included in patient's workup (20). Abdominal CT has a sensitivity of 97% in diagnosing liver abscess, and is considered the gold standard imaging technique (9). The double target sign is a characteristic imaging feature of hepatic abscess demonstrated on CT scan, in which a central low attenuation lesion filled with liquid is

Table 2. Comparison of the 3 cases with hepatic abscess due to retained biliary stent presenting patients' age, symptoms, abscess's characteristics, characteristics of retained stent and management

Author	Age	Symptoms	Abscess location	Abscess size	Characteristics of retained stent	Duration of retained stent	Management
Alhaddad O <i>et al.</i> (7)	62	-Abdominal pain -Fever -Jaundice	Right hepatic lobe	10x10 cm	Plastic stent	20 years	-ERCP -Pigtail stent insertion to abscess -Antibiotics
Rajmohan R <i>et al.</i> (8)	37	-Abdominal pain -Fever -Diarrhea	Hepatic dome	Multiple, <3 cm	Multiple plastic stents	10 years	-ERCP -Antibiotics
Gkionis <i>et al.</i>	62	-Vomiting -Abdominal pain -Fever -Jaundice	Right hepatic lobe	17x11.3x 7.7 cm	Plastic stent	6 years	-ERCP -Pigtail stent insertion to abscess -Antibiotics

surrounded by a high attenuation inner rim representing the membrane of the abscess and a low attenuation outer ring depicting the edema of the liver parenchyma (18). Moreover, CT is extremely helpful in guiding accurate percutaneous drainage which is nowadays the most widely accepted approach in terms of treatment along with antibiotic administration (21).

In the vast majority of cases the abscess is polymicrobial and the most commonly involved pathogens in the formation of hepatic abscesses are *Escherichia Coli*, *Klebsiella pneumoniae*, *Bacteroides* and *Enterococcus* (17). In abscesses due to retained biliary endoprosthesis the first step in patient's management, should be the removal or replacement of the forgotten stent via ERCP followed, in most cases, by a combination of antibiotic therapy and adequate drainage (19). The antibiotic regimen should cover a wide spectrum of microbes and for that reason should consist of ampicillin combined with an aminoglycoside and metronidazole (18). Antibiotic therapy alone, without drainage, should be reserved only for patients in good clinical status and those who have multiple micro abscesses, smaller than 3 cm in diameter, not amenable to drainage (18). The antibiotic treatment can be modified based on the results of blood or pus cultures. The duration of the antibiotic therapy should be individualized on the basis of the clinical response and most of the patients should receive antibiotics for 4-6 weeks (17-19).

Drainage of pyogenic liver abscesses is the mainstay treatment and can be performed surgically or with the use of minimally invasive techniques. Image guided percutaneous drainage has success rate up to 90% and has become the treatment of choice in most centers, while surgical drainage nowadays is reserved for patients who fail to respond to treatment with percutaneous drainage and antibiotics or have concurrent intraabdominal pathology which requires surgical management (21).

In conclusion, CBD patency should be always checked after insertion of biliary endoprosthesis as it can lead even to the formation of hepatic abscess, a rare but potentially lethal complication. Clinical vigilance, early appropriate imaging, rapid removal of the endoprosthesis along with drainage and antibiotic treatment are pivotal in the management of this rare clinical scenario.

CONCLUSION

The formation of hepatic abscess due to retained biliary stent is a rare complication of ERCP. Obviously, close follow up is of outmost importance.

ACKNOWLEDGEMENTS

None.

DECLARATIONS

Funding : There was no funding.

Conflict of Interests : Authors have no potential competing interests or conflicts to report.

Ethics approval and consent to participate : This case report was conducted in accordance with the ethical standards of the institutional and national research committee and with the 1964 Helsinki Declaration and its later amendments or comparable ethical standards. The case report was approved by the Ethics Committee of the Scientific Board of Venizeleio General Hospital of Heraklion (Decision No.127/Meeting 24/04-10-2022). Written informed consent was obtained from the patient. A copy of the written consent is available for review by the Editor-in-Chief of

the journal.

Consent for publication : Written informed consent was obtained from the patient for the publication of this case report and any accompanying images. A copy of the written consent is available for review by the Editor-in-Chief of the journal.

Availability of data and material : The datasets generated and analysed during the current study are available from the corresponding author on reasonable request.

Authors Contribution : IG, MG, GK and PN analyzed and interpreted the patient's data. The first draft of the manuscript was written by IG, MG and supervised by AL. All authors commented on previous versions of the manuscript. AL and EV participated in design and coordination. All authors read and approved the final manuscript.

REFERENCES

- Dumonceau JM, Tringali A, Papanikolaou IS, Blero D, Mangiavillano B, Schmidt A, Vanbiervliet G, Costamagna G, Devière J, García-Cano J, Gyökeres T, Hassan C, Prat F, Siersema PD, Van Hooft JE : Endoscopic biliary stenting : indications, choice of stents, and results : European Society of Gastrointestinal Endoscopy (ESGE) Clinical Guideline - Updated October 2017. *Endoscopy* 50 : 910-930, 2018
- Buxbaum JL, Abbas Fehmi SM, Sultan S, Fishman DS, Qumseya BJ, Cortessis VK, Schilperoort H, Kysh L, Matsuoka L, Yachinski P, Agrawal D, Gurudu SR, Jamil LH, Jue TL, Khashab MA, Law JK, Lee JK, Naveed M, Sawhney MS, Thosani N, Yang J, Wani SB : ASGE guideline on the role of endoscopy in the evaluation and management of choledocholithiasis. *Gastrointest Endosc* 89 : 1075-1105.e15, 2019
- Kim SJ, Ohanian E, Lee F, Nam B, Che K, Laine L, Kim SE, Kim JJ : Predictors and outcomes of delayed plastic biliary stent removal following endoscopic retrograde cholangiopancreatography. *Scand J Gastroenterol* 52 : 1128-1132, 2017
- Sohn SH, Park JH, Kim KH, Kim TN : Complications and management of forgotten long-term biliary stents. *World J Gastroenterol* 23 : 622-628, 2017
- Lesetedi C, Motsumi MJ : Forgotten metal stent (3 years) presenting with a high burden of intra- and extra-hepatic ducts stones and cholangitis. *J Surg Case Rep* 2019 : rjz294, 2019
- Barai V, Hedawoo J, Changole S : Forgotten CBD stent (102 months) with stone-stent complex : A case report. *Int J Surg Case Rep* 30 : 162-164, 2017
- Alhaddad O, Elsabaawy M, Edrees A, Elshimy E, Elsabaawy D, Mansour T : A case report of COVID-19 evoked cholangitic liver abscess. *Egypt Liver J* 12 : 5, 2022
- Rajmohan R, Charudatta W, Bobby J, Shino P, Pranay S, Santosh K, Paul M, Kaleem R : A case of forgotten biliary stent presenting as multiple liver lesions : A single institution experience. *The American Journal of Gastroenterology* 116 : pS1426, 2021
- Catalano O, De Bellis M, Sandomenico F, de Lutio di Castelguidone E, Delrio P, Petrillo A : Complications of biliary and gastrointestinal stents : MDCT of the cancer patient. *AJR Am J Roentgenol* 199 : W187-96, 2012
- Odabasi M, Arslan C, Akbulut S, Abuoglu HH, Ozkan E, Yildiz MK, Eris C, Gunay E, Tekesin K, Muftuoglu T : Long-term effects of forgotten biliary stents : a case series and literature review. *Int J Clin Exp Med* 7 : 2045-52, 2014
- Jaleel R, Simon EG, Gupta P, Patnaik I, David D, Chowdhury

- SD : Retained biliary plastic stents - lest we forget. *Trop Doct* 51 : 177-180, 2021
12. Merei F, Shapiro G, Shakra IA, Bickel A, Ganam S, Bez M, Kakiashvili E : An unusual case of multifocal pyogenic abscess formation following ERCP procedure. *BMC Surg* 20 : 92, 2020
 13. van Boeckel PGA, Vleggaar FP, Siersema PD : Plastic or metal stents for benign extrahepatic biliary strictures : a systematic review. *BMC Gastroenterol* 9 : 96, 2009
 14. Ramchandani M, Lakhtakia S, Costamagna G, Tringali A, Püspök A, Tribl B, Dolak W, Devière J, Arvanitakis M, van der Merwe S, Laleman W, Ponchon T, Lepilliez V, Gabbrieli A, Bernardoni L, Bruno MJ, Poley JW, Arnelo U, Lau J, Roy A, Bourke M, Kaffes A, Neuhaus H, Peetermans J, Rousseau M, Nageshwar Reddy D : Fully covered self-expanding metal stent vs multiple plastic stents to treat benign biliary strictures secondary to chronic pancreatitis : A multicenter randomized trial. *Gastroenterology* 161 : 185-195, 2021
 15. Kaasis M, Boyer J, Dumas R, Ponchon T, Coumaros D, Delcenserie R, Canard JM, Fritsch J, Rey JF, Burtin P : Plastic or metal stents for malignant stricture of the common bile duct? Results of a randomized prospective study. *Gastrointest Endosc* 57 : 178-82, 2003
 16. Jha AK, Jha P, Jha SK, Keshari R : Plastic versus metal stents for inoperable gallbladder cancer with hilar biliary obstruction : the jury is still out. *Ann Gastroenterol* 34 : 12-19, 2021
 17. Du ZQ, Zhang LN, Lu Q, Ren YF, Lv Y, Liu XM, Zhang XF : Clinical characteristics and outcome of pyogenic liver abscess with different size : 15-year experience from a single center. *Sci Rep* 6 : 35890, 2016
 18. Lardiè-re-Deguelte S, Ragot E, Amroun K, Piardi T, Dokmak S, Bruno O, Appere F, Sibert A, Hoeffel C, Sommacale D, Kianmanesh R : Hepatic abscess : Diagnosis and management. *J Visc Surg* 152 : 231-43, 2015
 19. Shi SH, Zhai ZL, Zheng SS : Pyogenic liver abscess of biliary origin : The existing problems and their strategies. *Semin Liver Dis* 38 : 270-283, 2018
 20. Sheybani A, Gaba RC, Lokken RP, Berggruen SM, Mar WA : Liver Masses : What physicians need to know about ordering and interpreting liver imaging. *Curr Gastroenterol Rep* 19 : 58, 2017
 21. Al-Sayaghi KM, Alhujaily M, Zaky MK, Alhasan AS, Babikir TB, Alnehmi FS, Abdalrahman HH, Abdelmalik MAA, Ali AM, Fadlalmola HA, Swamy DSV : Percutaneous needle aspiration versus catheter drainage in the management of liver abscess : an updated systematic review and meta-analysis. *ANZ J Surg* doi : 10.1111/ans.18129.