

## Case Report

# Recurrent multiple liver metastases of clear cell renal cell carcinoma with a significant response to sunitinib after nivolumab treatment

Kouki Tada,<sup>1</sup> Kei Daizumoto,<sup>1</sup> Masayuki Takahashi,<sup>1</sup> Hisanori Uehara,<sup>2</sup> Megumi Tsuda,<sup>1</sup> Yoshito Kusuhara,<sup>1</sup> Tomoya Fukawa,<sup>1</sup> Yasuyo Yamamoto,<sup>1</sup> Kunihisa Yamaguchi<sup>1</sup> and Hiro-omi Kanayama<sup>1</sup>

<sup>1</sup>Department of Urology, Tokushima University Graduate School of Biomedical Sciences, and <sup>2</sup>Division of Pathology, Tokushima University Hospital, Tokushima, Japan

### Abbreviations & Acronyms

AE = adverse event  
 IO-drug = Immuno-Oncology drug  
 PD = progressive disease  
 PDGFR = platelet-derived growth factor receptor  
 PR = partial response  
 RCC = renal cell carcinoma  
 SD = stable disease  
 VATS = video-assisted thoracic surgery  
 VEGFR-TKI = vascular endothelial growth factor receptor-tyrosine kinase inhibitor

**Introduction:** A case of multiple liver metastases of clear cell RCC with a significant response to sunitinib as the fifth line after nivolumab is reported.

**Case presentation:** The patient was a 65-year-old man who underwent open nephrectomy for RCC. After the nephrectomy, he had recurrences several times, and metastasectomy had been performed for each recurrence. At 13 years after the nephrectomy, multiple liver, and lung metastases appeared. The treatment was switched to axitinib, followed by cabozantinib, then nivolumab. The best response was PR, SD, and PD for these three drugs, and treatment duration was 14, 3, and 3 months, respectively. As the fifth line, sunitinib was administered, with significant shrinkage of the multiple liver metastases, and PR has been maintained for 34 months.

**Conclusion:** Sunitinib after an IO-drug showed a significant effect in spite of only slight efficacy with other VEGFR-TKIs, which may have occurred through the alteration of the immunological microenvironment.

**Key words:** molecular-targeted therapy, nivolumab, renal cell carcinoma, sunitinib.

**Correspondence:** Masayuki Takahashi, M.D., Ph.D., Department of Urology, Tokushima University Graduate School of Biomedical Sciences, 3-18-15 Kuramoto-cho, Tokushima, Tokushima 770-8503, Japan. Email: takahashi.masayuki@tokushima-u.ac.jp

**How to cite this article:** Tada K, Daizumoto K, Takahashi M *et al.* Recurrent multiple liver metastases of clear cell renal cell carcinoma with a significant response to sunitinib after nivolumab treatment. *IJU Case Rep.* 2023; 6: 41–44.

This is an open access article under the terms of the [Creative Commons Attribution-NonCommercial-NoDerivs](#) License, which permits use and distribution in any medium, provided the original work is properly cited, the use is non-commercial and no modifications or adaptations are made.

Received 28 March 2022; accepted 30 September 2022.

Online publication 18 October 2022

## Keynote message

In this case, sunitinib administered as the fifth line after nivolumab demonstrated the remarkable tumor reduction for multiple liver metastases of RCC, which is considered to be an unfavorable factor for VEGFR-TKIs. A VEGFR-TKI may have been effective due to the alteration of tumor immunological microenvironment after IO-drug treatment although different mechanisms of action exist among the VEGFR-TKIs.

## Introduction

The advent of IO-drugs as the monotherapy in the subsequent therapy or the combination therapy in the first line of treatment has dramatically changed the treatment landscape for metastatic RCC. However, the efficacy of drugs used in very late line is limited. We present an interesting case where sunitinib administered as the fifth line after nivolumab was very effective.

## Case presentation

The patient was a 65-year-old man. The progress is also shown in the figure (Fig. 1).

He had undergone open nephrectomy for left RCC (clear cell carcinoma, Fuhrman Grade 3, INF $\beta$ , pT2, v+, pN0, RM0) in X year. Interferon alfa-2b was given as adjuvant therapy. During the adjuvant therapy with interferon alfa-2b, a lung metastasis appeared 1 year later and was resected by VATS. Ten years after the nephrectomy, the patient had a recurrence of splenic metastasis and underwent a splenectomy. Two years later, recurrent metastasis appeared in the left retroperitoneum, and combined resection of the retroperitoneal mass and tail of the pancreas was performed. One year later, multiple liver and lung metastases appeared and the patient was referred to our department.

Chest and abdominal pelvic contrast-enhanced CT demonstrated multiple lung metastases in both lungs, and multiple metastatic foci with a ring-shaped contrast effect were seen in the liver (Fig. 2). The patient was started on axitinib as the second-line therapy. After 5 months of treatment, the tumor shrank by 36.1% and a PR had been achieved. After 14 months, axitinib was discontinued due to PD.

The patient was started on cabozantinib as the third-line therapy. At 3 months after starting cabozantinib, gastroschisis and perforated abscesses were observed. In addition to these AEs, the disease was progressive and cabozantinib was discontinued. After the gastroschisis subsided, nivolumab was started as the fourth-line therapy. After 3 months, nivolumab was discontinued due to a marked increase in liver metastases.

Sunitinib at 25 mg was started as the fifth-line therapy. Sunitinib was temporarily interrupted with AEs requiring hospitalization, including fever, liver dysfunction, and worsening of general condition.

After 2 weeks of interruption, sunitinib was re-started with no AEs, then, the dose was increased to 37.5 mg. Numbness and pain in the arms and legs and decreased appetite appeared gradually, the dose was again reduced to 25 mg. At

5 months after the introduction of sunitinib, CT showed PR with 55.5% shrinkage in target lesions of multiple liver metastases. Thereafter, because of the worsening of the retroperitoneal abscess, the dose of sunitinib was reduced to 12.5 mg, which does not cause any major health problems, and PR is maintained 34 months after sunitinib initiation (Fig. 3).

## Discussion

As the primary treatment for metastatic clear cell RCC, VEGFR-TKI monotherapy had been the mainstay of systemic therapy. Recently, international phase III trials such as CheckMate 214, KEYNOTE-426, JAVELIN Renal 101, and CheckMate 9-ER have shown the superiority of IO-IO combination or IO-drug plus VEGFR-TKI combination therapy over sunitinib.<sup>1–4</sup> However, with regard to the subsequent therapy, nivolumab has proved to be effective after VEGFR-TKI in the CheckMate 025 trial, but the efficacy of VEGFR-TKI therapy after IO-drug is still unclear.<sup>5</sup>

In this case, sunitinib administered as the fifth line was very effective after nivolumab. It is important to consider the

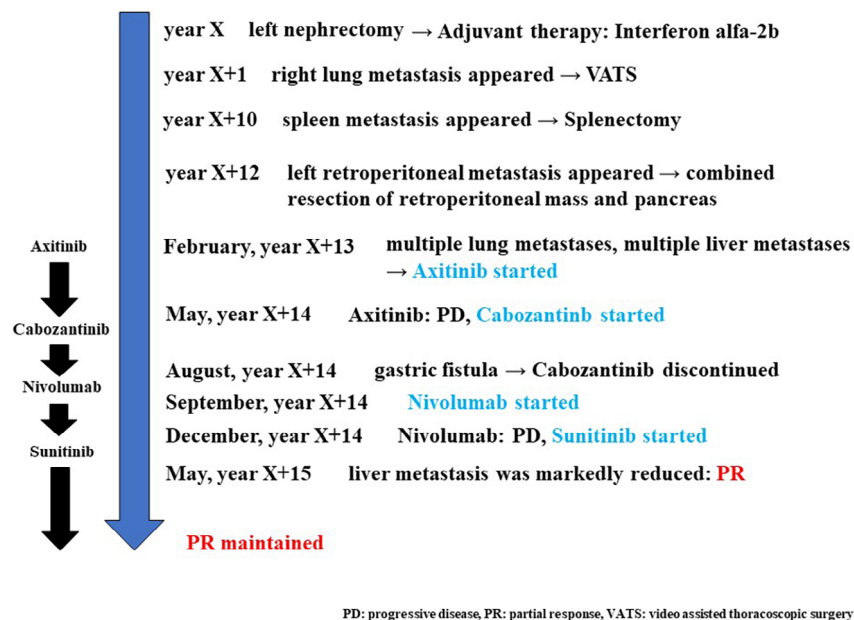


Fig. 1 Clinical course from the onset of RCC to the present.

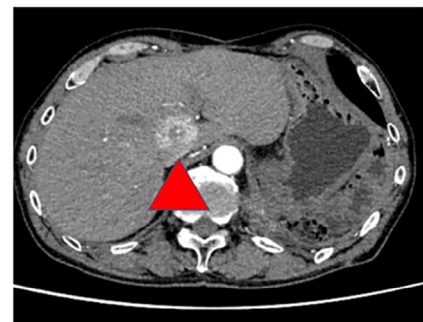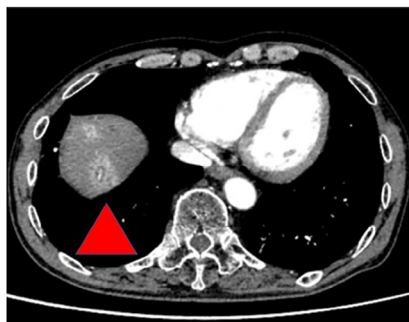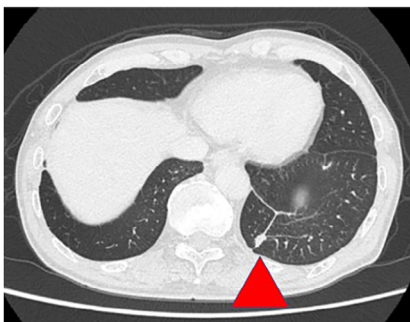


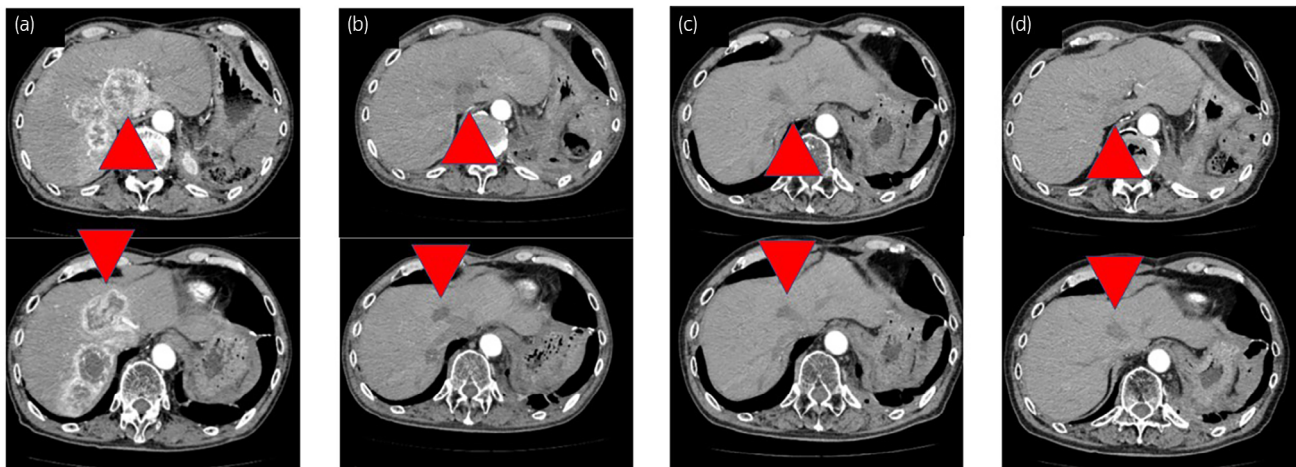
Fig. 2 Contrast-enhanced CT images of representative lung and liver metastases before starting Axitinib.

reasons why fifth-line sunitinib has been so effective with long-term PR. The first reason may be a specific characteristic of the therapeutic agent. The VEGFR-TKIs that are approved for metastatic RCC include sorafenib, sunitinib, pazopanib, axitinib, and cabozantinib, and each drug inhibits its own specific signaling pathways in addition to VEGFR. Sunitinib inhibits not only VEGFR, but also PDGFR and KIT, and it is possible that inhibition of PDGFR and KIT, which is not inhibited by axitinib or cabozantinib, resulted in a significant response.

The second reason may be that IO treatment before sunitinib altered the tumor immunological microenvironment. An observational study by Tomita et al. showed that the objective response rate of molecular targeted therapy after nivolumab or nivolumab plus ipilimumab combination therapy was 27% and 32%, respectively, in Japanese patients with mRCC.<sup>6</sup> In the study by Nadal et al, the objective response rate of VEGFR-TKI treatment after nivolumab or nivolumab plus ipilimumab combination therapy was 36.2%, which is comparable to the study by Tomita.<sup>7</sup> In the latest study, Bando et al. investigated the effectiveness of molecular targeted therapy after nivolumab treatment for metastatic RCC, where TKI treatment after nivolumab showed a significant response with PR of 22.5% and SD of 45.0%.<sup>8</sup> Several other studies have

reported the efficacy of VEGFR-TKI therapy after IO therapy (Table 1).<sup>9,10</sup> In the present case, as in those reports, the prior use of nivolumab may have induced a significant antitumor effect of sunitinib even in the fifth-line treatment. Such efficacy of chemotherapy after IO treatment has been reported not only in metastatic RCC, but also in other malignancies.<sup>11,12</sup> Also, NLR is thought to reflect the immune microenvironment of cancer patients, and in the study by Soda et al., the dynamics of NLR in the early stages of nivolumab treatment were inversely correlated with subsequent treatment response.<sup>13</sup> In the present case, the NLR before nivolumab initiation was 2.61, while the NLR before sunitinib initiation was 3.10, hardly any change, consistent with the pattern of the efficacy of the following treatment in this study. The patient also developed fever 4 weeks after starting sunitinib, at which time the NLR temporarily increased, but after the fever resolved, the NLR was rather lower than before the fever. A reduction in NLR has also been reported to be associated with an improved prognosis with sunitinib, and it is presumed that some immune response occurred in this case and that sunitinib was also significantly effective.<sup>14</sup>

Additionally, nivolumab alone did not show any response in this case, but after discontinuation of nivolumab, immunological effects may have continued afterward and a sort of



**Fig. 3** The course of liver metastases treated with sunitinib by contrast-enhanced CT. (a) Before starting Sunitinib (b) 5 months later: The ring contrast effect was no longer seen and the tumor diameter markedly decreased. (c) 16 months later: Tumor had continued to shrink. (d) 22 months later: Tumor response was maintained.

**Table 1** ORR of molecular targeted therapy after IO-drugs for metastatic renal cell carcinoma

Author	Prior drug	Patients No.	Subsequent drug	ORR (%)
Y. Tomita, et al	Nivolumab	26	Sunitinib, Axitinib, Pazopanib, Everolimus	27
	Nivolumab + Ipilimumab	19		32
R. Nadal, et al	Nivolumab	32	Axitinib, Sunitinib, Pazopanib, Sorafenib	36.2
	Nivolumab + Ipilimumab	17		
Y. Bando, et al	Nivolumab	40	Axitinib, Pazopanib, Sunitinib, Sorafenib	22.5
P. C. Barata, et al	Nivolumab + Ipilimumab	11	Axitinib, Cabozantinib, Pazopanib, Sunitinib	33
A. Y. Shah, et al	Atezolizumab/Nivolumab	12	Axitinib, Cabozantinib, Pazopanib, Sunitinib	50
	Nivolumab + Ipilimumab	32		43.8

IO-drug, immuno oncology-drug; ORR, objective response rate.

synergistic effect of nivolumab and sunitinib may have produced such anti-tumor effect for the liver metastases for a long time.

## Conclusion

A case of metastatic clear cell RCC that responded well to sunitinib as the fifth line after nivolumab treatment was presented. The reasons for the significant response of sunitinib in late-stage therapy suggest differences in the target genes of each VEGFR-TKI and the use of IO-drug.

## Acknowledgment

We would like to thank our patient for his cooperation.

## Author contributions

Kouki Tada: Writing – original draft. Kei Daizumoto: Writing – review and editing. Masayuki Takahashi: Supervision. Hisanori Uehara: Data curation. Megumi Tsuda: Writing – review and editing. Yoshito Kusuhara: Writing – review and editing. Tomoya Fukawa: Writing – review and editing. Yasuyo Yamamoto: Writing – review and editing. Kunihisa Yamaguchi: Writing – review and editing. Hiro-omi Kanayama: Supervision.

## Conflict of interest

Hiro-omi Kanayama received an honorarium from Takeda Pharmaceutical Company Limited and ONO PHARMACEUTICAL CO., LTD.

Masayuki Takahashi received an honorarium from Merck Biopharma Co., Ltd, Pfizer Inc, MSD K.K., Takeda Pharmaceutical Company Limited, Novartis Pharma K.K., and ONO PHARMACEUTICAL CO., LTD.

## Approval of the research protocol by an Institutional Reviewer Board

The ethical IRB number is 2004.

## Informed consent

Informed consent was obtained from the patient included in the study.

## Editorial Comment

### Editorial Comment on “Recurrent multiple liver metastases of clear cell renal cell carcinoma with a significant response to sunitinib after nivolumab treatment: A case report”

This is an open access article under the terms of the [Creative Commons Attribution](#) License, which permits use, distribution and reproduction in any medium, provided the original work is properly cited.

## Registry and the Registration No. of the study/trial

Not applicable.

## References

- Motzer RJ, Tannir NM, McDermott DF *et al.* Nivolumab plus ipilimumab versus sunitinib in advanced renal-cell carcinoma. *N. Engl. J. Med.* 2018; **378**: 1277–90.
- Rini BI, Plimack ER, Stus V *et al.* Pembrolizumab plus axitinib versus sunitinib for advanced renal-cell carcinoma. *N. Engl. J. Med.* 2019; **380**: 1116–27.
- Motzer RJ, Penkov K, Haanen J *et al.* Avelumab plus axitinib versus sunitinib for advanced renal-cell carcinoma. *N. Engl. J. Med.* 2019; **380**: 1103–15.
- Choueiri TK, Powles T, Burotto M *et al.* Nivolumab plus cabozantinib versus sunitinib for advanced renal-cell carcinoma. *N. Engl. J. Med.* 2021; **384**: 829–41.
- Motzer RJ, Escudier B, McDermott DF. Nivolumab versus everolimus in advanced renal-cell carcinoma. *N. Engl. J. Med.* 2015; **373**: 1803–13.
- Tomita Y, Kimura G, Fukasawa S *et al.* Efficacy and safety of subsequent molecular targeted therapy after immuno-checkpoint therapy, retrospective study of Japanese patients with metastatic renal cell carcinoma (AFTER I-O study). *Jpn. J. Clin. Oncol.* 2021; **51**: 966–75.
- Nadal R, Amin A, Geynisman DM *et al.* Safety and clinical activity of vascular endothelial growth factor receptor (VEGFR)-tyrosine kinase inhibitors after programmed cell death 1 inhibitor treatment in patients with metastatic clear cell renal cell carcinoma. *Ann. Oncol.* 2016; **27**: 1304–11.
- Bando Y, Furukawa J, Terakawa T *et al.* Treatment outcomes of molecular targeted therapy following nivolumab in metastatic renal cell carcinoma. *Jpn. J. Clin. Oncol.* 2021; **51**: 1313–8.
- Barata PC, De Liano AG, Mendiratta P *et al.* The efficacy of VEGFR TKI therapy after progression on immune combination therapy in metastatic renal cell carcinoma. *Br. J. Cancer* 2018; **119**: 160–3.
- Shah AY, Kotecha RR, Lemke EA *et al.* Outcomes of patients with metastatic clear-cell renal cell carcinoma treated with second-line VEGFR-TKI after first-line immune checkpoint inhibitors. *Eur. J. Cancer* 2019; **114**: 67–75.
- Park SE, Lee SH, Ahn JS, Ahn MJ, Park K, Sun JM. Increased response rates to salvage chemotherapy administered after PD-1/PD-L1 inhibitors in patients with non-small cell lung cancer. *J. Thorac. Oncol.* 2018; **13**: 106–11.
- Szabados B, van Dijk N, van der Heijden MS *et al.* Response rate to chemotherapy after immune checkpoint inhibition in metastatic urothelial cancer. *Eur. Urol.* 2018; **73**: 149–52.
- Soda H, Ogawara D, Fukuda T *et al.* Dynamics of blood neutrophil-related indices during nivolumab treatment may be associated with response to salvage chemotherapy for non-small cell lung cancer: a hypothesis generating study. *Thorac. Cancer.* 2019; **10**: 341–6.
- Templeton AJ, Knox JJ, Lin X *et al.* Change in neutrophil-to-lymphocyte ratio in response to targeted therapy for metastatic renal cell carcinoma as a prognosticator and biomarker of efficacy. *Eur. Urol.* 2016; **70**: 358–64.

The advent of tyrosine kinase inhibitors (TKIs) and immune checkpoint inhibitors (ICIs) has increased treatment options for metastatic renal cell carcinoma (mRCC). In this case, a patient with mRCC who received sunitinib as 5th line therapy