

Washington University School of Medicine

Digital Commons@Becker

2020-Current year OA Pubs

Open Access Publications

11-1-2022

Acute-onset, painful, acral granuloma annulare in a 52-year-old female

Faisal S Ahmad

Michael R Vittori

William H McCoy IV

Follow this and additional works at: https://digitalcommons.wustl.edu/oa_4



Part of the [Medicine and Health Sciences Commons](#)

Please let us know how this document benefits you.

Acute-onset, painful, acral granuloma annulare in a 52-year-old female



Faisal S. Ahmad, BA,^a Michael R. Vittori, MD,^b and William H. McCoy IV, MD, PhD^a

Key words: acute-onset painful acral granuloma annulare; AOPAGA; GA; granuloma; granuloma annulare; histiocyte; painful; rash.

INTRODUCTION

Granuloma annulare (GA) most commonly presents as annular plaques on the hands or feet. On histology, this disease is defined by the presence of a palisaded or interstitial lymphohistiocytic infiltrate, mucin deposition, and collagen alteration.¹ Localized, generalized, and subcutaneous GA is frequently encountered, but rarer GA variants also exist.¹ Acute-onset, painful, acral GA (AOPAGA) is a rarely reported localized GA variant.² Here, we present a 52-year-old AOPAGA patient.

CASE REPORT

A 52-year-old female with a past medical history significant for migraines, transient ischemic attack, iron deficiency anemia, gastroesophageal reflux disease, and multinodular goiter presented in April 2021 with a multi-year history of intermittent, painful, bilateral, finger rash. The rash consisted of tender papules that limited her normal daily activities. Lesions progressed proximally along her fingers but stayed distal to the metacarpophalangeal joints. Lesions appeared without a clear trigger and resolved without intervention. During this time, the patient also developed distal interphalangeal and ankle arthralgias.

Prior to being seen in our clinic, the patient underwent an autoimmune, infectious, and malignancy workup (Supplementary Table I, available via Mendeley at <https://doi.org/10.17632/yn3r6bd7bf.2>) that did not identify a cause for her rash and arthralgias. She was given betamethasone valerate

Abbreviations used:

AOPAGA:	acute-onset, painful, acral granuloma annulare
GA:	granuloma annulare

0.1% cream and clobetasol propionate 0.05% ointment for her rash. After 6 weeks of use, there was no improvement, which led the patient to seek evaluation at our institution.

In our clinic, the patient reported no personal or family history of similar dermatologic findings or rheumatologic conditions. While experiencing her hand rash in June 2020, she did report a subjective increase in the size of her thyroid nodules, though her thyroid-stimulating hormone and T4 were normal at that time (Supplementary Table I, available via Mendeley at <https://doi.org/10.17632/yn3r6bd7bf.2>). Her medications included omeprazole, ferrous sulfate, cardioprotective aspirin, cholecalciferol, naproxen, rizatriptan, promethazine, and metaxalone. She had no history of tobacco use.

Physical examination revealed slightly violaceous, mildly indurated, thin papules on the palmar/glabrous surfaces of the right and left fingers (Fig 1, A and B). Punch biopsies of the newest and oldest lesions demonstrated lymphocytes and histiocytes around and between collagen bundles, an associated perivascular lymphocytic infiltrate, and no notable neutrophilic infiltrate (Fig 1, C and D). The dermatopathologist's diagnosis based on these

From the Division of Dermatology, Department of Medicine, Washington University School of Medicine, St. Louis, Missouri^a; and Department of Medicine, Rhode Island Hospital, The Warren Alpert Medical School of Brown University, Providence, Rhode Island.^b

Funding sources: NIH, United States grants: KL2TR002346, UL1TR002345, 5K08AR076464-03.

IRB approval status: Not applicable.

Consent: Written consent was given to the authors for the publication of patient photographs and medical information in print and online with the understanding that this information will be publicly available.

Correspondence to: William H. McCoy IV, MD, PhD, Division of Dermatology, Department of Medicine, Washington University, 660 S Euclid Ave, St. Louis, MO 63110-1010. E-mail: mccoy@wustl.edu.

JAAD Case Reports 2022;29:127-30.
2352-5126

© 2022 by the American Academy of Dermatology, Inc. Published by Elsevier, Inc. This is an open access article under the CC BY-NC-ND license (<http://creativecommons.org/licenses/by-nc-nd/4.0/>).

<https://doi.org/10.1016/j.jidcr.2022.08.050>

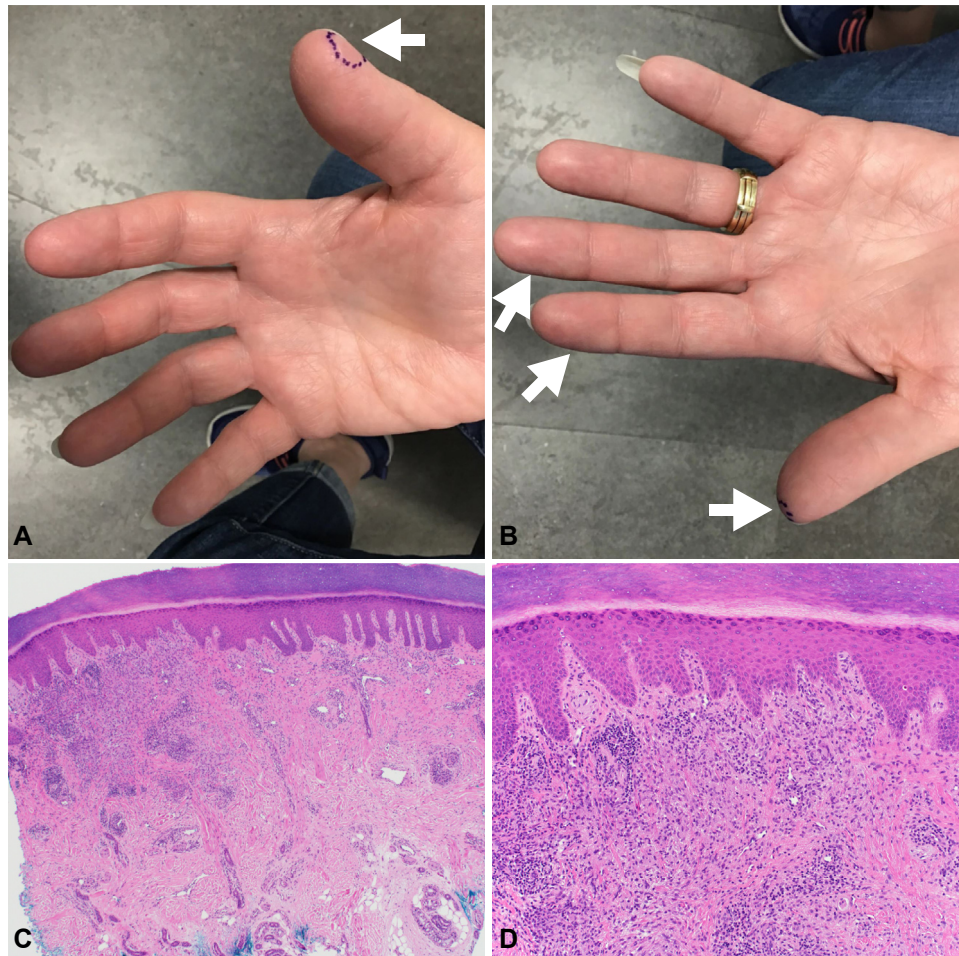


Fig 1. Acute-onset, painful, acral granuloma annulare clinical images and histology. **A** and **B**, Painful, slightly violaceous, thin papules on the palmar/glabrous surfaces of the fingers. The (**A**—right thumb) newest and (**B**—left thumb) oldest lesions were marked in *purple* and biopsied. AOPAGA lesions are indicated by *white arrows* (**A**—right hand, tip of digit 1; **B**—left hand, tips of digits 1-3). **C** and **D**, Granulomatous, lymphohistiocytic inflammation in the dermis of the patient's biopsy specimen is shown at (**C**) 40 \times and (**D**) 100 \times magnification. Lymphocytes and histiocytes are arranged around bundles of collagen. AOPAGA, Acute-onset, painful, acral granuloma annulare.

biopsies was granulomatous dermatitis with findings most suggestive of GA. These histology findings were similar to those of a right distal thumb biopsy of the patient's hand rash performed by an outside provider in November 2020. The histopathology observed in our patient's multiple finger biopsies mirrors that described in published reports of palmar GA.²⁻⁵

In conjunction with the patient's biopsies, a repeat inflammatory workup (erythrocyte sedimentation rate, C-reactive protein, antinuclear antibodies) was obtained to determine if the patient's arthralgias represented an evolving autoimmune process. These labs were normal. Based on this patient's clinical, laboratory, and biopsy findings, alternate

diagnoses for this patient's presentation were ruled out (Supplementary Table II, available via Mendeley at <https://doi.org/10.17632/yn3r6bd7bf.2>).

A diagnosis of AOPAGA was made, and the patient was treated with a 7-week prednisone taper starting at 50 mg daily. The patient's AOPAGA resolved within 2 weeks but recurred at prednisone doses below 40 to 45 mg/day. An extended prednisone course (40 mg/day for 2 months followed by a 4-week prednisone taper) was started to overlap with the initiation of methotrexate as a steroid-sparing therapy for GA.

The patient then decided to not pursue methotrexate therapy or any other steroid-sparing treatment. She was lost to follow-up for 1 year. After

Table I. Summary of AOPAGA cases

First author (year)	Patient (age, sex)	GA location(s)*	Systemic symptoms	Successful treatment	Significant Comorbidities
Barksdale SK (1994) ⁶	75, male	Fingers [†]	Not reported	Not reported	Lymphoma
Barksdale SK (1994) ⁶	66, female	Fingertips [‡]	Not reported	Not reported	Lymphoma
Barksdale SK (1994) ⁶	60, female	Dorsal hands	Not reported	Not reported	Lymphoma
Brey NV (2006) ²	42, female	Hands [§] , legs, feet	Arthralgias of knees and ankles	Hydroxychloroquine sulfate	None
Brey NV (2006) ²	50, female	Lateral hands , dorsal hands	None	Intralesional triamcinolone, fluticasone propionate cream, nicotinamide-folic acid-zinc oxide combination	Not reported
Brey NV (2006) ²	48, female	Dorsal hands, marginal hands, wrists, upper and lower extremities, trunk, occipital scalp	Diffuse arthralgias	Hydroxychloroquine sulfate, hydrocortisone acetate/pramoxine, hydrochloride lotion	Not reported
Brey NV (2006) ²	65, female	Upper and lower palms	None	Prednisone, betamethasone dipropionate ointment	Not reported
Haushalter K (2007) ⁷	36, female	Palms, fingertips	None	Not reported	None
Spencer B (2007) ⁸	72, female	Palms	None	Dapsone	Not reported
Gutte R (2012) ³	Patient 1	Palms	None	Not reported	Not reported
Gutte R (2012) ³	Patient 2	Palms	None	Not reported	Not reported
Gutte R (2012) ³	Patient 3	Palms	None	Not reported	Not reported
Gutte R (2012) ³	Patient 4	Palms	None	Not reported	Not reported
Huh JW (2016) ⁴	57, female	Fingers [§] , legs	Febrile sensations, myalgia, back pain	None identified [¶]	None
Sonthalia S (2014) ⁵	44, male	Palms, soles	None	Clobetasol ointment	None
Rai T (2017) ⁹	55, female	Palms, soles	None	Prednisone, clobetasol, levocetirizine	Not reported
Hsing MT (2018) ¹⁰	37, female	Dorsal foot	Migrating joint pain, myalgia	Prednisone, fluocinonide cream	IDA, Meniere's disease
Ahmad FS (2022)	52, female	Palms, fingertips	Arthralgias	Prednisone	IDA, multinodular goiter, GERD, migraines, TIA, osteopenia

• This case report.

AOPAGA, Acute-onset, painful, acral granuloma annulare; GA, granuloma annulare; GERD, gastroesophageal reflux disease; IDA, iron-deficiency anemia; TIA, transient ischemic attack.

*Glabrous/volar skin is highlighted in Bold.

[†]Fingers were assumed to be acral but not necessarily glabrous/volar (eg, palms/soles).

[‡]Fingertip and lateral hand lesions are presumed to be on glabrous/volar hand (ie, equivalent to palms/soles).

[§]Images included lesions on palmar/volar/glabrous skin.

^{||}Individual patient information (eg, age, sex) was not available in this case series.

[¶]Intermittent treatment with oral prednisolone did not effectively manage this patient's AOPAGA as new cutaneous lesions persistently developed.

contact was re-established, the patient reported that her AOPAGA had recurred off prednisone, but that she did not wish to pursue further treatment.

DISCUSSION

AOPAGA was first described by Brey et al² in 2006. This rare variant of localized GA is characterized by the abrupt formation of tender papules and annular plaques primarily on the hands and feet. In our patient, a diagnosis of AOPAGA was made via clinicopathological correlation.

While GA commonly involves the dorsal hands/feet, the volar/glabrous surfaces are typically spared. Formation of GA lesions on palmar skin, as seen in our patient, is exceptionally rare.^{1,3} Among the 4 cases included in the original description of AOPAGA, Brey et al reported 2 patients with lesions on the palms.² Including this case report's patient, 18 AOPAGA cases have now been reported, with 14 cases noting AOPAGA involvement of volar/glabrous hand skin (eg, palms, fingertips) and 9 cases reporting AOPAGA exclusively on volar/glabrous hand skin (Table I).²⁻⁹

We hypothesize that the propensity of AOPAGA to exclusively appear on volar/glabrous hand skin (50% of AOPAGA cases) suggests an environmental trigger may initiate AOPAGA. Further, we hypothesize that the high level of sensory innervation in volar/glabrous skin underlies the unique painful presentation of AOPAGA. Other subtypes of GA are typically asymptomatic or only mildly painful/pruritic.¹ Systemic symptoms (eg, arthralgias, myalgias) have been observed in 5 of the 18 AOPAGA patients (Table I), which has previously led to the hypothesis that this condition represented an early manifestation of autoimmune disease.^{2,4,10} Our patient's progressive ankle and distal interphalangeal joint pain temporally coincided with the development of her palmar lesions, but no other evidence of autoimmune disease was identified. Most AOPAGA cases have not reported systemic symptoms or autoimmune disease, though 11% of AOPAGA patients had a history of iron-deficiency anemia and 17% of AOPAGA patients had lymphoma.

Associations with systemic conditions (eg, diabetes, thyroid disease, HIV, dyslipidemia, and malignancy) have been described for GA.¹ Our patient's normal laboratory workup did not support an association between a systemic condition (eg, iron-deficiency anemia, lymphoma, thyroid disease)

and ongoing AOPAGA. As our case lacked laboratory data (1) immediately prior to, and (2) near the start of our patient's AOPAGA, we cannot say whether a systemic disease (eg, iron-deficiency anemia) might initiate but then not be required to sustain AOPAGA. Based on our assessment of all published AOPAGA cases, we recommend that an AOPAGA patient be evaluated for lymphoma and iron-deficiency anemia. Further, we suggest that providers consider (1) a diagnosis of AOPAGA in patients who present with painful, volar/glabrous lesions, and (2) treating AOPAGA with a systemic therapy to alleviate the impact of this disease's painful presentation on activities of daily living.

Conflicts of interest

None disclosed.

REFERENCES

- Piette EW, Rosenbach M. Granuloma annulare: clinical and histologic variants, epidemiology, and genetics. *J Am Acad Dermatol*. 2016;75(3):457-465. <https://doi.org/10.1016/j.jaad.2015.03.054>
- Brey NV, Malone J, Callen JP. Acute-onset, painful acral granuloma annulare: a report of 4 cases and a discussion of the clinical and histologic spectrum of the disease. *Arch Dermatol*. 2006;142(1):49-54. <https://doi.org/10.1001/archderm.142.1.49>
- Gutte R, Kothari D, Khopkar U. Granuloma annulare on the palms: a clinicopathological study of seven cases. *Indian J Dermatol Venereol Leprol*. 2012;78(4):468-474. <https://doi.org/10.4103/0378-6323.98078>
- Huh JW, Jeong YI, Choi KH, Park HJ, Jue MS. A case of acute-onset, painful acral granuloma annulare. *Ann Dermatol*. 2016;28(1):119-120. <https://doi.org/10.5021/ad.2016.28.1.119>
- Sonthalia S, Arora R, Sarkar R, Khopkar U. Papular granuloma annulare of palms and soles: case report of a rare presentation. *F1000Res*. 2014;3:2-7. <https://doi.org/10.12688/f1000research.3-32.v1>
- Barksdale SK, Pernicario C, Halling KC, Stickler JG. Granuloma annulare in patients with malignant lymphoma: clinicopathologic study of thirteen new cases. *J Am Acad Dermatol*. 1994;31(1):42-48. [https://doi.org/10.1016/S0190-9622\(94\)70133-4](https://doi.org/10.1016/S0190-9622(94)70133-4)
- Haushalter K, Hughey L, Foster W, Croitrou A. Painful acral nodules as a manifestation of interstitial granuloma annulare. *J Am Acad Dermatol*. 2007;56(2):AB57. <https://doi.org/10.1016/j.jaad.2006.10.300>
- Spencer B, Butler D. Painful palmar granuloma annulare responsive to dapsone. *J Am Acad Dermatol*. 2007;56:AB48.
- Rai T. Papular granuloma annulare of palms and soles. *Indian Dermatol Online J*. 2017;8(6):511-513. https://doi.org/10.4103/idoj.IDOJ_338_16
- Hsing MT, Tsai YY, Hsu HT. Acute-onset, painful acral granuloma annulare with unusual microcalcification. *Australas J Dermatol*. 2018;59(4):e291-e294. <https://doi.org/10.1111/ajd.12821>