

Washington University School of Medicine

Digital Commons@Becker

---

2020-Current year OA Pubs

Open Access Publications

---

11-1-2022

## Durable melanoma control following disseminated talimogene laherparepvec herpetic infection

Leonid Shmuylovich

Aubriana M McEvoy

Ryan C Fields

Leonel Hernandez-Aya

George Ansstas

*See next page for additional authors*

Follow this and additional works at: [https://digitalcommons.wustl.edu/oa\\_4](https://digitalcommons.wustl.edu/oa_4)



Part of the [Medicine and Health Sciences Commons](#)

Please let us know how this document benefits you.

---

---

**Authors**

Leonid Shmuylovich, Aubriana M McEvoy, Ryan C Fields, Leonel Hernandez-Aya, George Ansstas, and David Y Chen

# Durable melanoma control following disseminated talimogene laherparepvec herpetic infection



Leonid Shmuylovich, MD, PhD,<sup>a</sup> Aubriana M. McEvoy, MD, MS,<sup>a</sup> Ryan C. Fields, MD,<sup>b</sup> Leonel Hernandez-Aya, MD,<sup>c</sup> George Anstas, MD,<sup>d</sup> and David Y. Chen, MD, PhD<sup>a</sup>

**Key words:** disseminated herpes infection; durable response; melanoma; talimogene laherparepvec; T-VEC.

## INTRODUCTION

Talimogene laherparepvec (T-VEC) is a genetically modified, live herpes simplex virus type 1 (HSV-1) oncolytic therapy that was the United States Food and Drug Administration-approved in 2015 as monotherapy for unresectable melanoma.<sup>1</sup> Although modifications to the HSV-1 genome result in attenuation of viral pathogenicity, localized herpetic infections following T-VEC administration have been reported both in initial clinical trials and rare cases.<sup>2,3</sup> Although T-VEC-induced disseminated herpes infection, particularly in the setting of immunosuppression, is a theoretical adverse effect, disseminated herpes infection because of T-VEC administration has been suggested only in 1 case report.<sup>4</sup> Here, we report the clinical course of 1 patient who developed disseminated herpes infection following their first T-VEC injection. Following infection resolution, the patient experienced prolonged melanoma control without further therapy.

## CASE REPORT

A 96-year-old woman presented to medical oncology and dermatology for recurrent melanoma on the lower portion of the right extremity. Her right plantar foot primary melanoma was initially biopsied 3 years prior with a Breslow thickness of >4.2 mm with ulceration and elevated mitoses. Wide local excision with 2-cm gross margins was performed soon after, which demonstrated a residual melanoma (2.7-mm thickness, ulcerated and mitogenic) with

### Abbreviations used:

HSV: herpes simplex virus  
T-VEC: talimogene laherparepvec

negative surgical margins. Sentinel lymph node biopsy result and imaging studies were negative for metastatic disease (initial stage IIC; T4bN0M0). Three years after the initial diagnosis, she developed a nodule on the medial aspect of the right thigh. Positron emission tomography-computed tomography demonstrated multiple new 2-deoxy-2-[18F] fluoro-D-glucose-avid lesions in the lower portion of the right extremity and right external iliac lymph nodes consistent with recurrent melanoma. She was otherwise well and desired treatment. The multidisciplinary tumor board consensus plan was to treat this patient with T-VEC, followed by systemic checkpoint blockade in the case of progression.

The first cycle of T-VEC (1mL of 10<sup>6</sup> pfu/mL) was administered to a single right thigh lesion. Within 48 hours, the patient developed a fever of 100.3 °F which was attributed to symptoms commonly seen after T-VEC administration. Although her initial fever improved with acetaminophen, her temperature spiked to 103.3 °F around 72 hours after T-VEC administration, and she developed progressive lethargy and anorexia. The clinical evaluation demonstrated elevated transaminases (aspartate aminotransferase, 91 U/mL and alanine aminotransferase, 68 U/mL) and leukocytosis

From the Division of Dermatology,<sup>a</sup> and Division of Oncology, Department of Medicine,<sup>d</sup> and Department of Surgery, Washington University School of Medicine, St. Louis, Missouri<sup>b</sup>; and Division of Medical Oncology, Department of Medicine, University of Miami, Coral Gables, Florida.<sup>c</sup>

Drs Shmuylovich and McEvoy contributed equally to this article. Funding sources: None.

IRB approval status: Not applicable.

Correspondence to: David Y. Chen, MD, PhD, Division of Dermatology, Department of Medicine, Washington University

School of Medicine, 660 S. Euclid Ave, St. Louis, MO 63110.

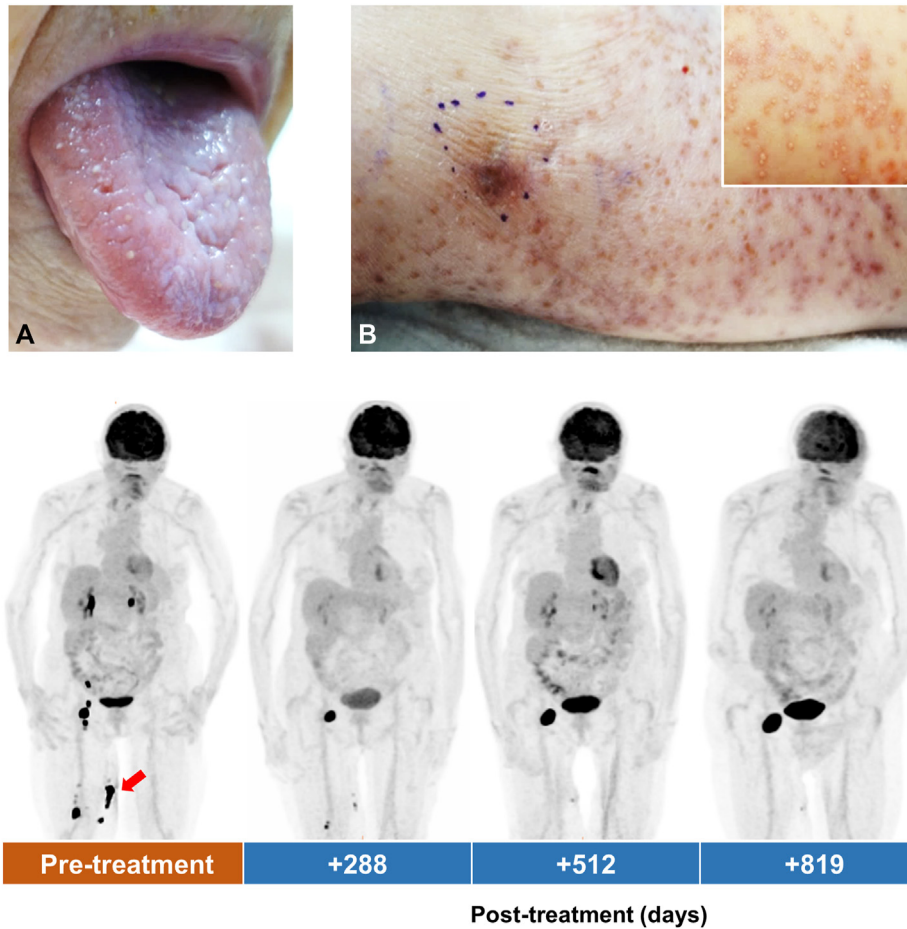
E-mail: [davidchen@wustl.edu](mailto:davidchen@wustl.edu).

JAAD Case Reports 2022;29:131-3.

2352-5126

© 2022 by the American Academy of Dermatology, Inc. Published by Elsevier, Inc. This is an open access article under the CC BY-NC-ND license (<http://creativecommons.org/licenses/by-nc-nd/4.0/>).

<https://doi.org/10.1016/j.jidcr.2022.09.012>



**Fig 1.** Clinical response to talimogene laherparepvec (T-VEC) administration. **A**, Painful lingual vesicles developed 8 days following right thigh intralesional administration T-VEC. **B**, Rash on right thigh developed 12 days after right thigh intralesional T-VEC administration (*inset*, initial vesicular morphology), resolving rash extends beyond the site of T-VEC administration (*purple marker* denotes palpable lesion). **C**, Positron emission tomography-computed tomography demonstrates 2-deoxy-2-[18F] fluoro-D-glucose avid, biopsy-proven melanoma before therapy (treated lesion, *red arrow*) with follow-up scans at indicated intervals.

(17,700 cells/mm<sup>3</sup>; notable for an absolute neutrophil count of 15.7 cells/mm<sup>3</sup> and eosinophilia of 1500 cells/mm<sup>3</sup>), while chest radiograph, bacterial blood cultures, viral nasopharyngeal multiplex polymerase chain reaction, and urinalysis did not suggest an infectious etiology. Her symptoms improved after intravenous fluid administration in the clinic, and she was discharged home.

Eight days after T-VEC administration, she developed painful lingual vesicles. She reported no prior history of cold sores, although her HSV exposure status before treatment was unknown. Twelve days after the T-VEC therapy, she developed a vesicular rash on the right thigh (Fig 1, A and B). Viral polymerase chain reactions from the oral lesions, skin lesions, and blood were all HSV-1 positive. The

manufacturer provided quantitative polymerase chain reaction testing confirmed T-VEC strain HSV-1 in her oral mucosa, thigh lesions, and blood samples (220,000,000; 302,000; and 7140 T-VEC copies/mL, respectively). She was treated with a 10-day course of oral valacyclovir, with normalization of laboratory test findings and resolution of the herpetic rash.

After recovering from disseminated HSV, positron emission tomography-computed tomography studies demonstrated the decreased size and 2-deoxy-2-[18F] fluoro-D-glucose avidity of right inguinal lymphadenopathy and medial aspect of the thigh subcutaneous nodules. She continued to experience decreasing melanoma burden despite receiving no further therapy. Although her right

inguinal melanoma has slowly grown over 2 years of observation after a single dose of T-VEC, she continues to have durable control of her melanoma (Fig 1, C).

## DISCUSSION

T-VEC is an important tool in the treatment of advanced melanoma. The pivotal T-VEC trial demonstrated a modest 16.3% durable response rate and an overall response rate of 26.4%,<sup>1</sup> whereas the final analysis of the OPTiM trial (phase 3, T-VEC vs granulocyte-macrophage colony-stimulating factor) reported an overall response of 31.5% and the durable response of 19%.<sup>5</sup> In more recent trials reflecting real-world usage, patients treated with T-VEC achieved higher overall response rates ranging from 38% to 88.5%.<sup>6-8</sup> The rate of adverse effects because of T-VEC administration was very low in these studies, and cases of cutaneous and mucosal herpetic lesions were reported.<sup>1,2</sup> Recently, a case of disseminated HSV following T-VEC administration was reported, with HSV-1 DNA identified from oral ulcer swabs and lumbar spinal fluid, although T-VEC strain quantitative polymerase chain reaction was not performed.<sup>4</sup> T-VEC bioavailability and viral shedding during a typical treatment course were studied in detail.<sup>2</sup> Nearly all patients (59/60) had detectable T-VEC DNA in their blood, with 72% (43/60) having detectable T-VEC DNA in the blood after cycle 1. Interestingly, HSV-1 seronegative patients appeared to be more likely to have detectable T-VEC DNA after cycle 1 than HSV-1 seropositive patients (14/17, 82% vs 27/40, 68%). Cutaneous or mucosal suspected herpetic lesions were present in 19 of 60 patients during the study period, whereas only 3 patients had lesional T-VEC DNA detected. Among study patients, no cases of disseminated herpetic infection were reported.

Although T-VEC DNA was detected in the blood of patients in earlier T-VEC trials, very few have developed distant herpetic lesions or systemic syndromes. This likely reflects the attenuated nature of T-VEC and the effectiveness of host immunity. Although the patient, in this case, was not overtly immunocompromised, her advanced age may have conferred an altered immune state, which limited her ability to mount an effective immune response against the expected T-VEC viremia initially after the treatment. Over time, she developed an immune response to her melanoma with a notable abscopal effect as evidenced by the regression of multiple, untreated lesions and the relative stability of her

metastatic recurrence over 2 years without further melanoma therapy. Immunosenescence has been proposed as a complex array of changes in adaptive and innate immunity arising in the elderly that result in functional immune suppression, balanced by a countervailing low-grade inflammatory state.<sup>9</sup> This patient's systemic response to disseminated T-VEC infection may have counteracted this state and initiated an immunologic state of tumor elimination and finally, equilibrium.<sup>10</sup>

This case provides compelling evidence that disseminated HSV infection is a possible, and potentially serious, adverse event after intralesional T-VEC therapy that is treatable with oral valacyclovir. The exceptional tumor response in this patient should spur future studies, evaluating pretreatment biomarkers associated with optimal T-VEC response.

## Conflicts of interest

None disclosed.

## REFERENCES

1. Andtbacka RH, Kaufman HL, Collichio F, et al. Talimogene laherparepvec improves durable response rate in patients with advanced melanoma. *J Clin Oncol*. 2015;33:2780-2788.
2. Andtbacka RHI, Amatruda T, Nemunaitis J, et al. Biodistribution, shedding, and transmissibility of the oncolytic virus talimogene laherparepvec in patients with melanoma. *EBioMedicine*. 2019;47:89-97.
3. Chesney J, Awasthi S, Curti B, et al. Phase IIIb safety results from an expanded-access protocol of talimogene laherparepvec for patients with unresected, stage IIIB-IVM1c melanoma. *Melanoma Res*. 2018;28:44-51.
4. Kimmis BD, Luu Y, Dai H. Disseminated herpes infection following talimogene laherparepvec administration. *JAMA Dermatol*. 2022;158(4):456-457.
5. Andtbacka RHI, Collichio F, Harrington KJ, et al. Final analyses of OPTiM: a randomized phase III trial of talimogene laherparepvec versus granulocyte-macrophage colony-stimulating factor in unresectable stage III-IV melanoma. *J Immunother Cancer*. 2019;7:145.
6. Franke V, Berger DMS, Klop WMC, et al. High response rates for T-VEC in early metastatic melanoma (stage IIIB/C-IVM1a). *Int J Cancer*. 2019;145:974-978.
7. Louie RJ, Perez MC, Jajja MR, et al. Real-world outcomes of talimogene laherparepvec therapy: a multi-institutional experience. *J Am Coll Surg*. 2019;228:644-649.
8. Perez MC, Zager JS, Amatruda T, et al. Observational study of talimogene laherparepvec use for melanoma in clinical practice in the United States (COSMUS-1). *Melanoma Manag*. 2019;6:MMT19.
9. Nikolich-Zugich J. The twilight of immunity: emerging concepts in aging of the immune system. *Nat Immunol*. 2018;19:10-19.
10. Dunn GP, Old LJ, Schreiber RD. The three Es of cancer immunoeediting. *Annu Rev Immunol*. 2004;22:329-360.