

Washington University School of Medicine

Digital Commons@Becker

---

2020-Current year OA Pubs

Open Access Publications

---

8-1-2023

## An experimental model of chronic severe mitral regurgitation

Martha M O McGilvray

Tari-Ann E Yates

Lynn Pauls

Meghan O Kelly

Nicholas Razo

*See next page for additional authors*

Follow this and additional works at: [https://digitalcommons.wustl.edu/oa\\_4](https://digitalcommons.wustl.edu/oa_4)



Part of the [Medicine and Health Sciences Commons](#)

Please let us know how this document benefits you.

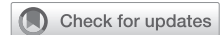---

---

**Authors**

Martha M O McGilvray, Tari-Ann E Yates, Lynn Pauls, Meghan O Kelly, Nicholas Razo, Stacie McElligott, Glenn J Foster, Jie Zheng, Jonathan K Zoller, Christian Zemlin, and Ralph J Damiano Jr

# Unidirectional reversed Potts shunt with reinforced valved femoral vein homograft



Mahmut Ozturk, MD, Aybala Tongut, MD, Manan Desai, MD, Yves d'Udekem, MD, PhD, and Can Yerebakan, MD, PhD, Washington, DC

From the Children's National Hospital, The George Washington University School of Medicine and Health Sciences, Washington, DC.

Disclosures: The authors reported no conflicts of interest.

The *Journal* policy requires editors and reviewers to disclose conflicts of interest and to decline handling or reviewing manuscripts for which they may have a conflict of interest. The editors and reviewers of this article have no conflicts of interest.

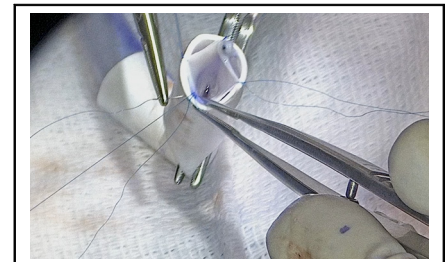
Received for publication Oct 12, 2022; accepted for publication Oct 18, 2022; available ahead of print Nov 2, 2022.

Address for reprints: Can Yerebakan, MD, PhD, Department of Cardiac Surgery, Children's National Hospital, The George Washington University School of Medicine and Health Sciences, 111 Michigan Ave NW, Washington, DC 20010 (E-mail: [cyerebakan@childrensnational.org](mailto:cyerebakan@childrensnational.org)).

JTCVS Techniques 2023;17:164-5  
2666-2507

Copyright © 2022 The Author(s). Published by Elsevier Inc. on behalf of The American Association for Thoracic Surgery. This is an open access article under the CC BY-NC-ND license (<http://creativecommons.org/licenses/by-nc-nd/4.0/>).

<https://doi.org/10.1016/j.jtc.2022.10.014>



Femoral vein homograft reinforced with a PTFE conduit.

## CENTRAL MESSAGE

Reinforced femoral vein homograft could be a viable alternative in creating rPS and lessen the risk of infective endocarditis and need for anticoagulation.

▶ Video clip is available online.

The surgical treatment of drug-refractory idiopathic pulmonary arterial hypertension at the level of the interatrial septum has been the choice of treatment until the emergence of the reversed Potts shunt (rPS). Since its introduction, rPS has been used in an increasing frequency, even as an alternative to lung or heart–lung transplantation in symptomatic patients with suprasystemic pulmonary arterial pressures to mimic Eisenmenger's physiology beyond supra-aortic vessels. Although confined to small cohorts, initial results with this approach have been promising, with prompt improvement in right ventricular systolic function, quality of life, and prolonged survival<sup>1,2</sup>; however, the indication and the optimal technical approach remain obscure. The latest alteration to the classic rPS was the creation of a unidirectional valved shunt (UVS), which unloads the right ventricle and prevents bidirectional shunting in early systole as the result of delayed right ventricular contraction or ventricular desynchronization that is observed in pulmonary hypertension.<sup>3</sup> Surgically, this was performed by sewing a bovine jugular vein graft into a standard polytetrafluoroethylene graft. Herein, we present a novel UVS design with a 10-mm femoral vein graft in a 10-mm Gore-Tex graft (W. L. Gore & Associates, Inc) in a symptomatic patient with refractory pulmonary hypertension and chronic lung disease.

## METHODS

A waiver of documented consent was granted by the Children's National Hospital Institutional Review Board. The patient was a 12-year-old girl with pulmonary hypertension associated with a moderate-sized atrial septal defect, history of low birth weight (500 g), prematurity (24 weeks), and chronic lung disease. At 1 year of age, she had been admitted to the hospital due to respiratory syncytial virus infection, which had necessitated venovenous extracorporeal membrane oxygenation. She presented to our hospital with markedly reduced exercise capacity (New York Heart Association functional class III) and asthma-like symptoms despite triple therapy with selective IP prostacyclin-receptor agonist, phosphodiesterase-5 inhibitor, and endothelin receptor antagonist.

Surgery was performed via median sternotomy. Cardiopulmonary bypass was established through routine aorta-bicaval cannulation, and the patient was cooled down to 28 °C. Following aortic crossclamping and antegrade Custodiol cardioplegia, a large ostium secundum atrial septal defect was closed through right atriotomy with a CardioCel neo patch (LeMaitre Vascular) using a continuous 5-0 PROLENE suture (Ethicon). A 4-mm fenestration was performed on the patch, through which the left heart was deaired. After the removal of the crossclamp, a valved rPS that was already prepared using a 10-mm femoral vein homograft with a valved section was inserted into a 10-mm Gore-Tex graft (Video 1). After measurement of the length, the vein graft was sutured on both ends to the Gore-Tex graft using 7-0 PROLENE in a continuous fashion. A few fenestrations were created on the Gore-Tex graft to prevent compression due to possible bleeding between the homograft and Gore-Tex tube. On cardiopulmonary bypass, the descending aorta and the isthmus region were side clamped, with continuous near-infrared spectroscopy monitoring of the lower body. Following an appropriate incision, the Potts shunt graft was sutured to the descending aorta distal to the subclavian artery using a 6-0 C1

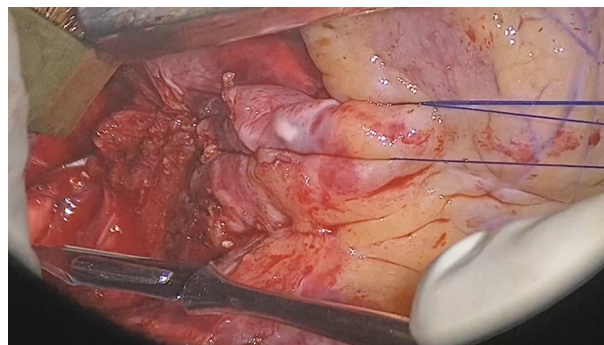
suture. Then, the proximal part was attached to the main pulmonary artery using a 6-0 PROLENE suture. Postoperative transesophageal echocardiogram revealed a good left ventricular function, moderately depressed right ventricular function similar to the preoperative level, and right-to-left blood flow through the Potts shunt. A delayed chest closure was performed later. The patient was discharged home on the 13th postoperative day and was doing well on her last follow-up at 3 months.

## DISCUSSION

In patients with refractory pulmonary hypertension with infra- or systemic pulmonary arterial pressures and exercise intolerance, placement and bidirectional flow through the rPS could potentially worsen right ventricular function and pulmonary hypertension. Initial experiences with UVS with flap-valves or jugular vein homografts have been promising. Considering the increased infective endocarditis risk of bovine jugular venous valved conduits and the potential need for anticoagulation after rPS surgery, we preferred using a reinforced cryopreserved valved femoral vein graft as an alternative. We have previously published our experience with this graft in the right ventricular outflow tract position, which has yielded comparable results with aortic or pulmonary homografts.<sup>4</sup> Therefore, we suggest the consideration of reinforced femoral vein grafts for the creation of rPS, although longer follow-up with a larger group of patients is warranted to determine the durability of this conduit and the prognosis of the patients.

## CONCLUSIONS

Unidirectional rPS can alleviate the worsening of the right ventricular function and pulmonary circulation due to the intermittent bidirectional flow through the aortopulmonary shunt in patients with pulmonary hypertension with infra- or systemic pulmonary artery pressures. In addition to the previous rPS designs with flap valves or jugular vein homografts, a femoral vein homograft could be a viable alternative and lessen the risk of infective



**VIDEO 1.** An alternative for unidirectional reversed Potts shunt—Gore-Tex–reinforced cryopreserved valved femoral vein homograft. Video available at: [https://www.jtcvs.org/article/S2666-2507\(22\)00540-5/fulltext](https://www.jtcvs.org/article/S2666-2507(22)00540-5/fulltext).

endocarditis and need for anticoagulation. When reinforced with a PTFE conduit, sustained valve integrity under systemic pressures can be expected.

## Acknowledgments

We would like to thank our talented medical illustrator Sofia Hanabergh, MSc for assisting us with the video preparation.

## References

1. Aggarwal M, Grady RM, Choudhry S, Anwar S, Eghtesady P, Singh GK. Potts shunt improves right ventricular function and coupling with pulmonary circulation in children with suprasystemic pulmonary arterial hypertension. *Circ Cardiovasc Imaging*. 2018;11:e007964.
2. Baruteau A-E, Belli E, Boudjemline Y, Laux D, Lévy M, Simonneau G, et al. Palliative Potts shunt for the treatment of children with drug-refractory pulmonary arterial hypertension: updated data from the first 24 patients. *Eur J Cardiothorac Surg*. 2015;47:e105-10.
3. Rosenzweig EB, Ankola A, Krishnan U, Middlesworth W, Bacha E, Bacchetta M. A novel unidirectional-valved shunt approach for end-stage pulmonary arterial hypertension: early experience in adolescents and adults. *J Thorac Cardiovasc Surg*. 2021;161:1438-46.e2.
4. Sinha L, Mota L, Ozturk M, Staffa SJ, Zurakowski D, Jonas RA, et al. Cryopreserved valved femoral vein homografts for right ventricular outflow tract reconstruction in infants. *J Thorac Cardiovasc Surg Open*. 2020;4:58-65.