



## CASE REPORT / ПРИКАЗ БОЛЕСНИКА

## Rare case of myelodysplastic syndrome with near-tetraploidy and *TP53* mutation

Nataša Čolović<sup>1,2</sup>, Vesna Đorđević<sup>1</sup>, Milica Radojković<sup>2,3</sup>, Teodora Karan-Đurašević<sup>4</sup>, Nataša Tošić<sup>4</sup>

<sup>1</sup>University Clinical Center of Serbia, Clinic of Hematology, Belgrade, Serbia;

<sup>2</sup>University of Belgrade, Faculty of Medicine, Belgrade, Serbia;

<sup>3</sup>Dr. Dragiša Mišović Clinical Hospital Center, Clinic of Internal Medicine, Belgrade, Serbia;

<sup>4</sup>University of Belgrade, Institute of Molecular Genetics and Genetic Engineering, Belgrade, Serbia

### SUMMARY

**Introduction** Chromosomal numerical aberrations are very common in hematological malignancies, but near-tetraploidy (80-104 chromosomes) is rare in myeloid lineage malignancies, with only a few cases reported in myelodysplastic syndrome (MDS). Due to a small number of cases with this rare cytogenetic abnormality, clinicopathological significance of near-tetraploidy in MDS is still unknown. In this case report we present a case of *de novo* MDS patient with near-tetraploidy in association with *TP53* mutation, and we aimed to elucidate the prognostic significance of this rare genetic feature.

**Case outline** In August of 2018, a 71-year-old male presented with severe anemia, thrombocytopenia, leucopenia, and enlarged spleen. Laboratory data were as follows: hemoglobin (Hb) 93 g/L, white blood cells  $2.8 \times 10^9/L$  and platelets  $23 \times 10^9/L$ . The bone marrow aspirate was hypercellular, megakaryocytes were not found, 15% of granulocytic cells were with signs of dysplasia, and 16% of blast cells without Auer rods. The finding was in correlation with diagnosis of MDS, type refractory anemia with excess blasts 2 which was also confirmed by immunophenotyping. Cytogenetic finding was near-tetraploidy (48,XY+mar[10]/92,XXYY[10]), and *TP53* mutational analysis showed the presence of mutation in exon 8 (p.D281A; c.842 A > C). The patient received from time-to-time packed red blood cells and platelets, and died four months after initial diagnosis.

**Conclusion** Near-tetraploidy associated with *TP53* mutation has been described only in few MDS cases. Results of these reports including ours suggest that the association of *TP53* mutation and near-tetraploidy is a poor prognostic factor.

**Keywords:** near-tetraploidy; *TP53* mutation; myelodysplastic syndrome; prognosis

### INTRODUCTION

Myelodysplastic syndromes (MDS) are a group of clonal hematopoietic stem cell malignancies characterized by ineffective hematopoiesis, bone marrow dysplasia, peripheral blood cytopenia and by intrinsic risk of acute myeloid leukemia (AML) transformation [1]. Chromosomal abnormalities may be numeric and structural and can be found in about 50% of primary MDS and in around 80% patients with secondary MDS after chemotherapy or some toxic agents [2, 3]. Chromosomal abnormalities can vary from a single chromosome abnormality such as monosomy, to a complex karyotype. Numerical abnormality like near-tetraploidy (80-104 chromosomes) is rare in myeloid lineage hematologic malignancies like MDS and it is associated with poor outcome [4]. In addition to pretreatment karyotype being essential for risk stratification and treatment of MDS patients, in recent years the influence of mutations detected in over 89% of cases, has been making its impact on the prognostic stratification model [5]. Mutations in *TP53* gene detected in around 10% of novel MDS cases has been shown to have independent adverse prognostic effect [6].

Here, we report the case of a 71-year-old man diagnosed with MDS, with near-tetraploidy accompanied with *TP53* mutation.

### CASE REPORT

In August 2018, a 71-year-old man, with a history of diabetes mellitus and hypertension, in presented with severe anemia, thrombocytopenia, leucopenia, and enlarged spleen with diameter  $159 \times 64$  mm on ultrasonography. He was admitted at the University Clinical Center of Serbia, Clinic of hematology on under the suspicion of evolution of MDS in AML, Eastern Cooperative Oncology Group performance status 2, and Hematopoietic Cell Transplantation-Comorbidity Index 1.

Laboratory findings were: hemoglobin (Hb) 93 g/L, white blood cells (WBC)  $2.8 \times 10^9/L$ , platelets  $23 \times 10^9/L$  (leukocyte formula: segmented 11%, lymphocytes 70%, monocytes 2%, eosinophils 3%, basophils 11%, metamyelocytes 1%, blasts 2%, erythroblasts 7/100 WBC). Biochemical analyses were: glycaemia 9.3 mmol/l, total bilirubin  $33 \mu\text{mol/L}$ , ferritin 547 ng/ml, fibrinogen 5.87 g/L, d-dimer 1.29 mg/L. Virology, human immunodeficiency virus, Hepatitis B surface antigen and Hepatitis C were negative.

The bone marrow aspirate was hypercellular, megakaryocytes were not found, granulocytic cells were 15% with signs of dysplasia, hypogranular and hyposegmented Pelgeroid-like neutrophil element, with 16% of blast cells,

**Received • Примљено:**

July 28, 2023

**Revised • Ревизија:**

October 29, 2023

**Accepted • Прихваћено:**

October 30, 2023

**Online first:** November 8, 2023

**Correspondence to:**

Nataša TOŠIĆ

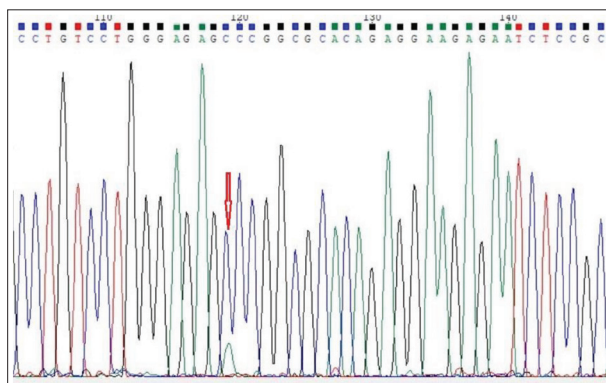
University of Belgrade  
Institute of Molecular Genetics  
and Genetic Engineering  
Laboratory for Molecular  
Biomedicine

Vojvode Stepe 444a

11042 Belgrade

Serbia

[natasa.tosic@imgge.bg.ac.rs](mailto:natasa.tosic@imgge.bg.ac.rs)



**Figure 1.** Direct sequencing of exon 8 of *TP53* gen amplified by polymerase chain reaction; the red arrow shows heterozygous, missense mutation at the position 842 (A-green, to C-blue; c.842A > C), resulting in the substitution of amino-acid at the position 281 (Asp to Ala; p.D281A); it has been reported in the COSMIC (Catalogue of somatic mutations in cancer) data base by number COSM11665

without Auer rods, 40% of blast cells were myeloperoxidase positive, erythroid cell line 62% striking was megaloblastic, with presence of two to three nucleoli in erythroblasts with signs of vacuolization. The finding was in correlation with diagnosis of MDS, type refractory anemia with excess blasts (RAEB 2). Immunophenotyping of bone marrow cells done by flow cytometry, showed positivity for HLA-DR, CD34, CD71, CD38, CD200, CD123, cMPO, clizozime, CD117, CD3, CD22. This results also correlated with diagnosis of RAEB 2.

Cytogenetic finding was 48,XY+mar[10]/92,XXYY[10]. Molecular analyses of *SFB3B1* and *TP53* gene was done using polymerase chain reaction followed by direct sequencing [7, 8]. The patient was *SFB3B1* negative, but in *TP53* gene we detected a single mutation in exon 8 (p.D281A; c.842 A > C) (Figure 1). The diagnosis of MDS, type RAEB 2 was confirmed with Eastern Cooperative Oncology Group performance status 2 and Hematopoietic Cell Transplantation-Comorbidity Index 1. The patient was unwilling for intensive treatment with chemotherapy. In further course he received from time-to-time packed red blood cells and platelets. He died in December 2018.

All procedures performed were in accordance with the ethical standards of the institutional and/or national research committee and with the 1964 Helsinki Declaration and its later amendments or comparable ethical standards.

## DISCUSSION

MDS is a highly heterogeneous group of disorders with numerous genetic aberrations. Cytogenetic findings are important prognostic factor incorporated in almost all prognostic scoring systems. Presence of three or more chromosomal anomalies is regarded as complex karyotype which can be associated with progression of MDS to AML. Comparing the karyotype in acute leukemias and MDS, numeric aberrations dominate in MDS while in acute leukemias structural aberrations are dominant. Balanced cytogenetic abnormalities, including reciprocal

translocations, inversions and insertions, are prevalent in myeloid leukemias but are uncommon in MDS, in which unbalanced numeric chromosomal abnormalities reflecting a gain or loss of chromosomal material are more prevalent [3].

Numeric chromosomal abnormality near-tetraploidy could be found in 1.2% of AML, but only in 0.57% of MDS patients [9, 10]. Tumor suppressor gene *TP53* is located on the short arm of chromosome 17(17p13) [9]. *TP53* gene encodes p53 protein which is main regulator of cellular homeostasis, cellular division, DNA-damage replication and apoptosis [9, 11]. *TP53* overexpression may precede to a change of diploidy to tetraploidy state of the cell population, enabling DNA duplication without cell division leading to polyploidy. Near-tetraploidy associated with *TP53* mutation has been described only in four MDS cases [9]. Haase at al. [12] analyzed cytogenetic findings in a cohort of 2072 patients with MDS but there was no one patient with near-triploidy or near-tetraploidy karyotype. In a study on 1576 patients with MDS the incidence of near-triploidy and near-tetraploidy was 0.57% [12]. In this cohort study, the authors have found nine patients with near-triploidy and near tetraploidy karyotype, but association with *TP53* mutation is not described. Among them, eight had only polyploidy, without other aberrations and one had at the same time complex karyotype. In the group of 979 adult patients with different hematological malignancies, association of *TP53* mutation and near-triploidy or near-tetraploidy karyotype was diagnosed in four MDS patients, three with RAEB and one with refractory cytopenia with multilineage dysplasia (RCMD). Patients with RAEB lived two, three, and six months while patient with RCMD lived 18 months.

In conclusion, *TP53* mutation are found in 5–20% patients with MDS, more frequent in high-risk group associated with complex karyotype involving chromosome 5, 7, and 17 causing negative impact on prognosis [13, 14]. However, *TP53* mutations are rarely associated with near-triploidy or near-tetraploidy karyotype. Latest research of MDS genomic landscape showed that *TP53* mutations are frequently associated with aneuploidy and chromothripsis, and not with other MDS “driver” mutations, suggesting that for *TP53* mutations, alterations at chromosome level represent cooperating, “second hit” event, driving MDS towards leukemic transformation [15]. In spite of the small number of reported cases, it is impossible to determine the prognostic impact of the combined occurrence of near-tetraploidy and *TP53* mutation. Based on our case report, we could speculate that it has a poor impact on the prognosis and outcome of the disease.

## ACKNOWLEDGMENTS

This work has been funded by grant from the Ministry of Education, Science and Technological Development, Republic of Serbia (Grant No. 451-03-68/2022-14/200042).

**Conflicts of interest:** None declared.

## REFERENCES

- Arber DA, Orazi A, Hasserjian RP, Borowitz MJ, Calvo KR, Kvasnicka HM, et al.; International Consensus Classification of Myeloid Neoplasms and Acute Leukemias: integrating morphologic, clinical, and genomic data. *Blood*. 2022;140(11):1200–28. [DOI: 10.1182/blood.2022015850] [PMID: 35767897]
- Nguyen-Khac F, Bidet A, Daudignon A, Lafage-Pochitaloff M, Amey G, Bilhou-Nabéra C, et al. The complex karyotype in hematological malignancies: a comprehensive overview by the Francophone Group of Hematological Cytogenetics (GFCH). *Leukemia*. 2022;36(6):1451–66. [DOI: 10.1038/s41375-022-01561-w] [PMID: 35430613]
- Shahjehani M, Hadad EH, Azizidoost S, Nezhad KC, Shahrazi S. Complex karyotype in myelodysplastic syndromes: Diagnostic procedure and prognostic susceptibility. *Oncol Rev*. 2019;13(1):389. [DOI: 10.4081/oncol.2019.389] [PMID: 30858933]
- Veryaskina YA, Titov SE, Kovynov IB, Pospelova TI, Zhimulev IF. Prognostic Markers of Myelodysplastic Syndromes. *Medicina (Kaunas)*. 2020;56(8):376. [DOI: 10.3390/medicina56080376] [PMID: 32727068]
- Saygin C, Godley LA. Genetics of Myelodysplastic Syndromes. *Cancers*. 2021;13(14):3380. [DOI: 10.3390/cancers13143380] [PMID: 34298596]
- Cumbo C, Tota G, Anelli L, Zagaria A, Specchia G, Albano F. TP53 in Myelodysplastic Syndromes: Recent Biological and Clinical Findings. *Int J Mol Sci*. 2020;21(10):3432. [DOI: 10.3390/ijms21103432] [PMID: 32414002]
- Huber S, Haferlach T, Meggendorfer M, Hutter S, Hoermann G, Baer C, et al. SF3B1 mutated MDS: Blast count, genetic abnormalities and their impact on classification and prognosis. *Leukemia*. 2022;36(12):2894–902. [DOI: 10.1038/s41375-022-01728-5] [PMID: 36261576]
- Malcikova J, Tausch E, Rossi D, Sutton LA, Soussi T, Zenz T, et al. ERIC recommendations for TP53 mutation analysis in chronic lymphocytic leukemia—update on methodological approaches and results interpretation. *Leukemia*. 2018;32(5):1070–80. [DOI: 10.1038/s41375-017-0007-7] [PMID: 29467486]
- Wu J, Lin H, Chen C, Luo Y, Dai W, Lin X, et al. [Analysis of genetic and clinical characteristics of nine cases of myelodysplastic syndrome with near tetraploid/tetraploidy karyotype]. *Zhonghua Yi Xue Yi Chuan Xue Za Zhi*. 2020;37(12):1336–9. [Article in Chinese] [DOI: 10.3760/cma.j.cn511374-20191015-00530] [PMID: 33306816]
- Watanabe A, Inokuchi K, Yamaguchi H, Mizuki T, Tanosaki S, Shimada T, et al. Near-triploidy and near-tetraploidy in hematological malignancies and mutation of the p53 gene. *Clin Lab Haematol*. 2004;26(1):25–30. [DOI: 10.1111/j.0141-9854.2003.00574.x] [PMID: 14738434]
- Duarte FB, Lemes RPG, Dos Santos TEJ, Barbosa MC, de Vasconcelos JPL, Rocha-Filho FD, et al. Presence of new mutations in the TP53 gene in patients with low-risk myelodysplastic syndrome: two case reports. *J Med Case Rep*. 2017;11(1):143. [DOI: 10.1186/s13256-017-1301-8] [PMID: 28527473]
- Haase D, Germing U, Schanz J, Pfeilstöcker M, Nösslinger T, Hildebrandt B, et al. New insights into the prognostic impact of the karyotype in MDS and correlation with subtypes: evidence from a core dataset of 2124 patients. *Blood*. 2007;110(13):4385–95. [DOI: 10.1182/blood-2007-03-082404] [PMID: 17726160]
- Weinberg OK, Siddon A, Madanat YF, Gagan J, Arber DA, Dal Cin P, et al. TP53 mutation defines a unique subgroup within complex karyotype de novo and therapy-related MDS/AML. *Blood Adv*. 2022;6(9):2847–53. [DOI: 10.1182/bloodadvances.2021006239] [PMID: 35073573]
- Stengel A, Haferlach T, Baer C, Hutter S, Meggendorfer M, Kern W, et al. Specific subtype distribution with impact on prognosis of TP53 single-hit and double-hit events in AML and MDS. *Blood Adv*. 2023;7(13):2952–6. [DOI: 10.1182/bloodadvances.2022009100] [PMID: 36735768]
- Abel HJ, Oetjen KA, Miller CA, Ramakrishnan SM, Day RB, Helton NM, et al. Genomic landscape of TP53-mutated myeloid malignancies. *Blood Adv*. 2023;7(16):4586–98. [DOI: 10.1182/bloodadvances.2023010156] [PMID: 37339484]

## Мијелодиспластични синдром са приближном тетраплоидијом удруженом са мутацијом гена *TP53* – редак случај

Наташа Чоловић<sup>1,2</sup>, Весна Ђорђевић<sup>1</sup>, Милица Радојковић<sup>2,3</sup>, Теодора Каран-Ђурашевић<sup>4</sup>, Наташа Тошић<sup>4</sup>

<sup>1</sup>Универзитетски клинички центар Србије, Клиника за хематологију, Београд, Србија;

<sup>2</sup>Универзитет у Београду, Медицински факултет, Београд, Србија;

<sup>3</sup>Клиничко-болнички центар „Др Драгиша Мишовић“, Клиника за интерну медицину, Београд, Србија;

<sup>4</sup>Универзитет у Београду, Институт за молекуларну генетику и генетско инжењерство, Београд, Србија

### САЖЕТАК

**Увод** Нумеричке аберације хромозома су веома честе код хематолошких малигнитета, али су приближне тетраплоидије (80–104 хромозома) ретке у малигнитетима мијелодиспластичком синдрому (МДС). Због малог броја случајева са овом ретком цитогенетском абнормалношћу, клиничко-патолошки значај приближне тетраплоидије у МДС-у је још увек непознат. Овим приказом *de novo* болесника са МДС-ом, са приближном тетраплоидијом и мутацијом у гену *TP53*, циљ нам је био да расветлимо прогностички значај ове ретке генетске карактеристике.

**Приказ болесника** Приказан је 71-годишњи болесник који је у августу 2018. године развио симптоме тешке анемије, тромбоцитопеније, леукопеније и увећане слезине. Лабораторијске анализе су показале следеће: хемоглобин 93 g/L, леукоцити  $2,8 \times 10^9/L$  и тромбоцити  $23 \times 10^9/L$ . Аспират коштане сржи је био хиперћелијски, мегакариоцити нису на-

ђени, 15% гранулоцита је било са знацима дисплазије, 16% бласта без Ауерових штапића. Налаз је одговарао дијагнози МДС-а, типа рефракторне анемије са вишком бласта 2, што је потврђено и имунолошком фенотипизацијом. Цитогенетском анализом утврђено је присуство приближне тетраплоидије (48,XY+mar[10]/92,XXYY[10]), а анализа мутација у гену *TP53* показала је присуство мутације у егзону 8 (*p.D281A*; *c.842 A > C*). Болесник је по потреби примао трансфузију еритроцита и тромбоците, а умро је четири месеца након почетне дијагнозе.

**Закључак** Присуство приближне тетраплоидије удружене са мутацијама у гену *TP53* описано је само у неколико случајева МДС-а. Резултати ових случајева, као и наши резултати, указују на то да приближна тетраплоидија повезана са присуством мутација у гену *TP53* представља фактор лоше прогнозе.

**Кључне речи:** приближна тетраплоидија; мутације гена *TP53*; мијелодиспластични синдром; прогноза