

Advantages of Tissue Level Implants in Case of Alveolar Ridge and Mucosal Atrophy

Marika Kublashvili, Professor

Tamar Dolidze, Professor

Grigol Robakidze University, School of Medicine, Georgia

[Doi: 10.19044/esipreprint.12.2023.p199](https://doi.org/10.19044/esipreprint.12.2023.p199)

Approved: 01 December 2023

Posted: 06 December 2023

Copyright 2023 Author(s)

Under Creative Commons CC-BY 4.0

OPEN ACCESS

Cite As:

Kublashvili M. & Dolidze T. (2023). *Advantages of Tissue Level Implants in Case of Alveolar Ridge and Mucosal Atrophy*. ESI Preprints.

<https://doi.org/10.19044/esipreprint.12.2023.p199>

Abstract

In the modern market, there is a great variety of dental implants, which differ from each other in design, geometry, connection type, surface treatment technology, etc. However, the most fundamental and main differentiating component between implants is how the implants are inserted into the bone and how it is positioned in relation to the soft tissues. Accordingly, they are divided into sunken, i.e., bone-level implants, and non-sunken, i.e., tissue-level implants, in which case the implant-abutment connection, or interface, is located at the gum level. This study shows the advantages of tissue-level implants in the case of atrophy of the alveolar ridge and also studies the comparison of bone lost in the case of bone-level implants and tissue-level implants.

Keywords: Tissue level, bone level, epithelium, milled surface, osteointegration, crestal bone

Introduction

Brånemark's studies mainly reflect osteointegration, i.e., the interaction of the implant and the bone tissue. The Swiss scientist Schroeder, who is also one of the most important figures in the world of dental implantology, in the late 70s, got acquainted with Brånemark's research, and he paid attention to the most important factor: the implant, as well as the tooth, which is extracted from the bone and gum, needed to be protected

from the non-sterile environment of the oral cavity. He created a tissue-level implant -- an ideal implant that created the best conditions for soft tissue integration. This implant creates ideal conditions for healing. After its insertion, the rupture of the soft tissue connection does not take place during the entire period of its operation. "The soft tissue barrier at implants and teeth"; Berglundh T, m Lindhe J, Ericsson I, Marinello CP, Liljenberg B, Thomsen P; *Clinical implants Res* 1991; 2:81-90

The height of the supra osseous part in the Schroder implant was 2.8 mm. This part of the implant is made of milled metal. Today, the height of the milled portion of tissue level implants ranges from 1.6-1.8 mm.

During the insertion of a gingival-level implant, the oral epithelium grows and migrates in an apical direction to protect the superstructure of the implant. With the help of hemidesmosomes, the connection-integration between the epithelium and the surface of the implant is established. At the same time, in the space between the alveolar ridge and the implant in the neck area of the implant, granulation tissue is formed, which later transforms into a connective-tissue connection. It prevents the apical growth of epithelium. The connective-tissue junction provides a conduit for the soft-tissue complex. It develops on the rough surface of the implant, and the epithelial junction on the milled surface.

Development and improvement of implant systems, implant design and geometry, and implantation methods have increased the demands and expectations for the mentioned procedure.

Progress in medicine is determined by whether we get the maximum result with minimal intervention. In some cases, the use of gum-level implants allows us to do just that, especially in cases of alveolar folds and soft tissue atrophy on the lower jaw, when it is impossible to achieve a stable result in time without additional surgical intervention. Influence of the size of the microcap on crestal bone changes around titanium implants. A histometric evolution of unloaded non-submerged implants in the canine mandibula; Joachim S, Hermann JS, John D, Schoolfield, Robert K, Schenk, Daniel Buser and David L Cochran. *Journal of Periodontology*. October 2001

Figure 1 (Lower Jaw Distal Defect)

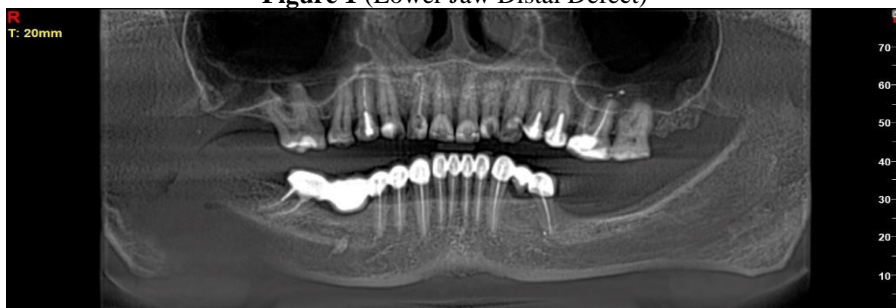

Figure 2 (Inserted Tissue Level Implants)

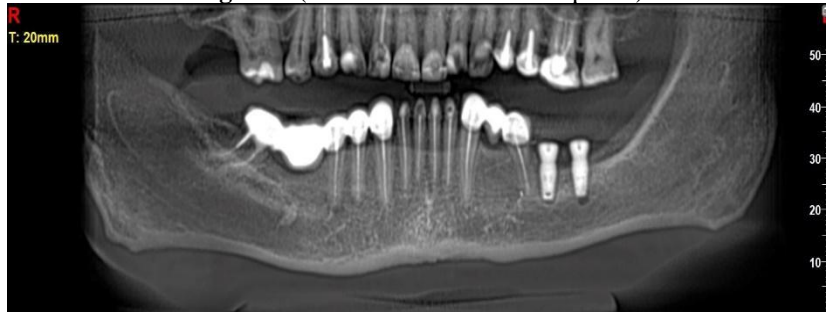


Figure 3 (Dental Implant in Different Layers)

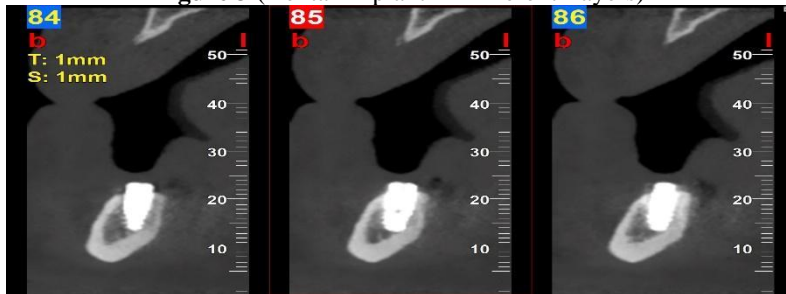

Figure 4 (tissue level implants)

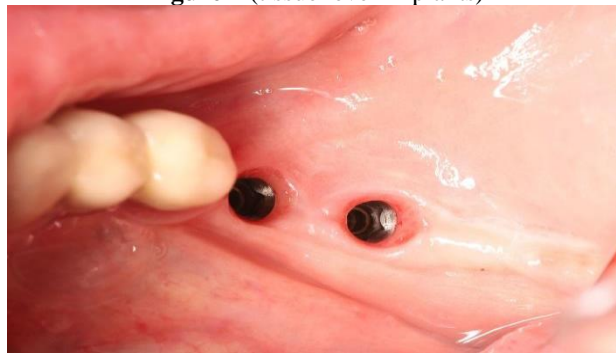
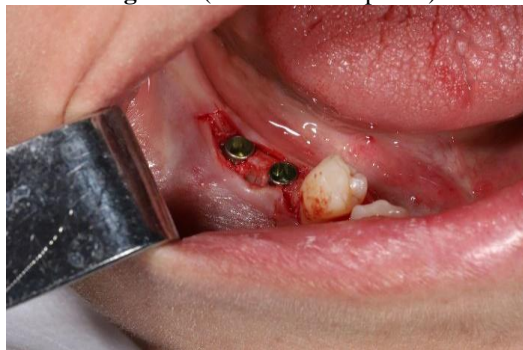
Figure 5 (tissue level implants)



The most important and main component of successful osteo and soft tissue integration is the minimal loss of marginal bone during the tissue remodeling stage.

The results and aim of the research.

The aim of our study was to study the marginal bone loss in mandibular alveolar ridge and soft tissue atrophy using different brands of tissue level implants and to compare it with the rate of bone loss when using bone level implants.

We used different brands of tissue level implants, and the height of the milled part on the bone varied from 1.6 to 1.8 mm. Biologic width around titanium implants. A physiologically formed and stable dimension over time.” Hermann JS, Busar RK, Higginbottom FL, Cochran DL; Clin Oral Imp Res 2000 “Implant-tissue interfaces following treatment of peri-implantitis using guided tissue. “

In recent years, tissue level implants have become less popular. It, like any other implant, is not a universal implant that is recommended to be used in all clinical cases, however, in those specific cases where there is an indication for its use, this type of implant is truly irreplaceable.

The use of implants at the tissue level is not recommended in the aesthetic area, because over time, due to physiological atrophic processes, a milled neck of the implant may be visualized. It is ideal for lateral segment involvement and limb defects, as well as "all on 4" and "all on constructions.

Figure 6 (Edentulous Lower Jaw)

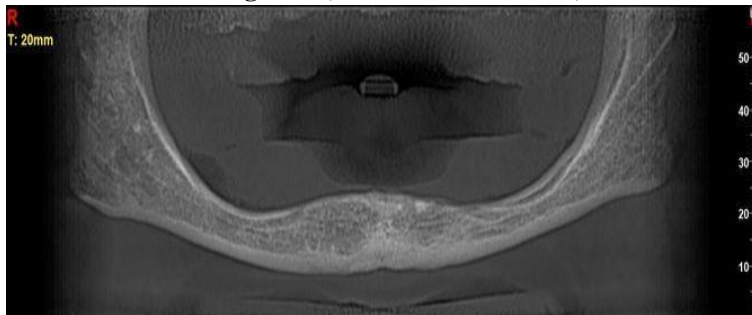


Figure 7 (Construction “all on 4”)

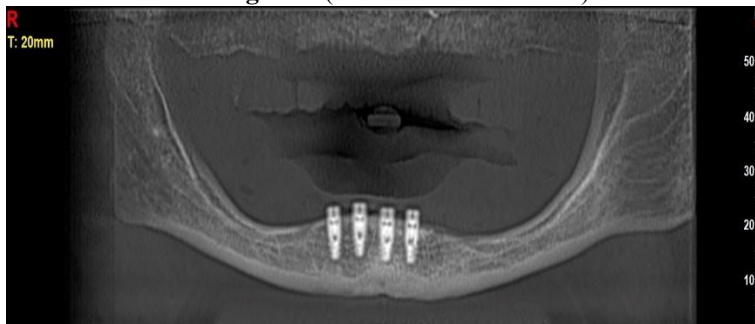
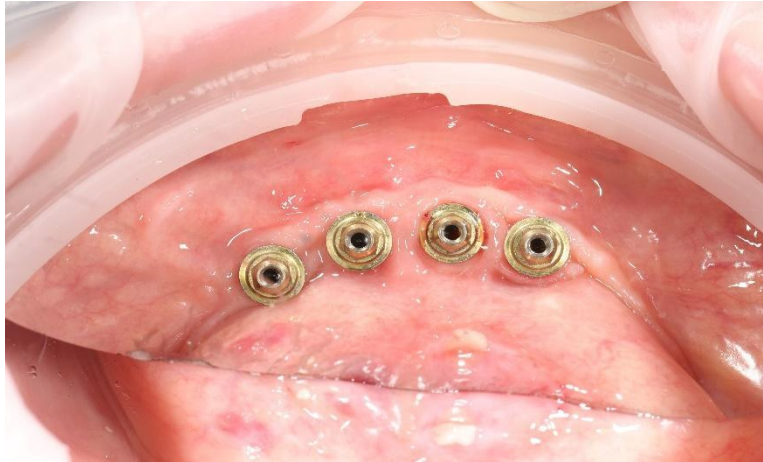
Figure 8 (all on 4 with multiunits)

The advantages of gingival level implants are:\

1. They create ideal conditions for the formation of supracrustal soft tissues. After inserting the implant, the connective tissue and epithelial tissue joints are no longer traumatized because of the removal and insertion of the superstructures, which prevents marginal bone loss.
2. There is a gap (1.8 mm) between the bone edge and the interface of the implant, so micro-movements during loading do not directly affect the marginal bone and do not cause its resorption.
3. In the case of non-submerged implants, the angle of inclination of the restoration cutting profile and its convexity does not represent a danger in the development of peri-implantitis and marginal bone loss.

Conclusion

Based on the above, gingival level implants are an ideal choice for alveolar folds and mucosal atrophy on the lower jaw, when short (<8mm) implants must be inserted. When keratinized mucosa is no longer present, geometric support of the implant is essential to ensure a stable result with less traumatic intervention and minimal cost.

Our study found that 4 months after implant placement, the average bone loss in the test group was 0.3 mm, and in the control group it was 1.28 mm. The study found that marginal bone loss with tissue level implants was an average of 1 mm less than with bone level implants, and the average bone loss was 0.3 mm. Thus, this implant is an alternative to other implants in case of atrophied mandible, both in the case of the total edentulous jaw in "all on 4" and "all on 6" constructions, as well as in the presence of lateral segmental and distal defects.

Human Studies

All procedures performed in studies involving human participants were in accordance with the ethical standards of the institutional and/or national research committee and with the 1964 Helsinki Declaration and its later amendments or comparable ethical standards.

Funding Statement: The authors did not obtain any funding for this research.

Data Availability: All the data are included in the content of the paper.

Conflict of Interest: The authors reported no conflict of interest.

References:

1. Biologic width around titanium implants. A physiologically formed and stable dimension over time.” Hermann JS, Busar RK, Higginbottom FL, Cochran DL; Clin Oral Imp Res 2000
2. “Implant-tissue interfaces following treatment of peri-implantitis using guided tissue regeneration. A light and microscopic study” Schupbach P, Hurzeler W, & Grunder U, (1994). Clinical oral implants research
3. Influence of thin mucosal tissues on crestal bone stability around implants with platform switching; A 1-year pilot study” Tomas Linkevicius, peteris Apse, Simonas Grybauskas, Algirdas Puisys; J Oral maxillofacSurg 2010.
4. Influence of the size of the micro gap on crestal bone changes around titanium implants. A histometric evaluation of unloaded non-submerged implants in the canine mandibula; Joachim S, Hermann JS, John D, Schoolfield, Robert K, Schenk, Daniel Buser and David L Cochran. Journal of Periodontology. October 2001
5. Microleakage into and from two-stage implants; An in vitro comparative study; Wendel Teixeira, Ricardo Faria Ribeiro, Sandra Sato, Vinicius Pedrazzi. The international Journal of oral & maxillofacial implants. July 2011.
6. Momen A. Atieh, Hadeel M, Ahmad H. Atieh; “Platform switching for marginal bone preservation around dental implants; A systematic review and meta-analysis” J periodontal 2010.
7. “The soft tissue barrier at implants and teeth”; Berglundh T, mLindhe J, Ericsson I, Marinello CP, Liljenberg B, Thomsen P; Clinical implants Res 1991; 2:81-90
8. The peri-implant Sulcus Compared with internal implant and superstructure components: A microbiological analysis. Jan Cosyn,

- Louis Van Aelst, Bruno Collaert, G Rutger Persson, Hugo De Bruyn; Clinical implant dentistry and related research 2011.
9. “Ultrastructural Study of the attachment of human gingiva to titanium vivo” T.R Gould, L. Westbury, D.M Brunette J Prosthetic Dent 1984
 10. The influence of soft tissue thickness on crestal bone changes around implants: A1-year prospective controlled clinical trial”; Tomas Linkevicius, Peteris Apse, Simonas Grybauskas, Algirdas Puisys; INT J ORAL MAXILLOFAC IMPLANTS-2009.
 11. The influence of submerged healing abutment or subcrestal implant placement on soft tissue thickness and crestal bone stability. A 2-year randomized clinical trial. Tomas Linkevichus, Algirdas Puisys, Rokas Linkevicius, Jonas Alkimavicius, Evelina Gineviciute, Laura Linkeviciuce: Clin implant dent relate res 2020.
 12. “Ultrastructural Study of the attachment of human gingiva to titanium vivo” T.R Gould, L. Westbury, D.M Brunette J Prosthetic Dent 1984