



## Surgical Decompression of Thoracic Ossification of the Posterior Longitudinal Ligament through Posterior Approach: A Case Report

Majid Reza Farrokhi<sup>1,2</sup>, Seyed Reza Mousavi<sup>1,2</sup>, Mohammad Reza Tamjidi<sup>1,2</sup>, Saeed Tayebi Khorami<sup>1,2</sup>, Abbas Khosravi Farsani<sup>1,2</sup>, Jaloliddin Mavlonov<sup>1,2</sup>, Hamid Jangi Aghdam<sup>1,2</sup>, Armin Akbarzadeh<sup>3\*</sup>

<sup>1</sup>Shiraz Neuroscience Research Center, Shiraz University of Medical Sciences, Shiraz, Iran

<sup>2</sup>Department of Neurosurgery, School of Medicine, Shiraz University of Medical Sciences, Shiraz, Iran

<sup>3</sup>Bone and Joints Diseases Research Center, Department of Orthopedic Surgery, School of Medicine, Shiraz University of Medical Sciences, Shiraz, Iran

\*Corresponding author: Armin Akbarzadeh

Address: Bone and Joints Diseases Research Center, Department of Orthopedic Surgery, School of Medicine, Shiraz University of Medical Sciences, Postal code: 14117-18541, Shiraz, Iran. e-mail: armin.akbarzadeh@ymail.com

Received: May 12, 2023

Revised: June 23, 2023

Accepted: August 18, 2023

### ► ABSTRACT

Thoracic ossification of the posterior longitudinal ligament (OPLL) is a rare condition that is mainly accompanied by cervical OPLL or ossification of thoracic ligamentum flavum. In case of causing neurological manifestations, it is preferred to treat the condition surgically. Several surgical procedures were introduced, including anterior, posterior, or combined approaches. Laminectomy with instrumented fusion is the most popular procedure utilized via the posterior approach. A 32-year-old obese woman, who suffered from back pain and weakness in both lower extremities for one month, was referred to our spine outpatient clinic. Imaging revealed lower thoracic OPLL (T7/T8 & T8/T9 & T9/T10). The posterior longitudinal ligament had a mixed ossification pattern (beaked and continuing cylindrical). To maintain thoracic spine stability and prevent future kyphosis, we performed laminectomy and long segment fixation (T7 to T12). The post-operative neurological examination revealed a considerable increase in muscle strength and significant pain relief.

**Keywords:** Ossification of the posterior longitudinal ligament; Thoracic spine; Surgical treatment; Posterior approach.

Please cite this paper as:

Farrokhi MR, Mousavi SR, Tamjidi MR, Tayebi Khorami S, Khosravi Farsani A, Mavlonov J, Jangi Aghdam H, Akbarzadeh A. Surgical Decompression of Thoracic Ossification of the Posterior Longitudinal Ligament through Posterior Approach: A Case Report. *Bull Emerg Trauma*. 2023;11(4):196-199. doi: 10.30476/BEAT.2023.98867.1443.

### Introduction

Ossification of the posterior longitudinal ligament (OPLL) is a disorder in which calcification of the posterior longitudinal ligament is caused by a number of factors, including obesity,

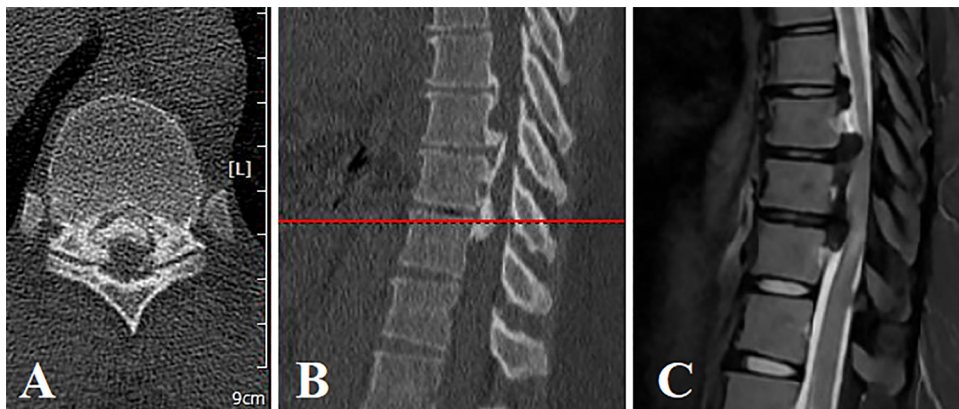
diabetes mellitus, inappropriate sleep habits, and other conditions. OPLL is more prevalent in the cervical spine, which has higher mobility than thoracic vertebrae, which are stabilized by rib articulation [1]. Thoracic OPLL usually combines with cervical OPLL or thoracic ossification

of ligamentum flavum, resulting in numerous neurological impairments depending on the extent of involvement. Both anterior and posterior approaches have been used for many surgical procedures, and each could be applied in particular conditions [1]. In this study, we reported a 32-year-old woman who was diagnosed with OPLL and had surgical treatment in our clinic.

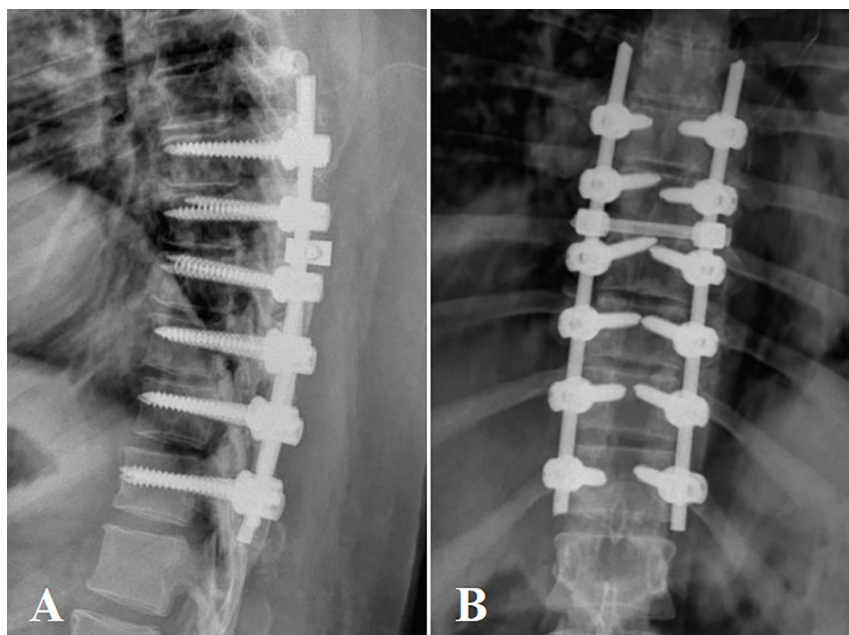
### Case Presentation

A 32-year-old woman who suffered from weakness in both lower extremities and the inability to walk without help for one month was referred to our spine outpatient clinic. It was a progressive course. In neurological examination, the power of both lower extremities was decreased (4/5). Her gait was spastic and walker-assisted. Both plantar reflexes were upward, and deep tendon reflexes showed hyperreflexia. All sensory examinations were normal. The sphincter tone was unchanged. Moreover, she was obese (BMI=40 Kg/m<sup>2</sup>) and had hypertension. Laboratory tests, including complete

blood count (CBC), electrolytes, Erythrocyte sedimentation rate (ESR), C-reactive protein (CRP), and liver function tests (LFT) were carried out. The plain radiographic findings were inconclusive. Therefore, the patient underwent thoracic spine Magnetic Resonance Imaging (MRI). The MRI revealed spinal cord compression at the middle and lower thoracic levels (T7/T8 & T8/T9 & T9/T10) in favor of thoracic OPLL, which was confirmed by CT scan (Figure 1). The posterior longitudinal ligament had a mixed ossification type (beaked and continued cylindrical). After performing complete perioperative evaluations, she underwent laminectomy along with long-segment instrumented fixation from T7 to T12, using 12 pedicular screws and one cross-link (Figure 2). After laminectomy, the quality of decompression was assessed by reducing the dural sac tension and increasing its pulsation and refilling. Intraoperative neurophysiological monitoring was performed during the procedure. Post-operative neurological assessment revealed that muscle power had improved and spasticity was significantly decreased.



**Fig. 1.** Axial (A) and sagittal (B) views of the CT scan reveal T7 to T10 ossification of the posterior longitudinal ligament. The Magnetic Resonance Imaging (MRI) (C) shows hypointense OPLL in the T2 MRI sequence with hypersignal change in the adjacent spinal cord.



**Fig. 2.** Lateral (A) and antero-posterior (B) views of post-operative X-ray radiograph of our case with thoracic ossification of the posterior longitudinal ligament who underwent laminectomy and instrumented fusion from T6 to T11.

## Discussion

The posterior longitudinal ligament ossification is a condition that mostly affects the cervical spine. OPLL can induce neuropathic pain, which can be managed by non-operative methods such as physical therapy and analgesic medications. However, in the case of myelopathy, surgical treatment should be considered [1]. OPLL of the thoracic spinal column is a rare condition that usually manifests as myelopathy [2]. OPLL is not evenly distributed geographically throughout the world, and it is most prevalent in East Asia, particularly Japan. Obesity is one of the most crucial predisposing factors associated with thoracic OPLL. A recent study found a correlation between BMI and the incidence and severity of OPLL [3].

Various surgical methods have been described. The purpose of OPLL surgery is to decompress the spinal cord. The thoracic spine OPLL is less frequent than cervical spine OPLL. However, it is more challenging because of physiologic kyphosis of the upper and middle parts of the thoracic spine, the presence of watershed area in the thoracic spine, and the difficulty of the anterior approach in the thoracic region if demanded [1]. Several surgical methods were introduced for decompression. They are performed via anterior, posterior, or combined approaches. Although the anterior approach provides direct access to OPLL, it has some disadvantages that make it undesirable. Anterior approach has the risk of injury to adjacent respiratory and circulatory organs. In the case of OPLL at multiple levels, it is difficult to extend the anterior approach. Furthermore, many surgeons are unfamiliar with the anterior approach [4]. The posterior approach is a preferred one because of its lower complication rate [5]. Several procedures, including laminoplasty, laminectomy (with or without fixation) [3, 6], concomitant anterior decompression, and dekyphosis surgery are among the options for spinal cord decompression. Our case was suffering from T7/T8 (middle thoracic) and T8/T9 and T9/T10 (lower thoracic) levels. Laminectomy can be used to treat OPLL at lower thoracic levels (T8/T9 to T11/T12). The lower thoracic region is a transitional zone in which thoracic kyphosis alters to lumbar lordosis. Therefore, some suggest that lower thoracic laminectomy does not typically weaken the posterior structural support of the spinal column, and concomitant instrumentation is unnecessary [1]. However, Yamazaki *et al.* [7] reported a case of T10/T11 OPLL that underwent laminectomy and developed paraparesis early post-operatively. The patient was treated using instrumented fusion. As a result, they concluded that the laminectomy had affected stability in their case. In addition to laminectomy, some patients (mainly those with beak-type OPLL) require additional procedures to decompress the spinal cord [4]. The necessity

for additional decompression procedures is determined intra-operatively by observing dural sac tension, pulsation, and refilling. Moreover, in the case of proper decompression, intraoperative ultrasonography can reveal the cord's backward shift and increase the free space between the cord and dural sac [8, 9]. Using sulfur hexafluoride micro-bubble contrast, ultrasonography can assess the blood flow to the spinal cord [10, 11]. In case of incomplete decompression, further procedures such as anterior decompression and dykyphosis are required [12]. Anterior decompression can be applied through a posterior approach by extirpation of OPLL (direct decompression) or floating of the OPLL (indirect decompression) [13]. When OPLL adheres to the dural sac, floating is beneficial. Dekyphosis surgery is another procedure that can indirectly decompress the spinal cord by compressing the adjacent pedicular screws and enhancing the blood flow by shortening the spinal cord at the OPLL level [14].

We performed laminectomy and fixation through a posterior approach. Since our patient was obese and had a comorbid condition (hypertension), we preferred to shorten the time of surgery, and because pre-operative imaging indicated no significant kyphosis of the thoracic spine, we refused to select methods other than laminectomy and fixation. We chose long segment fixation (T7 to T12) to maintain the stability of the thoracic spine and prevent future kyphosis.

## Declaration

**Ethics approval and consent to participate:** The study protocol was approved by the local ethics committee. Informed consent was obtained from the patient.

**Consent for publication:** The authors provide consent for publication.

**Conflict of Interest:** None declared.

**Funding:** None declared.

**Authors' Contributions:** MRF: study concept, data gathering, revision of the manuscript; SRM: revision of the manuscript; MRT: data gathering, preparation of the manuscript; STK: data gathering, preparation of the manuscript; AKF: revision of the manuscript; JM: revision of the manuscript; HJA: revision of the manuscript; AK: interpretation of results, data gathering, preparation of the manuscript.

**Acknowledgment:** The authors would like to thank Shiraz University of Medical Sciences, Shiraz, Iran, and also the Center for Development of Clinical Research of Nemazee Hospital, and Dr. Nasrin Shokrpour for editorial assistance.

## References

1. Hirabayashi S, Kitagawa T, Yamamoto I, Yamada K, Kawano H. Surgical Treatment for Ossification of the Posterior Longitudinal Ligament (OPLL) at the Thoracic Spine: Usefulness of the Posterior Approach. *Spine Surg Relat Res.* 2018;2(3):169-76.
2. Min JH, Jang JS, Lee SH. Clinical results of ossification of the posterior longitudinal ligament (OPLL) of the thoracic spine treated by anterior decompression. *J Spinal Disord Tech.* 2008;21(2):116-9.
3. Li M, Meng H, Du J, Tao H, Luo Z, Wang Z. Management of thoracic myelopathy caused by ossification of the posterior longitudinal ligament combined with ossification of the ligamentum flavum-a retrospective study. *Spine J.* 2012;12(12):1093-102.
4. Matsuyama Y, Yoshihara H, Tsuji T, Sakai Y, Yukawa Y, Nakamura H, et al. Surgical outcome of ossification of the posterior longitudinal ligament (OPLL) of the thoracic spine: implication of the type of ossification and surgical options. *J Spinal Disord Tech.* 2005;18(6):492-7; discussion 8.
5. Bernstein DN, Prong M, Kurucan E, Jain A, Menga EN, Riew KD, et al. National Trends and Complications in the Surgical Management of Ossification of the Posterior Longitudinal Ligament (OPLL). *Spine (Phila Pa 1976).* 2019;44(22):1550-7.
6. Koda M, Furuya T, Okawa A, Inada T, Kamiya K, Ota M, et al. Mid- to long-term outcomes of posterior decompression with instrumented fusion for thoracic ossification of the posterior longitudinal ligament. *J Clin Neurosci.* 2016;27:87-90.
7. Yamazaki M, Mochizuki M, Ikeda Y, Sodeyama T, Okawa A, Koda M, et al. Clinical results of surgery for thoracic myelopathy caused by ossification of the posterior longitudinal ligament: operative indication of posterior decompression with instrumented fusion. *Spine (Phila Pa 1976).* 2006;31(13):1452-60.
8. Gao A, Yu M, Wei F, Jiang L, Liu Z, Liu X. One-stage posterior surgery with intraoperative ultrasound assistance for thoracic myelopathy with simultaneous ossification of the posterior longitudinal ligament and ligamentum flavum at the same segment: a minimum 5-year follow-up study. *Spine J.* 2020;20(9):1430-7.
9. Tat J, Tat J, Yoon S, Yee AJM, Larouche J. Intraoperative Ultrasound in Spine Decompression Surgery: A Systematic Review. *Spine (Phila Pa 1976).* 2022;47(2):E73-e85.
10. Dubory A, Laemmel E, Badner A, Duranteau J, Vicaut E, Court C, et al. Contrast enhanced ultrasound imaging for assessment of spinal cord blood flow in experimental spinal cord injury. *J Vis Exp.* 2015(99):e52536.
11. Yang P, Ge R, Chen ZQ, Wen BT. Treatment of Thoracic Ossification of Posterior Longitudinal Ligament with One-Stage 360 Degree Circumferential Decompression Assisted by Piezosurgery. *J Invest Surg.* 2022;35(2):249-56.
12. Kato S, Murakami H, Demura S, Yoshioka K, Yokogawa N, Takaki S, et al. Indication for anterior spinal cord decompression via a posterolateral approach for the treatment of ossification of the posterior longitudinal ligament in the thoracic spine: a prospective cohort study. *Eur Spine J.* 2020;29(1):113-21.
13. Kanno H, Aizawa T, Hashimoto K, Itoi E, Ozawa H. Anterior decompression through a posterior approach for thoracic myelopathy caused by ossification of the posterior longitudinal ligament: a novel concept in anterior decompression and technical notes with the preliminary outcomes. *J Neurosurg Spine.* 2021:1-11.
14. Imagama S, Ando K, Ito Z, Kobayashi K, Hida T, Ito K, et al. Risk Factors for Ineffectiveness of Posterior Decompression and Dekyphotic Corrective Fusion with Instrumentation for Beak-Type Thoracic Ossification of the Posterior Longitudinal Ligament: A Single Institute Study. *Neurosurgery.* 2017;80(5):800-8.

**Open Access License**

All articles published by Bulletin of Emergency And Trauma are fully open access: immediately freely available to read, download and share. Bulletin of Emergency And Trauma articles are published under a Creative Commons license (CC-BY-NC).