

DOI: 10.4274/ijca.2023.29292

Int J Cardiovasc Acad 2023;9(4):95-98

# Successful Retrieval of Stripped Coronary Stents Using the Twisted Guide Wire Technique

Emrah Kaya, Taner Şen

Department of Cardiology, Kütahya Health Sciences University, Evliya Çelebi Training and Research Hospital, Kütahya, Turkey

## Abstract

Stent stripping during percutaneous coronary intervention is a rare but serious complication. The patient was admitted to the emergency department with chest pain. Electrocardiography revealed ST elevations in the anterolateral leads. The patient was urgently taken to the catheter laboratory. A guiding catheter without a hole was used to imagine the left coronary system. To avoid dumping, two holes were manually drilled into the distal region of the catheter with the needle tip. Occlusion was observed in the proximal region of left anterior descending artery. It was decided to implant a stent. However, when the stent arrived distal in the catheter, strain was felt. When the stent was advanced to the left main coronary artery (LMCA), it was observed that the stent detached from its balloon in the LMCA. It was planned to remove the stent using the twisted guide wire technique. In this technique, the guide wire inside the stripped stent lumen was not retracted. A second guide wire was advanced distally outside the stent lumen. Subsequently, these two parallel wires were twisted 10-15 times until the stent was trapped by the guide wires with the help of the torquer device. Twisted wires were pulled back. While the wires were retrieving, the trapped stent between guide wires was pulled back. Subsequently, a new stent was successfully implanted into the lesion. After the procedure, the damaged catheter and the removed stent were investigated. The distal inner lumen of the guiding catheters not smooth at the edges of the manually opened side holes because of protrusions. It was thought that the stent was stuck to these inner protrusions of the holes and detached from the balloon. Manually drilling a hole in the guiding catheter or any intervention disrupting the structure of the catheter should be avoided. The twisted guide wire technique is an alternative and effective method to retrieve a stripped stent.

**Keywords:** Complication, stent stripping, twisted guide wires

## INTRODUCTION

Stent stripping during percutaneous coronary intervention is a rare but serious complication. This can lead to systemic or coronary embolization, which can result in severe morbidity and mortality.<sup>[1]</sup> Stripping of the stent can lead to emergency coronary bypass surgery, coronary thrombosis, myocardial infarction, cerebrovascular accident, and death. Calcified and angulated lesions increase the risk of stent stripping and embolization.<sup>[2]</sup> Various devices and techniques are used to remove the stripped stent. There is no standard method for removing the embolized stent, and different methods can be

applied depending on the case and the operator. In this case report, we presented a stripped stent due to manual puncture of the back-up guiding catheter and its removal using the twisting guide wire technique. In this case report, we highlight the risk of complications that may arise from manual puncture of the back-up guiding catheter and emphasize the effectiveness of the twisting guide wire technique in retrieving a stripped coronary stent. This case serves as a reminder that even small manual interventions on equipment during a procedure can lead to significant and potentially life-threatening complications.

**To cite this article:** Kaya E, Şen T. Successful Retrieval of Stripped Coronary Stents Using the Twisted Guide Wire Technique. Int J Cardiovasc Acad 2023;9(4):95-98



**Address for Correspondence:** MD Emrah Kaya, Department of Cardiology, Kütahya Health Sciences University, Evliya Çelebi Training and Research Hospital, Kütahya, Turkey  
**E-mail:** dremrah68@gmail.com  
**ORCID ID:** orcid.org/0000-0003-0457-3124

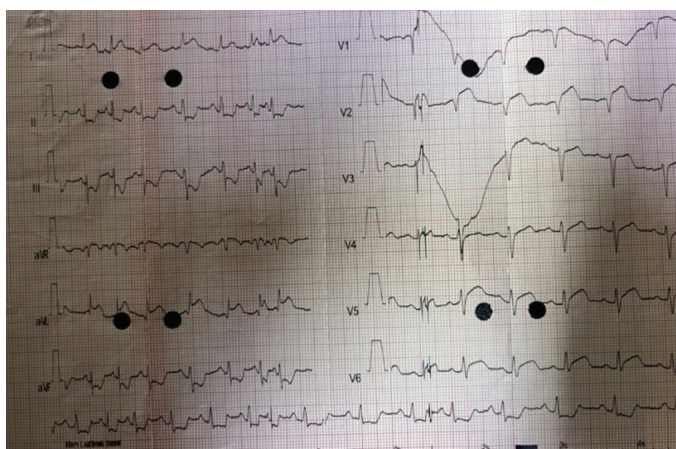**Received:** 15.09.2023  
**Revised:** 15.10.2023  
**Accepted:** 22.10.2023  
**Published Online:** 07.12.2023



©Copyright 2023 by the Cardiovascular Academy Society / International Journal of the Cardiovascular Academy published by Galenos Publishing House. Licensed by Creative Commons Attribution-NonCommercial-NoDerivatives 4.0 (CC BY-NC-ND 4.0)

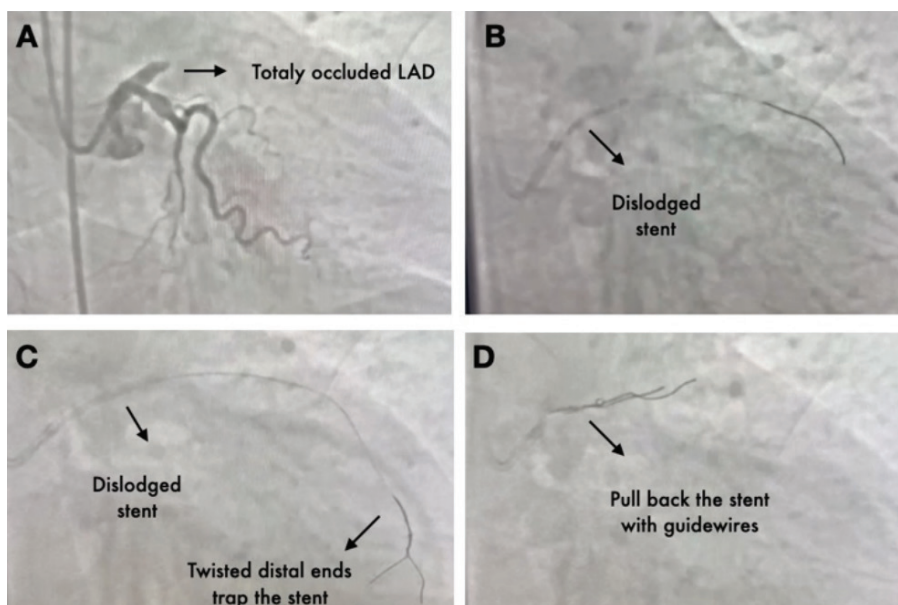
## CASE REPORT

A 68-year-old female patient with a past medical history of hypertension without any cardiac history was admitted to the emergency department with chest pain. Electrocardiography revealed ST elevations in the D1-AVL and V1-V6 leads and reciprocal ST depression in the inferior leads (Figure 1). The patient's blood pressure was found to be 140/85 mmHg, heart rate was 105 beats/min, and physical examination findings were normal. The patient was urgently taken to the catheter laboratory with a diagnosis of acute anterolateral myocardial infarction for primary percutaneous intervention. Ticagrelor



**Figure 1:** Electrocardiography at admission showing ST-segment elevation in D1-AVL, V1-V6 leads

(180 mg), acetyl salicylic acid (300 mg), and unfractionated heparin (100 u/kg) were administered during the procedure. The patient was cannulated with a 7 French (Fr) sheath through the right femoral artery, and a 6 Fr diagnostic right Judkins 4 catheter was advanced. No critical stenosis was observed in the right coronary artery. Later, a 7-Fr extra backup (EBU) 3.5 guiding catheter without a hole was used to visualize the left coronary system. To avoid dumping, two holes were manually drilled into the distal region of the catheter with the needle tip. There was no significant stenosis in the circumflex artery. Occlusion was observed in the proximal region of the left anterior descending artery (LAD). The lesion was crossed with a floppy guide wire (0.014 Asahi). Coronary flow was provided after 2.0x15 mm balloon predilatation. Then, it was decided to implant a 3.5x16 mm drug-eluting stent (DES) (Firehawk; Microport, Shanghai, China). However, when the stent arrived distal in the catheter, strain was felt. When the stent was advanced to the left main coronary artery (LMCA), the stent was detached from its balloon in the LMCA. It was planned to remove the stent using the twisted guide wire technique. In this technique, the guide wire inside the stripped stent lumen was not retracted. A second guide wire was advanced distally outside the stent lumen. Subsequently, these two parallel wires were twisted 10-15 times until the stent was trapped by the guide wires with the help of the torquer device. The twisted wires were then pulled back. While the wires were retrieving back, the trapped stent between guide wires was pulled back (Figure 2). Figure 3 shows the step-by-step twisted guide technique. Subsequently, a new not perforated EBU 3.5 guiding



**Figure 2:** Angiographic views **A.** Totally occluded LAD, **B.** Dislodged stent in LMCA, **C.** Second guide wire was advanced outside the stent lumen and two parallel wires were twisted around each other 10-15 times until the stent was trapped by the guide wires. **D.** While the wires were retrieving back, trapped stent between guide wires was pulled back.

LAD: Left anterior descending artery, LMCA: Left main coronary artery

catheter was advanced to LMCA. Predilatation was applied to the lesion this time with a 2.5x15 mm balloon. Subsequently, a new 3.5x16 mm DES (Firehawk; Microport, Shanghai, China) was successfully implanted into the lesion. Instent postdilatation was performed using a 4.0x12 mm noncompliant balloon, and the procedure was successfully terminated. After the procedure, the damaged catheter and the removed stent were investigated. The distal inner lumen of the guiding catheters not smooth at the edges of the manually opened side holes because of protrusions (Figure 4). It was thought that the stent was stuck to these inner protrusions of the holes and detached from the balloon. During follow-up, the patient had no complaints, the ejection fraction was 55%, and no wall motion

abnormality was observed on echocardiography. The patient was discharged after adjusting the optimal medical treatment, and the patient had no complaints at the next outpatient visit. Written informed consent was obtained from the patient for publication of the case report and the accompanying images.

### DISCUSSION

Stent stripping usually occurs for 3 reasons.<sup>[1]</sup> These are;

1. The stent can be detached from the balloon while the stent is being advanced to the not well predilated coronary artery segment.

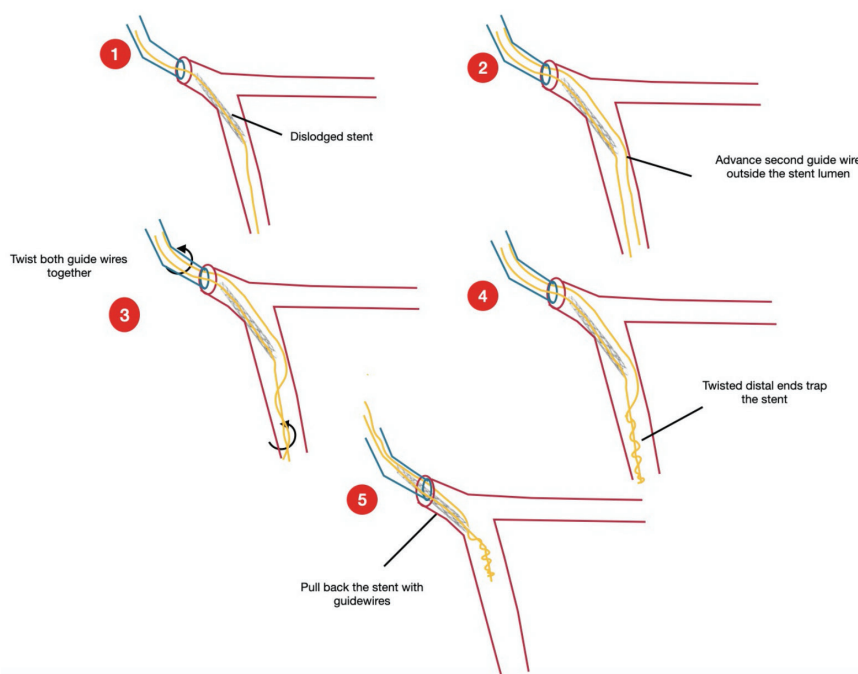


Figure 3: Step by step twisted guide wires technique

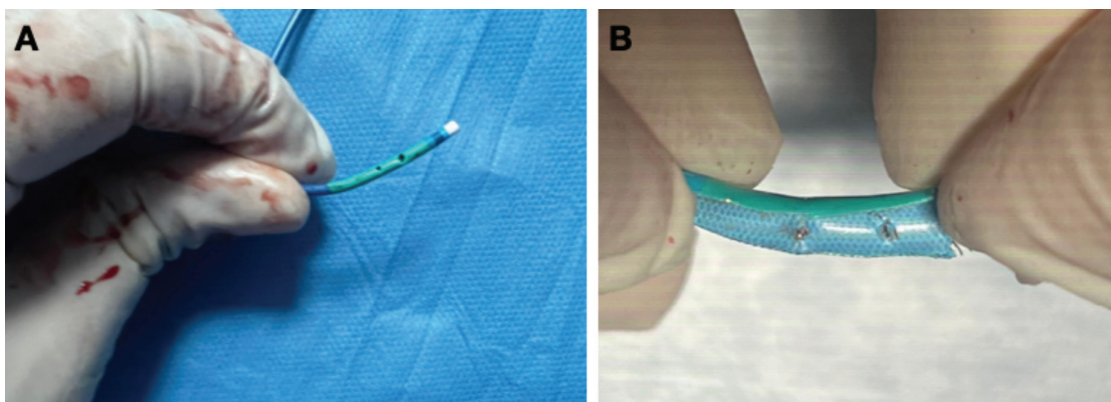


Figure 4: Images of the catheter A. Manually drilled holes on the extra-back up guiding catheter, B. The inner side of the catheter showing protrusions at the edges of the holes

2. The stent may become stuck in the lesion when advancing from the coronary lesion and may be stripped from its balloon when retreating.

3. If the stent was deformed proximally during the procedure or if the catheter was not coaxially cannulated, the stent may be stripped as it was pulled into the catheter. This is why it occurs most often.

However, in our case, because of the unnoticed damage to the inner lumen of the distal end of the catheter when opening a hole in the catheter in a way not included in the literature, the stent was stripped due to inner protrusions of the holes in the catheter while it was entering the main coronary.

When a stent is detached from the balloon in the coronary artery it is necessary to decide what can be done based on the position and condition of the stent. It should be planned to remove the stent back first, but if this is not possible, it should be considered to implant it in a suitable place in the artery. If the stent is to be removed, there are many methods available to retrieve the stripped stent, including gooseneck snare, balloon inflation distal to the stent in a low atmosphere, and the twisted guide wire technique.<sup>[3,4]</sup> In this case, we preferred the twisted guide wire technique, where one of the guide wires is inside the lumen of the stripped stent, while the other guide wire is advanced outside the stent.<sup>[5,6]</sup> The same torque device is attached to the ends of the two guide wires and rotated in the same direction until they twist each other.<sup>[7]</sup> Then, the two wires are pulled back together, and the stent is retrieved using the guide wires.<sup>[8]</sup> The operator should have previous experience with this twisted guidewire technique to decrease the risk of coronary artery damage. The twisting guide wire technique may cause coronary artery dissection. The operator has previous experience with this maneuver to avoid coronary artery dissection because we seek to palliate damage without increasing it. In cases where the stent cannot be retrieved and implanted where it is, it can be attached to the vessel wall with a new stent as a bail-out procedure, but this will increase the metal load. In addition, coronary bypass is an alternative to stent stripping in multi-vessel coronary artery disease involving LAD.<sup>[9]</sup>

## CONCLUSION

Stent stripping is a rare but difficult complication of percutaneous procedures that can cause serious cardiovascular problems. The operator should not force the stent, especially through an angulated and severe calcified coronary artery. Moreover, manually drilling a hole on the guiding catheter or any intervention disrupting the structure of the catheter should be avoided. The twisted guide wire technique is an alternative

and very effective method to retrieve a stripped stent. The technique to be used in the case of an embolized stent should be decided according to the experience of the operator and the patient's condition. It is extremely important to keep the laboratory equipped with equipment that may interfere with stent stripping.

## Ethics

**Informed Consent:** Written informed consent was obtained from the patient for publication of the case report and the accompanying images.

**Peer-review:** Internally peer-reviewed.

## Authorship Contributions

Surgical and Medical Practices: E.K., T.Ş., Concept: E.K., T.Ş., Design: E.K., T.Ş., Data Collection or Processing: E.K., T.Ş., Analysis or Interpretation: E.K., Literature Search: E.K., Writing: E.K., T.Ş.

**Conflict of Interest:** No conflict of interest was declared by the authors.

**Financial Disclosure:** The authors declared that this study received no financial support.

## REFERENCES

1. Brilakis ES, Best PJ, Elesber AA, Barsness GW, Lennon RJ, Holmes DR Jr, *et al.* Incidence, retrieval methods, and outcomes of stent loss during percutaneous coronary intervention: a large single-center experience. *Catheter Cardiovasc Interv* 2005;66:333-40.
2. Kawamura A, Asakura Y, Ishikawa S, Asakura K, Okabe T, Yamane A, *et al.* Extraction of previously deployed stent by an en-trapped cutting balloon due to the blade fracture. *Catheter Cardiovasc Interv* 2002;57:239-43.
3. Cishek MB, Laslett L, Gershony G. Balloon catheter retrieval of dislodged coronary stents: a novel technique. *Cathet Cardiovasc Diagn* 1995;34:350-2.
4. Sentürk T, Ozdemir B, Yeşilbursa D, Serdar OA. Dislodgement of a sirolimus-eluting stent in the circumflex artery and its successful deployment with a small-balloon technique. *Türk Kardiyol Dern Ars* 2011;39:418-21.
5. Wong PH. Retrieval of undeployed intracoronary Palmaz-Schatz stents. *Catheter Cardiovasc Diagn* 1995;35:218-23.
6. Colón-Arias F, Moronta-Franco M, Gutiérrez-Martínez A. Coronary stent embolization during percutaneous coronary intervention: Successful retrieval using twisting guide wire technique by radial approach. *J Cardiol Cases* 2021;23:271-3.
7. Eglin TK, Dickey KW, Rosenblatt M, Pollak JS. Retrieval of intravascular foreign bodies: experience in 32 cases. *AJR Am J Roentgenol* 1995;164:1259-64.
8. Eggebrecht H, Haude M, von Birgelen C, Oldenburg O, Baumgart D, Herrmann J, *et al.* Nonsurgical retrieval of embolized coronary stents. *Catheter Cardiovasc Interv* 2000;51:432-40.
9. Bolte J, Neumann U, Pfafferoth C, Vogt A, Engel HJ, Mehmel HC, *et al.* Incidence, management, and outcome of stent loss during intracoronary stenting. *Am J Cardiol* 2001;88:565-7.