



Should a forgotten guidewire be removed after years? An undesirable complication of hemodialysis catheter wire left in the body

Manouchehr Hekmat¹, Hamid Ghaderi¹, Zahra Ansari Aval^{1*}, Seyedeh Adeleh Mirjafari²,
Roshanak Tirdad³

¹Department of Cardiovascular Surgery, Shahid Beheshti University of Medical Sciences, Tehran, Iran

²Department of Pediatrics, Shahid Beheshti University of Medical Sciences, Tehran, Iran

³Department of Neurology, Shahid Beheshti University of Medical Sciences, Tehran, Iran

ARTICLE INFO

Article Type:
Case Report

Article History:

Received: 15 September 2023

Accepted: 5 November 2023

ePublished: 28 November 2023

Keywords:

Guidewire
Hemodialysis catheter
Seldinger technique
Cardiac surgery

ABSTRACT

Today, one of the most common methods used in the emergency room or intensive care unit (ICU) in patients is the Seldinger technique to access the central venous system, shunting for hemodialysis, intra-aortic balloon pump, or arterial insertion. Accidental leaving of the guide wire is an uncommon but important complication that can occur as a result of an incorrect technique, and it is sometimes found accidentally or due to complications years after the procedure. The case is a 53-year-old patient who underwent aortic valve replacement with a mechanical valve and mitral valve repair with a ring 12 years ago and was treated with warfarin. Two years after the heart surgery, due to chronic renal failure, the patient underwent dialysis, and after the preparation of an arteriovenous fistula, he underwent stenting. After approximately ten years, the patient developed fever, chills, and shortness of breath. During the examination, endocarditis was diagnosed, and a part of the aortic valve was released. There was a severe paravalvular leak in the aortic valve, and an abscess was formed in the aorta root. We also noticed a forgotten guide wire in the superior vena cava, right atrium, inferior vena cava, and hepatic vein, and echogenic masses were located on the guidewire. The diagnosis was confirmed by echocardiography, chest x-ray, and phenocopy. After antibiotic therapy, the patients underwent heart surgery, aortic valve replacement, and aortic root repair, and the guidewire was removed (70 cm long). Unfortunately, despite all measures, the patient died a few days after the surgery. Due to complications, a forgotten guidewire should be removed immediately after diagnosis. The preferred intervention is the removal of the guidewire by endovascular interventions, but surgical treatment should also be considered in some cases.

Implication for health policy/practice/research/medical education:

A forgotten guide wire should be removed immediately after diagnosis. The preferred intervention is the removal of the guidewire by endovascular interventions, but surgical treatment should also be considered in some cases.

Please cite this paper as: Hekmat M, Ghaderi H, Ansari Aval Z, Mirjafari SA, Tirdad R. Should a forgotten guidewire be removed after years? an undesirable complication of hemodialysis catheter wire left in the body. J Nephropharmacol. 2024;13(1):e11649. DOI: 10.34172/npi.2023.11649.

Introduction

The retention of the guidewire occurs where the Seldinger method is utilized, such as the installation of access to the central vein (CV line) (1) or the establishment of hemodialysis or artery line or intra-aortic balloon pump (2,3). These techniques are performed in intensive care unit (ICU) and cardiac surgery rooms, emergency departments, and often for ill patients.

Guidewire loss often occurs due to operator error and remains undisclosed due to fear and concerns about the consequences, and is usually discovered accidentally

after a long time (4) or after the development of related complications. Complications of guide wire loss include the migration of the guide wire to the pulmonary artery (5), guidewire knocking (6), a broken guidewire (7), arteriovenous fistula (8), and cerebral stroke (9). The guidewire can migrate to different places, such as from femoral to jugular (10), or infection and endocarditis (the presented case) (11,12).

The question is, if a guidewire is left without complications and found accidentally, should it be left on the site, or it should be removed?

*Corresponding author: Zahra Ansari Aval, Email: Z.ansari@sbmu.ac.ir, zahraansariaval@gmail.com

Case Report

A 53-year-old man presented with fever and chills commencing approximately two months previously. He had undergone heart surgery for an aortic valve replacement with a mechanical valve, the mitral valve was repaired with a ring 12 years ago, and he received warfarin. About two years after the heart surgery (10 years ago), he needed hemodialysis due to chronic renal failure, and he underwent stenting until the arterial-venous fistula in his hand was ready. Subsequently, in the follow-up echocardiography, the patient noticed an asymptomatic forgotten guidewire in the heart. Due to its asymptomatic character, the patient did not want to undergo another procedure and remove the guidewire. After about ten years, the patient developed fever and chills. In physical examination, we noticed endocarditis of the aortic valve, separation of parts of the artificial valve from the aortic ring, severe paravalvular leak in the aortic valve, and abscess formation in the aortic root. We also noticed a forgotten guidewire in the superior vena cava, and right atrium, looping in the right ventricle, inferior vena cava, and hepatic vein. Echogenic and mobile masses on the guide wire were detected by echocardiography, and the diagnosis was confirmed by fluoroscopy and chest X-ray (Figure 1).

After antibiotic treatment, he underwent heart surgery, aortic valve replacement was performed, and the aortic root was repaired.

Then the right atrium was opened, and the 70 cm long guide wire was removed (Figure 2).

The surgery was completed without any particular incident, although the measures taken, the patient died a few days after the surgery.

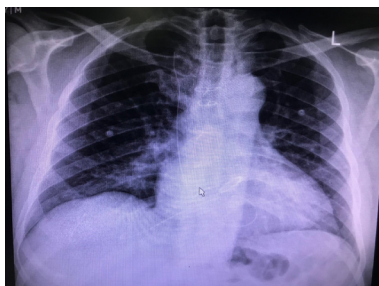


Figure 1. Guide wire diagnosis was confirmed by chest x-ray.

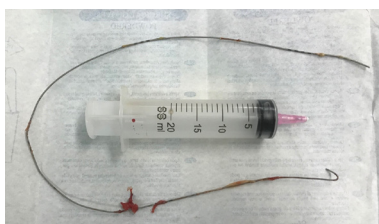

Figure 2. The 70 cm long guide wire was removed.

Discussion

Most of the cases of guidewire loss are caused by sufficient skills of the surgeon and not going through the learning curve enough (13). Sometimes, experienced people are responsible for this (14), and this occurs due to ignoring the recommended actions (15). During the insertion, those devices may be forgotten due to the operators' high self-confidence (13) or their high workload (14). Sometimes, forgotten or lost guidewire remains concealed lest be questioned by a superior (2) or a patient's legal complaint. Therefore, it usually remains concealed and is detected accidentally or due to complications.

In all cases, this incident can be prevented by keeping the end of the guide wire and leaving at least 18 cm from the end (2,13,14); and if this happens immediately, it can be removed with techniques on the bedside (3). If it is completely left inside the vessels, it should be removed by intravascular techniques (6).

There is no consensus on whether it should be removed through angiography, endovascular, or surgery. It is recommended that it should be removed first through endovascular angiography, and if this fails, then surgery should be considered (1,6).

In a study, 15 patients were subjected to intervention for foreign body removal for four years. In nine cases, foreign bodies were parts of central venous lead, three cases were remaining guidewire, two were pacemaker leads, and one case was coil displacement, all of which were removed by percutaneous interventions. Surgical removal should only be considered when these efforts fail or they are identified after a long time (1,6).

The question is, should a forgotten guidewire without complications be left or removed?

There are reports of guide wire migration in the body (5,10) or stroke in the brain (9), or the formation of a clot on it and sending an embolism or the development of endocarditis (the reported case). They can all endanger patients' lives. Therefore, the authors recommend that lost guide wires should be removed.

Conclusion

Instructing operators about the complications of loss of guide wire even after a while and ensuring and comforting can lead to the comprehension of complications and the expression of loss of guide wire, which can be done in the early stages and prevent later complications. Whenever a forgotten guide wire is found, it should be removed.

Acknowledgments

The authors would like to thank Modarres Hospital staff

Authors' contribution

Conceptualization: Manouchehr Hekmat.

Data curation: Seyedeh Adeleh Mirjafari.

Formal analysis: Hamid Ghaderi.

Funding acquisition: Seyedeh Adeleh Mirjafari.

Investigation: Hamid Ghaderi.
Methodology: Hamid Ghaderi.
Project administration: Manouchehr Hekmat.
Resources: Roshanak Tirdad.
Validation: Zahra Ansari Aval.
Supervision: Hamid Ghaderi.
Visualization: Roshanak Tirdad.
Writing–original draft: Hamid Ghaderi.
Writing–review and editing: Zahra Ansari Aval.

Conflicts of interest

The authors declare that they have no competing interests.

Ethical issues

This case report was conducted in accordance with the World Medical Association Declaration of Helsinki. Written informed consent was obtained from the patient for the publication of this case report. The authors have adhered to ethical standards, including avoiding plagiarism, data fabrication, and double publication.

Funding/Support

The authors declare that they did not receive any funding to complete this study.

References

- Zheng L, Cho YC, Shin JH, Park JH, Jang EB, Ibrahim A, et al. Percutaneous antegrade removal of foreign bodies in the urinary tract: a 20-year, single-center experience. *Acta Radiol.* 2021;62:1097-1103. doi: 10.1177/0284185120950127.
- Van Doninck J, Maleux G, Coppens S, Moke L. Case report of a guide wire loss and migration after central venous access. *J Clin Anesth.* 2015;27:406-10. doi: 10.1016/j.jclinane.2015.04.005.
- Dulhunty JM, Suhrbier A, Macaulay GA, Brett JC, van Straaten AV, Brereton IM, et al. Guide-wire fragment embolisation in paediatric peripherally inserted central catheters. *Med J Aust.* 2012;196:250-5.
- Almehmi SE, Abaza M, Krishna VN, Almehmi A. Delayed diagnosis of a retained guidewire after bedside femoral venous catheter insertion: A preventable complication. *Radiol Case Rep.* 2021;17:647-649. doi: 10.1016/j.radcr.2021.11.030.
- Akazawa S, Nakaigawa Y, Hotta K, Shimizu R, Kashiwagi H, Takahashi K. Unrecognized migration of an entire guidewire on insertion of a central venous catheter into the cardiovascular system. *Anesthesiology.* 1996;84:241-2. doi: 10.1097/00000542-199601000-00039.
- Khayat M, Khayat A, Chick JFB, Healey TL, Srinivasa RN. Percutaneous Interventional Radiology-Operated Endoscopy for Foreign Body Removal. *Tech Vasc Interv Radiol.* 2019;22:149-153.
- Darwazah AK, Abu Sham'a RA, Yassin IH, Islim I. Surgical intervention to remove an entrapped fractured guidewire during angioplasty. *J Card Surg.* 2007;22:526-8. doi: 10.1111/j.1540-8191.2007.00462.x.
- Kuramochi G, Ohara N, Hasegawa S, Moro H. Femoral arteriovenous fistula: a complication of temporary hemodialysis catheter placement. *J Artif Organs.* 2006;9:114-7. doi: 10.1007/s10047-005-0325-9.
- Alves Ramos Diniz PI, Rios Rodriguez JE, Salgado Pio Oliveira JP, Cruz Lira M, Lima da Rocha RD, Ribeiro Dos Santos Campelo P, et al. Forgotten guidewire: A case report. *Ann Med Surg (Lond).* 2022;79:103867. doi: 10.1016/j.amsu.2022.103867.
- van den Bogert PC, de Araujo WJB, Ruggeri VGM, Caron FC, Erzinger FL, de Macedo PEM. Accidental guide wire migration and late percutaneous externalization after central venous catheterization. *J Vasc Access.* 2023;24:824-827. doi: 10.1177/11297298211054898.
- Abdel-Aal AK, Saddekni S, Hamed MF. Guide wire entrapment in a vena cava filter: techniques for dislodgement. *Vasc Endovascular Surg.* 2013;47:115-23. doi: 10.1177/1538574412471209.
- De Praetere H, Di Bari N, Gutermann H, Van Kerrebroeck C, Dens J, Dion R. Extravascular migration of a guide wire with perforation of the heart eight months after percutaneous coronary intervention: consequence of a conservative approach. *Cardiology.* 2012;121:83-6. doi: 10.1159/000336489.
- Srivastav R, Yadav V, Sharma D, Yadav V. Loss of guide wire: a lesson learnt review of literature. *J Surg Tech Case Rep.* 2013;5:78-81. doi: 10.4103/2006-8808.128732.
- Abuhasna S, Abdallah D, Ur Rahman M. The forgotten guide wire: a rare complication of hemodialysis catheter insertion. *J Clin Imaging Sci.* 2011;1:40. doi: 10.4103/2156-7514.83397.
- Deep G, Sidhu N, Gupta KK, Sharma R. Loss of guide-wire during central venous cannulation - Life long learning! *J Anaesthesiol Clin Pharmacol.* 2022;38:156-157. doi: 10.4103/joacp.JOACP_20_19.

Copyright © 2024 The Author(s); Published by Society of Diabetic Nephropathy Prevention. This is an open-access article distributed under the terms of the Creative Commons Attribution License (<http://creativecommons.org/licenses/by/4.0>), which permits unrestricted use, distribution, and reproduction in any medium, provided the original work is properly cited.