

UDC 595.132.5

## DESCRIPTION OF THE NEMATODE *DIROFILARIA REPENS* (NEMATODA, ONCHOCERCIDAE) PARASITIC IN DOGS IN UKRAINE

V. Yevstafieva<sup>1,2,\*</sup>, V. Stybel<sup>3</sup>, V. Melnychuk<sup>1,2</sup>, B. Gutyj<sup>3</sup>, M. Leno<sup>3</sup>, S. Kravchenko<sup>1</sup>,  
O. Kyrychko<sup>1</sup>, N. Dmitrenko<sup>1</sup>, N. Syzonenko<sup>1</sup> & N. Opara<sup>1</sup>

<sup>1</sup>Poltava State Agrarian University, Skovorody st., 1/3, Poltava, 36003 Ukraine

<sup>2</sup>Institute of Veterinary Medicine of the National Academy of Agrarian Sciences of Ukraine, Kyiv, Ukraine,  
Donetska st., 30,  
Kyiv, 03151 Ukraine

<sup>3</sup>Lviv National University of Veterinary Medicine and Biotechnologies named after S. Z. Gzhytskyj, Pekarska st., 50,  
Lviv, 79000 Ukraine

\*Corresponding author

E-mail: evstva@ukr.net

V. Yevstafieva (<https://orcid.org/0000-0003-4809-2584>)

V. Stybel (<https://orcid.org/0000-0002-0285-6182>)

V. Melnychuk (<https://orcid.org/0000-0003-1927-1065>)

B. Gutyj (<https://orcid.org/0000-0002-5971-8776>)

M. Leno (<https://orcid.org/0000-0001-6158-3076>)

S. Kravchenko (<https://orcid.org/0000-0002-7420-9320>)

O. Kyrychko (<https://orcid.org/0000-0002-0769-0804>)

N. Dmitrenko (<https://orcid.org/0000-0001-5336-2361>)

N. Syzonenko (<https://orcid.org/0000-0002-7978-8675>)

N. Opara (<https://orcid.org/0000-0002-0128-8400>)

**Description of the Nematode *Dirofilaria repens* (Nematoda, Onchocercidae) Parasitic in Dogs in Ukraine.** Yevstafieva, V., Stybel, V., Melnychuk, V., Gutyj, B., Leno, M., Kravchenko, S., Kyrychko, O., Dmitrenko, N., Syzonenko, N. & Opara, N. — *Dirofilaria repens* is a zoonotic disease of domestic and wild carnivorous animals and humans. Subcutaneous migration of the parasite *Dirofilaria repens* Railliet & Henry, 1911 can lead to the local swellings with changeable localization. In humans, this parasite can cause the damage of lungs, male genitalia, and eyes. The range of *D. repens* is constantly spreading to new areas, and, considering the zoonotic potential of this parasite, it is important to widen the existing

data concerning the morphology of *D. repens*. Present study provides the morphometric description of nematodes *D. repens*, obtained from subcutaneous tissue of dogs in Ukraine. The aim of this study was to make an accent on the key features for performing the identification of parasites of this species. For males, 27 morphometric traits were identified, characterising the total size of the body and the esophagus, the thickness of the cuticle in the region of the mouth opening, the localisation of the nerve ring and the cloaca, the morphological structure and metric parameters of the spicules, and the length of the tail. For females, 18 morphometric traits were identified that, in addition to the common parameters, characterise cuticle thickness in the region of the vulva, localisation of the vulva and anus, body width in the regions of the anus and vulva, and tail length. This report widens the existing data on the morphological and metric characteristics of nematodes *D. repens*.

Key words: *Dirofilaria repens*, nematodes, identification, morphometry.

## Introduction

Among the agents of transmissible zoonotic nematodoses, *Dirofilaria repens* Railliet & Henry, 1911 (Nematoda, Onchocercidae) plays a significant role in the negative impact on human health (Pampiglione et al., 2001; Otranto et al., 2011; Pupić-Bakrač et al., 2021; Geissler et al., 2022). In particular, these nematodes can cause the symptoms similar to larva migrans in the human organism, and the juveniles often live under the eyelids and conjunctiva (Sassi et al., 2006; Hempel et al., 2012; Popescu et al., 2012). *Dirofilaria repens* also produces the nodules in the skin and subcutaneous adipose tissue, typical for dirofilariasis (Dang et al., 2010; Tasić et al., 2011; Kombade et al., 2015). There have been reports on *D. repens* in the scrotum, lymph nodes, abdomen, lungs, muscles and brain sheaths (Rivasi et al., 2006; Leccia et al., 2012; Vucaj Cirilovic et al., 2014; Matějů et al., 2016).

The authors also described the nematodes obtained from the scrotum and under the skin of dogs in Poland and identified as *D. repens* (Demiaszkiewicz et al., 2011). In addition to morphological characteristics, the researchers identified more parameters than suggested in keys (Railliet & Henry, 1911; Sonin, 1975; Capelli et al., 2018). They measured the body length in males and females, the distance from the neural circle to the head end, the length of the pharynx and its maximum width, the maximum width of the head end, the width of the terminal part of the pharynx, the maximum body width, the length of the tail end and the maximum thickness of the cuticula. In addition, body width in the region of the cloaca, length of the spicules and their width in the proximal part were measured in males, and the distance from the vulva to the head end, body width in the regions of the neural circle, vulva and anus were measured in females (Demiaszkiewicz et al., 2011).

Such different localisation of these nematodes has been defined using different identification methods with different sensitivity and efficiency (immunological, genetic and microscopic) (López et al., 2012; Bozidis et al., 2021; Smith et al., 2022). The latter allowed the identification of *Dirofilaria* species, taking into account the morphological characteristics and metric indices in the males and females of the parasites (Wong et al., 1978; Simón et al., 2012). In particular, the authors used electron microscopy to show that *D. repens* females from different regions of the human body showed certain differences in the structure of the head and tail ends. However, the cuticle structure appeared to be identical and corresponded to the identification keys for this species (Khedr et al., 2021). The authors suggested supplementing the identification keys with length and width, the presence of cuticular spines and the distance from the head end to the vulva (Levine, 1980; Iddawela et al., 2015).

The specific cuticle structure, characterised by the presence of transverse striae and longitudinal protrusions along the entire body, has been shown to be the distinguishing feature between mature and immature *D. repens*. The cuticle of *D. immitis* is devoid of protrusions, except for the ventral part of the tail end in males (Gardiner et al., 1978; Gutierrez et al., 1995; Vakalis & Himonas, 1997; Manfredi et al., 2007; Elsayad et al., 2012). There are also proposals to measure the height of the cuticular protrusions and the distance between them. In addition, scientists have found that the cuticle at the head end is thicker in *D. repens* than in *D. immitis*, and the tail end of females is sharp in *D. repens* and rounded in *D. immitis* (Suzuki et al., 2015).

Thus, despite the increasing distribution and zoonotic impact of *D. repens* around the world, scientists pay much less attention to it than to *D. immitis*, presumably due to the greater pathogenicity of the latter. Therefore, the aim of the present work was to study the morphological characteristics and metric parameters of *D. repens* nematodes collected from dogs in Ukraine.

## Material and Methods

The study was conducted in 2022–2023 in the laboratory of the Department of Parasitology and Veterinary and Sanitary Expertise of the Poltava State Agricultural University (Poltava) and in the private veterinary clinic “Dovira” (Kharkiv). Helminths were collected from the dogs brought to the clinic with the diagnosis of neoplasms under the skin. After removal, the helminths were fixed in 70% ethanol. The species

were identified using the key of Sonin (1975). A total of 13 specimens (8 females and 5 males) of *D. repens* were collected.

The parameters of morphological structures of mature *D. repens* males and females were measured using ImageJ for Windows® (version 2.00) in interactive mode, with the objectives  $\times 5$ ,  $\times 10$ ,  $\times 40$  and photo-ocular  $\times 10$ . Microphotographs were taken using digital microscope camera for Sigeta M3CMOS 14000 14.0 MP (China). Standard deviation (SD) and mean values (M) were calculated.

## Results and Discussion

Males and females *D. repens* had thread-like body. Body cuticle had longitudinal striation with well-expressed rib-like pattern, and thin transverse striation.

The head end of the nematodes was obtusely-rounded. In this region the cuticle was clearly expressed and thick. At the head end, the four pairs of head papillae were situated. Mouth opening was small, weakly expressed, and leading to a small mouth cavity (fig. 1, a). The esophagus was short; its muscular and glandular parts had no clear delimitation line (fig. 1, b). In the region of the nerve ring, the esophagus was slightly narrower.

Males of *D. repens* had rounded tail end, with narrow lateral alae. There were two spicules of different length and shape; the left one was longer (fig. 2, a). The longer spicule had the wider anterior part, which ends by a triangular widening with sharp end, and the thin posterior part. Its proximal end was of infundibular shape, and the distal end was rounded. The shorter spicule was wide, with proximal end wider than distal end (fig. 2, b). The caudal papillae were distinct. The number of pre-anal and post-anal papillae varied (fig. 2, c).

We defined 27 morphological indices for *D. repens* males that may facilitate the identification of this species. In previous studies, 2–13 characters have been used by the authors (table 1).

Particularly, besides the main morphological traits, separate authors suggested to measure the *D. repens* males' overall body length and width, body width in the regions of the cloaca and of the esophagus transition into the intestine, the overall esophagus length and its width in the widest part, length of the tail, spiculae, ratio between lengths of spiculae, width of their proximal ends, and distance from the head end to the nerve ring. We additionally suggest to use the morphometric indices of the spiculae (8 additional indices), the esophagus width in its different parts (2 additional indices), localization of the cloaca (2 additional indices), and the body width in the region of the nerve ring.




Fig. 1. Head end of *Dirofilaria repens*: a — mouth opening (Mo), cuticular layer (Cl); head papillae (Hp); b — esophagus (Es).

**Table 1. Metric parameters of ♂ *Dirofilaria repens*, n = 5 (M ± SD, min–max)**

Parameter	Present study	Railliet & Henry, 1911	Lent & Freitas, 1937	Sonin, 1975	Demiasz-kiewicz et al., 2011	Kravchenko & tin, 2012	Baisarova, 2021
Body length, mm	57.1 ± 6.5 48.0–66.5	48–70	27.75	51	63 56–70	58–71	87.3 ± 9.6 71–110
Body width, µm	406.7 ± 16.6 390.1–432.4	370–450	–	320	325 298–379	800–1000	1100 ± 0.4 900–1700
Body width in the region of, µm:							
nerve ring	238.5 ± 11.9 224.1–251.6	–	–	–	–	–	–
junction between esophagus and intestine – cloaca	382.7 ± 16.3 359.4–402.1	–	–	–	293 269–317	–	–
Esophagus length, mm	118.8 ± 15.0 98.6–137.2	–	–	–	99 95–104	–	–
Esophagus length, mm	761.9 ± 39.2 698.2–797.9	–	–	750	713 696–730	до 1400	–
Esophagus width in the region of, µm:							
nerve ring	42.2 ± 2.1 39.8–44.9	–	–	–	–	–	–
middle part	56.3 ± 4.6 48.2–59.2	–	–	–	–	–	–
the widest part	62.1 ± 2.1 59.8–64.9	–	–	–	40 36–45	–	–
Thickness of the cuticle in the region of mouth opening, µm	9.2 ± 0.8 (8.2–10.4)	–	–	–	–	–	–
Distance from anterior end to nerve ring, µm	227.9 ± 10.5 211.8–241.1	–	–	240	162 160–165	–	–
Distance from anterior end to cloaca, mm	57.1 ± 6.8 47.9–66.4	–	–	–	–	–	–
Distance from the nerve ring to cloaca, mm	56.8 ± 6.8 47.6–66.2	–	–	–	–	–	–
Tail length, µm	72.9 ± 7.1 62.2–80.1	66–85	72	80	77 73–82	–	–
Long spicule, µm:							
length	432.9 ± 24.0 392.1–450.9	465–590	430	300	541 537–547	160–270	–
width of proximal end	37.2 ± 1.8 35.2 – 39.9	–	–	–	22 20–27	–	–
width of distal end	3.1 ± 0.2 2.9–3.3	–	–	–	–	–	–
width in middle part	18.2 ± 0.7 17.1–18.9	–	–	–	–	–	–
width of widening part	25.2 ± 1.4 23.6–27.1	–	–	–	–	–	–
– handle length	250.3 ± 10.7 237.1–261.3	–	–	–	–	–	–
– lamina length	182.5 ± 32.1 130.7–209.5	–	–	–	–	–	–
Ratio of handle to lamina length	1.42:1 1.15:1–2.00:1	–	–	–	–	–	–
Short spicule, µm:							
length	178.7 ± 9.4 170.9–194.1	185–206	175	130	185 181–189	180–200	–
proximal end width	21.9 ± 4.0 14.9–25.1	–	–	–	27 23–35	–	–
distal end width	14.4 ± 0.7 13.2–15.1	–	–	–	–	–	–
middle part width	31.4 ± 1.2 30.1–33.1	–	–	–	–	–	–
Ratio of spicules' lengths	2.43:1 2.23:1–2.58:1	2.5 : 1	2.5 : 1	–	–	–	–

Note. Parameters were not defined.






Fig. 2. Tail end of  $\sigma$  *Dirofilaria repens*: a — lateral alae (WI), longer spicule (SI), c — shorter spicule (Ssh); b — proximal end of the spicule (Sp), distal end of the spicule (Sd), wide part (Pw), narrow part (Pn), triangular widening (Wt); c — caudal papillae.

Females of *D. repens* had the vulva situated in the anterior body part. Its opening was of oval shape and surrounded by barely noticeable lips. The vagina was well-expressed and long (fig. 3, a). The reproductive system was didelphic. Both uteri occupied almost the entire body cavity and contained the larvae (fig. 3, b). The anus was situated terminally. Tail end was slightly rounded.

We defined the 18 morphological indices in *D. repens* females. Other authors suggested from 2–12 indices as differential criteria for females of this species (table 2).

In the previous descriptions of *D. repens* females, the authors measured the overall body length, the esophagus length and width (in the widest part), the body width in the regions of the nerve ring, anus, vulva, and esophago-intestinal junction, the tail length, distances from the head end to the nerve ring and to the vulva. We additionally suggest 7 indices: the esophagus width in the regions of the nerve ring and middle part, the cuticle thickness in the regions of mouth opening and of the vulva, the distances from the vulva to the nerve ring, from the vulva to tail end, and from the vulva to anal opening. The literature data show that *D. repens* is endemic in many countries, affects both domestic and wild carnivores and humans. In the recent years, the range of *D. repens* has been constantly enlarging, reaching the new territories; or the number of its recorded cases (both in dogs and humans) has increased on those territories where such cases had been sporadic before. Therefore, this species can be assigned to the zoonotic emergent pathogens (McCall et al., 2008; Capelli et al., 2018; Simón et al., 2022). This drives the scientists to pay more attention to *D. repens*, particularly to its identification. Furthermore, a lot of studies are dedicated to the morphological traits of *D. repens* females obtained from humans (Iddawela et al., 2015;

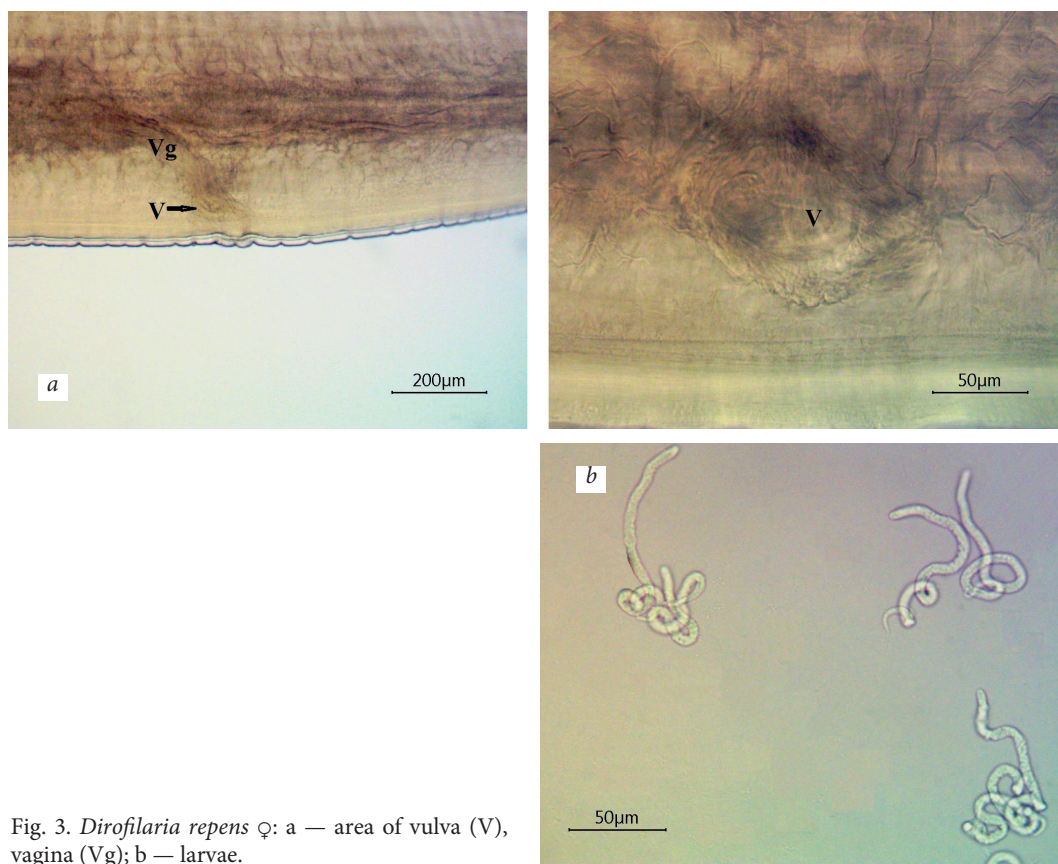


Fig. 3. *Dirofilaria repens* ♀: a — area of vulva (V), vagina (Vg); b — larvae.

Suzuki et al., 2015; Hennocq et al., 2020). That is why our study was focused on the differential morphological characteristics and metric parameters of *D. repens* obtained from dogs.

The present study showed that the overall structure of both males and females was characterized by expressed longitudinal striation on the cuticle along the entire body, which is the diagnostic character of the species according to many authors. Particularly, the pattern and height of cuticular crests differed significantly from the morphology of cuticle in *D. immitis*, *D. tenuis* and *D. ursi* (Orihel & Beaver, 1965; Billups et al., 1980; Pampiglione et al., 2009). The head end of nematodes was rounded, the mouth opening was small and weakly expressed, and the cuticle in this region was well-expressed; its thickness was 9.2 µm in males and 10.9 µm in females. So, the authors indicated that the cuticle thickness in *D. repens* exceeds that in *D. immitis* (Suzuki et al., 2015).

The results of the metric study of mature *D. repens* males and females allowed us to propose the identification of indices that extend the existing data on their identification. We also compared our data with existing data for the identification of *D. repens* obtained from dogs. For the identification of males, we proposed the use of 27 morphometric characters, while other authors proposed 2–13 characters. Previously, different authors diagnosed *D. repens* based on the morphology of males, taking into account the length and width of the body and oesophagus, the distance from the end of the head to the cloaca, the length of the tail, the length and width of the spicules, the width of the proximal ends of the spicules and the ratio of the lengths of the spicules. Our data have certain differences from the results of other authors by metric indices (Railliet & Henry, 1911; Lent & Freitas, 1937; Sonin,

**Table 2.** Metric parameters of ♀ *Dirofilaria repens*, n = 8 (M ± SD, min–max)

Parameter	Present study	Railliet & Henry, 1911	Lent & Freitas, 1937	Sonin, 1975	Demiaszkiewicz et al., 2011	Kravchenko & Itin, 2012	Baisarova, 2021
Body length, mm	17.2 ± 0.7 16.2–18.1	10–17	14–15	10.6	15.4 14.7–16.1	9.8–17.4	14.5 9.7–17.6
Body width, µm	565.2 ± 19.8 541.3–597.9	450–650	447–552	530	532 490–570	800–1000	1140 900–1700
Body width in the region of, µm:							
nerve ring	316.1 ± 19.1 294.1–342.6	–	–	–	290 283–298	–	–
transition from esophagus to intestine	452.2 ± 26.5 415.6–486.1	–	–	–	417 411–422	–	–
vulva	517.1 ± 31.4 463.4–556.1	–	–	–	503 499–508	–	–
anus	149.9 ± 9.6 132.2–162.5	–	–	–	145 128–169	–	–
Esophagus length, mm	912.7 ± 48.7 831.7–964.2	–	1050– 1053	910	966 915–1037	1110	–
Esophagus width in the region of, µm:							
nerve ring	34.6 ± 4.0 30.5–40.2	–	–	–	–	–	–
middle part	53.8 ± 3.2 50.2–60.1	–	49–54	–	–	–	–
the widest part	71.4 ± 2.8 68.2–77.2	–	–	–	89 77–102	–	–
Thickness of the cuticle in the region of mouth opening, µm	10.9 ± 0.8 9.2–11.8	–	–	–	–	–	–
Thickness of the cuticle in the region of vulva, µm	12.3 ± 0.77 11.1–13.4	–	–	–	–	–	–
Distance from anterior end to nerve ring, µm	258.1 ± 17.8 242.0–296.2	–	304–368	270	295 291–298	–	–
Distance from anterior end to vulva, mm	1.4 ± 0.1 1.3–1.6	1.5–1.9	1.84–1.92	–	1.55 1.45–1.63	1.6–2.7	–
Distance from the vulva to the nerve ring, mm	1.2 ± 0.1 1.1–1.3	–	–	–	–	–	–
Distance from the vulva to the tail end, mm	15.7 ± 0.7 14.7–16.7	–	–	–	–	–	–
Distance from the vulva to the anus, mm	15.7 ± 0.7 14.6–16.6	–	–	–	–	–	–
Tail length, µm	81.1 ± 8.6 70.4–92.2	105–126	–	90	85 73–102	–	–
Microfilaria length, µm	208.7 ± 10.2 193.4–224.9	300–360	–	300–360	329 296–362	–	–
Microfilaria width, µm	5.8 ± 0.4 5.3–6.4	6–8	–	6–8	7 5–8	–	–

Note. Parameters were not defined.

1975; Demiaszkiewicz et al., 2011; Kravchenko & Itin, 2012; Baisarova, 2021). According to previous studies, the variation in morphometric traits may be related to the study of immature nematodes, sampling conditions, and damage caused by surgical extraction of nematodes (Suzuki et al., 2015). We proposed to additionally use the width of the body and esophagus in separate parts, the thickness of the cuticle in the region of the mouth opening, the localisation of the cloaca, the width of the spicules in different parts, and the ratio of the handle to the lamina of the longer spicule for the identification of *D. repens* males.



Females of *D. repens* are proposed to be identified by 18 morphometric indices. At the same time, other authors proposed from 2 to 12 indices in females of this species. In particular, they recorded the length and width of the body, the length and width of the esophagus at its widest point, the distance from the tip of the head to the nerve ring and to the vulva, and the length of the tail. Our data again differed by certain indices (Railliet & Henry, 1911; Lent & Freitas, 1937; Sonin, 1975; Demiaszkiewicz et al., 2011; Kravchenko & Itin, 2012; Baisarova, 2021). Therefore, we additionally proposed to identify the localisation of the vulva and the anus, the thickness of the cuticle in the region of the mouth opening and the vulva, the width of the oesophagus in the region of the nerve ring and in its central part. The size of the microfilariae in the uteri was also determined; their length was 208.7  $\mu\text{m}$  (193.4–224.9  $\mu\text{m}$ ) and their width was 5.8  $\mu\text{m}$  (5.3–6.4  $\mu\text{m}$ ). Furthermore, according to the authors, these parameters varied in the range of 296–362  $\mu\text{m}$  and 5–8  $\mu\text{m}$ , respectively (Railliet & Henry, 1911; Sonin, 1975; Demiaszkiewicz et al., 2011). Insignificant variations in the indices may be explained by the examination of microfilariae at different stages of their development.

Thus, the use of proposed morphometric indices for identification of *D. repens* both by males, females and microfilariae may allow to widen the existing data and to make easier their identification.

## Conclusion

We performed morphological and metric description of nematodes *D. repens*, obtained from subcutaneous tissues of dogs in Ukraine. We considered, analysed and identified more morphometric parameters than other authors. There are 27 metric characters for males and 18 for females, of which 11 characterise the total length and width of the body and the esophagus in different parts, the localisation of the nerve ring, the thickness of the cuticle in the region of the mouth opening and the length of the tail. For males, 16 additional indices were proposed to measure the size of the spicules and the position of the cloaca. For females, 7 indices were proposed to characterise the position of the vulva and anus and the thickness of the cuticle in the region of the vulva.

## References

- Baisarova, Z. T. 2021. Biologija i morfologija *D. repens* i *D. imititis*. *International Research Journal*, **3** (105), 11–15. <https://doi.org/10.23670/IRJ.2021.105.3.026> [in Russian].
- Billups, J., Schenken, J. R., & Beaver, P. C. 1980. Subcutaneous dirofilariasis in Nebraska. *Archives of Pathology and Laboratory Medicine*, **104**, 11–13.
- Bozidis, P., Sakkas, H., Pertsalis, A., Christodoulou, A., Kalogeropoulos, C. D. & Papadopoulou, C. 2021. Molecular analysis of *Dirofilaria repens* isolates from eye-care patients in Greece. *Acta Parasitologica*, **66** (1), 271–276. <https://doi.org/10.1007/s11686-020-00257-4>
- Capelli, G., Genchi, C., Baneth, G., Bourdeau, P., Brianti, E., Cardoso, L., Danesi, P., Fuehrer, H. P., Giannelli, A., Ionică, A. M., Maia, C., Modrý, D., Montarsi, F., Krücken, J., Papadopoulos, E., Petrić, D., Pfeffer, M., Savić, S., Otranto, D., Poppert, S. & Silaghi, C. 2018. Recent advances on *Dirofilaria repens* in dogs and humans in Europe. *Parasites & Vectors*, **11** (1), 663. <https://doi.org/10.1186/s13071-018-3205>
- Dang, T. C., Nguyen, T. H., Do, T. D., Uga, S., Morishima, Y., Sugiyama, H. & Yamasaki, H. 2010. A human case of subcutaneous dirofilariasis caused by *Dirofilaria repens* in Vietnam: histologic and molecular confirmation. *Parasitology Research*, **107** (4), 1003–1007. <https://doi.org/10.1007/s00436-010-1961-4>
- Demiaszkiewicz, A. W., Polańczyk, G., Osińska, B., Pyziel, A. M., Kuligowska, I. & Lachowicz, J. 2011. Morphometric characteristics of *Dirofilaria repens* Railliet et Henry. 1911 parasite of dogs in Poland. *Wiadomości Parazytologiczne*, **57** (4), 253–256.
- Elsayad, M. H., Tolba, M. M., Yehia, M. A. H., Ahmed, A. S. & Abou-Holw, S. A. 2012. Human subcutaneous dirofilariasis: report of two cases of *Dirofilaria repens* in Alexandria, Egypt. *Parasitologists United Journal*, **5**, 67–72.



- Gardiner, C. H., Oberdorfer, C. E., Reyes, J. E. & Pinkus, W. H. 1978. Infection of man by *Dirofilaria repens*. *American Journal of Tropical Medicine and Hygiene*, **27** (6), 1279–1281. <https://doi.org/10.4269/ajtmh.1978.27.1279>
- Geissler, N., Ruff, J., Walochnik, J., Ludwig, W., Auer, H., Wiedermann, U. & Geissler, W. 2022. Autochthonous human *Dirofilaria repens* infection in Austria. *Acta Parasitologica*, **67** (2), 1039–1043. <https://doi.org/10.1007/s11686-021-00506-0>
- Gutierrez, Y., Misselevich, I., Fradis, M., Podoshin, L. & Boss, J. H. 1995. *Dirofilaria repens* infection in northern Israel. *American Journal of Surgical Pathology*, **19** (9), 1088–1091. <https://doi.org/10.1097/0000478-199509000-00014>
- Hempel, F., Poppert, S., Böker, T. & Schaaf, B. 2012. 75-year-old woman with symptoms of the eye. *Deutsche Medizinische Wochenschrift*, **137** (33), 1641–1642. <https://doi.org/10.1055/s-0032-1304889>
- Henocq, Q., Helary, A., Debelmas, A., Monsel, G., Labat, A., Bertolus, C., Martin, C. & Caumes, E. 2020. Oral migration of *Dirofilaria repens* after creeping dermatitis. *Parasite*, **27**, 16. <https://doi.org/10.1051/parasite/2020015>
- Iddawela, D., Ehambaram, K. & Wickramasinghe, S. 2015. Human ocular dirofilariasis due to *Dirofilaria repens* in Sri Lanka. *Asian Pacific Journal of Tropical Medicine*, **8** (12), 1022–1026. <https://doi.org/10.1016/j.apjtm.2015.11.010>
- Khedr, S. I., Said, D. E., Zeitoun, I. M. & Hussein, N. M. 2021. Scanning electron microscopy as a confirmatory tool for morphological identification of *Dirofilaria (Nochtiella) repens*. *Parasitologists United*, **14** (1), 22–28. <https://doi.org/10.21608/puj.2021.53673.1100>
- Kombade, S. P., Mantri, R. S., Ambhore, N. A. & Karyakarte, R. P. 2015. Subcutaneous human Dirofilariasis in Vidarbha. *Indian Journal of Pathology & Microbiology*, **58** (3), 387–388. <https://doi.org/10.4103/0377-4929.162923>
- Kravchenko, V. M. & Itin, G. S. 2012. Morphological characteristics of *Dirofilaria immitis* and *D. repens*. *Theory and Practice of Parasitic Disease Control*, **13**, 197–200 [In Russian].
- Leccia, N., Patouraux, S., Carpentier, X., Boissy, C., Del Giudice, P., Parks, S., Michiels, J. F. & Ambrosetti, D. 2012. Pseudo-tumor of the scrotum, a rare clinical presentation of dirofilariasis: a report of two autochthonous cases due to *Dirofilaria repens*. *Pathogens and Global Health*, **106** (6), 370–372. <https://doi.org/10.1179/2047773212Y.0000000029>
- Lent, H. & Freitas, J. F. T. de 1937. Dirofilariose sub-cutanea dos cães no Brasil. *Memórias Do Instituto Oswaldo Cruz*, **32**(3), 443–448. doi:10.1590/s0074-02761937000300007
- Levine, N. D. 1980. Nematode parasites of domestic animals and of man. 2nd ed. Burgess Publishing Co, Minneapolis.
- López, J., Valiente-Echeverría, F., Carrasco, M., Mercado, R. & Abarca, K. 2012. Morphological and molecular identification of canine filariae in a semi-rural district of the Metropolitan Region in Chile. *Revista Chilena de Infectología*, **29** (3), 248–289. <https://doi.org/10.4067/S0716-10182012000300006>
- Manfredi, M. T., DiCerbo, A. & Genchi, M. 2007. Biology of filarial worms parasitizing dogs and cats. *Mappe Parasitologiche*, **8**, 40–45.
- Matějů, J., Chanová, M., Modrý, D., Mítková, B., Hrazdilová, K., Žampachová, V. & Kolářová, L. 2016. *Dirofilaria repens*: emergence of autochthonous human infections in the Czech Republic (case reports). *BMC Infectious Diseases*, **16**, 171. <https://doi.org/10.1186/s12879-016-1505-3>
- McCall, J. W., Genchi, C., Kramer, L. H., Guerrero, J. & Venco, L. 2008. Heartworm disease in animals and humans. *Advances in Parasitology*, **66**, 193–285. [https://doi.org/10.1016/S0065-308X\(08\)00204-2](https://doi.org/10.1016/S0065-308X(08)00204-2)
- Orihel, T. C. & Beaver, P. C. 1965. Morphology and relationship of *Dirofilaria tenuis* and *Dirofilaria conjunctivae*. *American Journal of Tropical Medicine and Hygiene*, **14**, 1030–1043.
- Otranto, D., Brianti, E., Gaglio, G., Dantas-Torres, F., Azzaro, S. & Giannetto, S. 2011. Human ocular infection with *Dirofilaria repens* (Railliet and Henry, 1911) in an area endemic for canine dirofilariasis. *American journal of Tropical Medicine and Hygiene*, **84** (6), 1002–1004. <https://doi.org/10.4269/ajtmh.2011.10-0719>
- Pampiglione, S., Rivasi, F. & Gustinelli, A. 2009. Dirofilarial human cases in the Old World, attributed to *Dirofilaria immitis*: a critical analysis. *Histopathology*, **54**, 192–204.
- Pampiglione, S., Rivasi, F., Angeli, G., Boldorini, R., Incensati, R. M., Pastormerlo, M., Pavesi, M. & Ramponi, A. 2001. Dirofilariasis due to *Dirofilaria repens* in Italy, an emergent zoonosis: report of 60 new cases. *Histopathology*, **38** (4), 344–354. <https://doi.org/10.1046/j.1365-2559.2001.01099.x>
- Popescu, I., Tudose, I., Racz, P., Munteau, B., Giurcaneanu, C. & Poppert, S. 2012. Human *Dirofilaria repens* Infection in Romania: a case report. *Case Reports in Infectious Diseases*, **2012**, 472976. <https://doi.org/10.1155/2012/472976>
- Pupić-Bakrač, A., Pupić-Bakrač, J., Beck, A., Jurković, D., Polkinghorne, A. & Beck, R. 2021. *Dirofilaria repens* microfilaremia in humans: case description and literature review. *One Health*, **13**, 100306. <https://doi.org/10.1016/j.onehlt.2021.100306>
- Railliet, A. & Henry, A. 1911. Remarques au sujet des deux notes de MM. Bauche et Bernard. *Bulletin de la Societe de Pathologie Exotique*, **4** (7), 485–488.
- Rivasi, F., Boldorini, R., Criante, P., Leutner, M. & Pampiglione, S. 2006. Detection of *Dirofilaria (Nochtiella) repens* DNA by polymerase chain reaction in embedded paraffin tissues from two human pulmonary

- locations. *Acta Pathologica, Microbiologica, et Immunologica Scandinavica*, **114** (7–8), 567–574. [https://doi.org/10.1111/j.1600-0463.2006.apm\\_423.x](https://doi.org/10.1111/j.1600-0463.2006.apm_423.x)
- Sassi, S. H., Abid, L., Dhoub, R., Mrad, K., Bouguila, H., Abbes, I., Driss, M., Ben Ghorbel, R. & Ben Romdhane, K. 2006. Conjunctival dirofilariasis due to *Dirofilaria Repens*. A new Tunisian case. *Journal Francais D'ophthalmologie*, **29** (2), e5.
- Simón, F., Diosdado, A., Siles-Lucas, M., Kartashev, V. & González-Miguel, J. 2022. Human dirofilariasis in the 21st century: a scoping review of clinical cases reported in the literature. *Transboundary and Emerging Diseases*, **69** (5), 2424–2439. <https://doi.org/10.1111/tbed.14210>
- Simón, F., Siles-Lucas, M., Morchón, R., González-Miguel, J., Mellado, I., Carretón, E. & Montoya-Alonso, J. A. 2012. Human and animal dirofilariasis: the emergence of a zoonotic mosaic. *Clinical Microbiology Reviews*, **25** (3), 507–544. <https://doi.org/10.1128/CMR.00012-12>
- Smith, R., Murillo, D. F. B., Chenoweth, K., Barua, S., Kelly, P. J., Starkey, L., Blagburn, B., Wood, T. & Wang, C. 2022. Nationwide molecular survey of *Dirofilaria immitis* and *Dirofilaria repens* in companion dogs and cats, United States of America. *Parasites & Vectors*, **15** (1), 367. <https://doi.org/10.1186/s13071-022-05459-5>
- Sonin, M. D. 1975. Essentials of nematology. Filariases of animals and man and the diseases caused by them. Nauka, Moscow, 1975 [In Russian].
- Suzuki, J., Kobayashi, S., Okata, U., Matsuzaki, H., Mori, M., Chen, K. R. & Iwata, S. 2015. Molecular analysis of *Dirofilaria repens* removed from a subcutaneous nodule in a Japanese woman after a tour to Europe. *Parasite*, **22**, 2. <https://doi.org/10.1051/parasite/2015002>
- Tasić, S., Stojković, N., Miladinović-Tasić, N., Tasić, A., Mihailović, D., Rossi, L., Gabrielli, S. & Cancrini, G. 2011. Subcutaneous dirofilariasis in South-East Serbia-case report. *Zoonoses and Public Health*, **58** (5), 318–322. <https://doi.org/10.1111/j.1863-2378.2010.01379.x>
- Vakalis, N. C. & Himonas, C. A. 1997. Human and canine dirofilariasis in Greece. *Parassitologia*, **39** (4), 389–391.
- Vucaj Cirilovic, V., Dobrosavljev, M., Niciforovic, D., Donat, D., Bogdanovic-Stojanovic, D. & Jukovic, M. 2014. Dirofilariasis of the breast: sonographic appearance. *Journal of Clinical Ultrasound*, **42** (7), 433–435. <https://doi.org/10.1002/jcu.22139>.
- Wong, M. M. & Brummer, M. E. 1978. Cuticular morphology of five species of *Dirofilaria*: a scanning electron microscope study. *Journal of Parasitology*, **64** (1), 108–114.

Received 30 April 2023

Accepted 22 August 2023