

QUALITY OF HYPOSPADIAS SURGERY IN A HIGH VOLUME HOSPITAL: REVIEW OF SHORT TO MEDIUM-TERM OUTCOMES AFTER SNODGRASS HYPOSPADIAS REPAIR

Naveed Haroon¹, Muhammad Asif², Maryam Ikramullah³, Zakir Khan⁴, Shahzad Ur Rehman⁵, Kausar Anwar⁶, Romana Bibi⁷

How to cite this article

Haroon N, Asif M, Ikramullah M, Rehman SU, Khan Z, Anwar K. Quality of Hypospadias Surgery in a High Volume Hospital: Review of Short to Medium Term Outcomes after Snodgrass Hypospadias Repair. J Gandhara Med Dent Sci. 2024;11(1): 17-20

Date of Submission: 11-06-2023

Date Revised: 20-11-2023

Date Acceptance: 22-11-2023

¹Sr. Specialist Pediatric, Urology Sabah Al Ahmad Urology Center Jamal Abdul Nasir Street, Kuwait

³MPhil Anatomy Scholar, Khyber Medical University, Peshawar

⁴Consultant Urologist, DHQ Hospital Pabbi, Nowshera

⁵Consultant Urologist, THQ Hospital, Pabbi, Nowshera

⁶Trainee Medical Officer, Department of Urology, MTI, Lady Reading Hospital, Peshawar

⁷Trainee Medical Officer, Department of Gynecology, Khyber Teaching Hospital, Peshawar

Correspondence

²Muhammad Asif, Associate Professor, Department of Urology, MTI, Lady Reading Hospital, Peshawar

☎: +92-335-9935313

✉: drasif_15@yahoo.com

doi:

ABSTRACT

OBJECTIVES

The study aimed to review short-term and medium-term outcomes of Snodgrass repair from one-year to two-year follow-up.

METHODOLOGY

It's a retrospective review of 114 patients (secondary data) with distal penile hypospadias without curvature who underwent Snodgrass repair performed by a single surgeon in the department of Urology, Lady Reading Hospital Peshawar from March 2021 to March 2022. Hypospadias objective score Evaluation (HOSE) was used for functional and cosmetic outcomes.

RESULTS

The mean age at the time of presentation for surgery was 3 years. The mean documented follow-up was 13 months (2-23 months). 51% (58) of patients presented with coronal hypospadias, followed by sub-coronal, distal and glanular hypospadias. Overall complication rate was 10%. Three patients developed a total breakdown of their wounds that needed further staged procedures. Meatal stenosis was noted in three patients requiring meatal dilatation, and another two came back with non-obliterative strictures. One had gentle dilatation, and the other underwent an optical urethrotomy. The rest of the four patients developed urethrocutaneous fistulae (UCF), ultimately getting repaired 6 months postoperatively. Good cosmetic and functional results were achieved in 93% of cases (HOSE score of 14 or above).

CONCLUSION

This study shows that Snodgrass repair is the best option for mainly correcting distal penile and midshaft hypospadias and has an acceptably low complication rate with better short to medium-term outcomes.

KEYWORDS: Hypospadias; Outcomes; Snodgrass; Surgery

INTRODUCTION

Snodgrass repair in 1994 transformed the management of distal hypospadias and exhibited good results with mid-shaft hypospadias as well.¹ Before the popularity of this procedure, there were around 200 techniques employed by urologists worldwide. How frequently hypospadias surgery is performed in Pakistan is unknown, but in the UK, almost 1500 hypospadias surgeries are done each year.^{2,3} Snodgrass repair involves a urethral plate incision distal to the meatus followed by tubularisation and flap coverage. In addition, this procedure strives to achieve slit-like meatus and conical glans at the end of surgery.^{4,5} A plausible explanation of the success of this technique is the high vascularity of the urethral plate and vascularised dartos tissue covering the repair.⁶ Urethral plate width has been considered historically as a limiting factor as far as Snodgrass repair was concerned, which led operators to adopt other

techniques such as Mathieu repair and island flap to make up for the narrow plate.⁷ Very little data is available about the long-term results; hence, we cannot make progress for these patients. The reported complication rate is 5 to 20% after distal hypospadias repair. This duration of follow-up is one of the culprits in a discrepancy in complication rate. Almost half of the literature supports less than one year of follow-up, while the literature suggests that 50% of complications occur after the first year of repair. There is an apparent lack of focus on the long-term urinary function, sexual function, and the psychological element of the repair.⁸ Though there is considerable literature on the short-term results of Snodgrass repair, minimal attention has been paid to evaluate its long-term results. This study aims to assess one to two years follow-up of these patients using this technique, which will give us a better insight into the long-term results of Snodgrass hypospadias repair.

METHODOLOGY

This is a retrospective review (secondary data) of 114 distal and mid-shaft hypospadias patients who underwent Snodgrass repair in the Urology Lady Reading Hospital Peshawar department from March 2021 to March 2022. Data was collected to determine patient age, procedure, complications, and follow-up. The functional and cosmetic results were objectively assessed using the Hypospadias Objective Score Evaluation (HOSE) score originally devised by Holland et al.²¹ The minimum score is 5, and the maximum total score is 16. A score of 14 or above was considered good regarding overall cosmesis and function. Two independent individuals assessed parameters, one from faculty and the other from urology trainees. Data about complications like meatal stenosis, urethral stricture and UCF were meticulously noted. Most of the patients were telephonically called for follow-up in the clinic to document the abovementioned parameters.

All patients aged less than 10 years with primary distal hypospadias and intact urethral plates were included in the study. Patients with failed previous repair were excluded from the study. The elaborate surgical technique of Snodgrass repair has been described in various studies.^{9,10} After circumferential sub-coronal incision and penile degloving, an artificial erection test was performed, and ventral curvature was corrected, if any, with dorsal two para midline plication sutures as popularized by Mingin and Baskin.⁶ A urethral plate was incised, extending from the meatus distally to allow easy plate closure over a feeding tube. The Dartos layer was harvested to cover the urethral repair, and glansplasty was performed. Foreskin was trimmed at the end for circumcision, and the skin was closed. A feeding tube was fixed to the glans using proline 5/0. The wound was wrapped around by aseptic paraffin-impregnated gauze loosely, followed by another layer of simple gauze tightened with the help of sticking. Data was analyzed by SPSS version 22. Mean and Standard deviation (SD) were calculated for age and follow-up time variables. Frequencies and percentages were calculated for categorical variables like the location of hypospadias, postoperative complications and procedure outcome.

RESULTS

A total of 114 patients were retrospectively reviewed. The exact distribution of meatal locations has been

shown in Fig 1. The mean age at the presentation was 3 years (2.5-9 years), with a mean follow-up of 13 months (2-23 months). Postoperative complications are enumerated in Table 1. Skin infection was observed in 12 patients, while 3 had dehiscence and meatal stenosis. Urethrocutaneous fistula (UCF) occurred in 4 patients requiring repair. Wide vertical slit meatus was achieved in the majority of the patients (n=95), whereas the rest had narrow meatus with good calibre urinary flow, excluding those who ended up having meatal stenosis and complete wound dehiscence. Except for 6 patients with the more proximal location of the meatus, the rest had glanular meatus after surgery. Similarly, 97% of patients' glans fell in the conical category, which contributed to good overall cosmetic outcomes as described by the opinions and observations of most parents (n=97). Only 7 patients were reported to have deviated and splayed streams, and as far as erections are concerned, 94% of patients were seen to have straight erections during multiple follow-ups and assessment of visuals, as shown in Table 2. Good cosmetic and functional results were achieved in 93% of cases by using the HOSE score system (Score of 14 or above). Likewise, five patients had satisfactory cosmesis and poor cosmesis, including those who developed dehiscence.

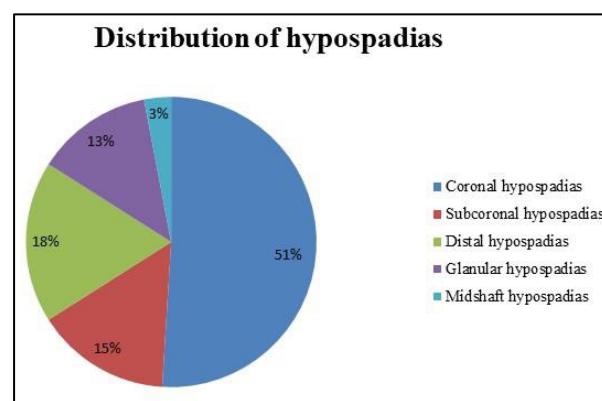


Figure 1: Pie Chart Showing the Distribution of Meatus in Hypospadias Patients

Table 1: Postoperative Complications

Complications	Patients(n)	%age	Management
Skin infection	12	10.5	Antibiotics
Meatal stenosis	03	2.6	Dilatation/Optical
Dehiscence	03	2.6	Revision surgery
Urethrocutaneous fistula	04	3.5	Fistula repair
Skin infection	12	10.5	Antibiotics

Table 2: Medium-Term Outcome Parameters

Outcome Assessed	Parameters	Number of Patients (n)	%age
Meatal Shape	Vertical	95	83
	slitcircular	19	17
Meatal Location	Glanular	108	95
	Coronal	04	04
Glanular Shape	Subcoronal	02	02
	Conical	111	97
Urinary Stream	Flat	03	03
	Forward/Straight	107	94
Erections	Splayed	07	06
	Straight	109	96
Overall Cosmesis	Mild bend(less than 10 degree)	05	04
	Good	105	93
	Satisfactory	06	05
	Poor	03	02

DISCUSSION

The most commonly performed procedure for distal hypospadias is TIP, which is a modified form of two procedures: urethral plate incision and tubularization.¹¹ The optimal age of surgery is debatable, with some surgeons doing it as early as 3 to 6 months of life, the reason being sufficient penile growth at 6 months of age and reduced anaesthesia risk. Aslam et al. repaired it at 3 years of age to allow maximum child development and eliminate the risk of anaesthesia.¹² In our study, the mean age of surgery is 3 years, with the maximum age reaching up to 9 years primarily because of late presentation of patients. The beauty of TIP repair is the low complication rate and excellent cosmesis with good functional outcomes.¹³ Superficial skin infection was our series's most common complication (10.5%). Factors contributing possibly to the majority of skin infections in our patients were poor wound hygiene at home, low compliance with medications and overall low socioeconomic status. UCF occurred in 4(3.5%) patients, comparable to the internationally reported range, i.e. 0-7%. One patient with UCF was associated with meatal stenosis, and 3 patients were those who had a mid-penile meatal location in the first place. One small fistula was treated conservatively by simple catheterization, and three were repaired after 6 months of the initial repair. Incidence of meatal stenosis after TIP repair has been reported up to 5.7%, and our results essentially fall in that range, i.e., 2.6%.¹⁴ Wound dehiscence reported in 2.6% of our cases occurred predominantly in the initial period of study, but the technique consolidated and experience gained along with the development of parent's education program brought down the dehiscence to complete nought. We achieved better outcomes of TIP repair, especially regarding overall cosmesis and urinary stream. Ninety-three per cent of the patients attained a score of 14 or above compared to the 96% reported by Gupta et al. in their study (15-21). Although parameters for objective

assessment of hypospadias repair are still debatable, meatus shape and location are two leading causes of dissatisfaction among parents and, therefore, the main reason for the revision of surgery. In one such series, almost 50% of the parents were satisfied with the overall cosmesis and aesthetic appearance of the penis. In our study, 75% of the parents were satisfied with the cosmetic outcome. We have noticed parents to be more concerned with stream and glanular meatus rather than the configuration of the glans and the circumcised look of the penis.

LIMITATIONS

Certain aspects of the study had an impact on the overall results. Being a retrospective study, the patients must be followed for extended periods to establish long-term results. In addition, we did not perform uroflowmetry to assess the flow rate objectively. Furthermore, there was no uniformity in the operative technique of hypospadias repair, which also affected the outcome.

CONCLUSIONS

Our study shows that Snodgrass repair is the best option for mainly correcting distal penile and midshaft hypospadias and has an acceptably low complication rate with better short to medium-term outcomes.

CONFLICT OF INTEREST: None

FUNDING SOURCES: None

REFERENCES

- Alwaeli HH, Hasan Al-Timimi HF, Ismail MB. Assessment of functional and cosmetic outcomes of Extended-tubularized incised plate for mid-shaft and distal hypospadias as a modification of Snodgrass repair: a cross-sectional study. *Ann Med Surg (Lond)*. 2023 Oct 1;85(10):4745-9.
- Poerwosusanta H, Poerwosusanta AR, Poerwosusanta EE, Aditia D. Perioperative techniques and long-term outcomes in hypospadias: A systematic review. *Malays J Med Health Sci*. 2023 Sep 1;19(5).
- Asad S, Khan FA, Ali S, Khan H, Rafaqat H, Ud I, Khattak D. Snodgrass hypospadias repair at Ayub teaching hospital: an audit of complications and outcomes. *Journal of Ayub Medical College Abbottabad-Pakistan*. 2023 Apr 1;35(2).
- Elshimy K. Is a urethral stent necessary after tubularized incised-plate urethroplasty for primary distal hypospadias repair: initial experience? *Egypt J Surg*. 2022 Apr 1;41(2):502-6.
- Jonuzi A, Zvizdić Z, Granov N, Mišanović V, Kulovac B. Primary distal hypospadias repair with Snodgrass technique: a prospective cohort study. *Med J*. 2022 Jul 1;28.
- AbouZeid A. Tubularized Incised Plate Urethroplasty for Primary Hypospadias Repair: versatility versus Limitations. *The J Genit Surg*. 2017;1(Ready articles):1-9.
- Mahmud SM, Tashfika UH, Ferdous KM. Outcome of classical tubularized incised-plate urethroplasty (TIP) for primary anterior hypospadias repair: 5 years' experience. *Saudi*

- J Med. 2023;8(1):33-7.
8. Long CJ. Long-term follow-up in hypospadias repair: what is it and are we there yet?. Hypospadias surgery: an illustrated textbook; 2022 May 22. p. 891-6.
 9. Bhat A. Modified tubularized incised urethral plate urethroplasty. In Hypospadiology: principles and practices 2022 Mar 10 (pp. 101-12). Singapore: Springer.
 10. Wali IM, AbouZeid AA, Radwan NA, GadAllah MA, Ghanem WA, El-Naggar O. Preoperative topical testosterone for penile hypospadias repair: a comparative study. Ann Pediatr Surg. 2020 Dec;16(1):1-9.
 11. Snodgrass W. Tubularized, incised plate urethroplasty for distal hypospadias. J Urol. 1994;151(2):464-5.
 12. Aslam R, Campbell K, Wharton S, Bracka A. Medium to long term results following single stage Snodgrass hypospadias repair. J Plast Reconstr Aesthet Surg. 2013;66(11):1591-5.
 13. Pan P. An objective assessment and comparison of the cosmetic outcome: parental perspective after tubularized incised plate urethroplasty with foreskin reconstruction and circumcision. J Indian Assoc Pediatr Surg. 2022 Nov;27(6):713-7.
 14. Al-TaHER R, Nofal M, Yousef AJ, Rashdan M, Tarawneh A, Alsmadi J et al. Double dartos flap layer in tubularized incised plate urethroplasty to prevent urethrocutaneous fistula in uncircumcised patients with distal hypospadias. Asian J Androl. 2023 Jan;25(1):93-7.
 15. Güner E, Ankan Y. Evaluation of surgical outcomes in different hypospadias types by HOSE score. J Urol Surg. 2020;7(1):54-7.
 16. Aziz A, Khan M, Ullah H, . O. Decreasing complications in distal hypospadias surgery, with single stage repairs. Pak J Med Health Sci. 2023 Apr 18;17(2):753-5.
 17. Gupta V, Yadav SK, Alanzi T, Amer I, Salah M, Ahmed M. Grafted tubularized incised-plate urethroplasty: an objective assessment of outcome with lessons learnt from surgical experience with 263 cases. Arab J Urol. 2016;14(4):299-304.
 18. Rabari MG, Tank R, Patel S, Gopat K. Complications of hypospadias surgery experience in A tertiary hospital. Natl J Integr Res Med. 2022 Mar 1;13(2).
 19. Snodgrass WT. Tubularized incised plate hypospadias repair: indications, technique, and complications. Urology. 1999;54(1):6-11.
 20. Samuel M, Wilcox DT. Tubularized incised plate urethroplasty for distal and proximal hypospadias. BJU Int. 2003;92(7):783-5.
 21. Holland AJ, Smith GH, Ross FI, Cass DT. HOSE: an objective scoring system for evaluating the results of hypospadias surgery. BJU Int. 2001;88(3):255-8.

CONTRIBUTORS

1. **Naveed Haroon** - Concept & Design
2. **Muhammad Asif** - Data Acquisition; Supervision
3. **Maryam Ikramullah** - Data Analysis/Interpretation
4. **Zakir Khan** - Drafting Manuscript
5. **Shahzad Ur Rehman** - Critical Revision
6. **Kausar Anwar** - Data Acquisition
7. **Romana Bibi** - Final Approval



LICENSE: JGMDS publishes its articles under a Creative Commons Attribution Non-Commercial Share-Alike license (CC-BY-NC-SA 4.0).
 COPYRIGHTS: Authors retain the rights without any restrictions to freely download, print, share and disseminate the article for any lawful purpose.
 It includes scholarly networks such as Research Gate, Google Scholar, LinkedIn, Academia.edu, Twitter, and other academic or professional networking sites.