

2023

A case of a prominent coumadin ridge poses a diagnostic dilemma

Astha Prasai

Rochester General Hospital, prasaia084@gmail.com

Krupa Shingada

Rochester General Hospital, krupashingada91@gmail.com

Omar AlAli

Rochester Regional Health System, Omar.AIAli@rochesterregional.org

Nawid Latifi

Rochester General Hospital, nawidlatifi@gmail.com

Mohammad Abu Sheikha

Rochester General Hospital, Mohammad.AbuSheikha@rochesterregional.org

Jian Shan

Rochester General Hospital, jian.shan@rochesterregional.org

Follow this and additional works at: <https://scholar.rochesterregional.org/advances>



Part of the [Medicine and Health Sciences Commons](#)



This work is licensed under a [Creative Commons Attribution-NonCommercial 4.0 International License](#)

Recommended Citation

Prasai A, Shingada K, AlAli O, Latifi N, Abu Sheikha M, Shan J. A case of a prominent coumadin ridge poses a diagnostic dilemma. *Advances in Clinical Medical Research and Healthcare Delivery*. 2023; 3(4). doi: 10.53785/2769-2779.1163.

ISSN: 2769-2779

This Case Report is brought to you for free and open access by RocScholar. It has been accepted for inclusion in *Advances in Clinical Medical Research and Healthcare Delivery* by an authorized editor of RocScholar. For more information, please contact Advances@rochesterregional.org.

A case of a prominent coumadin ridge poses a diagnostic dilemma

Author ORCID ID:

Astha Prasai: 0000-0002-4412-5038

Abstract

Introduction:

Coumadin ridge, also known as warfarin ridge, is an embryological remnant in the form of a muscular ridge in the left atrium. We present a case of a middle-aged gentleman with prominent Coumadin ridge.

Case:

49 year old male with history of pulmonary embolism (PE) (on Xarelto), attention deficit hyperactivity disorder (ADHD), prior polysubstance use, currently everyday smoker presented to the emergency department with history of shortness of breath and productive cough for 8 weeks. Initially he was treated with doxycycline for bronchitis and later with azithromycin for pneumonia as outpatient. He did not have chest pain, palpitations or limb swelling. On examination, heart sounds were distant and pulsus paradoxus was noted. He underwent computed tomography angiography (CTA) of the chest which revealed moderate left pleural effusion and a large pericardial effusion. Xarelto was held. He underwent pericardial window and thoracocentesis and chest tube placement for left pleural effusion. Intraoperative transesophageal echocardiography (TEE) showed likely thrombus or mass in the left atrial appendage (LAA). Thought to be xarelto failure, he was started on heparin for anticoagulation. He was also suspected to have malignancy given his extensive tobacco smoking history and family history of lung cancer. CT chest and fluid analysis was negative for malignancy. Cardiac magnetic resonance imaging (MRI) showed features suggestive of effusive constrictive pericarditis, left atrium was normal. Repeat TEE showed prominent Coumadin ridge with prominent LAA trabeculation with no mass or thrombus. Xarelto was restarted. Pericardial and pleural fluid analysis was negative for infectious workup including tuberculosis and autoimmune workup was also negative. He was started on colchicine and tapering dose of steroids for constrictive pericarditis. He improved and was discharged home to follow up with cardiology outpatient.

Discussion:

In our case, the echogenic hyperdensity on intraoperative transesophageal echocardiography raised suspicion of mass or thrombus. Our patient was already on Xarelto for pulmonary embolism. Direct oral anticoagulants (DOACs) failure has been reported in only approximately 2.1% of patients in large clinical trials. It is really interesting how coumadin ridge can almost be missed and how our patient was almost deemed to have xarelto failure, highlighting about the importance of being mindful about how the presence of prominent coumadin ridge could be easily mistaken for a pathology when it is not.

Keywords

coumadin ridge, transesophageal echocardiography, rivaroxaban

Creative Commons License



This work is licensed under a [Creative Commons Attribution-NonCommercial 4.0 International License](https://creativecommons.org/licenses/by-nc/4.0/)

Conflict of Interest Statement

None

This case report is available in *Advances in Clinical Medical Research and Healthcare Delivery*:
<https://scholar.rochesterregional.org/advances/vol3/iss4/1>

CASE REPORT

A Case of a Prominent Coumadin Ridge Poses a Diagnostic Dilemma

Astha Prasai*, Krupa Shingada, Omar Al Ali, Nawid Latifi, Mohammad A. Sheikha, Jian Shan

Rochester General Hospital, USA

Abstract

Introduction: Coumadin ridge, also known as warfarin ridge, is an embryological remnant in the form of a muscular ridge in the left atrium. We present a case of a middle-aged gentleman with prominent Coumadin ridge.

Case: 49 year old male with history of pulmonary embolism (PE) (on Rivaroxaban), currently every day smoker presented to the emergency department with history of shortness of breath and productive cough for 8 weeks. Heart sounds were distant and pulsus paradoxus was noted. Computed tomography angiography (CTA) of the chest revealed moderate left pleural effusion and a large pericardial effusion. Rivaroxaban was held. He underwent pericardial window and thoracocentesis and chest tube placement for left pleural effusion. Intraoperative transesophageal echocardiography (TEE) showed a likely thrombus or mass in the left atrial appendage (LAA). Thought to be rivaroxaban failure, he was started on heparin for anticoagulation. CT chest and fluid analysis was negative for malignancy. Cardiac magnetic resonance imaging (MRI) showed features suggestive of effusive constrictive pericarditis, left atrium was normal. Repeat TEE showed a prominent Coumadin ridge with prominent (LAA) trabeculation. Rivaroxaban was restarted. Fluid analysis was negative for infectious workup including tuberculosis. Colchicine and a tapering dose of steroids was started. He improved and was discharged home.

Discussion: In our case, the echogenic hyperdensity on intraoperative transesophageal echocardiography raised suspicion of mass or thrombus. Our patient was already on Rivaroxaban for pulmonary embolism. Direct oral anticoagulants (DOACs) failure has been reported in only approximately 2.1% of patients in large clinical trials. It is really interesting how coumadin ridge can almost be missed and how our patient was almost deemed to have rivaroxaban failure, highlighting about the importance of being mindful about how the presence of prominent coumadin ridge could be easily mistaken for a pathology when it is not.

Keywords: Coumadin ridge, Transesophageal echocardiography, Rivaroxaban

1. Background

Coumadin ridge, also known as warfarin ridge is an embryological remnant in the form of a muscular ridge in the left atrium. Radiologically, it is an important anatomical structure to be aware of as it can often be mistaken for a thrombus or a mass.¹ We present a case of a middle aged gentleman with prominent Coumadin ridge mimicking a mass or a thrombus in left atrial appendage (LAA), also thought to be Rivaroxaban failure.

2. Case

49-year-old male with history of unprovoked PE (on Rivaroxaban), ADHD, prior polysubstance use, currently everyday smoker presented to the ED with history of shortness of breath and productive cough for 8 weeks. He had pulmonary embolism about 15 years ago and was on warfarin for about a year. He did not have any formal hypercoagulable workup thereafter. In 2020, he had second bilateral pulmonary embolism that was thought to be unprovoked and was on Rivaroxaban thereafter.

Accepted 30 June 2023.
Available online ■■■

* Corresponding author.
E-mail address: prasaia084@gmail.com (A. Prasai).

<https://doi.org/10.53785/2769-2779.1163>
2769-2779/© 2023 Rochester Regional Health.

Eight weeks back, he was treated with doxycycline for bronchitis initially and later with azithromycin for pneumonia as outpatient. He did not have chest pain, palpitations or limb swelling. On examination, heart sounds were distant and pulsus paradoxus was noted. He had leukocytosis (white blood cell count (WBC) $13.6 \times 10^3/\mu\text{L}$ with predominant neutrophils), anemia (Hb 12.3 g/dl from baseline 14 g/dl). Electrocardiogram (EKG) showed low voltage QRS with nonspecific ST-T wave changes. Chest X-ray showed left lower lobe opacity. He underwent computed tomography angiography (CTA) chest which revealed moderate left pleural effusion and a large pericardial effusion. Rivaroxaban was held. He underwent pericardial window and thoracocentesis and chest tube placement for left pleural effusion. 1440 cc serosanguinous left pleural fluid and 360 cc serosanguinous pericardial fluid was drained. Intraoperative transesophageal echocardiography (TEE) showed likely thrombus/mass in left atrial appendage (Fig. 1). Thought to be Rivaroxaban failure, he was started on heparin for anticoagulation. He was also suspected to have malignancy given his extensive tobacco smoking history and family history of lung cancer. CT chest and fluid analysis was negative for malignancy. Cardiac magnetic resonance imaging (MRI) showed features suggestive of effusive constrictive pericarditis, left atrium was normal (Fig. 2). Repeat TEE showed prominent Coumadin ridge with prominent left atrial appendage (LAA) trabeculation with no mass or thrombus (Fig. 3). Rivaroxaban was restarted. Pericardial biopsy showed fibrinous and reactive pericarditis. Pericardial and pleural fluid analysis was negative for autoimmune and infectious workup including tuberculosis. He was

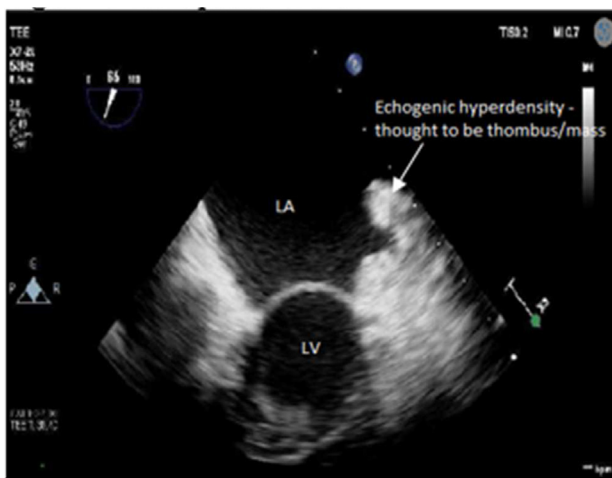


Fig. 1. Intra-operative TEE showing echogenic hyper-density in the left atrial appendage.

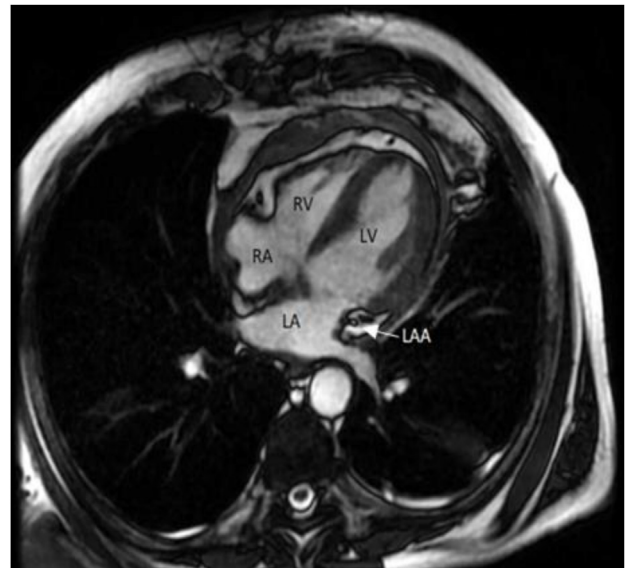

Fig. 2. Cardiac MRI showing heterogeneous thickening of pericardium, normal LAA.

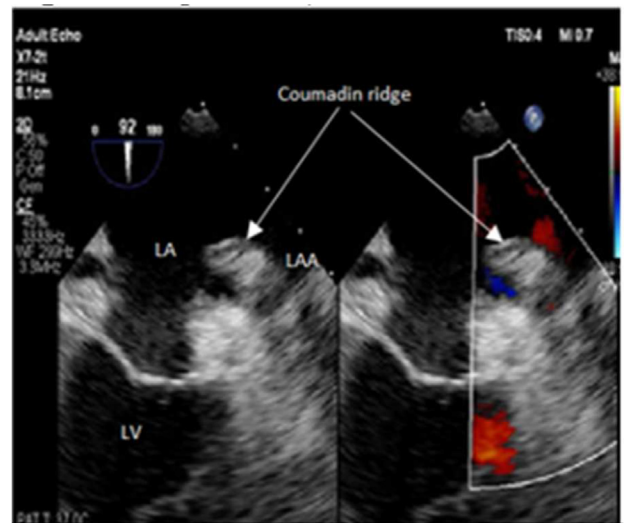


Fig. 3. Repeat TEE showing prominent Coumadin ridge in LAA.

started on colchicine and tapering dose of steroids for constrictive pericarditis. He improved and was discharged home to follow up with cardiology outpatient.

3. Discussion

Coumadin ridge is the confluence of the left superior pulmonary vein and the opening of left atrial appendage in the left atrium.¹ It consists of the ligament of Marshall, which is the remnant of the superior vena cava, an autonomic nerve bundle and a small atrial or sinoatrial artery.²

The Coumadin ridge is a normal variant and its name arises from the fact that, when prominent, it is often mistaken for a thrombus resulting in unnecessary anticoagulation. It can also be mistaken for a mass. However, sometimes true tumor or thrombi may be attached to the Coumadin ridge.³ Its utility in catheter ablation for atrial fibrillation has also been described.⁴

Often, Coumadin ridge can be identified on transthoracic echocardiography (TTE).⁵ It is usually thin in the proximal part and bulbous in the distal part which makes it look like a cotton tip applicator and is described as a Q tip sign on echocardiography.^{1,6} If still in doubt after TTE, full volume 3-D TTE with color Doppler can be done. However, posterior left atrial structures may not be well visualized on TTE.⁷ Therefore, TEE can help in better delineation. The motion of the artifact, presence of spontaneous echo contrast (SEC), using intravenous contrast, multiple views (X-plane, two orthogonal views of the lesion) can help interrogate the echogenic lesion to differentiate thrombus from Coumadin ridge in LAA.⁸ In most confusing scenarios, cardiac MRI or CT will be necessary for differentiation. On steady state free precession (SSFP) on cardiac MRI, Coumadin ridge can appear as a dark mass protruding into the bright left atrial cavity. On T1 and T2 weighted images, Coumadin ridge has same intensity as adjacent myocardial tissue whereas myxomas show high signal on T2 weighted images.⁵ On late gadolinium enhancement, Coumadin ridge does not show late enhancement whereas thrombus is demonstrated as low signal intensity mass around high intensity structure like blood whereas a myxoma or fibroelastoma has high signal intensity compared to the surrounding myocardium.^{5,9}

In our case, identification of echogenic hyper density on intraoperative transesophageal echocardiography raised suspicion of mass or thrombus. On cardiac MRI, pericardium was partially bright on T2 weighted images suggestive of edema and on post gadolinium enhancement, diffuse pericardial hyperenhancement was seen. However, no abnormalities were noted in the left atrium.

Our patient was already on Rivaroxaban for pulmonary embolism. Fluid cytology ruled out malignancy. Possibility of a thrombus could not be definitively ruled out. He had TTE done in 2020 which did not show any abnormality in the left atrium. He was planned to start on lovenox followed by warfarin if thrombus was identified on repeat transesophageal echocardiography.

Direct oral anticoagulants (DOACs) have been used widely in venous thromboembolism and in nonvalvular atrial fibrillation to prevent stroke and

systemic embolization. Factor Xa activity can be checked but not routinely available in all labs.¹⁰

DOACs failure has been reported in approximately 2.1% of patients in large clinical trials. In a single center study, 61% of patients with failure on DOAC were receiving DOAC for treatment of acute VTE and about 25% were on Rivaroxaban alone.¹⁰

In our case, repeat transesophageal echocardiography identified the hyper-density to be Coumadin ridge. There are a couple of interesting key points from this case report: 1) Cardiac MRI was not able to identify the Coumadin ridge in our patient; 2) Our initial leading diagnosis was Rivaroxaban failure, highlighting the importance of awareness of what the Coumadin ridge is, so as not to misdiagnose this benign anatomic variant for alternative pathology.

Conflicts of interest

None.

References

- McKay T, Thomas L. 'Coumadin ridge' in the left atrium demonstrated on three dimensional transthoracic echocardiography. *Eur J Echocardiogr.* 2008;9(2):298–300. <https://doi.org/10.1016/j.euje.2006.10.002>.
- Rajiah P, MacNamara J, Chaturvedi A, Ashwath R, Fulton NL, Goerne H. Bands in the heart: multimodality imaging review. *Radiographics.* 2019;39(5):1238–1263. <https://doi.org/10.1148/rgr.2019180176>.
- Lak HM, Kerndt CC, Unai S, Maroo A. Cardiac papillary fibroelastoma originating from the coumadin ridge and review of literature. *BMJ Case Rep.* 2020;13(8):e235361. <https://doi.org/10.1136/bcr-2020-235361>.
- Piątek-Koziej K, Holda J, Tyrak K, et al. Anatomy of the left atrial ridge (coumadin ridge) and possible clinical implications for cardiovascular imaging and invasive procedures. *J Cardiovasc Electrophysiol.* 2020;31(1):220–226. <https://doi.org/10.1111/jce.14307>.
- Gupta S, Plein S, Greenwood JP. The Coumadin ridge: an important example of a left atrial pseudotumour demonstrated by cardiovascular magnetic resonance imaging. *J Radiol Case Rep.* 2009;3(9):1–5. <https://doi.org/10.3941/jrcr.v3i9.210>.
- Lodhi AM, Nguyen T, Bianco C, Movahed A. Coumadin ridge: an incidental finding of a left atrial pseudotumor on transthoracic echocardiography. *World J Clin Cases.* 2015;3(9):831–834. <https://doi.org/10.12998/wjcc.v3.i9.831>.
- Jabri A, Deutch Z, Butt M, et al. A diagnostic dilemma upon discovery of a left atrial mass using an intracardiac echocardiogram. *HeartRhythm Case Rep.* 2021;7(8):507–509. <https://doi.org/10.1016/j.hrcr.2021.06.004>.
- Abdelmoneim SS, Mulvagh SL. Techniques to improve left atrial appendage imaging. *J Atr Fibrillation.* 2014;7(1):1059. <https://doi.org/10.4022/jafib.1059>.
- Weinsaft JW, Kim HW, Shah DJ, et al. Detection of left ventricular thrombus by delayed-enhancement cardiovascular magnetic resonance: prevalence and markers in patients with systolic dysfunction. *J Am Coll Cardiol.* 2008;52(2):148–157. <https://doi.org/10.1016/j.jacc.2008.03.041>.
- McIlroy G, Smith N, Lokare A, Beale K, Kartsios C. Treatment failure in patients receiving direct oral anticoagulants: clinical management and outcomes from a single-center review of 59 consecutive patients. *Blood.* 2018;132(Supplement 1):5058. <https://doi.org/10.1182/blood-2018-99-111108>.