

11. Schiff, E. A., Bovine Anaplasmosis Can be Controlled. *Journal of Veterinary Medicine Association*, Volume 159 (Dec. 1971): 1531-1533.
12. Soulsby, E. J. L., *Helminths, Arthropods, and Protozoa of Domesticated Animals*. 6th ed.: 752-753.
13. Smith, H. A., Jones, T. C., and Hunt, R. D., *Veterinary Pathology*. 4th ed. Lea and Febiger, Philadelphia (1972): 548-550.
14. United States Department of Agriculture, APHIS, What You Should Know About Anaplasmosis. 91-20 (April 1974).
15. Butler, Dr., State Veterinarian. Des Moines, Iowa.

Lead Poisoning in Dogs

by
John Bengfort, D.V.M.*
Dr. Robert W. Carithers†

SUMMARY

Lead poisoning is seen primarily in dogs less than one year old; the highest percentage of those are less than five months old. Many sources of lead are available to young dogs, although lead-based paint and linoleum are the principal problems. The characteristic clinical signs involve the gastrointestinal system (vomiting, colic and diarrhea), nervous system (hysteria, convulsions and nervousness) or both. Generally the signs are followed by a period of normalcy. Dogs are unique in that clinical pathological analysis showing many nucleated red blood cells and basophilic stippling in the absence of severe anemia is strongly suggestive for lead poisoning. However, analysis for blood lead with over 0.35 ppm. is the best diagnostic tool. Chelation therapy with Ca EDTA is the treatment of choice.

CASE REPORT

On August 1, 1975, a one-year-old male beagle was admitted to Stange Memorial Clinic as a lead poisoning suspect. The

dog's history included vomiting and abdominal pain for the past 10 days and nervous signs of two days duration manifested by convulsions, running, crying and apparent blindness. The dog reportedly had been tethered adjacent to an old building from which the owner had been scraping paint. On outpatient examination, the beagle appeared depressed and emaciated and vomited a yellow foamy material. He had reportedly not eaten any significant amount of food for about three weeks. When left to himself, he would stretch out his front legs and rest his head on them while keeping the hind legs erect. Abdominal radiographs revealed numerous flecks in the colon which could have been lead-based paint chips. Blood samples for hematologic examination and lead analysis were taken. Chelation therapy was initiated on the basis of the radiographs. He was given 12 mg/lb. of Ca EDTA subcutaneously. The blood analysis showed a hemoglobin of 13.6, PCV of 42, and a corrected WBC of 8,625. There were 387 NRBC/100 WBC, along with basophilic stippling, polychromasia and anisocytosis. The blood lead level was 1.34 ppm. The dog was given several enemas initially and was continued on Ca EDTA, lactated ringer's and glucose, periodically, for 14 days. He had several convulsions and went into more severe depression at the onset of Ca EDTA

*Dr. Bengfort is a 1976 graduate of the College of Veterinary Medicine, Iowa State University.

†Dr. Robert W. Carithers is Professor of Veterinary Clinical Sciences, Iowa State University.

therapy, but when it was stopped for one to two days, he would appear very bright and alert. As the treatment regime progressed, the Ca EDTA didn't have as much lead available to mobilize and therefore no effects were noted.

Periodic monitoring of blood and urine lead indicated that the blood lead was 0.44 ppm. and the urine lead 15.4 ppm. on August 8th. On August 15th, the blood lead was 0.5 ppm. and urine lead 1.4 ppm.

The dog was hospitalized a total of 15 days, with a total of 10 days Ca EDTA treatments. Upon his release, he was very active and playful, eating well and regaining lost weight.

DISCUSSION

In a study at Angell Memorial Animal Hospital in Boston, it was found that about one in every 25 dogs under six months of age had lead poisoning. They also noted a higher incidence in the summer months. This may be due to increased Vitamin D produced because of more exposure to sunlight aiding in intestinal absorption of ingested lead. Also, there are more sources of lead available in summer (2,5,6).

Due to the uncontrollable chewing habits of young dogs, anything containing lead can be a potential source. Lead-based paint has been the primary agent when the source was known. Unfortunately, in 70% of the documented cases, the source was unknown (6). Other lead containing items include linoleum, putty, toys, golf balls, rug pads, solder, batteries, glazed ceramic water bowls, lead weights, fishing sinkers, drapery weights, and plumbing materials. Automobile exhaust from leaded gasoline in areas of heavy traffic has been incriminated in those cases where the source was unknown (6).

Increased incidence of lead poisoning is usually in slum areas or where there is a high amount of natural lead available in the soil, such as around lead mines (3,5).

Clinically, the dog exhibits gastrointestinal and nervous symptoms. The gastrointestinal signs usually are apparent first and consist of vomiting, diarrhea (or constipation), anorexia, and marked emaciation. Colic or pain is the most consistent finding and is manifested by

whining, restlessness, abnormal positions, tensing of abdominal muscles, and crying (1,2). This is followed by a period of quiescence, after which the nervous signs develop. The nervous signs consist of hysteria, convulsions, champing, nervousness, and behavioral changes, particularly depression (1,2,5).

Blood lead analysis is the best diagnostic method for lead poisoning. Levels above 0.35 ppm. are indicative of unusual exposure. Normal levels are in the range of 0-0.15 ppm. (1,7). Since blood analysis for lead is not rapidly accomplished, other diagnostic methods have proven to be quite definitive. The hematologic finding of many nucleated red blood cells along with basophilic stippling of red blood cells in the absence of anemia is nearly pathognomonic. The number of nucleated RBC's varies directly with the amount of lead in the blood and hyperplasia of erythroid elements in bone marrow. One will see nucleated RBC's in severe anemia and hemangiosarcoma, but in lower numbers and rarely accompanied by stippled RBC's. In man and other animals, stippled RBC's are not uncommon in many conditions, but in dogs they are rarely seen to the same degree as in lead poisoning. Polychromatophilia, anisocytosis, poikilocytosis, and target cells are also numerous. Lead causes the RBC to be more fragile and shortens its life span. The fragile RBC's are slowly destroyed and replaced in part by immature and abnormal RBC's which account for the nucleated RBC's and basophilic stippling. Lead interrupts hemoglobin synthesis at several steps and interferes with normal maturation process of the RBC's. A slowly developing anemia may occur in the face of hyperplastic bone marrow in a long standing involvement (1,2,5,6).

Radiographs may be of considerable help in making an immediate diagnosis. The radiopaque lead-based paints will be visualized as small flecks in the gastrointestinal tract of the dog. Other lead objects will also show up. These must not be confused with gravel or chips of bone. Examination of feces for chips of paint or bone may suggest the nature of the substances in the gastrointestinal tract that were seen radiographically. Lead lines may develop in the metaphysis of the long bones

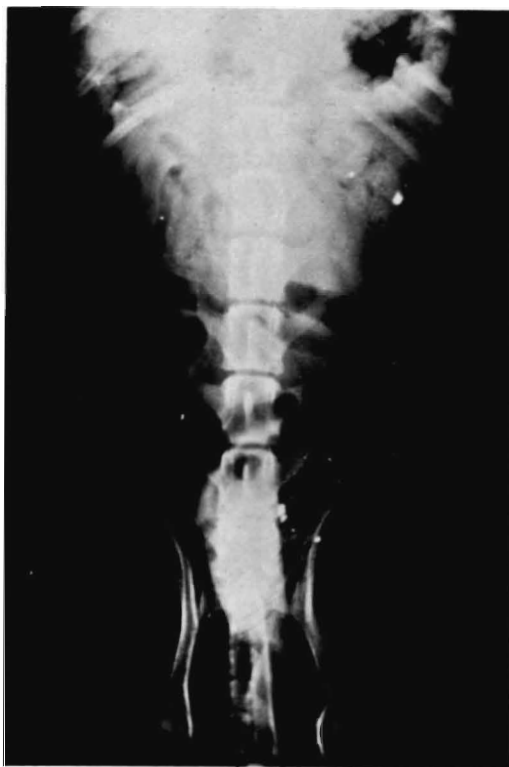
in immature dogs with poisoning of over 10 days' duration. These lines are seen in many bones and the ribs, but are best seen proximal to the open epiphysis of the distal radius, ulna and metacarpal bones. These changes, called metaphyseal sclerosis, are the result of incorporation of lead into sites of active bone formation, causing a dense zone of mineralized cartilage and bone. However, these changes are also seen in phosphorus and Vitamin D intoxication (2).

Urinalysis may be normal but usually hyaline and granular casts are found and sometimes small amounts of protein.

Once diagnosis is made, treatment should be started immediately to remove the lead from the body. Enemas can effectively remove small lead-containing objects from the large intestine. Emetics will remove lead from the upper gastrointestinal tract. Sedatives may be given to control convulsions and other nervous signs. Lead that has been absorbed by the body can be effectively removed by chelation with Ca EDTA given subcutaneously at the rate of 12 mg/lb. four times daily for five days, but not to exceed

two grams per day. Caution must be used to prevent the dog from going into convulsions and showing other nervous signs by mobilizing too much lead too fast. In the severe cases, the treatment should be repeated in five days, especially if neurological signs recur (1,2,3,6). Therapy should be accompanied by urine lead analysis to monitor success of treatment.

It has been suggested that lead stored in the bones may be mobilized spontaneously by infection, strenuous exercise, severe trauma or metabolic disorders. Therefore, lead ingested by a young puppy may be stored in the body in a low level, not causing immediate clinical signs (4). A type of chronic, low level lead poisoning may appear similar to canine distemper since more often than not no source of exposure to lead is found or no evidence of exposure is found except by blood lead analysis and hematologic examination (5). In one study of 27 cases of distemper diagnosed in dogs, 14 had liver Pb of 75 ppm (4). Samples of liver obtained post mortem provide the best single diagnostic test for lead poisoning, the upper limit of normal being 3.5 ppm.



This radiograph reveals the flecks of lead-based paint in the intestinal tract.

The cortex of the kidney is also a good post mortem source with normal lead level being below 1-3 ppm (1).

Lead is removed slowly from the body primarily by the kidneys. Clinical pathology shows that in the kidney, lead causes degeneration and necrosis of renal tubules which may result in chronic nephritis (5). The nervous signs come as a result of segmented degeneration which results in un-unified motor nerve conduction resulting in ataxia and uncoordinated musculoskeletal movements (1). The brain lesions include degeneration and fibrosing of vessels, hemorrhages and gliosis.

Consequently, as a result of the various effects of lead poisoning, a differential diagnosis must include distemper, hepatitis, rabies, chronic nephritis, and poisoning by other toxic agents.

BIBLIOGRAPHY

1. Buck, W. B., G. D. Osweiler and G. A. Van Gelder. *Clinical and Diagnostic Veterinary Toxicology*. Dubuque, Iowa. Kendall-Hunt Publishing Co., 1973 pp. 193-201.
2. Kirk, R. W. *Current Veterinary Therapy V*. Philadelphia, Pa. W. B. Saunders Co., 1974 pp. 133-139.
3. Scott, H. M. Lead Poisoning in Small Animals. *Vet Record*, 1963, 75:830-833.
4. Wilson, M. R. and G. Lewis. Lead Poisoning in Dogs. *Vet Record*, 1963, 75: 787-791.
5. Zook, B. C., J. L. Carpenter and E. B. Leads. Lead Poisoning in Dogs. *JAVMA*, 1969, 155:1329-1342.
6. Zook, B. C., J. L. Carpenter and R. M. Roberts. Lead Poisoning in Dogs: Occurrence, Source, Clinical Pathology and Electroencephalography. *American Journal Vet Research*, 1972a. 33:891-902.
7. Zook, B. C., L. Kopito, J. L. Carpenter, D. V. Cramer and H. Shwachman. Lead Poisoning in Dogs: Analysis of Blood, Urine, Hair and Liver for Lead. *American Journal Vet Research*, 1972a. 33:903-909.

Canine Vasectomy

by
Sally McCreery*

Many people are starting to consider vasectomy as a substitution for castration in the canine species. Vasectomy is indicated in cases where owners do not want to breed the dog due to hereditary problems such as hip dysplasia. Vasectomy does not alter the male hormones as does castration. Young dogs still develop normal male characteristics and there is no problem of weight gain from decreased metabolic rate due to loss of testosterone. Intact male dogs have more drive to exercise and therefore keep in shape. Many owners also prefer not to castrate their dogs due to psychological identification problems.

A nine month old German Shorthair was admitted to Stange Memorial Clinic, Iowa State University August 30, 1976 to un-

*S. McCreery is a senior Veterinary Medicine student at Iowa State University.

dergo the vasectomy procedure. After inducing general anesthesia the area of the prepuce was surgically prepared. A 2 cm incision was made on the ventral midline of the prepuce just cranial to the scrotum. This incision was midway between and parallel to both spermatic cords permitting blunt dissection of these structures. The spermatic cords and their respective blood supply were drawn into the incision site one at a time. The ductus deferens, a white cordlike structure 3 mm in diameter, was identified. The tunica vaginalis parietalis was incised and the ductus deferens with its separate fold of tunica vaginalis was exposed. Two crushing forceps were placed on the ductus, 1 cm apart. The portion in between the forceps was excised and the severed ends were ligated with 2-0 chromic gut. The incision in the tunica vaginalis was carefully