

## Case reports

# Effects of COVID-19 on auditory and vestibular function in an adult patient: a longitudinal case study

Maria Cristina Alves Corazza<sup>1,2</sup> Patrícia Arruda de Souza Alcarás<sup>2</sup> Larissa Vianna<sup>2</sup> Luíza Alves Corazza<sup>3</sup> Adriana Bender Moreira de Lacerda<sup>2,4</sup> Bianca Simone Zeigelboim<sup>2</sup> 

<sup>1</sup> Universidade do Oeste Paulista, Faculdade de Medicina, Presidente Prudente, São Paulo, Brasil.

<sup>2</sup> Universidade Tuiuti do Paraná, Programa de Pós-Graduação "Mestrado e Doutorado" em Distúrbios da Comunicação, Curitiba, Paraná, Brasil.

<sup>3</sup> Hospital Santa Marcelina de Itaquera, Departamento de Neurologia, São Paulo, São Paulo, Brasil.

<sup>4</sup> Université de Montreal, École d'Orthophonie et d'Audiologie, UdeM, Montreal, Quebec, Canadá.

## ABSTRACT

COVID-19 is a viral infection that mainly affects the lower respiratory tract and with the affinity of the Spike protein to the Angiotensin 2 converter enzyme, inducing a prothrombotic state which may lead to compromising of the cardiovascular, central nervous, auditory, and vestibular systems. Viral infections knowingly affect vestibular and auditory systems. This study aimed to present the auditory and vestibular findings of a woman without otoneurological complaints, before the infection with SARS-CoV-2. This is a longitudinal case report, presenting the evolution of the otoneurological clinical picture accompanied by the results of a battery of tests. The results evidenced a unilateral, permanent, cochlear sensorineural hearing loss through altered otoacoustic emissions albeit with normal tonal thresholds, accompanied by peripheral vestibular hypofunction which worsened with time, without any other factor that could justify these findings. This study shows the importance of the complete protocol of tests performed over time for a better understanding of long-time implications of the SARS-CoV-2 infection.

**Keywords:** COVID-19; SARS-CoV-2; Hearing; Vertigo; Hearing Loss

A study conducted at the Universidade do Oeste Paulista, Presidente Prudente, São Paulo, Brazil.

**Financial support:** Nothing to declare.

**Conflict of interests:** Nonexistent.

### Corresponding author:

Maria Cristina Alves Corazza  
Rua Fagundes Varela, 426, Ap. 902, Vila Lessa  
CEP: 19020-620 - Presidente Prudente, São Paulo, Brasil  
E-mail: criscorazza40@gmail.com

**Received on:** July 12, 2023

**Accepted on:** October 10, 2023



This is an Open Access article distributed under the terms of the Creative Commons Attribution License, which permits unrestricted use, distribution, and reproduction in any medium, provided the original work is properly cited.

## INTRODUCTION

A world health emergency, COVID-19, a severe acute respiratory syndrome (SARS), caused by SARS-CoV-2 virus, rapidly reached pandemic proportions in the last three years, initially with high mortality rates, which was modified by vaccination.

It is a viral infection affecting mainly the lower airway, but also compromising other organs, such as liver and the gastrointestinal tract<sup>1</sup>. Due to the affinity of the Spike protein to the Angiotensin 2 Converter Enzyme (ACE2), there may be renal and nervous system compromising<sup>2</sup>.

Viral infections knowingly cause auditory and vestibular disturbances. The human inner ear has ACE2 receptors, which, together with the transmembrane protease serine 2 and FURIN, enable SARS-CoV-2 to enter the cell<sup>3</sup>. Through confocal microscopy, authors evidenced that Schwann and ciliary cells can be infected by the SARS-CoV-2<sup>3</sup>. The neurotropic effects of this virus have been discussed, considering its broad spectrum of neuropathic effects, including alterations in neural networks that comprise hearing and balance. Encephalitis, meningitis, demyelination, and Guillain-Barré Syndrome have also been described<sup>4</sup>.

A study remarks that the use of ototoxic drugs during care/internment of COVID-19 may cause vestibulocochlear impairment, leading to hearing and balance complaints<sup>5</sup>.

To better understand the effects of SARS-CoV-2 in hearing and equilibrium of infected people, this study aimed to report auditory and vestibular findings of a woman without hearing or balance complaints prior to the SARS-CoV-2 infection.

## CASE REPORT

This is a longitudinal case report with written consent, approved by the Ethics Research Board of the Universidade do Oeste Paulista, Brazil, by Plataforma Brazil, under CAAE 68179723.3.0000.5515 and protocol number 6.057.002, and in conformity with the Helsinki Declaration.

A 41-year-old woman, housewife, right-handed, with incomplete high school. She had no history of exposure to pesticides or noise, and no auditory or vestibular symptoms before COVID-19. She was diagnosed through nasal swab (RT-PCR) in May 2021, primarily reporting throat ache. Her symptoms worsened, and she was admitted to ICU, where she was treated for 24 days with anticoagulants, ceftriaxone, and dexamethasone, also requiring orotracheal intubation

for ventilatory support. She was discharged with the prescription of rivaroxaban, to prevent thromboembolic events.

After two months, she was referred by the Municipal Health Secretariate to a multidisciplinary program (comprising Medicine, Nursing, Physiotherapy, Speech Therapy, Nutrition, Biomedicine and Psychology) of a university of the outskirts of the São Paulo State. All patients from this program referring systemic signs and symptoms underwent this same protocol. Auditory and vestibular assessments were conducted at the Speech Therapy outpatient clinic from this institution.

Upon initial anamnesis, on July 23<sup>rd</sup>, 2021, main complaints were elbow joint pain and weakness of the right arm, which were slowly improving, as well as body ache, hair loss, after SARS-Cov-2 infection. She reported previous migraine, which did not worsen. She denied: tinnitus, hypoacusis, hearing fluctuations, aural plenitude, difficulty on understanding people on noise and silence, otalgia, as well as dizziness and or vertigo, pre and post COVID-19. She had no family history of hearing loss, lipidic alterations, hormonal disorders, neurologic conditions, thrombotic conditions, only reporting hypertension in a grandparent.

When analyzing her discharge papers, there was use of ceftriaxone and dexamethasone as antibiotics. She did not use hydroxychloroquine, ivermectin and azithromycin (this association was known in Brazil as the COVID kit, used by some individuals as a prevention method.)

After anamnesis, was proceeded with otoscopy, using Mikatos LED Mini 1000, which was normal; pure-tone (PTA), speech audiometry and high frequencies audiometry (HFA), using Interacoustics® model AC-40 audiometer; tympanometry and acoustic reflex testing, using Interacoustics® model AT-235; distortion-product (DPOAE) and transient-evoked otoacoustic emissions (TEOAE), using Otodynamics Ltda® model ILO 292-V6. During re-evaluations, four (November 2021) and 20 months (March 2023) later, tests were repeated and additionally, brainstem auditory evoked potential (BAEP) using Intelligent Hearing System®, model Smart EP, Masking Level Difference (MLD), using Interacoustics® model AC-40 audiometer and vectonystagmography (VENG), using Neurograff Electromedicine®, model VecWin Digital were conducted.

## RESULTS

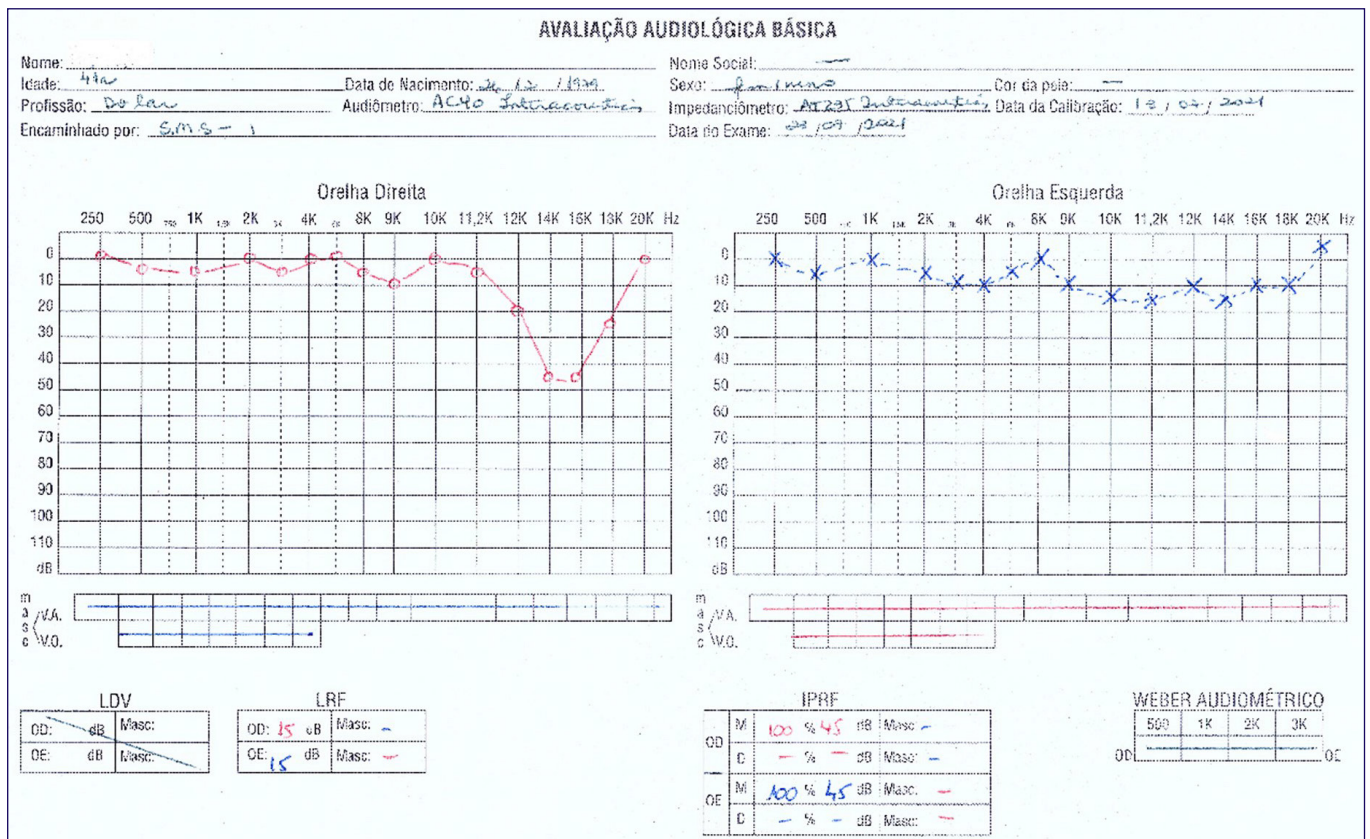
Results are shown in chronologic order, as seen in Table 1.

In the first evaluation, July 23<sup>rd</sup>, 2021, PTA, and HFA showed normal hearing thresholds in both ears, confirmed by speech audiometry (Figure 1).

**Table 1.** Description of audiological findings in chronological order

Exams	Chronological order			
	July 23 <sup>rd</sup> 2021	November 5 <sup>th</sup> 2021	November 27 <sup>th</sup> 2021	March 14 <sup>th</sup> 2023
PTA	Normal bilaterally	RE = normal LE = altered	RE = normal LE = altered	RE = normal LE = altered
HFA	Normal bilaterally	RE = normal LE = altered	RE = normal LE = altered	RE = normal LE = altered
Speech Audiometry	Normal bilaterally	RE = normal LE = altered with rollover	RE = normal LE = altered without rollover	RE = normal LE = altered without rollover
Tympanometry	Normal bilaterally	Normal bilaterally	Normal bilaterally	Normal bilaterally
Acoustic reflex	Altered bilaterally	Altered bilaterally	Altered bilaterally	Altered bilaterally
TEOAE	RE = normal LE = altered	RE = normal LE = altered	RE = normal LE = altered	RE = normal LE = altered
DPOAE	RE = normal LE = altered	RE = normal LE = altered	RE = normal LE = altered	RE = normal LE = altered
BAEP	Not performed	RE = normal LE = altered	RE = normal LE = altered	RE = normal LE = altered
MLD	Not performed	Altered	Normal	Normal
VENG	Not performed	Altered	Altered	Altered

Captions: RE = right ear, LE = left ear, PTA = pure tone audiometry, HFA = high frequencies audiometry, TEOAE = transient evoked otoacoustic emissions, DPOAE = distortion product evoked otoacoustic emissions, BAEP = brainstem evoked auditory potential, MLD = Masking Level Difference, VENG = vectoelectronystagmography.



Captions: OD = right ear; OE = left ear; Hz = hertz; k = kilo, M = monosyllabic, D = dissyllabic, LDV = voice detection threshold, LRF = speech reception threshold, IPRF = percentual speech recognition index, VA = air pathway, VO = bone pathway.

**Figure 1.** Conventional hearing and high frequencies thresholds, July 23<sup>rd</sup>, 2021

Tympanometry and acoustic reflex testing inferred normal anatomy, with medium ear volume of 0,66ml and pressure peak of -43 daPa on the right ear and 0,53 ml and -39 daPa on the left ear. Acoustic reflex was absent contralaterally in 2 kHz and 4 kHz on the right ear and 1 kHz, 2 kHz, and 4 kHz on the left ear, while

ipsilateral reflexes were present in 1 kHz, bilaterally and only on the right ear, on 2 kHz.

Regarding otoacoustic emissions, results are described in Table 2. Both TEAOE and DPOAE were altered on the left ear, implying external ciliary cells damage.

**Table 2.** Transient evoked otoacoustic emission findings, July 23<sup>rd</sup>, 2021

FREQUENCY	RE TEAOE			LE TEAOE		
	Signal	Noise	SNR	Signal	Noise	SNR
1,0 kHz	0.0	-19.7	19.8	-0.4	-16.1	15.7
1,4 kHz	1.2	-19.0	20.2	-1.0	-17.8	16.8
2,0 kHz	2.3	-16.4	18.7	-13.2	-17.9	4.6
2,8 kHz	5.2	-15.8	21.0	-18.1	-15.5	-2.6
4,0 kHz	3.4	-13.7	17.2	-21.0	-12.4	-8.6
General response		9.8			2.5	

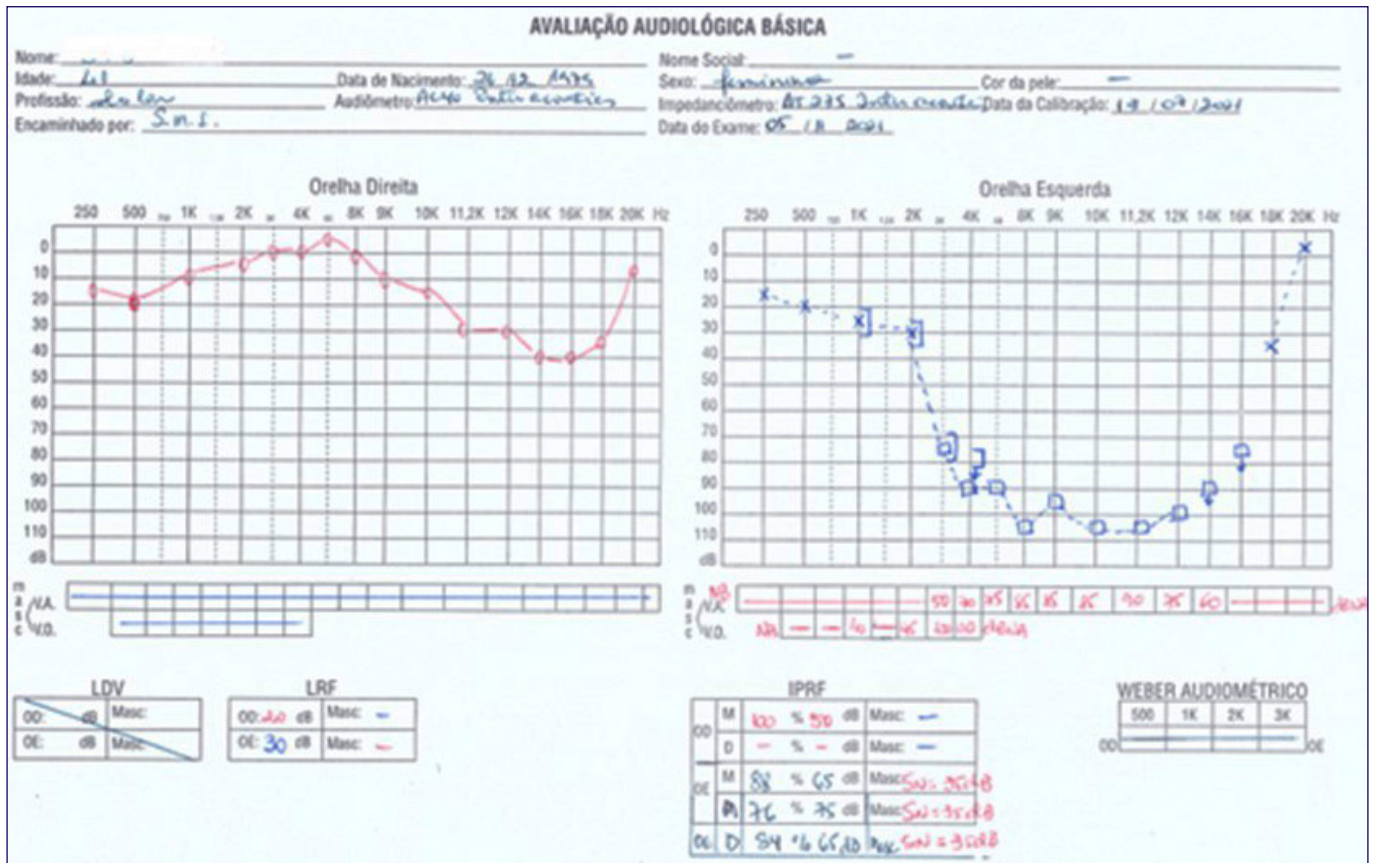
  

FREQUENCY	RE DPOAE OD			LE DPOAE		
	Signal	Noise	SNR	Signal	Noise	SNR
1,0 kHz	9.0	-3.9	12.9	-1.6	-9.3	7.7
1,4 kHz	5.2	-7.5	12.7	-6.4	-13.5	7.1
2,0 kHz	-1.9	-8.3	6.4	-30.0	-11.5	-18.5
2,8 kHz	-2.0	-10.2	8.2	-15.9	-14.6	-1.3
4,0 kHz	5.3	-9.6	14.9	-25.2	-12.2	-13.0
6,0 kHz	7.3	-8.7	16.0	-19.3	-10.6	-8.7

Captions: TEAOE = transient evoked otoacoustic emissions; DPOAE = distortion product evoked otoacoustic emissions; RE = right ear; LE = left ear; SNR = signal noise ratio; Hz hertz; k = kilo.

Four months after, on November 5<sup>th</sup>, 2021, she was reevaluated. The patient denied vestibulocochlear complaints or any health problems. She had no fever, indisposition, breathing or heart alterations or gastrointestinal symptoms. She underwent PTA, HFA, tympanometry, acoustic reflex testing, TEOAE, DPOAE, as well as BAEP, VENG and MLD.

Upon pure tone audiometry, right ear was normal and left ear presented with a moderate neurosensorial hearing loss, with a sloping configuration on conventional frequencies and worsening on high frequencies, with absence in 14 kHz and 16 kHz (Figure 2). On speech audiometry, there was *Rollover* on the left ear, suggesting a retro cochlear origin, despite no hearing difficulties and normal auditory perception in both ears.



Captions: OD = right ear; OE = left ear; Hz = hertz; k = kilo, M = monosyllabic, D = dissyllabic, LDV = voice detection threshold, LRF = speech reception threshold, IPRF = percentual speech recognition index, VA = air pathway, VO = bone pathway.

**Figure 2.** Conventional hearing and high frequencies thresholds, November 5<sup>th</sup>, 2021

Tympanometry, acoustic reflex testing, TEOAEs and DPOAEs showed similar results to previous testing.

BAEP, conducted with click stimuli on 80 dBNHL on the right ear and on 80, 90 and 99 dBNHL on the left ear showed I, III and V waves present on right ear and, on left ear, absence of all waves on 80 dBNHL, presence of waves III and V on 90 dBNHL and presence of waves I, III e V in 99 dBNHL (Table 3).

The waves alteration on the left ear corroborated pure tone audiometry findings, once she displayed hearing loss on high frequencies, without threshold to produce the potentials. Even though this register could happen due to a cochlear lesion, it would be unwise to immediately discard a retro cochlear insult.

**Table 3.** Brainstem auditory evoked potential findings, November 5<sup>th</sup>, 2021.

Ear	Intensity	Latency			Interpeak latency		
		I	III	V	I-III	III-V	I-V
RE	80 dB (ms)	1.5	3.65	5.65	2.15	2.00	4.15
	80 dB (ms)	--	--	--	--	--	--
LE	90 dB (ms)	--	4.30	5.65	--	1.35	--
	99 dB (ms)	1.65	4.40	5.83	2.75	1.42	4.18

Captions: RE = right ear; LE = left ear; ms = millisecond; dB = decibel

To verify binaural interaction and evaluate lower brainstem, MLD was performed. A threshold of 7 dB was found, when normality would be equal or higher than 10 dB.

To evaluate the vestibular pathways, VENG followed,

disclosing caloric test abnormalities with right side hyperreflexia, as well as a type III register on pendular tracking, found in central or peripheral vestibular affections. There were no pathognomonic signs of central disease. (Table 4).

**Table 4.** Vectoelectronystagmography findings, November 5<sup>th</sup>, 2021.

Test	Result	Pattern
Calibration	Regular	Regular
Spontaneous – open eyes	Absent	Absent
Spontaneous – closed eyes	Absent	Absent
Semi- Spontaneous		
Right	Absent	Absent
Left	Absent	Absent
Up	Absent	Absent
Down	Absent	Absent
Saccadic Movements	Regular	Regular
Pendular Tracking	Type III in 80 Hz	Type I/Type II
Gain	0.45	0.80 to 1.30
Optokinetic	Symmetric	Symmetric
Per Rotatory: Lateral and Vertical	Symmetric	Symmetric
Post Caloric (Air)		
50°C	RE: 17.7°/s LE: 10.5°/s	5 to 62°/s
24°C	RE: 46.3°/s LE: 26.6°/s	5 to 62°/s
Absolute Values	RE: 64.0°/s LE: 37.1°/s	5 to 62°/s
Relative:	LP 26.6%	19 to 100%
O.F.S.	Present	Present

Captions: O.F.S. = Ocular Fixation Suppression. LP = Labyrinthine Predominance.  
Note: Reference values from VecWin Digital – Neurograft Electromedicine program.

Subsequent evaluation on November 27<sup>th</sup>, 2021, had analogous results concerning PTA, HFA, tympanometry, TEOAEs and DPOAEs. On speech audiometry, there was a change on speech percentual recognition index and *Rollover* was no longer present. Findings were compatible with cochlear alteration and there was improvement of MLD, as of then, of 14dB.

On VENG, pendular tracking improved, becoming normal (type I), but caloric testing showed unilateral left hyporeflexia. Anamnesis disclosed tinnitus on left ear and considering findings, she was referred to evaluation for central causes. Brain and Mastoid MRI were normal.

Upon last evaluation, on March 14<sup>th</sup>, 2023, patient did not refer difference on auditory perception between ears, and PTA, HFA, tympanometry, TEOAEs and DPOAEs and MLD remained unchanged. Final audiological diagnosis was cochlear left sensorineural hearing loss. VENG showed reduced left labyrinthic responses and compensatory increased caloric responses on the right side, hence why the patient was not clinically symptomatic.

Anamnesis showed clinical improvement, no longer reporting tinnitus or joint pain, remaining right side arm weakness. She denied use of any continuous medications on the last year.

She was prescribed use of hearing aids and vestibular rehabilitation.

## DISCUSSION

Studies have shown auditory and vestibular alterations in patients after contact with SARS-CoV-2<sup>6,9</sup> with various otoneurological signs and symptoms, such as vertigo, tinnitus, and hearing loss<sup>5,10</sup>.

Inner ear disturbances after viral infections may happen due to reduction on oxygen blood levels, leading to vascular cochlear lesions<sup>11</sup>. Viruses' neurotropic effects may cause disruptions on neural pathways related to hearing and balance<sup>5</sup>.

In this case report, initially normal hearing thresholds were observed, with acoustic reflex and evoked otoacoustic emissions disturbances, followed by, in a posterior evaluation, a left sensorineural hearing loss, which could have been either cochlear or retro cochlear - given otoacoustic emissions, BAEP and MLD results, as well as *Rollover* - and a vestibular peripheral disorder, as shown by the VENG. On subsequent evaluation, findings pointed towards a cochlear disorder, no longer presenting *Rollover* and normalization of MLD, as well as normal anatomy, seen through MRI.

Similar results were observed on two other case reports, in which unilateral irreversible sensorineural hearing loss was found, without structural findings on MRI<sup>6,7</sup>.

According to the literature, vestibulocochlear disturbances could be related to compromise of the cochlea or neuritis, due to viral affection of inner ear and/or VII cranial nerve<sup>7</sup>. Other authors believe in a vascular insult to the cochlea or vestibular system, related to coagulation abnormalities, leading to microvascular ischemia<sup>12</sup>.

The patient referred coagulation abnormalities, having used anticoagulants during hospital internment and after discharge (Xarelto<sup>®</sup>), for about three months. Vascular disturbances and SARS-CoV-2 neurotropic effects may be hypothesized as causes of the cochlear lesion and origin of the transitory alteration of the auditory pathway<sup>5,11</sup>.

Audiometry alone is insufficient to investigate auditory function in these cases, once the initial examination found normal hearing thresholds in both ears, despite altered otoacoustic evoked emissions, pointing to external ciliary cells damage, hence why follow up was performed.

Despite no complaint of auditory perception difference in any of the ears, and the appearance of tinnitus, left sensorineural hearing loss was evidenced on following exams. Authors have described many mechanisms could be associated to unilateral hearing loss in COVID-19, such as: viral infection of VIII cranial nerve, cochlear inflammation, and stress induced response due to crossed reaction to inner ear antigens<sup>13</sup>.

A study conducted to measure relationship between COVID-19 severity and cochlear damage<sup>14</sup> using PTA and TEOAEs, as well as determine the starting point to the disease related hearing loss, its duration and possible recovering, showed that findings were mostly transitory, with recuperation of thresholds. The reported patient, differently from their population<sup>14</sup>, presented with permanent and irreversible loss.

Watchful follow up enabled the disclosure of neuropathic transitoriness of the process, considering the evolution of acoustic reflex, MLD and BAEPs, as well as the permanent installation of a cochlear permanent hearing loss, without other factors that could justify their occurrence.

Regarding the posterior labyrinth, first examination was done after the hearing loss diagnosis, so there are no records simultaneous to normal hearing;

hypofunction was evidenced accompanying left side audiometric findings. Initially, the right labyrinth had increased activity, characterizing labyrinthine compensation. Literature describes the fast capacity of the posterior labyrinth to adjust itself for compensation<sup>15</sup>, hence the absence of vestibular nature complaints.

The type III pendular tracking result obtained on second evaluation corroborates to the hypothesis of an auditory pathway compromise, which can be present in either peripheral or central affections, yet, more commonly in central<sup>16</sup>. This pattern was transitory, returning to a type I result in subsequent exams. On every occasion, vestibular complaints such as dizziness, vertigo or imbalance were absent, and there was always a reduced left side labyrinth function upon caloric testing, confirming the vestibulo-cochlear compromise. Some papers have described SARS-CoV-2 related vestibular neuritis<sup>17,18</sup>.

Considering the reported findings, otoneurological follow up in patients after COVID-19 is justified, to better comprehend and appreciate outcomes of the generalized inflammatory response and viral neurotropic effects. Its absence may incur in a wrong localization of the lesion, considering that hearing thresholds may be normal.

This case enabled follow up of the pathological process and to verify the transitoriness of auditory and vestibular pathways signs and symptoms, probably related to a neuritis<sup>17,18</sup> as well as to describe permanent cochlear sequelae, unilateral and peripheral.

The extended protocol, comprising both auditory and vestibular evaluations allowed appreciation of a post COVID-19 disorder, going from transitory retro-cochlear to cochlear permanent hearing loss.

## FINAL CONSIDERATIONS

This study presented the follow up of a clinically asymptomatic post COVID-19 patient, enabling the visualization of an inner ear lesional process through, initially, otoacoustic evoked emissions prior to audiometry alterations. Through an expanded protocol, both permanent worsening of hearing thresholds and vestibular alterations, without other factors that could justify these findings, were observed.

Thus, in infectious diseases, especially viral ones, a longitudinal evaluation with a complete protocol may aid in the comprehension of their long-term implications.

## REFERENCES

1. Campos MR, Schramm JM, Emmerick ICCM, Rodrigues JM, Avelar FG, Pimentel TG. Burden of disease from COVID-19 and its acute and chronic complications: reflections on measurement (DALYs) and prospects for the Brazilian Unified National Health System. *Cad. Saúde Pública.* 2020;36(11):e00148920. <https://doi.org/10.1590/0102-311X00148920> PMID:33146278.
2. Zhang S, Liu Y, Wang X, Yang L, Li Haishan, Wang Y et al. SARS-CoV-2 binds platelet ACE2 to enhance thrombosis in COVID-19. *J Hematol Oncol.* 2020;13(1):120. <https://doi.org/10.1186/s13045-020-00954-7> PMID:32887634.
3. Jeong M, Ocwieja KE, Han D, Wackym PA, Zhang Y, Brown A et al. Direct SARS-Cov-2 infection of the human inner ear may underlie COVID-19 associated audiovestibular dysfunction. *Commun Medicine.* 2021;1:44. <https://doi.org/10.1038/s43856-021-00044-w> PMID: 34870285.
4. Mao L, Jin H, Wang M, Hu W, Chen S, He Q et al. Neurologic manifestations of hospitalized patients with coronavirus disease 2019 in Wuhan, China. *JAMA Neurol.* 2020;77(6):683-90. <https://doi.org/10.1001/jamaneurol.2020.1127> PMID:32275288.
5. Karimi-Galougahi M, Naeini AS, Raad N, Mikaniki N, Ghorbani J. Vertigo and hearing loss during the COVID-19 pandemic - is there an association? *Acta Otorhinolaryngol Ital.* 2020;40(6):463-5. <https://doi.org/10.14639/0392-100X-N0820> PMID:32519994.
6. Koumpa FS, Forde CT, Manjaly JG. Sudden irreversible hearing loss post COVID-19. *BMJ Case Rep.* 2020;13:e238419. <https://doi.org/10.1136/bcr-2020-238419> PMID:33051251.
7. Lang B, Hintze J, Conlon B. Coronavirus disease 2019 and sudden sensorineural hearing loss. *J Laryngol Otol.* 2020;1:1-3. <https://doi.org/10.1017/S0022215120002145> PMID:33000716.
8. Swain SK, Pani SR. Incidence of hearing loss in COVID-19 patients: a COVID hospital-based study in the eastern part of India. *Int J Cur Res Rev.* 2021;13(3):103-7. <https://doi.org/10.31782/IJCRR.2021.13329>
9. Parrino D, Frosolini A, Toninato D, Matarazzo A, Marioni G, Filippis C. Sudden hearing loss and vestibular disorders during and before COVID-19 pandemic: an audiology tertiary referral centre experience. *Am J Otolaryngol.* 2022;43(1):103241. <https://doi.org/10.1016/j.amjoto.2021.103241> PMID:34555789.
10. Jafari Z, Kolb BE, Mohajerani MH. Hearing loss, tinnitus and dizziness in Covid-19: a systematic review and meta-analysis. *Can J Neurol Sci.* 2021;12:1-12. <https://doi.org/10.1017/cjn.2021.63> PMID:33843530
11. Chandrasekhar SS, Do BST, Schwartz SR, Bontempo LJ, Faucett EA, Finestone AS et al. Clinical practice guideline: sudden hearing loss (Update). *Otolaryngol Head Neck Surg.* 2019;161(1\_suppl):S1-S45. <https://doi.org/10.1177/0194599819859885>
12. Kwenandar F, Japar KV, Damay V, Hariyanto TI, Tanaka M, Lugito NPH et al. Coronavirus disease 2019 and cardiovascular system: a narrative review. *Int J Cardiol Heart Vasc.* 2020;3(29):100557. <https://doi.org/10.1016/j.ijcha.2020.100557> PMID:32550259.
13. Kilic O, Kalcioğlu M, Cag Y, Tuysuz O, Pektas E, Caskurlu H et al. Could sudden sensorineural hearing loss be the sole manifestation of COVID-19? An investigation into SARS-COV-2 in the etiology of sudden sensorineural hearing loss. *Int J Infect Dis.* 2020;97:208-11. <http://10.1016/j.ijid.2020.06.023> PMID: 32535294. PMID: 32535294. PMID: 32535294. PMID: 32535294.



14. Yildiz E. Comparison of pure tone audiometry thresholds and transient evoked otoacoustic emissions (TEOAE) of patients with and without Covid-19 pneumonia. *Am J Otolaryngol.* 2022;43(2):103377. <https://doi.org/10.1016/j.amjoto.2022.103377> PMID:35121526.
15. Bergquist F, Ludwig M, Dutia MB. Role of the commissural inhibitory system in vestibular compensation in the rat. *J Physiol.* 2008;586(Pt-18):4441-52. <https://doi.org/10.1113/jphysiol.2008.155291> PMID:18635647.
16. Rebelo SM, Castro HD, Ito YI, Caovilla HH, Ganança MM, Albernaz PL et al. Rastreo pendular em síndromes vestibulares periféricas e centrais à vecto-electronistagmografia. *Acta AWHO.* 1985;4(4):205-10.
17. Satar B. Criteria for establishing an association between Covid-19 and hearing loss. *Am J Otolaryngol.* 2020;41(6):102658. <https://doi.org/10.1016/j.amjoto.2020.102658> PMID:32836039.
18. Malayala SV, Raza A. A case of COVID-19-induced vestibular neuritis. *Cureus.* 2020;12(6):e8918. <https://doi.org/10.7759/cureus.8918> PMID:32760619.

**Author Contributions:**

MCAC, PASA: conception, data collection, investigation, data analysis, methods, research, Project administration, first draft, review, and writing;

LV: research, review, writing;

LAC: methods, research, writing review and English version;

ABML, BSZ: project administration, supervision, writing review.