

SYSTEMATIC REVIEW

Tuberculin Skin Test and Interferon- γ Release Assay for the Diagnosis of Tuberculous Spondylitis

Tsabita Hadid¹, Muhammad Faris^{2,3*}, Betty Agustina Tambunan⁴,
Caesaroy Afif Wibowo¹

¹Faculty of Medicine, Universitas Airlangga, Surabaya, Indonesia

²Department of Neurosurgery, Faculty of Medicine, Universitas Airlangga;
Dr. Soetomo General Academic Hospital, Surabaya, Indonesia

³Department of Neurosurgery, RS Adi Husada Undaan Wetan Surabaya

⁴Department of Clinical Pathology, Faculty of Medicine, Universitas Airlangga;
Dr. Soetomo General Academic Hospital, Surabaya, Indonesia

Article Info

Article history:

Received 20-12-2022

Revised 08-03-2023

Accepted 11-04-2023

Published 10-07-2023

Keywords:

Pott's disease

Spinal tuberculosis

Tuberculin skin test

Interferon- γ release

assay

Health risk

*Corresponding author:

Muhammad Faris

mfarisns@fk.unair.ac.id

ABSTRACT

Background: Tuberculous spondylitis or Pott's disease is extrapulmonary tuberculosis that is still a concern to health workers because of the broad spectrum of its clinical symptoms. Delay in diagnosis is very common in this disease. Therefore, its diagnostic tool needs to be thoroughly reviewed to determine its effectiveness. The diagnostic tools studied in this study were Tuberculin Skin Test (TST) and Interferon- γ Release Assay (IGRA). **Objective:** To analyze the role of TST and IGRA as diagnostic tools for the diagnosis of tuberculous spondylitis. **Material and Method:** This study used a systematic review method to analyze topic-related kinds of literature written in English and Indonesian found on PubMed, Scopus, ProQuest, and Web of Science databases. The literature screening process was carried out based on the PRISMA 2020 Guidelines. **Result:** Sixteen types of literature were included for a total of 116 patients. TST was detected positive in 45 (63%) and negative in 21 (30%) of a total of 66 patients with Pott's disease. IGRA was detected positive in 51 (77%), negative in 8 (12%), and indeterminate in 2 (3%) of a total of 61 patients with Pott's disease. **Conclusion:** TST and IGRA results significantly correlate with the diagnosis of tuberculous spondylitis. Both tests are still relevant for use in the diagnosis of the disease. IGRA and TST are used according to the needs of health workers and patients' health backgrounds.

How to cite:

Hadid, T., Faris, M., Tambunan, B.. 2023. Tuberculin Skin Test and Interferon- γ Release Assay on the Diagnosis of Tuberculous Spondylitis. *Majalah Biomorfologi*, 33(2):92-99

Majalah Biomorfologi (Biomorphology Journal) p.ISSN:0215-8833, e.ISSN: 2716-0920

doi: [10.20473/mbiom.v33i2.2023.92-99](https://doi.org/10.20473/mbiom.v33i2.2023.92-99)



Copyright: © 2023 by the authors. Open access publication under the terms and condition of the Creative Commons Attribution 4.0 International license (CC.BY 4.0).

Highlights

1. TST and IGRA have a significant correlation with the diagnosis of patients with Tuberculous Spondylitis.
2. Various factors may affect the results of TST and IGRA. Thus, the use of TST and IGRA can be adjusted according to the condition of the hospital, the availability of diagnostic tools, the health worker's physical examination results, and the patient's medical history.

BACKGROUND

Tuberculosis is still a concern in the health sector because of its high prevalence and mortality. With a total of 1,400,000 deaths in 2019, tuberculosis is one of the top 10 causes of death and the leading cause of death from a single infectious agent on a global scale. A total of 95% of cases and deaths from TB come from developing countries. Indonesia is one of eight developing countries that account for 2/3 of all new TB cases in the world ([World Health Organization, 2023](#)).

Spondylitis TB is a form of extrapulmonary TB infection that affects the patient's spine, which accounts for 50% of cases of osteoarticular TB ([Rajasekaran, et al., 2018](#)). This disease is quite dangerous because it can cause damage to the vertebrae, spinal deformities and/or paraplegia, and pulmonary insufficiency due to thoracic deformities ([Moon, 2014](#)). Until now, the diagnosis of spondylitis TB has been a challenge for health workers because of the wide and non-specific spectrum of clinical manifestations. This can cause a delay in diagnosis, resulting in a significant increase in the risk of morbidity and mortality due to disease progression and subsequent complications ([Kusmiati & Narendrani, 2019](#)). Early diagnosis and treatment are essential to avoiding this long-term disability ([Chen, et al., 2016](#)).

The gold standard for diagnosing tuberculous spondylitis is Magnetic Resonance Imaging (MRI). MRI is the most suitable radiological imaging for spondylitis TB because its contrast to soft tissue is more sensitive compared to other imaging modalities ([Ansari, et al., 2013](#)). However, MRI is a tool that is relatively expensive and only available in several qualified health facilities. This can be damaging to patients with early symptoms of spondylitis TB disease who happen to be in a location where MRI is not available at nearby health facilities. In addition to these reasons, Pott's disease cannot rely solely on diagnostic modalities. The diagnosis of spondylitis TB usually relies on a combination of clinical, radiological, bacteriological, pathological, and molecular tests. Spondylitis TB will be difficult to differentiate from osteomyelitis as well as spinal tumors, both primary and metastatic, if we rely only on clinical findings and radiographic results ([Priyambodo & Pratama, 2020](#); [Rasouli, et al., 2012](#)).

Radiological imaging, such as MRI is needed to measure the severity of the disease, but laboratory diagnostic tools such as TST, PCR, IGRA, pus culture, and others are required to confirm the diagnosis ([Merino, et al., 2012](#)). A pus culture can be used when a wound or abscess has formed and there is a sample of pus that can be tested for the presence of bacteria. This test required 3-6 weeks for the Mycobacterium bacteria to grow and be examined ([Batirel, et al., 2015](#)). Meanwhile, TST and IGRA are diagnostic tools that rely on the body's hypersensitivity reaction of the individual undergoing those tests, so they are not invasive and can be considered to use, even though the patient has only shown initial symptoms. These tests only need less than a week for the results to obtain. This is quite an important point for the goal in the early diagnosis of a disease.

The role of the TST and IGRA in the diagnosis of spondylitis TB is to detect the presence or absence of *Mycobacterium tuberculosis* bacteria in the patient's blood ([Batirel, et al., 2015](#)). This can be very practical so that the health worker involved can eliminate the differential diagnosis of spondylitis TB which varies if it is only seen through radiographic examination and the patient's clinical manifestations ([Rasouli, et al., 2012](#)). Through this study, the authors aimed to assess the effectiveness of the TST and IGRA in the diagnosis of spondylitis TB using a systematic review method of published journals, and conclusions will be drawn at the end of the study.

OBJECTIVE

The objective of this study was to analyze the role of TST and IGRA as diagnostic tools for the diagnosis of tuberculous spondylitis.

MATERIAL AND METHOD

This study used a quality systematic review method conducted by two independent reviewers based on our inclusion and exclusion criteria and carried out according to the Preferred Reporting Items for Systematic Review and Meta-analysis (PRISMA) 2020. The sample in this study included all studies that have been published in the Medline database, [Google Scholar](#), [ProQuest](#), [Sage Journals](#),

EBSCOhost, and Web of Science that discuss the role of using both TST and IGRA in the diagnosis of Pott's disease.

Mendeley desktop version 1.19.8 and Rayyan software is used to avoid article duplication and allow research studies to match the specified inclusion criteria. The quality of the literature will be assessed based on the Joanna-Briggs Institute critical appraisal tool. The results are summarized in a table and analyzed using IBM SPSS Statistics for Windows, version 25 (IBM Corp., Armonk, N.Y., USA) to discover the correlation between the two diagnosis tools and the results of the diagnosis of spondylitis TB using the Fisher's exact test formula. The comparison between TST and IGRA was qualitatively presented.

RESULT

Literature screening based on PRISMA 2020 guideline

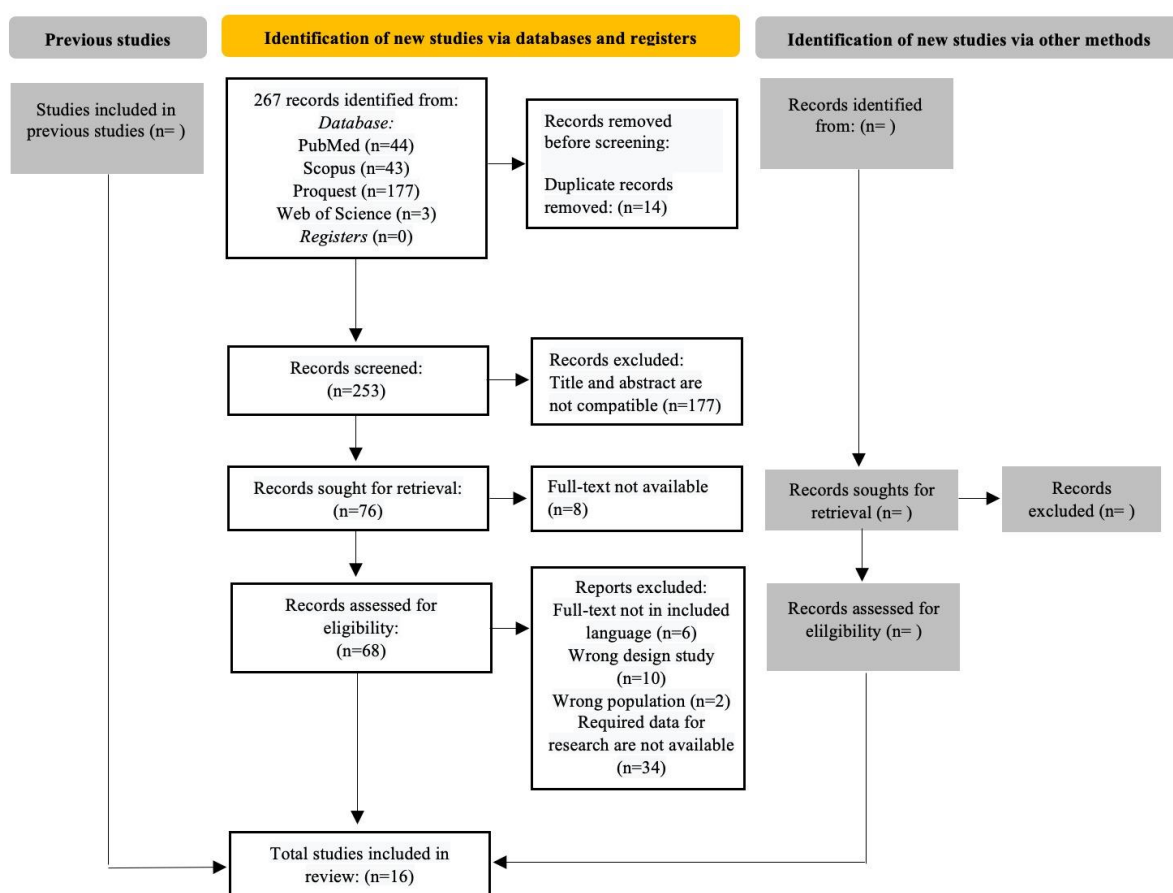


Figure 1. PRISMA 2020 flow diagram on literature screening.

Literature quality assessment

Assessments were carried out using the Joanna-Briggs Institute (JBI) critical appraisal tool for case reports, case series, and cohort retrospective and prospective studies. JBI provides a different checklist for each different type of study with "1" as "Yes", "0" as "No", and "U" as "Unclear". This assessment resulted in 10 case report articles with low risk, 2 case report articles with moderate risk, 1 case series article with moderate risk, and 3 cohort studies (prospective and retrospective) with low risk. Patients obtained from the total literature were 116, where all patients were individuals diagnosed with or resembling Potts disease through MRI imaging results and had data on diagnostic test results using TST

and IGRA.

Prevalence and Fisher’s exact test of TST in tuberculous spondylitis diagnosis

Table 1. Distribution of TST results on patients with TB spondylitis and bacterial spondylodiscitis.

	TST+	TST-	Total
Pott’s Disease	45	21	66
Bacterial spondylodiscitis	1	4	5
Total	46	25	71

These data show that out of a total of 71 patients diagnosed with TB spondylitis, TST was positive in 45 patients (63%) and negative in 21 patients (30%). Positive TST results were also found in one patient (1%) and negative in four patients (6%) without TB spondylitis.

Table 2. Fisher’s exact test of TST results on tuberculous spondylitis diagnosis.

	Value	df	Exact Sig (2-Sided)
Pearson Chi-Square	4.730	1	.030
Fisher’s Exact Test			.049
N of Valid Cases	71		

Table 2 above displays that the p-value of the Fisher's Exact Test is 0.049 (p <0.05).

Prevalence and Fisher’s exact test of IGRA in tuberculous spondylitis diagnosis

Table 3. Distribution of IGRA results on patients with tuberculous spondylitis and bacterial spondylodiscitis.

	IGRA+	IGRA-	Unclear	Total
Pott’s Disease	51	8	2	61
Bacterial spondylodiscitis	1	4	-	5
Total	52	12	2	66

These data show that from a total of 66 patients from the included literature, IGRA was detected positive in 51 patients (77%), negative in eight patients (12%), and with indeterminate results in two patients (3%) in tuberculous spondylitis. Positive IGRA results were also found in one patient (2%) and negative in four patients (6%) without tuberculous spondylitis.

Table 4. Fisher’s exact test of IGRA results on tuberculous spondylitis diagnosis

	Value	df	Exact Sig (2-Sided)
Pearson Chi-Square	13.907	2	.008
Fisher’s Exact Test	10.402		.010
N of Valid Cases	66		

Table 4 shows that the p-value of the Fisher's Exact Test is 0.01 (p <0.05).

DISCUSSION

Correlation between the use of TST with the diagnosis of tuberculous spondylitis

The Tuberculin Skin Test (TST) is a diagnostic tool that aims to detect whether there are tuberculin bacteria in a person. The TST is a skin test to detect exposure to TB bacteria, and its mechanism detects

delayed hypersensitivity in patients. [Table 1](#) shows that TST has positive results for more than half of the total patients with tuberculous spondylitis, namely 45 patients (68%) of a total of 66 patients. TST results were positive in patients who were not diagnosed with tuberculous spondylitis, which was only one patient out of a total of five cases. He was a male patient with spondylodiscitis of the cervical spine.

The results of statistical tests in [Table 2](#) using the Fisher's exact test displayed a p-value of 0.049 ($p < 0.05$). This shows that the use of TST has a significant relationship with the diagnosis of tuberculous spondylitis patients. TST has a sensitivity of 40-50% and a specificity of 75% for spondylitis TB. The sensitivity of TST is not very high because false positive cases are often found, such as positive TST results in individuals infected with bacteria other than *M. tuberculosis* or individuals with a history of previous BCG administration ([Centers for Disease Control and Prevention \(CDC\), 2020](#)).

Correlation between the use of IGRA and the diagnosis of tuberculous spondylitis

IGRA is a serological diagnostic tool for tuberculous spondylitis. Based on the data obtained from the literature above, [Table 3](#) shows that IGRA has positive results for more than half of the total patients with tuberculous spondylitis: 51 patients (84%) of a total of 61 patients. IGRA results were positive in patients who were not diagnosed with tuberculous spondylitis in only one out of a total of five, namely cases of spondylitis of the cervical spine. Indeterminate IGRA results were found in two patients with tuberculous spondylitis. Both indeterminate results used QuantiFERON Gold In-Tube, and both were found in pediatric patients. A study conducted by [Tebruegge, et al. \(2014\)](#) stated that indeterminate results in QuantiFERON-TB Gold In-Tube (QFT-GIT) are indeed more common in pediatric and elderly patients (9.1% and 7.4%, respectively) compared to adult patients (2.6%, Fisher's exact test with p-value < 0.0001).

The results of statistical tests in [Table 4](#) using Fisher's exact test showed a p-value of 0.01 ($p < 0.05$). This shows that the use of IGRA has a significant correlation with the diagnosis of Tuberculous Spondylitis. This finding was supported by data from a cross-sectional study conducted by [Kumar, et al., \(2010\)](#), who stated that IGRA had high sensitivity and specificity for the diagnosis of Tuberculous Spondylitis of 84% and 95%, respectively.

The role of using TST and IGRA for the diagnosis of tuberculous spondylitis

The diagnosis of TB spondylitis is quite challenging to confirm when using only one modality. Ten radiological modalities and clinical symptoms alone are not sufficient to differentiate it from vertebral osteomyelitis caused by other bacteria and fungi ([Dean, et al., 2019](#)). Therefore, various other diagnostic tools need to be performed on patients with suspected TB spondylitis to confirm the etiology. TST and IGRA are diagnostic tools used to confirm tuberculosis infection. The authors compared the results of the TST and IGRA in the same population and study.

In the comparison performed by the authors, IGRA has a higher sensitivity for diagnosing TB spondylitis compared to TST. IGRA can differentiate spondylitis caused by *M. tuberculosis* and *M. bovis*. A case example was recorded in case study research by [Minakata, et al., \(2020\)](#) of a 73-year-old male patient with positive TST test results and negative QuantiFERON tests. The patient had clinical symptoms and radiological features resembling TB spondylitis. A positive TST test further strengthened this suspicion, but other laboratory results confirmed that the patient had spondylitis caused by *M. bovis* as a result of BCG therapy. In this case, QFT can help eliminate the differential diagnosis of TB spondylitis caused by BCG. The specific antigen contained in the QFT test reacts with the antibody complex present in non-BCG tuberculosis bacteria but not in *M. bovis* BCG.

The second case example of positive TST and negative IGRA was a child patient in a study conducted by [Kumar, et al., \(2013\)](#), the patient was a Brazilian citizen with a diagnosis of osteoarticular tuberculosis and was HIV-positive. The patient's MRI image showed lesions at T11 and T12. A positive result on the TST test with an induration of 20 mm was obtained in this patient. However, the IGRA QFT Gold In-Tube Assay result for the patient was negative. Apart from TST and IGRA, positive results were obtained from a single-tube, nested, PCR (STN-PCR) for *M. tuberculosis* in blood and urine samples, and negative results were obtained from Lowenstein-Jensen culture.

The patient above was unique because the data listed in the study were contradictory to prior studies. In previous patients with spondylodiscitis due to BCG therapy, it was found that IGRA was considered more specific in differentiating *M. tuberculosis* infection from other Mycobacteriae group bacteria compared to TST. The first possibility is that this patient was also exposed to a Mycobacteriae family

group other than *M. tuberculosis*. However, this hypothesis was ruled out because of positive STN-PCR results for *M. tuberculosis*. Based on a meta-analysis study conducted by [Ma, et al., \(2021\)](#), IGRA is more sensitive in detecting TB in HIV-positive patients compared to TST, which can cause false-negative results. However, in this patient, the TST result was positive and the IGRA result was negative. From this case, we can conclude that both TST and IGRA are not always accurate in confirming a diagnosis. The results of each diagnostic tool depend on the patient's condition, patient's medical history and treatment, as well as the patient's reaction to the tests performed. Confirmation of the diagnosis in this patient was determined by considering the positive results of TST and STN-PCR as well as the patient's MRI image.

One case from the included literature shows that a patient with a final diagnosis of TB spondylitis had negative TST and negative IGRA results. These data were found in a study presented by [Senanayake & Karunaratne \(2014\)](#), concerning a 10-year-old female child patient from Sri Lanka with spondylitis TB in the cervical vertebrae (C3). This patient underwent TST and IGRA (QuantiFERON) tests, and both results came out negative. The patient never had a previous history of TB, and the patient's family TST test results were negative for exposure to TB bacteria. No other tests, such as culture, smear, or tissue histology, were performed to confirm the diagnosis in this patient. The definitive diagnosis of spondylitis TB was confirmed because, three months after starting treatment, the patient's MRI image showed linear calcification of the cervical spine. This shows that IGRA and TST can show false-negative results in patients, even if the patient is exposed to TB bacteria. This possibility often occurs in individuals with active TB, such as the patient in this case, because TST and IGRA have the main mechanisms for detecting whether TB bacteria have ever been in an individual ([Colmenero, et al., 2013](#)).

Based on the analysis of several cases where the two tests, TST and IGRA, were compared, it can be concluded that both TST and IGRA can have false positive or false negative results depending on the patient's background and the human error of the health workers on duty. TST and IGRA also have weaknesses in differentiating TB infection in patients with active or latent TB infection because both test mechanisms only detect an immune response to TB bacteria ([Goletti, et al., 2022](#)). Therefore, TST and IGRA alone are not recommended to be used independently in determining the diagnosis of spondylitis TB, and other confirmatory diagnostic modalities must be performed, such as culture or PCR, which are more specific in detecting active TB. However, if the patient was escorted by anamnesis and clinical symptoms that led to high suspicion of spondylitis TB, TST, and IGRA with positive results alone are enough to refer to a higher health facility for further radiological examination and confirmation of the diagnosis.

Strength and limitations

This study compares both TST and IGRA for the diagnosis of tuberculous spondylitis in a systematic review, which is a fairly high level of evidence-based research. TST and IGRA are more accessible and less invasive than an MRI or biopsy. Through this study, it is hoped that researchers will understand the outcomes of using TST and IGRA in patients with tuberculous spondylitis, especially when the patient's symptoms are still quite common. This article is limited in determining the diagnostic value of TST and IGRA for the diagnosis of tuberculous spondylitis due to heterogeneous data from population type, study type, test details, and other related issues. The lack of homogeneous data makes this research unable to proceed to meta-analysis, and only a systematic review is sufficient.

CONCLUSION

TST and IGRA have a significant correlation with the diagnosis of a patient with Pott's disease. Qualitatively described and reviewed, the comparison between TST and IGRA is in its specificity; TST can give false positive results from patients with spondylodiscitis-induced BCG or patients with non-Mtb infections, while IGRA can eliminate those false positive results and specify it to Mtb-infections only. The use of TST and IGRA can be adjusted according to the condition of the hospital, the availability of diagnostic tools, the health worker's physical examination results, and the patient's medical history.

Acknowledgment

Special thanks to the supervisors who have given the authors guidance throughout the process of making this research.

Conflict of Interest

All authors have no conflict of interest.

Funding

This research received no grant from any public, commercial, or non-profit funding agency.

Author Contribution

TH contributes to conception and design, analysis and interpretation of the data, drafting of the article, critical revision of the article for important intellectual content, and final approval of the article. MF contributes to conception and design, critical revision of the article for important intellectual content and final approval of the article. BAT contributes to conception and design and final approval of the article.

REFERENCES

- Ansari, S., Amanullah, M.F., Rauniyar, R., Ahmad, K. 2013. Pott's spine: Diagnostic imaging modalities and technology advancements. *North American Journal of Medical Sciences*, 5(7): 404. doi: [10.4103/1947-2714.115775](https://doi.org/10.4103/1947-2714.115775).
- Batirel, A., Erdem, H., Sengoz, G., Pehlivanoglu, F., Ramosaco, E., et al. 2015. The course of spinal tuberculosis (Pott disease): results of the multinational, multicentre Backbone-2 study. *Clinical Microbiology and Infection*, 21(11): 1008.e9-1008.e18. doi: [10.1016/j.cmi.2015.07.013](https://doi.org/10.1016/j.cmi.2015.07.013).
- Centers for Disease Control and Prevention (CDC). 2020. Tuberculin skin testing fact sheet, CDC. Available at: <https://www.cdc.gov/tb/publications/factsheets/testing/skintesting.htm> (Accessed: 20 July 2022).
- Chen, C.H., Chen, Y.M., Lee, C.W., Chang, Y.J., Cheng, C.Y., et al. 2016. Early diagnosis of spinal tuberculosis. *Journal of the Formosan Medical Association*, 115(10): 825–836. doi: [10.1016/j.jfma.2016.07.001](https://doi.org/10.1016/j.jfma.2016.07.001).
- Colmenero, J.D., Mesa, J.D.R., Jimenez, R.S., Sobrino, B., Morata, P. 2013. Establishing the diagnosis of tuberculous vertebral osteomyelitis. *European Spine Journal*, 22(S4): 579–586. doi: [10.1007/s00586-012-2348-2](https://doi.org/10.1007/s00586-012-2348-2).
- Dean, A., Zyck, S., Toshkezi, G., Galgano, M., Marawar, S. 2019. Challenges in the diagnosis and management of spinal tuberculosis: Case series. *Cureus*. doi: [10.7759/cureus.3855](https://doi.org/10.7759/cureus.3855).
- Goletti, D., Delogu, G., Matteelli, A., Migliori, G.B. 2022. The role of IGRA in the diagnosis of tuberculosis infection, differentiating from active tuberculosis, and decision making for initiating treatment or preventive therapy of tuberculosis infection. *International Journal of Infectious Diseases*, 124: S12–S19. doi: [10.1016/j.ijid.2022.02.047](https://doi.org/10.1016/j.ijid.2022.02.047).
- IBM Corp. Released 2017. IBM SPSS Statistics for Windows, Version 25.0. Armonk, NY: IBM Corp
- Kumar, M., Kumar, R., Srivastava, A. K., Nag, V. L., Maurya, A. K., et al. 2013. Clinical utility of interferon- γ releases assays (IGRAS) in pott's disease. *International Journal of Bioassays*, 2(4): 655–660. Available at: <https://www.ijbio.com/articles/clinical-utility-of-interferon-releases-assay-igras-in-potts-disease.pdf>.
- Kumar, R., Das, R.K., Mahapatra, A. K. 2010. Role of interferon γ release assay in the diagnosis of Pott disease. *Journal of Neurosurgery: Spine*, 12(5): 462–466. doi: [10.3171/2009.10.SPINE093](https://doi.org/10.3171/2009.10.SPINE093).
- Kusmiati, T., Narendrani, H. P. 2019. POTT'S disease. *Jurnal Respirasi*, 2(3): 99. doi: [10.20473/jr.v2-I.3.2016.99-109](https://doi.org/10.20473/jr.v2-I.3.2016.99-109).
- Ma, Y., Xu, Y., Cao, X., Chen, X., Zhong, Y. 2021. Diagnostic value of interferon- γ release assay in HIV-infected individuals complicated with active tuberculosis: a systematic review and meta-analysis. *Epidemiology and Infection*, 149: e204. doi: [10.1017/S0950268821001953](https://doi.org/10.1017/S0950268821001953).
- Merino, P., Candel, F.J., Gestoso, I., Baos, E., Picazo, J. 2012. Microbiological diagnosis of spinal tuberculosis. *International Orthopaedics*, 36(2): 233–238. doi: [10.1007/s00264-011-1461-x](https://doi.org/10.1007/s00264-011-1461-x).
- Minakata, T., Nakano, Y., Tamura, S., Kazuki, Y., Hayakawa, K., et al. 2020. Tuberculous spondylitis caused by intravesical bacillus calmette-guerin therapy. *Internal Medicine*, 59(5): 733–737. doi: [10.1007/s00586-012-2348-2](https://doi.org/10.1007/s00586-012-2348-2).

[10.2169/internalmedicine.3288-19](https://doi.org/10.2169/internalmedicine.3288-19).

- Moon, M.-S. 2014. Tuberculosis of spine: Current views in diagnosis and management. *Asian Spine Journal*, 8(1): 97. doi: [10.4184/asj.2014.8.1.97](https://doi.org/10.4184/asj.2014.8.1.97).
- Prijambodo, B., Pratama, U. S. 2020. Clinical, laboratory and radiologic evaluations in patients with malignant tuberculous spondylitis. *Indian Journal of Forensic Medicine and Toxicology*, 14(4), 4476-4481. <https://doi.org/10.37506/ijfmt.v14i4.12346>.
- Rajasekaran, S., Soundararajan, D.C.R., Shetty, A.P., Kanna, R.M. 2018. Spinal tuberculosis: Current concepts. *Global Spine Journal*, 8(4_suppl): 96S-108S. doi: [10.1177/2192568218769053](https://doi.org/10.1177/2192568218769053).
- Rasouli, M.R., Mirkoohi, M., Vaccaro, A.R., Yarandi, K.K., Movaghar, V.R. 2012. Spinal tuberculosis: Diagnosis and management. *Asian Spine Journal*, 6(4): 294. doi: [10.4184/asj.2012.6.4.294](https://doi.org/10.4184/asj.2012.6.4.294).
- Senanayake, M. P., Karunaratne, I. 2014. A child presenting with tuberculous spondylitis in a single third cervical vertebra: a case report. *Journal of Medical Case Reports*, 8(1): 284. doi: [10.1186/1752-1947-8-284](https://doi.org/10.1186/1752-1947-8-284).
- Tebruegge, M., de Graaf, H., Sukhtankar, P., Elkington, P, Marshall, B., et al. 2014. Extremes of age are associated with indeterminate quantiFERON-TB gold assay results. *Journal of Clinical Microbiology*. Edited by G. A. Land, 52(7): 2694–2697. doi: [10.1128/JCM.00814-14](https://doi.org/10.1128/JCM.00814-14).
- World Health Organization. 2023. Tuberculosis, WHO. Available at: <https://www.who.int/news-room/fact-sheets/detail/tuberculosis>.