

Case report



AN UNCOMMON CASE OF FILUM TERMINALE HEMANGIOBLASTOMA NON-ASSOCIATED WITH VON HIPPEL – LINDAU DISEASE

Todor Shamov¹, Tihomir Eftimov¹, Georgi K. Georgiev¹, Rosen T. Rousseff²
1)Department of Neurosurgery, Military Medical Academy – Sofia, Bulgaria.
2)Department of Neurology, Faculty of Medicine, Medical University - Pleven, Bulgaria.

SUMMARY

A 55-year-old man presented with low backache, paraesthesia, and spasticity of both lower limbs. He had urinary retention and constipation.

Investigations revealed a vascular intradural cauda equina tumor. MRI scan demonstrated an enhancing mass at the third and fourth lumbar vertebral levels. There were multiple dilated and tortuous veins draining from both poles of the tumor.

At surgery, we found a well-defined tumor with an orange hue and fleshy consistency was encountered arising from the filum terminale, comprising a few adjacent nerve roots. The tumor was excised en bloc. The filum terminale was also been resected.

A sporadic hemangioblastoma arising from the filum terminale should be considered as a rare cause of back pain and sciatica. Total excision of the tumor offers a cure.

Keywords: Cauda equine, Filum terminale, hemangioblastoma, von Hippel–Lindau syndrome,

Spinal cord hemangioblastomas consist of around 8 % of all spinal cord tumors. They are the third most common spinal cord tumors after ependymomas and astrocytomas. [1]

Hemangioblastomas are predominantly solitary tumors. In about 30% of cases, spinal cord hemangioblastomas are associated with von Hippel – Lindau syndrome. These tumors are intramedullary, and usually, they are visible and protruding on the spinal cord surface, unlike astrocytomas and ependymomas, which are entirely intramedullary.

In rare cases, hemangioblastomas may tend to extramedullary expansion. In these cases, they originate from the DREZ zone of the spinal cord and are associated with the intramedullary part of the posterior nerve root. [2]

In extremely rare cases, hemangioblastomas of filum terminale and cauda equina could be observed without being associated with von Hippel – Lindau syndrome. [3]

In the currently available literature, we have found about 20 described cases of hemangioblastomas of the filum terminale and cauda equina. Among all these cases, only a few cases are identified as isolated hemangioblastomas of filum terminale. [4-12] In this report, we present a rare case of hemangioblastoma of filum terminale not associated with von Hippel – Lindau syndrome.

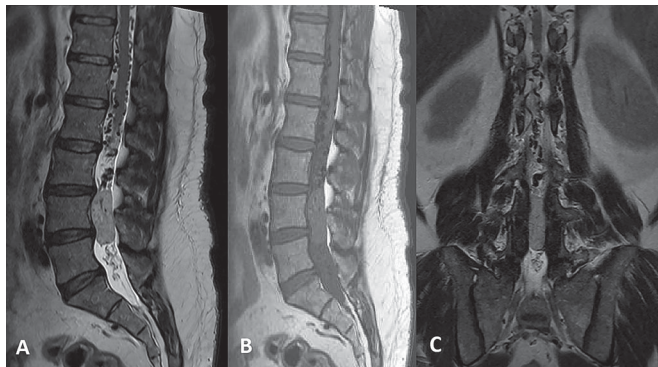
CASE PRESENTATION

A 55-year-old man presented to the neurosurgical department at Military Medical Academy – Sofia with the following complaints: Low back pain and bilateral radicular pain in the area of L3 and L4 dermatomes. The pain is accompanied by episodes of urinary retention, constipation, and erectile dysfunction. During the neurological examination, the patient had spastically increased muscle tone for the lower extremities against the background of absent knee and Achilles reflexes.

Magnetic resonance imaging of the lumbar spine showed an intradural cauda equina tumor located in the segment from the lower endplate of the L3 vertebral body to the upper endplate of the L5 vertebral body. The depicted tumor formation was isointense on the T1 echo and iso to hyperintense on the T2 echo. The tumor increased its signal intensity after contrast media application. Noteworthy

are the numerous folded and dilated vessels originating from the upper part of the tumor formation, tracing in the cranial aspect along the entire covered segment.

Fig. 1. A) T2 image in the sagittal plane illustrated the location of the tumor and the multiple flow void changes as a result of the developed vascular network cranial to the tumor. B) T1 image in sagittal plane. C) T2 image in the coronal plane showing the multiple vessels cranial to the tumor.

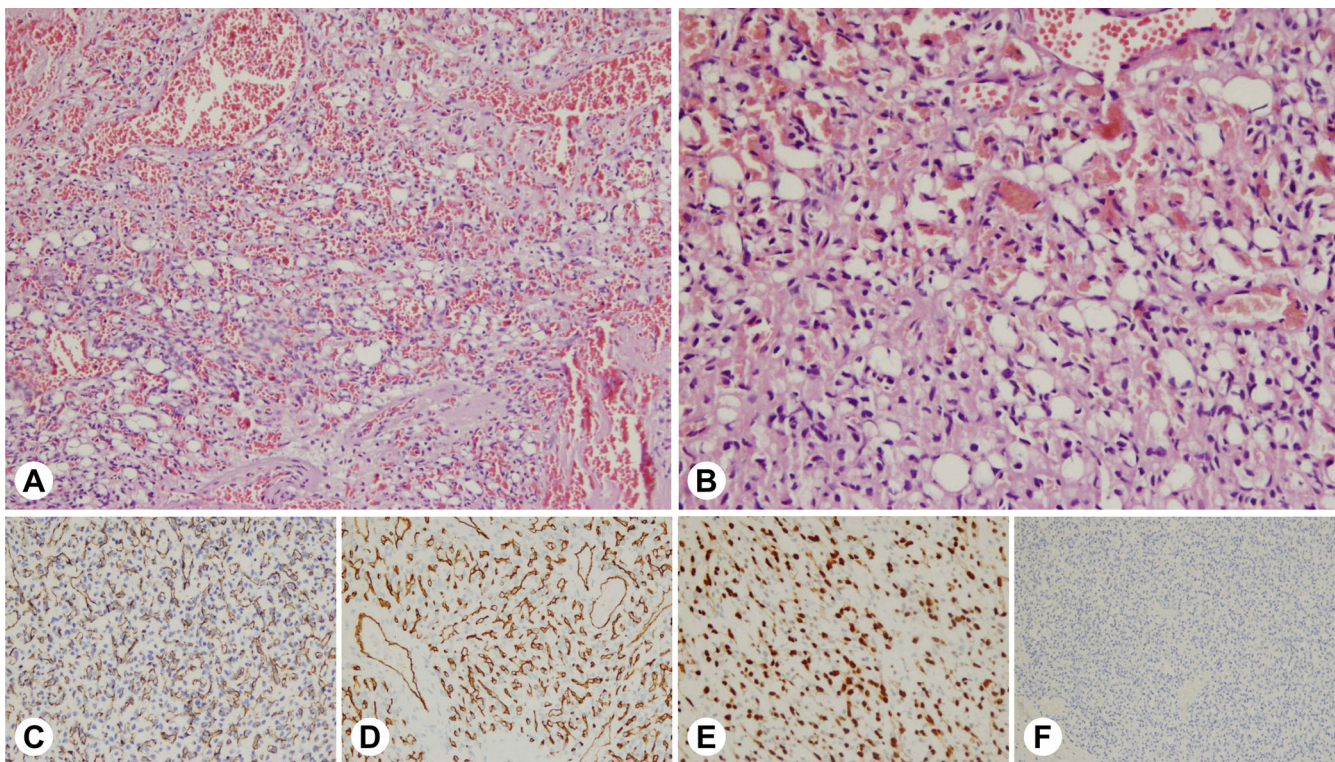


The patient was undergone on operation as laminectomy of L4 arch was performed. The segmental zygo-apophyseal joints were spared, and some bony structures in cranial and caudal plane were removed. The dura mater was found thinned and atrophic, and after its incision, we came

across a densely-elastic reddish tumor formation. There were dilated venous vessels in the dorsal aspect of the tumor. The nerve roots constituting cauda equina were dislocated at the periphery of the tumor. The tumor was fixed and originated from filum terminale, which was medially located and thickened in the cranial and caudal aspects. The attempt to take a biopsy was accompanied by profuse bleeding and difficult hemostasis, necessitating compression of biopsy places, the tumor surface coagulation, and microdissection of the nerve roots adherent to the tumor. To achieve en block resection, filum terminale was cut in the cranial and caudal poles of the tumor.

The pathohistological examination of the excised tumors showed fragments of benign tumor formation composed of fibrous septa and capillary type vessels upholstered by single endothelial cells with bland-type nuclear and cytoplasmic characteristics surrounded by a layer of smooth muscle cells. Among the capillary lumen, large vascular clefts are formed with flattened endothelium and thickened vascular wall, and all vessels were filled with erythrocytes. Large dilated and hyalinized vessels were visible along the periphery of the tumor formation. The endothelial cellular components of the tumor express the following immunohistochemical markers – CD31, CD34, and ERG, while the smooth cell components express S100 and S100 protein. The diagnosis of capillary hemangiomas was made based on the morphological and immunohistochemical characteristics of the tumor.

Fig 2. The histological and immunohistochemical samples of the tumor. A) Hematoxyline-eosine 10X; B) Hematoxyline-eosine 20X; C) CD31 20X; D) CD34 20X; E) ERG 20X; F) GFAP 10X.

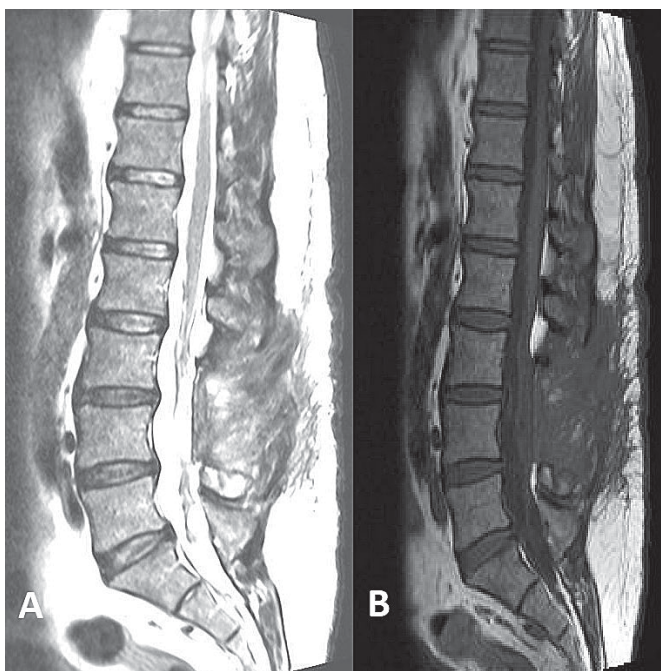


The patient was ambulated on the third postoperative day. Transient episodes of urinary retention were observed and had been treated by intermittent catheterization

and direct-action cholinomimetics. There weren't wound complications in the postoperative period. Abdominal ultrasonography and fundoscopy have been performed to ex-

clude the typical changes characterizing the von Hippel – Lindau disease. On the third month after the operation, the patient had neurologically free, and there weren't urinary retention or constipation. The control MRT showed total tumor excision and a lack of pathologically enlarged vessels.

Fig. 3. Control MRT has been performed at the third month after the operation. **A)** T1 echo; **B)** T2 echo. There wasn't data for contrast medium intake or pathologically dilated vessels.



DISCUSSION

The most common localization of spinal cord hemangioblastomas is in the cervical and thoracic segments of the spinal cord. About 20 percent of the spinal cord hemangioblastomas show a tendency to extramedullary growth. This is explained by the fact that the vascular endothelial growth factor is produced by stromal cells, and the same factor is associated with endothelial proliferation. [13]

In 1943, Wyburn and Mason described a case of a 25-year-old woman with radicular pain in the L2-S2 dermatomes area accompanied by low back pain. The surgical treatment performed at that time revealed a hemangioblastoma of the filum terminale. Later in 1965 year Sloof et al. reported a second case of hemangioma of

the filum terminale. In the CT era, Wolbers et al. described a case of hemangioblastoma in the L1 spinal segment involving the conus medularis and filum terminale. The first case of cauda equine hemangioblastoma diagnosed with MRI was described by Tibbs et al. [14]

At present, the diagnosis of these tumors is not problematic. It should be noted here that a characteristic feature of the T2 echo is the presence of a flow void phenomenon, which correlates with enlarged and hypertrophied drainage vessels. This can lead to increased pressure in the spinal cord venous system, and the clinical presentation could be similar to that of spinal cord arteriovenous fistulas. A similar syndrome was described by Foix and Alajouanine in 1926, in which they described inferior spastic paraparesis with erectile dysfunction; they then called this syndrome subacute necrotic myelopathy and, in autopsy material described dilated spinal cord vessels. [3] In the cases we described, we also observed lower extremity spasticity combined with erectile dysfunction.

Spinal angiography has been recommended by some authors because, in these cases, embolization of the feeding vessels of the tumor could be performed, resulting in less intraoperative bleeding and lower operative morbidity. [12]

Intraoperatively, a thickened and hypertrophic arachnoid membrane is usually encountered, and the tumor is covered by the tumor-thickened vessels and surrounding rootlets. According to some authors, the diagnosis of hemangioblastoma of the filum terminale is somewhat tentative as it is based on the surgeon's intraoperative judgment. In a not insignificant number of cases, there is also the involvement of the adjacent roots by the tumor, which may make dissection difficult. Tumor microdissection is initiated from the cranial or caudal pole of the tumor. An en-bloc resection of the tumor with interruption of the filum terminale is recommended. When adjacent roots are involved, their dissection proceeds and entry into the tumor parenchyma may be concomitant with profuse bleeding, which is a prerequisite for iatrogenic root damage and high postoperative morbidity. In these cases, total tumor excision may not be possible, and the patient may have to be referred for postoperative radiotherapy, which in the long term could lead to worsening neurological status.

In conclusion, it can be said that hemangioblastomas of the filum terminale are a rare cause of back pain accompanied by radicular symptomatology. Total surgical excision is possible in most cases and results in a definitive cure and complete recovery of patients.

REFERENCES:

1. Na JH, Kim HS, Eoh W, Kim JH, Kim JS, Kim E-S. Spinal cord hemangioblastoma / : diagnosis and clinical outcome after surgical treatment. *J Korean Neurosurg Soc.* 2007 Dec;42(6):436–40. [[PubMed](#)]
2. Escott EJ, Kleinschmidt-DeMasters BK, Brega K, Lillehei KO. Proximal nerve root spinal hemangioblastomas: presentation of three cases, MR appearance, and literature review. *Surg Neurol.* 2004 Mar;61(3):262-73; discussion 273. [[PubMed](#)]
3. Evzikov GY, Konovalov NA, Kushel YV, Timonin SY, Argylova VN. [Hemangioblastomas of the filum terminale and cauda equina]. [in Russian] *Zh Vopr Neurokhir Im N N Burdenko.* 2021; 85(2):60-66. [[PubMed](#)]
4. Ciappetta P, Occhiogrosso G, Domenicucci M, D'Andrea G, Bastianello S, Frati A. Hemangioblastoma of the filum terminale. Case report and review of the literature. *J Exp Clin Cancer Res.* 2007 Jun;26(2):281–5. [[PubMed](#)]
5. Fujii Y, Nishisho T, Tezuka F, Iwanami A, Yamashita K, Toki S, et al. Hemangioblastoma of the Cauda Equina : A Case Report and Review of the Literature. *J Med Invest.* 2022; 69(3.4):312-5. [[PubMed](#)]
6. D'Oria S, Giraldi D, Flores DAA, Murrone D, D'Angelo V, Chaurasia B. Sporadic hemangioblastoma of cauda equina: A case report and brief literature review. *J Craniovertebr Junction Spine.* 2022 Jul-Sep;13(3):265-70. [[Internet](#)]
7. Martins HO, Brock RS, Taricco MA, Pereira JF. Junior, de Oliveira MF. Sporadic hemangioblastoma of cauda equina: An atypical case report. *Surg Neurol Int.* 2019 Apr 24;10(60)1-4. [[Crossref](#)]
8. Tibbs RE Jr, Harkey HL, Raila FA. Hemangioblastoma of the filum terminale: case report. *Neurosurgery.* 1999 Jan;44(1):221-3. [[PubMed](#)]
9. Nadkarni TD, Menon RK, Desai KI, Goel A. Hemangioblastoma of the filum terminale. *J Clin Neurosci.* 2006 Feb;13(2):285-8. [[PubMed](#)]
10. da Costa LB Jr, de Andrade A, Braga BP, Ribeiro CA. Cauda equina hemangioblastoma: case report. *Arg Neuropsiquiatr.* 2003 Jun;61(2B):456-8. [[PubMed](#)]
11. Sergides IG, Wainwright KL, Biggs M. Incidental hemangioblastoma of the filum terminale. *Acta Neurol Belg.* 2009 Mar;109(1):55-6. [[PubMed](#)]
12. Biondi A, Ricciardi GK, Faillot T, Capelle L, Van Effenterre R, Chiras J. Hemangioblastomas of the lower spinal region: report of four cases with preoperative embolization and review of the literature. *AJNR Am J Neuro radiol.* 2005 Apr;26(4):936-45. [[PubMed](#)]
13. Chen X, Xu G, Bi Q, Huang Y, Shao H, Jin M, et al. Cauda Equina Syndrome as First Manifestation of von Hippel-Lindau Disease. *World Neurosurg.* 2019 May;125:316-9. [[PubMed](#)]
14. Blaty D, Malos M, Palmrose T, McGirr S. Sporadic Intradural Extramedullary Hemangioblastoma of the Cauda Equina: Case Report and Literature Review. *World Neurosurg.* 2018 Jan;109:436-41. [[PubMed](#)]

Please cite this article as: Shamov T, Eftimov T, Georgiev GK, Rousseff RT. An uncommon case of filum terminale hemangioblastoma non-associated with von Hippel – Lindau disease. *J of IMAB.* 2023 Oct-Dec;29(4):5236-5239. [[Crossref](#) - <https://doi.org/10.5272/jimab.2023294.5236>]

Received: 19/05/2023; Published online: 22/11/2023



Address for correspondence:

Assoc. prof. Todor Shamov MD, PhD
Military Medical Academy - Sofia
E-mail: shamov@abv.bg