



## Impact of Biphasic Calcium Phosphate mixed with injectable platelet rich fibrin (i-PRF) on bone density in surgically created bone defects in a sheep animal model (A Radiographic Assessment)

Junayna H. Ali <sup>1</sup> , Rayan S. Hamed <sup>2</sup> 

Department of Oral and Maxillofacial Surgery, College of Dentistry, University of Mosul, Iraq.

### Article information

Received: March 11, 2022

Accepted: May 9, 2022

Available online: September 1, 2023

### Keywords:

Injectable platelet rich fibrin,  
Biphasic calcium phosphate,  
Bone density.

### \*Correspondence e-mail:

Junayna.ali@uomosul.edu.iq

### Abstract

**Aims:** To assess bone density means with Biphasic calcium phosphate alone or mixed with injectable platelet rich fibrin in bone defects created surgically in sheep's tibia / radius using standard radiographic assessment. **Materials and Methods:** Three bony defects of 4mm full and 7 mm in diameter were created in every tibias/radius of five sheep. The defects were stuffed within the following order: from a proximal to distal orientation; 1st defect was full of biphasic calcium phosphate alone, second left empty to be filled by physiological clot and also the third with i-PRF mixed with BCP and covered with absorbable collagen membrane for tissue guiding and then sutured. Densitometric analysis of bone defects was made to measure density of bone at four-time intervals (two, four, six and eight weeks) post-surgically. **Results:** Densitometric analysis results showed a major distinction within the BCP+i-PRF group and BCP group compared with the control one and at all-time intervals with the best density being in the 1st group followed by the BCP alone group and least in the control group. **Conclusions:** BCP and i-PRF, both of them increased and sustained bone density (synergistic effect) throughout the study period and as revealed by densitometric data.

### الخلاصة

**الأهداف:** تهدف الدراسة الى تقييم كثافة العظام مع فوسفات الكالسيوم ثنائي الطور وحدها أو مختلطة مع الفيبرين الغني بالصفائح الدموية القابل للحقن في عيوب العظام التي تم إنشاؤها جراحياً في عظم الساق للأغنام باستخدام التقييم الشعاعي القياسي. **المواد وطرائق العمل:** تم إجراء ثلاثة عيوب قياسية في العظم بقطر 4ملم وعمق 7ملم. تم ملء العيوب بالترتيب التالي: العيب الأول ملى بفوسفات الكالسيوم ثنائي الطور وحده، والثاني ترك فارغاً ليتم ملؤه بخثرة دموية والثالث ملى بالفيبرين الغني بالصفائح الدموية القابل للحقن ممزوجاً بفوسفات الكالسيوم ثنائي الطور. تم استخدام التصوير الشعاعي الرقمي لغرض تقييم كثافة العظام خلال الفترات الزمنية ( اسبوعان , أربعة أسابيع , ستة أسابيع وثمانية أسابيع ). **النتائج:** أظهرت النتائج وجود فرق كبير ذو دلالة إحصائية وخلال الفترات الزمنية التي تم الدراسة عليها في مجموعة الفيبرين الغني بالصفائح الدموية القابل للحقن ممزوجاً بفوسفات الكالسيوم ثنائي الطور وفي مجموعة فوسفات الكالسيوم ثنائي الطور وحده عند مقارنتها مع المجموعة الضابطة ، وأيضاً عند المقارنة بين المجموعات تم الكشف عن اختلاف كبير ذو دلالة إحصائية ، مع أعلى متوسط هو ثمانية أسابيع بعد الجراحة لمجموعة الفيبرين الغني بالصفائح الدموية القابل للحقن ممزوجاً بفوسفات الكالسيوم ثنائي الطور. **الاستنتاجات:** قام كل من فوسفات الكالسيوم ثنائي الطور و الفيبرين الغني بالصفائح الدموية القابل للحقن بتحسين كثافة العظام والحفاظ عليها (تأثير تآزري) طوال فترة الدراسة وكما تم الكشف عنها خلال نتائج التصوير الشعاعي.

DOI: 10.33899/rdenj.2022.133155.1157 , © 2023, College of Dentistry, University of Mosul.

This is an open access article under the CC BY 4.0 license (<http://creativecommons.org/licenses/by/4.0/>)

## INTRODUCTION

In clinical and medical research, augmentation of bone deficiencies caused by trauma, tumors, infections, and surgical excision is still a major difficulty<sup>1</sup>. Various bone graft materials have been developed and are utilized in oral and maxillofacial procedures to restore bony deformities<sup>2</sup>. The similarity in physicochemical properties to human bone, BCP has been widely used. It is primarily made up of less soluble hydroxyapatite (HA) for space preservation and more sustainable  $\beta$ -TCP for resorption rate control. It's a low-cost biomaterial that's biocompatible and osteoconductive<sup>3</sup>. In the field of regenerative medicine, as surgical adjuncts or suspensions, platelet concentrates for topical application have originated. They are autologous blood extracts that are transferred to a diseased area to aid in recovery. In all surgical fields, improving healing is an ongoing concern<sup>4</sup>. Choukroun et al. in France created Platelet Rich Fibrin (PRF) in 2001, which is a platelet concentrate the second generation. PRF is a clear and straightforward, low-cost, and minimally intrusive approach producing a natural intensity of autologous growth factors in a that is commonly utilized to speed soft and hard tissue healing. As a result, PRF is used in a wide range of medicinal fields.<sup>5,6,7</sup> Modifying the spin centrifugation forces resulted within the development of associate degree injectable platelet-rich fibrin in 2014. when put next to the primary generation platelet-derived

PRP, centrifugation at low speeds is needed for the manufacture of the liquid kind of i-PRF (flowable PRF) furthermore because the introduction of a cloth rich in leukocytes, platelets, and growth factors corresponding to VEGF, TGF-1, and PDGF. The autografting product injectable platelet-rich fibrin has been applied to boost bone regeneration by emitting intrinsic growth factors<sup>8</sup>. Short and slow centrifugation rates result in a stronger presence of regeneration cells with higher concentrations of growth factors as compared to other PRF formulations that use faster centrifugation speeds<sup>9</sup>.

## MATERIALS AND METHODS

Approval of study was from the Scientific Research Committee / Department of Oral and Maxillofacial Surgery / College of Dentistry / Mosul University. Five healthy local breed male sheep (age 1.5 -2 years), weighing 40-45 kg (mean= 42.5kg) were used. Prior to any surgery, the animals were acclimated for two weeks and their general health was checked to assure the absence of any general or infectious disease. Each sheep model served as four observation subgroups; two, four, six and eight weeks with all five animals being operated on. Each sheep's tibias and radiuses were operated on at random intervals of two weeks between each surgery.

### **Preparation of i-Platelet Rich Fibrin:**

The site of blood collection in sheep was the jugular vein. From each sheep, two – 10

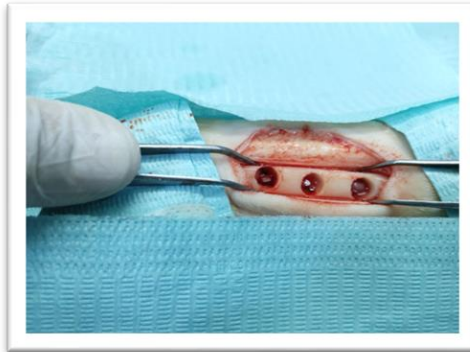
ml blood samples were drawn in plastic tubes without any coatings, and immediately centrifuged. According to the preparation protocol, the centrifuge cycle for the preparation of an injectable PRF is 700 rpm for 3 minutes. Retrieve the tube from the centrifuge and ensure that the blood has separated into 2 fractions. The lower layer fraction consists of red blood cells, and the upper layer consist of plasma, platelets, and coagulating factors still in the uncoagulated form. In liquid form, the separated plasma and platelets form a light-yellow tinted layer using a syringe aspirate the top layer with the head of the syringe slightly above the intersection of the two layers. The aspirate is a partially active injectable version of PRF that can be blended with any particulate bone transplant once it is received.

**Surgical procedure:** It was performed under general anesthesia and under sterile conditions. IM injection of a mixture containing (10mg/ml/kg) Ketamine hydrochloride general anesthetic agent (Hameln / Germany) and (2mg/ml/kg) Xylazine solution for sedation and analgesia (Intercheme / Holland) was given for general anesthesia (induction and maintenance). With a no. 15-scalpel blade, any residual fine fleece at the operation site was carefully scraped off after the animal was anesthetized. The surgical region was disinfected with a 10% povidone iodine (Iraq) solution. For hemostasis, local anesthesia with epinephrine 1:80,000 (New

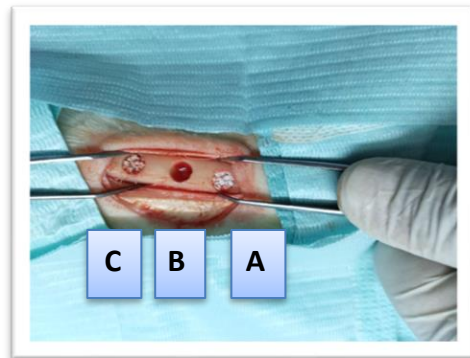
Static / Colombia) was placed by infiltration at the site of the operation prior to the incision. A longitudinal incision of at least 5cm was made separately in skin and periosteum along the lateral surface of bone of the tibia / radius. A trephine bur with 4 mm depth and 7 mm width level mounted on a straight angle handpiece (speed of 1000 rotations per minute) was used to create three standardized monocortical bone defects. During the preparation of the holes, the trephine bur was positioned perpendicular to the long axis of the bone surface. Three typical bone defects of 7 mm width and 4 mm depth, more than 6mm apart, were produced in each tibia or radius under abundant irrigation with chilled 0.9 percent normal saline (Haidylena / Egypt) as shown in Figure (1). The defects were filled in the following order: from a proximal to distal orientation; first defect was to be filled with biphasic calcium phosphate alone, second left empty to be filled by physiological clot, third with i-PRF mixed with biphasic calcium phosphate as shown in Figure (2). For standardization, a pre-weighed amount of BCP (using an electronic weight scale) was instilled into the defect. Animal post-operative care: IM (intramuscular) injection of Oxytetracycline (20 mg/ml/10kg) B.W (Alamycin 10 / Norbrook / UK) was given immediately after surgery. The animals were kept in the animal house for the first week and then were allowed to eat and drink as they pleased, with the veterinarian inspecting

them on a regular basis. Until the sutures were removed, the bandage covering the incision was changed every three days and

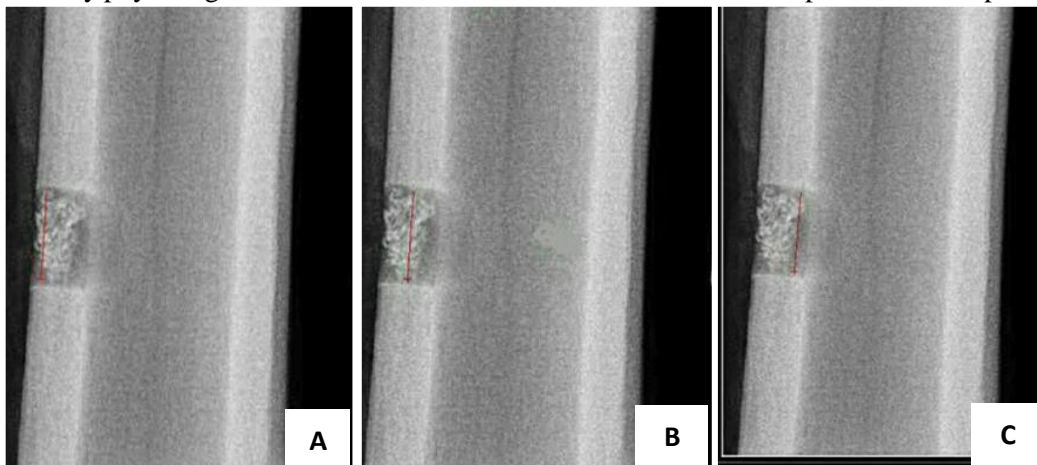the wound was monitored for any signs of infection (at the tenth post-operative day).



**Figure (1):** Three standard bone defects of 7 mm width and 4 mm depth, more than 6mm apart made in each tibia or radius.



**Figure (2) :** **A-** Defect filled with biphasic calcium phosphate alone, **B-** Defect left empty to be filled by physiological clot, **C-** Defect filled with i-PRF mixed with biphasic calcium phosphate.



**Figure (3):** Red line represent Focal of Interest (FOI) for densitometric analysis of bony defect at the upper (A), middle (B) and lower regions (C).

### **Radiographic Assessment**

Densitometric analysis of bone defects was made to evaluate density of bone at four-

time intervals (two, four, six and eight weeks) post-surgically. Animals were euthanized by a licensed butcher once the scheduled operation time frame for each sheep was completed, four 13-15-centimeter limb biopsy specimens were taken from each sheep using a hacksaw and scraped clean from underlying soft tissue. Each tibia/radius was examined with a digital dental radiological machine, and the X-ray images were evaluated with imaging analysis software (version 7.0.3). Densitometric results are represented as a graph with values ranging from 0 to 255, with 0 representing black and 255 representing white. The bone deficiency was the focus of interest (FOI) as shown in Figure (3).

### **Statistical analysis:**

Because all of the variables to be evaluated were non-parametric, the following tests were used: The Kruskal–Wallace test is used to determine the significance of each interval within the same group. For densitometry analysis at scheduled intervals, the Mann-Whitney test is used to show significance between groups.

## **RESULTS**

All of the animals' healing ran smoothly, with no difficulties. There was a total of 60 samples analyzed. Descriptive and Kruskal-Wallis test analysis for mean

gray scale values in the control surgical bone defect group, BCP alone group and BCP+i-PRF group at four intervals showed a statistical significant difference among them, Mann-Whitney test between intervals revealed a highly significant difference between mean gray scale values in two week interval control bone defects and BCP alone group when compared to the other three intervals, a significant difference in four weeks surgical bone defects versus six weeks and eight weeks intervals, and a significant difference in four weeks surgical bone defects versus six weeks and eight weeks intervals. There was also a significant difference between six- and eight-week intervals. The results of the BCP+i-PRF group demonstrated a significant difference between mean gray scale values in the two-week interval when compared to the four- and eight-week intervals, but not with the six-week period. Furthermore, there was a significant difference in surgical bone abnormalities at four weeks, six weeks, and eight weeks intervals. There was also a significant difference between six- and eight-week intervals. When compared to the control defect group and at each time interval, Mann-Whitney test findings for mean gray scale values demonstrated statistical significance across the three groups, with means higher in the BCP + i-PRF group and BCP alone group correspondingly.

**Table 1:** Mean gray scale value comparison of each group at four-time intervals. Vale are Mean (Standard Deviation SD).

Groups	Two weeks	Four weeks	Six weeks	Eight weeks
Control	41.65 (2.14)	63.49 (2.11)	70.76 (6.29)	72.60 (6.82)
BCP	142.37 (2.252)	146.93 (2.434)	152.64 (1.510)	174.43 (0.848)
BCP+i-PRF	141.48 (2.252)	150.2 (2.167)	160.47 (10604)	174.554 (0.847)

**Table 2:** Mean gray scale value comparison among the three groups at four-time intervals. Value is significance.

Groups	Two weeks	Four weeks	Six weeks	Eight weeks
Control verse BCP	0.012*	0.009*	0.009*	0.009*
Control verse i-PRF+BCP	0.009*	0.009*	0.009*	0.009*
BCP verse i-PRF+BCP	0.009*	0.009*	0.009*	0.047*

\*Significance set at  $p \leq 0.05$ 

## DISCUSSION

Due to the propensity of bone to regenerate, under optimal physiological conditions, the vast majority of bone defects can heal on their own. On the other hand, the repair of a bone defect takes time and the formation of new bone is delayed due to a lack of blood flow to the fracture site and a lack of Ca and Ph to reinforce and harden the new bone<sup>10</sup>. When compared to autogenous grafts, BCP has the following advantages: synthetic origin, biocompatibility, osteoconductivity, infinite quantity, and no need for a second surgical site. As a result, in the study, clinically used BCP was chosen<sup>3</sup>. Platelet concentrates have long been utilized to treat a range of diseases in several medical fields, including dentistry, orthopedics, and now dermatology<sup>11</sup>. In the current study, the injectable form of PRF (also termed i-PRF) was used. While many animal species have a faster bone healing rate than humans, sheep have a bone healing rate that is comparable to humans. Sheep, are most

accepted animals for use in experimental studies, primarily in studies evaluating orthopedic and implant systems (in dental clinics), as well as their benefits and drawbacks, when compared to other experimental models in medicine, particularly dentistry, orthopedics, and now dermatology, based on these facts<sup>12</sup>. There are currently no experimental data on the combination of i-PRF and BCP that we are aware of. The current study's findings revealed that BCP has a good effect on bone regeneration at all-time intervals studied. For densitometric analysis, the results of the current study in all i-PRF+BCP groups showed an ascending rise of means in a chronological order. This is an agreement to Abdu et al., study that assessed the influence of using injectable platelet-rich fibrin mixed with bovine bone in management of critical size bone defect and it was discovered that there was a statistically significant difference in mean bone density in both groups at the 3rd and 6th months, concluding that the use of

albumin coated xenograft with PRF was effective in socket preservation, significantly reducing ridge resorption in all dimensions with improved bone quality in the study group<sup>13</sup>. Miron et al. further showed that the usage of (i-PRF) as a biomaterial is well documented in the literature, particularly in dentistry. In all cases where it has been used, authors have found it to be a good alternative to PRP in dermatology<sup>9</sup>.

### CONCLUSIONS

Within the limits of the present study, and at the end of experiment, the study concludes that throughout the study period and as revealed by densitometric results, both BCP and i-PRF increased and sustained bone density. In its current variants, PRF seem to be a well-accepted minimally invasive procedure with positive clinical outcomes.

### REFERENCES

1. Chen Y, Xu J, Huang Z, Yu M, Zhang Y. An Innovative Approach for Enhancing Bone Defect Healing Using PLGA Scaffolds Seeded with Bone Marrow Mesenchymal Stem Cells ( BMSCs ). *Nat Publ Gr* [Internet]. 2017;(February):1–13.
2. Lee E, Kim D, Lim H, Lee J, Jung U, Choi S. Comparative evaluation of biphasic calcium phosphate and biphasic calcium phosphate collagen composite on osteoconductive potency in rabbit calvarial defect. 2015;1–7.
3. Bölükbaşı N, Yeniyoğlu S, Tekkesin MS, Altunalmaz K. The Use of Platelet-Rich Fibrin in Combination With Biphasic Calcium Phosphate in the Treatment of Bone Defects: A Histologic and Histomorphometric Study. *Curr Ther Res - Clin Exp*. 2013;75:15–21.
4. Azzaldeen A, Mai PA, Abu-Hussein P, Istituto M, Toscano S, Toscano IS, et al. Correspondence Abu-Hussein Muhamad Platelet-rich fibrin (PRF) in dentistry. ~ 1 ~ *Int J Appl Dent Sci* [Internet]. 2019;5(4):1–08.
5. Dohan DM, Choukroun J, Diss A, Dohan SL, Dohan AJJ, Mouhyi J, et al. Platelet-rich fibrin (PRF): A second-generation platelet concentrate. Part I: Technological concepts and evolution. *Oral Surgery, Oral Med Oral Pathol Oral Radiol Endodontology*. 2006;101(3).
6. Dohan DM, Choukroun J, Diss A, Dohan SL, Dohan AJJ, Mouhyi J, et al. Platelet-rich fibrin (PRF): A second-generation platelet concentrate. Part II: Platelet-related biologic features. *Oral Surgery, Oral Med Oral Pathol Oral Radiol Endodontology*. 2006;101(3).
7. Dohan DM, Choukroun J, Diss A, Dohan SL, Dohan AJJ, Mouhyi J, et al. Platelet-rich fibrin (PRF): A second-generation platelet concentrate. Part III: Leucocyte activation: A new feature for platelet concentrates? *Oral*

- Surgery, Oral Med Oral Pathol Oral Radiol Endodontology. 2006;101(3).
9. Thanasrisuebwong P, Surarit R, Bencharit S, Ruangsawasdi N. Influence of fractionation methods on physical and biological properties of injectable platelet-rich fibrin: An exploratory study. *Int J Mol Sci.* 2019;20(7).
  10. Miron RJ, Fujioka-Kobayashi M, Hernandez M, Kandalam U, Zhang Y, Ghanaati S, et al. Injectable platelet rich fibrin (i-PRF): opportunities in regenerative dentistry? *Clin Oral Investig.* 2017;21(8):2619–27.
  11. Li Y, Chen SK, Li L, Qin L, Wang XL, Lai YX. Bone defect animal models for testing efficacy of bone substitute biomaterials. *J Orthop Transl.* 2015;3(3):95–104.
  12. Shashank B, Bhushan M. Injectable Platelet-Rich Fibrin (PRF): The newest biomaterial and its use in various dermatological conditions in our practice: A case series. *J Cosmet Dermatol.* 2021;20(5):1421–6.
  13. Sartoretto SC, Uzeda MJ, Miguel FB, Nascimento JR, Ascoli F, Calasans-Maia MD. Sheep as an experimental model for biomaterial implant evaluation. *Acta Ortop Bras.* 2016;24(5):262–6.
  14. abdu islam, elmohandes wael, hosni ahmed. assessment of using injectable PRF mixed with xenograft in the regeneration of critical-sized maxillary bone cavity. *Al-Azhar J Dent Sci.* 2020;23(4):383–91.