

December 2023

## Prostatic Utricle Presenting as a Midline Scrotal Mass

Kaitlyn E. Schultis

*University of Nebraska Medical Center*

Bryant Van Leeuwen

*University of Nebraska Medical Center*

John Makari

*Children's Hospital and Medical Center and University of Nebraska Medical Center*

Tell us how you used this information in this [short survey](#).

Follow this and additional works at: <https://digitalcommons.unmc.edu/gmerj>



Part of the [Male Urogenital Diseases Commons](#), and the [Urogenital System Commons](#)

### Recommended Citation

Schultis, K. E., Van Leeuwen, B., , Makari, J. Prostatic Utricle Presenting as a Midline Scrotal Mass. Graduate Medical Education Research Journal. 2023 Dec 26; 5(2).  
<https://digitalcommons.unmc.edu/gmerj/vol5/iss2/13>

This Case Report is brought to you for free and open access by DigitalCommons@UNMC. It has been accepted for inclusion in Graduate Medical Education Research Journal by an authorized editor of DigitalCommons@UNMC. For more information, please contact [digitalcommons@unmc.edu](mailto:digitalcommons@unmc.edu).

---

## Prostatic Utricle Presenting as a Midline Scrotal Mass

### Abstract

The prostatic utricle is a remnant of the Müllerian duct located within the verumontanum. An enlarged, clinically significant prostatic utricle has classically been associated with hypospadias. Prostatic utricles often present with persistent lower urinary tract symptoms, recurrent infections, and urinary incontinence. We present a prostatic utricle that presented as a scrotal mass concerning for rhabdomyosarcoma in a male with normal external genitalia.

### Keywords

prostatic utricle, scrotal mass, rhabdomyosarcoma, utricle

### Creative Commons License



This work is licensed under a [Creative Commons Attribution-Noncommercial-No Derivative Works 4.0 License](https://creativecommons.org/licenses/by-nc-nd/4.0/).

### Cover Page Footnote

ACKNOWLEDGEMENTS N/A FUNDING SOURCE Self-funded CONFLICTS OF INTERESTS The authors have no conflicts of interest to disclose.

## Prostatic Utricle Presenting as a Midline Scrotal Mass

Kaitlyn E. Schultis<sup>1</sup>, Bryant Van Leeuwen<sup>2</sup>, John Makari<sup>2,3</sup>

<sup>1</sup>College of Medicine, University of Nebraska Medical Center, Omaha, NE, USA

<sup>2</sup>Division of Urology, University of Nebraska Medical Center, Omaha, NE, USA

<sup>3</sup>Division of Pediatric Urology, Children's Hospital and Medical Center, Omaha, NE, USA

<https://doi.org/10.32873/unmc.dc.gmerj.5.2.013>

### Abstract

The prostatic utricle is a remnant of the Müllerian duct located within the verumontanum. An enlarged, clinically significant prostatic utricle has classically been associated with hypospadias. Prostatic utricles often present with persistent lower urinary tract symptoms, recurrent infections, and urinary incontinence. We present a prostatic utricle that presented as a scrotal mass concerning for rhabdomyosarcoma in a male with normal external genitalia.

### Keywords

Prostatic utricle, scrotal mass, rhabdomyosarcoma, utricle

### Introduction

In this case, we describe an enlarged prostatic utricle, which presented as a firm, midline scrotal mass most concerning for rhabdomyosarcoma. Prostatic utricles are a normal remnant of the Müllerian duct located in the midline of the prostatic urethra at the level of the verumontanum. Enlarged prostatic utricles, or cystic prostatic utricles, can cause lower urinary tract symptoms or recurrent infections requiring surgical excision. To our knowledge, this is the first report of a prostatic utricle presenting as a scrotal mass.

### Case

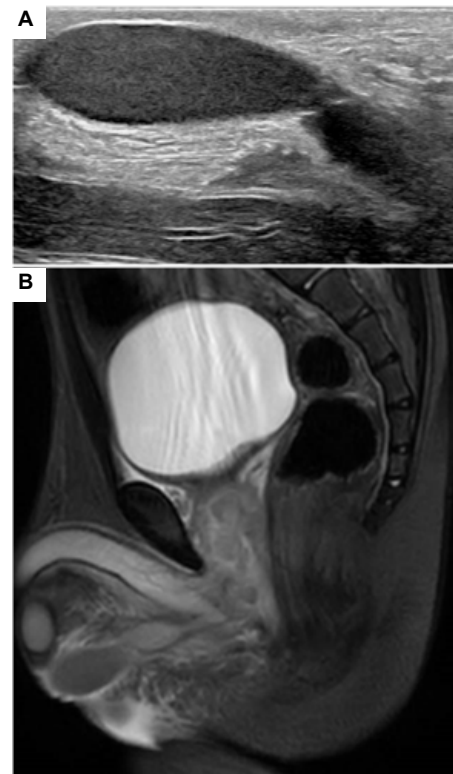
A 2-year-old male presented to our Emergency Department with an enlarging scrotal mass. His mother first recognized the scrotal mass the day prior and presented to an outside facility where a scrotal ultrasound was performed, showing a hypoechoic mass between the testicles with a small tract extending into the pelvis. At that time, they scheduled a follow-up with an MRI. However, the patient's mass continued to grow and became associated with pain and fever. Physical exam revealed a 3 cm scrotal mass abutting the midline scrotal skin that extended toward the bulbar urethra, where it appeared to terminate (**Figure 1**). It was tender and did not involve the testicles or cord structures.

There was concern for scrotal abscess, urethral fistula with urinoma, or a solid tumor. Scrotal ultrasound did not show evidence of the mass tracking into the inguinal canal or a bowel gas pattern (**Figure 2A**).

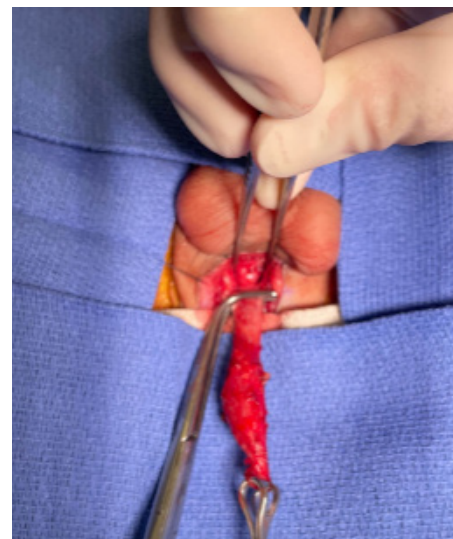
MRI pelvis with and without contrast was then obtained, which showed a heterogeneously enhancing mass centered in the prostate “likely representing rhabdomyosarcoma” (**Figure 2B**). MRI also showed subcentimeter adenopathy and potential invasion at the bladder base. The patient was then taken to the operating room for cystoscopy and scrotal exploration under the same anesthesia. Pan cystoscopy was normal, however, pressure applied to the mass caused an expulsion of a purulent paste-like material from the verumontanum/prostatic utricle, which was sent for culture. The mass was then suture ligated, with the origin of the proximal stalk being just right of the bulbar urethra, consistent with a prostatic utricle (**Figure 3**). A foley catheter was placed for 5 days. Final pathology showed an inflamed squamous epithelium-lined cyst. Follow-up ultrasound six weeks post-op showed normal scrotum.



**Figure 1.** Midline scrotal lesion, separate from the testicles and cord structures.



**Figure 2.** Imaging results. A) Midline sagittal US showing an intrascrotal, extratesticular mass extending toward midline pelvis & B) MRI pelvis showing heterogeneously enhancing mass centered in the region of the prostate with cystic extension into the scrotum.



**Figure 3.** Mass dissected to bulbar urethra.

## Discussion

The prostatic utricle is a vestigial structure present in all males and is located within the midline prostatic urethra as a slit at the verumontanum. It is formed as a part of normal embryologic male development by the regression of Müllerian duct structures in response to Müllerian-inhibiting substance. An enlarged prostatic utricle is classically defined as a utricle which allows passage of a cystoscope at least 2 cm deep.<sup>1</sup> Enlarged prostatic utricles were first noted to be associated with hypospadias in 1948.<sup>2</sup> They have also been linked to cryptorchidism and other disorders of sexual development. However, the majority of pediatric literature on enlarged, symptomatic utricles revolves around boys with hypospadias. In this population, it is present in 14-57 percent of boys, depending on the severity of hypospadias, with a higher correlation in proximal hypospadias.<sup>3</sup>

The majority of enlarged prostatic utricles are asymptomatic. However, they can cause external compression of the urethra, causing significant lower urinary tract symptoms, including dysuria, hematuria, post-void dribbling, and pseudo-incontinence caused by emptying of the utricle between voids.<sup>4</sup> Stasis of urine within the enlarged utricle can also cause urinary tract infections, stone formation, recurrent epididymo-orchitis, and rarely scrotal abscesses.<sup>5</sup> Enlarged utricles can also be the cause of difficult catheterization and are suspected at the time of difficult stent placement during hypospadias repair.

Diagnoses of a clinically significant prostatic utricle is typically achieved with a voiding cystourethrogram or retrograde urethrogram, which can visualize the utricle about 80% of the time. Some have argued for the use of ultrasound as an initial diagnostic test, given its non-invasive nature. Kojima et al. argued that ultrasonography was able to visualize an enlarged utricle in 75% of their contingent.<sup>6</sup> However, there has been little literature after 2001, and with the advancement in sonographic technologies, the rate of diagnosis may be equivocal. In cases where a prostatic utricle is suspected but imaging is negative, cystoscopy allows for a definitive diagnosis. A grading system for utricles has been devised based on cystoscopy and retrograde urethrogram:

- Grade 0 – the opening is within the posterior urethra, with proximal extent of the body distal to the verumontanum.
- Grade I – the opening is within the posterior urethra, with proximal extent past the verumontanum.

- Grade II – the opening is within the posterior urethra with proximal extent past the bladder neck.
- Grade III – the opening is proximal to the bulbous urethra.<sup>7</sup>
- However, there has been no clinical correlation of this grading scale outside of its relation to severity of hypospadias.

Treatment of symptomatic prostatic utricles is surgical through an open perineal or laparoscopic/robotic abdominal approach. Surgery can be complicated given the anatomical relation to the vas deferens, seminal vesicles, bladder, rectum, ureters, and vascular structures. Some have described cystoscopic treatment with fulguration having good success rates and resolution of symptoms.<sup>8</sup>

Our case represents a unique presentation in multiple ways. An isolated, enlarged, symptomatic prostatic utricle in males with normal external genitalia is considered uncommon. While there has been some recent attention on this subject in lower urinary tract symptoms in phenotypically normal males, there is a paucity of presentations in the pediatric literature outside of hypospadias.<sup>5</sup> To our knowledge, this is the first case of a prostatic utricle presenting as a scrotal mass or having extension into the scrotum. Ramareddy & Alladi reported a case of recurrent scrotal abscesses requiring excision of a prostatic utricle, left hemi-uterus and fallopian tube, and left gonad with vas and its vessels. On histology, there was no testicular tissue.<sup>9</sup> Our case differs significantly given his normal external genitalia and single rapidly enlarging mass apparent in the scrotum.

Further setting this case apart is the physical exam and ultrasound concerning for a mass and the MRI showing the appearance of a heterogeneously enhancing mass within the prostate.

## Conclusion

This case, to our knowledge, is the first reported case of a prostatic utricle presenting as an enlarging scrotal mass in a boy with normal external genitalia. Ultrasound and MRI were both concerning for a rhabdomyosarcoma or another solid tumor. Given this and other case reports, more attention should be brought to boys with normal external genitalia and enlarged hypospadias. In cases of a rapidly enlarging scrotal masses, an enlarged prostatic utricle should be considered in the differential. ■

## Funding Source

Self-funded

## Conflicts of Interest

The authors have no conflicts of interest to disclose.

## References

- 1 Kogan SJ, Hafez ESE. Pediatric Andrology. *Clinics in Andrology*. Volume 7. Dordrecht Springer Netherlands; 2012:188. doi: 10.1007/978-94-011-7511-1
- 2 Howard FS. Hypospadias with enlargement of the prostatic utricle. *Surg Gynecol Obstet*. 1948;86(3):307-316.
- 3 Devine CJ, Gonzalez-Serva L, Stecker JF, Devine PC, Horton CE. Utricular configuration in hypospadias and intersex. *J Urol*. 1980;123(3):407-411. doi: 10.1016/s0022-5347(17)55959-5
- 4 Gygi C, Carvajal MI, Plaschkes J, Kaiser G. Prostatic utricle: an unusual case report. *Eur J Pediatr Surg*. 1994;4(4):211-213. doi: 10.1055/s-2008-1066107
- 5 Hester AG, Kogan SJ. The prostatic utricle: An under-recognized condition resulting in significant morbidity in boys with both hypospadias and normal external genitalia. *J Pediatr Urol*. 2017;13(5):492.e1-492.e5. doi: 10.1016/j.jpuro.2017.01.019
- 6 Kojima Y, Hayashi Y, Maruyama T, Sasaki S, Kohri K. Comparison between ultrasonography and retrograde urethrography for detection of prostatic utricle associated with hypospadias. *Urology*. 2001;57(6):1151-1155. doi: 10.1016/s0090-4295(01)00954-2
- 7 Ikoma F, Shima H, Yabumoto H. Classification of enlarged prostatic utricle in patients with hypospadias. *Br J Urol*. 1985;57(3):334-337. doi: 10.1111/j.1464-410x.1985.tb06356.x
- 8 Husmann DA, Allen TD. Endoscopic management of infected enlarged prostatic utricles and remnants of rectourethral fistula tracts of high imperforate anus. *J Urol*. 1997;157(5):1902-1906. doi: 10.1016/S0022-5347(01)64898-5
- 9 Ramareddy RS, Alladi A. Scrotal abscess: Varied etiology, associations, and management. *J Indian Assoc Pediatr Surg*. 2016;21(4):164-168. doi: 10.4103/0971-9261.186545