

Fall 2023

An Unusual Presentation of Pigmented Purpuric Lichenoid Dermatitis

Christine De Antonis

Jordan T. Hyde

Jason B. Lee

Sylvia Hsu

Follow this and additional works at: <https://jdc.jefferson.edu/dcbfp>



Part of the [Dermatology Commons](#), and the [Skin and Connective Tissue Diseases Commons](#)

[Let us know how access to this document benefits you](#)

This Article is brought to you for free and open access by the Jefferson Digital Commons. The Jefferson Digital Commons is a service of Thomas Jefferson University's [Center for Teaching and Learning \(CTL\)](#). The Commons is a showcase for Jefferson books and journals, peer-reviewed scholarly publications, unique historical collections from the University archives, and teaching tools. The Jefferson Digital Commons allows researchers and interested readers anywhere in the world to learn about and keep up to date with Jefferson scholarship. This article has been accepted for inclusion in Department of Dermatology and Cutaneous Biology Faculty Papers by an authorized administrator of the Jefferson Digital Commons. For more information, please contact: JeffersonDigitalCommons@jefferson.edu.

UC Davis

Dermatology Online Journal

Title

An unusual presentation of pigmented purpuric lichenoid dermatitis

Permalink

<https://escholarship.org/uc/item/81j436wv>

Journal

Dermatology Online Journal, 29(5)

Authors

De Antonis, Christine
Hyde, Jordan T
Lee, Jason B
[et al.](#)

Publication Date

2023

DOI

10.5070/D329562410

Copyright Information

Copyright 2023 by the author(s). This work is made available under the terms of a Creative Commons Attribution-NonCommercial-NoDerivatives License, available at <https://creativecommons.org/licenses/by-nc-nd/4.0/>

Peer reviewed

An unusual presentation of pigmented purpuric lichenoid dermatitis

Christine De Antonis¹ BS, Jordan T Hyde¹ MD, Jason B Lee² MD, Sylvia Hsu¹ MD

Affiliations: ¹Department of Dermatology, Temple University Lewis Katz School of Medicine, Philadelphia, Pennsylvania, USA, ²Department of Dermatology and Cutaneous Biology, Sidney Kimmel Medical College, Philadelphia, Pennsylvania, USA

Corresponding Author: Sylvia Hsu MD, Department of Dermatology, Temple University Hospital, 3401 North Broad Street, Suite B500, Philadelphia, PA 19140, Tel: 215-707-3376, Email: Sylvia.Hsu@tuhs.temple.edu

Abstract

Pigmented purpuric lichenoid dermatitis (PPLD) is a rare subtype of pigmented purpuric dermatosis, which classically presents with a mixture of lichenoid papules and patches on the bilateral lower extremities. Herein, we describe an unusual case of a 47-year-old man with PPLD who presented with 1-3mm discrete papules without the presence of larger patches. The diagnosis of PPLD should be considered for patients presenting with bilateral symmetric discrete papules on the legs.

Keywords: Blum, capillaritis, dermatosis, Gougerot, lichenoid, pigmented, purpuric

Introduction

Pigmented purpuric dermatoses (PPD), also known as capillaritis, are a group of chronic skin disorders characterized by the presence of symmetric petechial lesions primarily present on the lower extremities [1,2]. Pathogenesis is believed to be secondary to subtle inflammation of superficial capillaries in the papillary dermis with subsequent erythrocyte extravasation [1,2]. Although clinical presentation varies depending on the subtype of PPD, lesions frequently appear as red-brown macules and patches due to hemosiderin formation from erythrocyte degradation [2]. Five main clinical variants are described and include progressive purpuric pigmented dermatosis, or Schamberg disease (the most common variant), purpura

annularis telangiectodes of Majocchi, pigmented purpuric lichenoid dermatitis of Gougerot and Blum, eczematid-like purpura of Doucas and Kapetanakis, and lichen aureus [1,2]. All variants share similar histologic features, including blood vessel dilation, erythrocyte extravasation, hemosiderin deposition, and superficial perivascular lymphohistiocytic infiltrate [1,2].

Pigmented purpuric lichenoid dermatitis of Gougerot and Blum (PPLD) is a rare subtype most often seen in middle-aged to older men [2]. Typical presentation involves a mixture of symmetric Schamberg-like lesions (yellow-brown patches with pinpoint petechiae, resembling cayenne pepper) and red-brown lichenoid papules on the bilateral lower extremities [2]. The disease tends to be chronic and occasionally pruritic [2]. In addition to the common histologic features shared among all PPD, PPLD may demonstrate a lichenoid infiltrate, spongiosis, and focal parakeratosis [2].

Given the rarity of PPLD, limited reports exist, which describe the full spectrum of clinical features seen in this disease. Herein, we describe an unusual case of PPLD which presented with chronic discrete papules without the classic Schamberg-like patches.

Case Synopsis

A 47-year-old man presented with a stable, occasionally pruritic rash on his lower legs and feet that had persisted for the past 10 years. The patient had never sought treatment previously. Skin

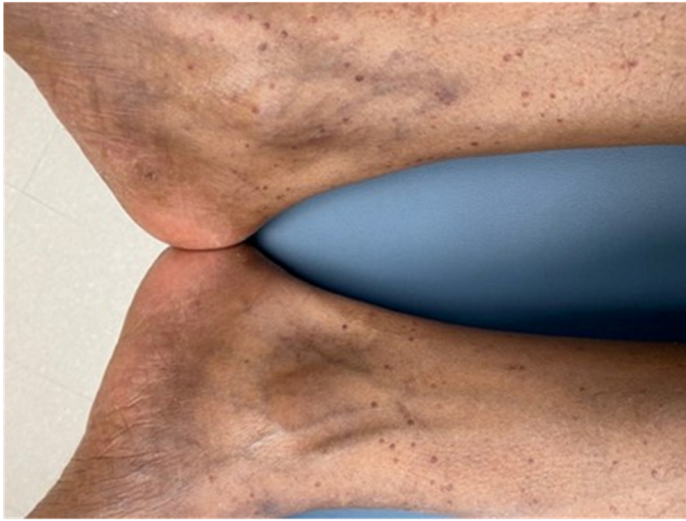


Figure 1. 1-3mm red-brown papules distributed symmetrically on the bilateral lower extremities.

examination revealed 1-3mm, symmetric red-brown papules on his lower legs and dorsal feet bilaterally (**Figure 1**). Skin biopsies of the left and right shins were performed which showed focal superficial perivascular infiltrate consistent of lymphocytes, histiocytes, and extravasated erythrocytes with overlying subtle interface dermatitis (**Figure 2**). Due to the stable and asymptomatic nature of the lesions, the patient deferred treatment at this time.

Case Discussion

Most published case reports describing patients with PPLD depict the presence of both types of lesions. However, in the patient described here, discrete papules were present chronically without the presence of larger patches.

The optimal treatment regimen for patients with PPD remains uncertain, but current guidelines recommend utilization of non-pharmacological interventions, such as compression stockings and

References

1. Sardana K, Sarkar R, Sehgal VN. Pigmented purpuric dermatoses: An overview. *Int J Dermatol.* 2004;43:482–8. [PMID: 15230884].
2. Spigariolo CB, Giacalone S, Nazzaro G. Pigmented Purpuric Dermatoses: A Complete Narrative Review. *J Clin Med.* 2021;10:2283. [PMID: 34070260].
3. Kaplan J, Burgin S, Sepehr A. Granulomatous pigmented purpura: report of a case and review of the literature. *J Cutan Pathol.* 2011;38:984–9. [PMID: 21752054].
4. Rudolph RI. Lichen aureus. *J Am Acad Dermatol.* 1983;8:722–4. [PMID: 6863634].
5. Lor P, Krueger U, Kempf W, Burg G, Nestle FO. Monoclonal rearrangement of the T cell receptor gamma-chain in lichenoid pigmented purpuric dermatitis of gougerot-blum responding to topical corticosteroid therapy. *Dermatol Basel Switz.*

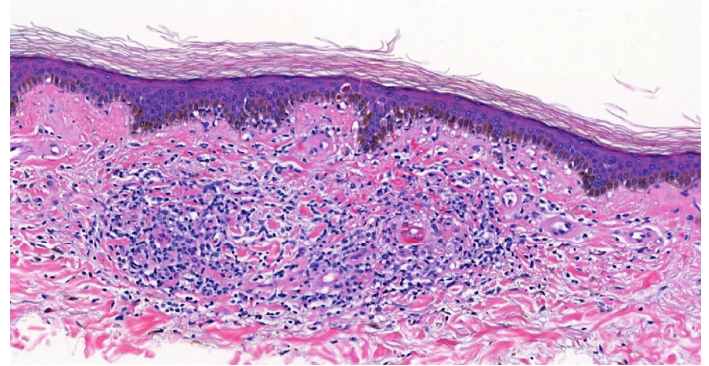


Figure 2. Histopathology demonstrating focal lymphohistiocytic perivascular infiltrate and extravasated erythrocytes with subtle overlying interface. H&E, 20x.

topical corticosteroids as first-line therapy options [3-10]. Additional options include but are not limited to topical calcineurin inhibitors [11], phototherapy [6,12-14], pentoxifylline [15], rutoside/ascorbic acid [16], and colchicine [17,18].

There is a lack of data analyzing efficacy of the aforementioned treatment options, specifically in PPLD patients. As such, it remains unclear whether PPLD patients would benefit from a tailored therapeutic regimen which differs from other PPD subtypes.

Conclusion

Pigmented purpuric lichenoid dermatitis classically presents with a combination of cutaneous papules and larger patches. In the patient described here, discrete papules were present without patches. It is important that dermatologists are aware of this uncommon PPLD presentation.

Potential conflicts of interest

The authors declare no conflicts of interest.

- 2002;205:191–3. [PMID: 12218245].
6. Coulombe J, Jean S-E, Hatami A, et al. Pigmented purpuric dermatosis: clinicopathologic characterization in a pediatric series. *Pediatr Dermatol*. 2015;32:358–62. [PMID: 25690369].
 7. Newton RC, Raimer SS. Pigmented purpuric eruptions. *Dermatol Clin*. 1985;3:165–9. [PMID: 4092379].
 8. Ratnam KV, Su WP, Peters MS. Purpura simplex (inflammatory purpura without vasculitis): a clinicopathologic study of 174 cases. *J Am Acad Dermatol*. 1991;25:642–7. [PMID: 1791222].
 9. Moche J, Glassman S, Modi D, Grayson W. Segmental lichen aureus: a report of two cases treated with methylprednisolone aceponate. *Australas J Dermatol*. 2011;52:15–8. [PMID: 21605087].
 10. Risikesan J, Sommerlund M, Ramsing M, Kristensen M, Koppelhus U. Successful Topical Treatment of Pigmented Purpuric Lichenoid Dermatitis of Gougerot-Blum in a Young Patient: A Case Report and Summary of the Most Common Pigmented Purpuric Dermatoses. *Case Rep Dermatol*. 2017;9:169–76. [PMID: 29033823].
 11. Murota H, Katayama I. Lichen aureus responding to topical tacrolimus treatment. *J Dermatol*. 2011;38:823–5. [PMID: 21352316].
 12. Kocaturk E, Kavala M, Zindanci I, et al. Narrowband UVB treatment of pigmented purpuric lichenoid dermatitis (Gougerot-Blum). *Photodermatol Photoimmunol Photomed*. 2009;25:55–6. [PMID: 19152519].
 13. Fathy H, Abdelgaber S. Treatment of pigmented purpuric dermatoses with narrow-band UVB: a report of six cases. *J Eur Acad Dermatol Venereol JEADV*. 2011;25:603–6. [PMID: 21492246].
 14. Krizsa J, Hunyadi J, Dobozy A. PUVA treatment of pigmented purpuric lichenoid dermatitis (Gougerot-Blum). *J Am Acad Dermatol*. 1992;27:778–80. [PMID: 1430408].
 15. Panda S, Malakar S, Lahiri K. Oral pentoxifylline versus topical betamethasone in Schamberg disease: a comparative randomized investigator-blinded parallel-group trial. *Arch Dermatol*. 2004;140:491–3. [PMID: 15096387].
 16. Schober SM, Peitsch WK, Bonsmann G, et al. Early treatment with rutoside and ascorbic acid is highly effective for progressive pigmented purpuric dermatosis. *J Dtsch Dermatol Ges J Ger Soc Dermatol JDDG*. 2014;12:1112–9. [PMID: 25482694].
 17. Cavalcante MLLL, Masuda PY, de Brito FF, et al. Schamberg's disease: case report with therapeutic success by using colchicine. *An Bras Dermatol*. 2017;92:246–8. [PMID: 28538889].
 18. Geller M. Benefit of colchicine in the treatment of Schamberg's disease. *Ann Allergy Asthma Immunol Off Publ Am Coll Allergy Asthma Immunol*. 2000;85:246. [PMID: 11030283].