

Case Report

Trocar Site Recurrence after Laparoscopic Cholecystectomy for Unsuspected Isolated Gallbladder Metastasis of Melanoma: A Case Report and Review of the Literature

Céline Sergeant^{a,b} Joseph Kerger^a Annie Drowart^a François Sales^c
Mireille Langoua^a

^aDepartment of Medical Oncology, Institut Jules Bordet, Brussels, Belgium; ^bDepartment of Medical Oncology, Université Libre de Bruxelles, Brussels, Belgium; ^cDepartment of Surgical Oncology, Institut Jules Bordet, Brussels, Belgium

Keywords

Melanoma · Gallbladder · Metastasectomy · Laparoscopy · Port-site metastasis

Abstract

Cutaneous melanoma can metastasize to almost any organ, including in-transit metastases, lymph nodes, liver, lungs, brain, and bones. Spread to the gastrointestinal tract is less common and generally concerns the small bowel, colon, and stomach. Gallbladder involvement is rarer, and only few cases describe it as the sole site of metastasis upon diagnosis. Melanoma metastases to the gallbladder are usually detected on staging or surveillance imaging, as patients usually show few or no symptoms. In resectable stage IV melanoma patients, complete surgical resection appears to improve the prognosis. However, due to the rarity of isolated gallbladder metastasis of melanoma, there are no guidelines regarding the optimal surgical approach (endoscopic or open cholecystectomy). Here, we report the case of isolated gallbladder melanoma metastasis found after laparoscopic cholecystectomy performed in a 46-year-old female patient with no known history of cancer presenting with acute cholecystitis symptoms. Six weeks after surgery, the patient developed trocar site recurrence. This case highlights the importance of a planned and open surgery for resectable melanoma metastases rather than a laparoscopic approach.

© 2023 The Author(s).
Published by S. Karger AG, Basel

Correspondence to:
Céline Sergeant, celine.sergeant@outlook.com

Introduction

Cutaneous melanoma is known to metastasize to any organ. The most affected sites are the lymph nodes, skin, lungs, brain, and liver. Even if malignant melanoma is one of the most common malignancies associated with metastatic disease of the gastrointestinal (GI) tract [1], GI involvement represents less than 5% of metastatic melanomas. The majority of the latter are found in the small intestine [2, 3]. The gallbladder as the sole metastatic site is rarely described. While autopsy studies show that occult gallbladder metastases are found in up to 20% of patients deceased from melanoma [4], gallbladder involvement is rarely reported in living patients as it is usually associated with diffuse metastatic disease [5, 6]. Besides, only 15% of patients diagnosed with gallbladder metastasis of melanoma present with typical acute cholecystitis, while most of them are asymptomatic or present with nonspecific symptoms [7].

According to the 8th AJCC classification, melanoma with detectable distant metastatic disease is classified as stage IV melanoma and historically predicted a poor prognosis, with a 5-year survival of only 5–10% and a median survival of 6–10 months, depending on the site of metastases [8]. Current evidence has shown that in resectable stage IV melanoma patients, complete resection of all distant metastatic lesions improves the prognosis [8–10]. However, spread to the gallbladder being rarely found in an oligometastatic resectable situation, guidelines regarding optimal surgical approach for its resection are lacking. Fast recovery after a minimally invasive procedure (endoscopic approach) could allow the patient to rapidly initiate adjuvant immunotherapy [7]. However, laparoscopic techniques may be at risk of peritoneal or port-site metastases [2, 3, 11].

Hereafter, we discuss the case of a 46-year-old woman with a sole site of melanoma metastasis in the gallbladder. The CARE Checklist has been completed by the authors for this case report, attached as online supplementary material (for all online suppl. material, see <https://doi.org/10.1159/000534147>).

Case Presentation

A 46-year-old Caucasian female patient with no history of cancer and no other relevant personal history except for a slight overweight (body mass index of 26 kg per meter squared) presented to the emergency department of a general hospital for sudden abdominal pain and vomiting. She had no fever. Physical examination revealed right upper quadrant and epigastric tenderness, with a positive Murphy's sign and a nonpalpable gallbladder. Laboratory findings showed a mild inflammatory syndrome (C-reactive protein 10 mg per liter, normal laboratory value inferior to 5 and white blood cell count 12,840 per mL, normal laboratory value inferior to 10,000), as well as a slightly elevated transaminase level (aspartate aminotransferase 42 units per liter, normal laboratory value inferior to 34) and a high level of gamma-glutamyl transferase (111 units per liter, normal laboratory value inferior to 36). The bilirubin level was normal. An abdominal ultrasound showed a distended gallbladder (approximately 6 cm wide and 11 cm long) with hydrops due to intraluminal heterogeneous material (shown in Fig. 1a). The patient was diagnosed with uncomplicated acute cholecystitis, and no other examination was performed. She underwent a few days later a laparoscopic cholecystectomy. Abdominal cavity exploration revealed a thickened gallbladder wall with patches of necrosis. Manipulation of the gallbladder led to its inadvertent perforation and intraperitoneal emission of a purulent fluid. The gallbladder was then placed in a retrieval bag and removed through the supra-umbilical trocar site. In total, the procedure lasted approximately 40 min and there was little intraoperative blood loss (less than 100 mL). Pathological report found an

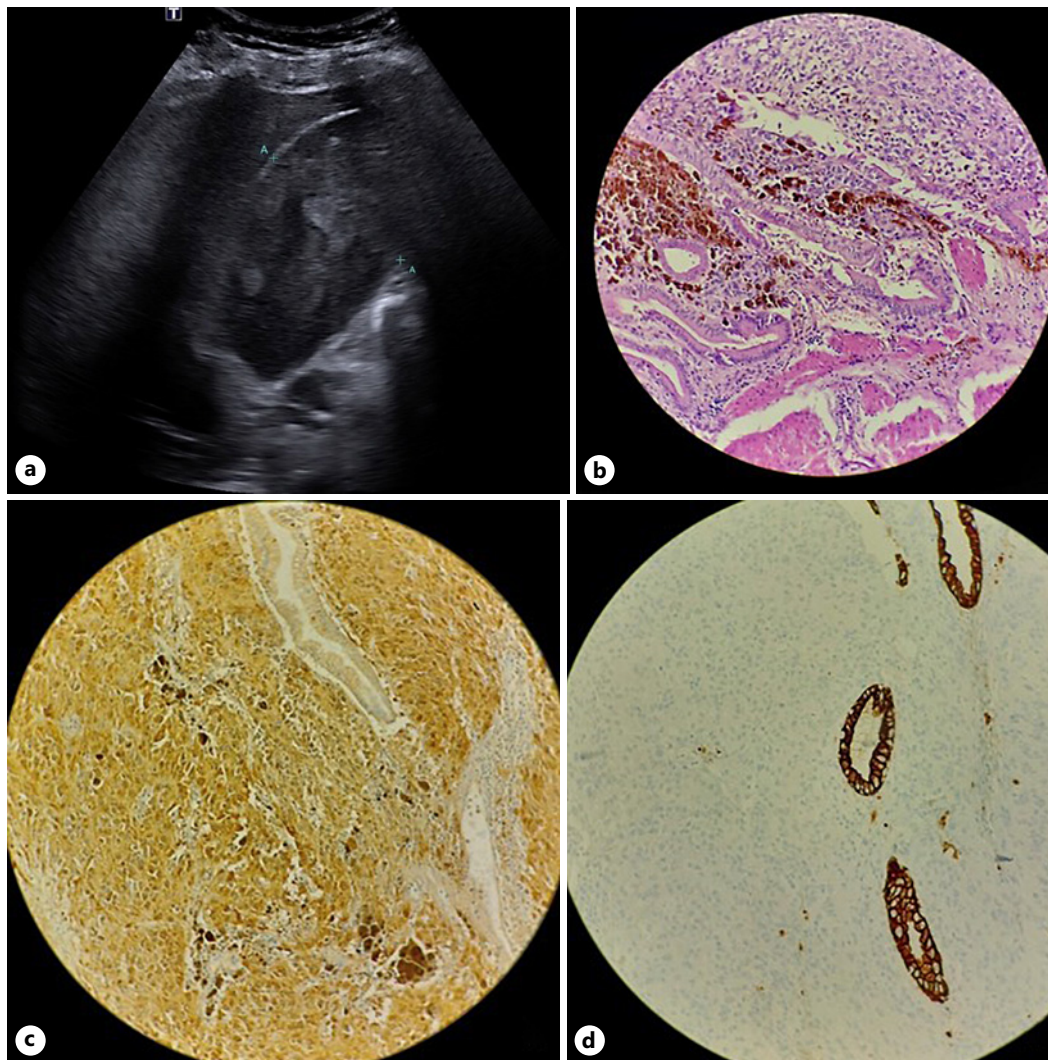


Fig. 1. Abdominal ultrasound showing a distended gallbladder filled with intraluminal heterogeneous material (a), histological examination of surgical specimen showing the gallbladder and the tumor with melanocytic pigments (b), immunohistochemistry staining positive for S100 in the tumor and negative in the glands (c), and negative for CKAE1AE3 in the tumor and positive in the glands (d).

8 cm endoluminal necrotic mass compatible with a mutated BRAF V600E melanoma (shown in Fig. 1b–d). The patient was then addressed to our oncological institute for her melanoma workup and treatment. A positron emission tomography scan showed no 18F-fluorodeoxyglucose-avid lesion (neither the primary cutaneous melanoma nor distant lesions). Brain magnetic resonance was normal as well. Dermatologic examination revealed a small lesion (1 cm in its long axis) on the patient's back (shown in Fig. 2). Resection confirmed a superficial spreading melanoma, Breslow thickness of 0.55 mm, Clark level II, with no ulceration, stratified pT1a, considered the probable primary lesion. The patient was considered with no residual disease and started anti-PD-1 monotherapy with Pembrolizumab. Six weeks after surgery and 3 weeks after the first course of Pembrolizumab, the patient noticed a palpable supra-umbilical mass (shown in Fig. 3a). A repeated positron emission tomography scan revealed an 18F-fluorodeoxyglucose avid (sub-)cutaneous lesion in the supra-umbilical

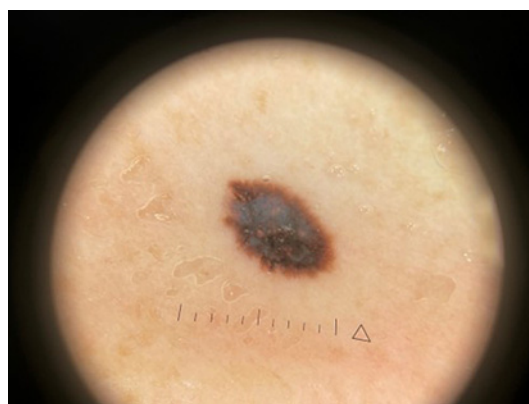


Fig. 2. Dermoscopy of suspected primary cutaneous melanoma on the patient's back (1 cm in its long axis).

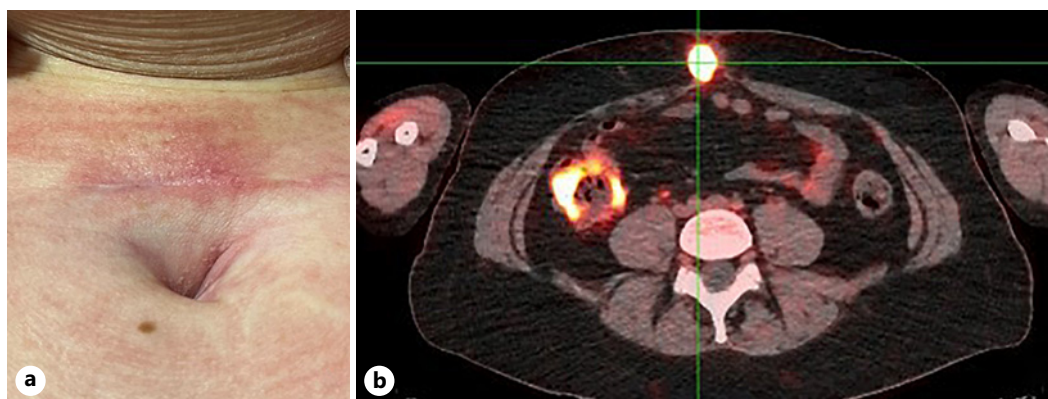


Fig. 3. Palpable supra-umbilical mass (a), positron emission tomography scan showing a 18F-fluorodeoxyglucose-avid (sub-)cutaneous lesion in the supra-umbilical trocar site (b).

trocar site (the one used to extract the gallbladder during laparoscopic surgery) (shown in Fig. 3b). Biopsy confirmed the diagnosis of port-site metastasis. The patient died a few months later of widespread metastatic disease (peritoneum, lymph nodes, liver, bones).

Discussion

Cutaneous melanoma has a high propensity to metastasize. Most frequent sites include lymph nodes, skin, lungs, brain, and liver, whereas spread to the GI tract occurs at a frequency of less than 5% [2, 3]. In 15% of those cases only, the gallbladder is found to be a metastatic site [2]. Nevertheless, while metastatic spread of melanoma to the gallbladder is rare, melanoma still accounts for approximately 50% of metastatic lesions found in this organ. A bit less frequent primary origins are renal cell carcinoma, breast cancer, and GI tract tumors [12].

The most likely metastatic pathway of melanoma to the gallbladder is hematologic spread [3, 7], but another theory supports the migration of microscopic liver foci to the gallbladder through bile flow [3, 13, 14], which could explain the common synchronous dissemination to the small intestine [13]. When found, gallbladder metastasis is usually seen in the context of a widespread metastatic disease [5, 6]. Rarely, patients have melanoma metastasis limited to

the gallbladder, and existing literature is thus limited to case reports and small case series, explaining the lack of standard diagnostic and therapeutic guidelines.

Reviewing the literature of case reports published in English between 2000 and 2022, we found 24 cases of melanoma metastasized to the gallbladder which underwent surgical resection (described in Table 1). As it does in our patient, the gallbladder represents the unique distant metastatic site (upon diagnosis or at recurrence) in 14 of those cases. The time between melanoma diagnosis and discovery of gallbladder metastasis varies significantly, from synchronous detection to 9 years later. Histology, Breslow thickness, Clark level, and sentinel lymph node biopsy status also vary significantly across case reports, and gallbladder metastasis can arise even in low-risk melanoma [12].

Gallbladder melanoma metastatic lesions are asymptomatic in approximately half of the cases, thus being discovered on staging or surveillance imaging. Half of patients present symptoms, however usually nonspecific, such as nausea, abdominal pain, lack of appetite, or weakness, whereas only 15% mimic typical acute cholecystitis [7, 13, 29], as did our patient. Jaundice, obstruction of the common bile duct, hemobilia, and biliary fistula have also been reported [5]. Laboratory tests are usually normal, although there can be a slight increase in neutrophil count (in case of cholecystitis) and liver tests [5].

Right upper quadrant abdominal pain is a common complaint in the emergency department. In most adults presenting with acute onset of upper right abdominal pain, biliary colic or acute cholecystitis are usually the first primary diagnostic considerations. However, other benign and malignant conditions can mimic acute cholecystitis [30]. In our case, given the patient's age, gender, and phenotype (slightly overweight), the absence of relevant medical history, the clinical presentation, and the mild inflammatory syndrome, acute cholecystitis was the first hypothesis. When acute cholecystitis is suspected, ultrasound is usually the first imaging test performed, as it is non-invasive, non-irradiating, inexpensive, and widely available [30]. The presence of cholelithiasis combined with a positive sonographic Murphy's sign are the most specific sonographic findings of acute cholecystitis. Other frequently found but less specific signs include gallbladder distension, wall thickening, and the presence of pericholecystic fluid [31]. Metastases to the gallbladder are generally described as a focal thickening of the gallbladder wall or a hyperechoic polypoid mass with few acoustic shadowing. The image may show a lumen filled with content in which it is difficult to differentiate between tumefactive biliary sludge and neoplastic masses [32], as in the presented case. We retrospectively examined the patient's ultrasound images at presentation. There was gallbladder distension, but the absence of wall thickening and cholelithiasis pleaded against the acute cholecystitis hypothesis. Moreover, the heterogeneity of the intraluminal material should have been considered suspicious, and second-step investigations should have been conducted, such as a computed tomography scanner, magnetic resonance imaging, and positron emission tomography scan.

Metastasectomy is standard treatment for patients affected with solitary resectable melanoma metastasis to prolong their survival [8, 13, 14]. In a 1999 series [29], 7 resectable stage IV melanoma patients with gallbladder involvement underwent cholecystectomy (the type of surgical approach was not specified), achieving a 1-year survival rate of 100%. Also, in case reports describing melanoma patients with isolated gallbladder metastasis (14 patients), cholecystectomy appears to improve disease-free survival (outcomes are detailed in Table 1). Among them, 10 patients had no residual disease at the time of last follow-up [2, 6, 13–15, 17, 20, 21, 23, 25], which could go up to 60 months [14]. One other patient was operated on despite diffuse nonresectable metastatic disease (subcutaneous and pulmonary lesions considered stable after immunotherapy) and showed a stable disease 15 months after surgery [16]. Thus, of these 14 resectable stage IV melanoma patients, 11 showed a favorable outcome after surgery. Even if the surgical approach was different (4 patients had an open surgery, 6

Table 1. Summary of case reports of operated gallbladder melanoma metastasis published between 2000 and 2022

Author, year, number of cases, reference	Melanoma characteristics			Presentation		Other synchronous sites of recurrence	Indication for surgery		Type of procedure		Gallbladder regional LN pathologic status	Other treatment	Outcomes
	Time since melanoma diagnosis, months	histology	Breslow, mm	Clark	ulceration		SLN status or Stage	incidentally (imaging)	symptoms	symptoms/Cholecystitis			
Sawyer, 2022, 1, [12]	48	Nodular	0.9	II	NR	NR	X	Subcutaneous, brain	X	No	No	Ipi Nivo	NR
Jeon, 2021, 1, [2]	At Dx	Either unknown cutaneous primary or primary gastric melanoma			NA	X	None	Other: suspicion of gallbladder cancer	X	Locoregional lymphadenectomy	Neg	None	No residual disease 52 months after surgery
Bangae, 2021, 1, [7]	24	NR	NR	NR	NR	Stage IIA	X	Brain	X	No	NA	Surgery and RT on brain lesions. Nivo	No residual disease at 20 cycles of Nivo
D'Urso, 2020, 1, [15]	7	Nodular	7.6	IV	Yes	SLN neg	X	None	X	No	NA	Adjuvant Nivo	No residual disease 7 months after surgery
Hess, 2020, 1, [16]	62	NR	1.3	NR	NR	Stage IIA, then stage IV (subcutaneous and pulmonary)	X	None	X	No	NA	Pre-op Pembro	Stable disease 15 months after surgery
Di Buono, 2020, 1, [3]	6	Nodular	4	IV	Yes	SLN neg	X	None	X	Removal of suspicious LN only (surgical findings)	Neg	NR	NR
Saraswat, 2019, 1, [17]	Several years	NR	NR	NR	NR	NR	X	None	X	No	NA	Adjuvant IO	No residual disease 5 months after surgery
Patel, 2017, 1, [6]	3	Nodular	12	IV	Yes	Stage IIC	X	None	X	No	NA	None	No residual disease 6 months after surgery

Table 1 (continued)

Author, year, number of cases, reference	Time since melanoma diagnosis, months	Melanoma characteristics			SLN status or Stage	Presentation		Other synchronous sites of recurrence	Indication for surgery		Type of procedure		Gallbladder regional LN pathologic status	Other treatment	Outcomes
		histology	Breslow, mm	Clark		ulceration	incidentally (imaging)		symptoms	symptoms/Cholecystitis	resectable setting	open			
Khan, 2017, [5]	At Dx	SSM	2.71	IV	Yes	SLN neg	X	None	X	X	No	NA	NR	NR	
Hall, 2018, [18]	24	SSM	>2	NR	NR	Stage IIA	X	Distant LN, lung, liver	X	X	No	NA	Palliative care	Death within months	
Giannini, 2016, [13]	108	Nodular	7	IV	Yes	SLN neg	X	Spleen	X	X	Removal of suspicious LN only (surgical findings)	Neg	Splenectomy	Cerebral and pancreatic progression 1 month after surgery, alive 6 months after surgery	
	24	Nodular	2.5	III	NR	SLN neg	X	None	X	X	Removal of suspicious LN only (surgical findings)	Neg	Adjuvant Interferon	No residual disease 6 months after surgery	
Onozawa, 2014, [19]	At Dx	Unknown primary				Stage IV	X	Liver, lung, bone, GI, tract	X	X	No	NA	Chemotherapy (DAC+am then CVD)	Death 8 months after surgery of widespread disease	
Christou, 2014, [20]	4	Nodular	2.2	IV	Yes	SLN neg	X	None	X	X	Removal of suspicious LN only (radiological findings)	Neg	None	No residual disease 6 months after surgery	
Furumoto, 2013, [21]	18	Sinonasal cavity				NA	X	None	X	X	Locoregional lymphadenectomy	Neg	None	No residual disease 13 months after surgery	
Vernadakis, 2009, [22]	24	SSM	3.8	III	NR	NR	X	Brain	X	X	No	NA	Chemo (DTIC)	Death 5 months after surgery of widespread disease	

Table 1 (continued)

Author, year, number of cases, reference	Time since melanoma diagnosis, months	Melanoma characteristics			SLN status or Stage	Presentation		Other synchronous sites of recurrence	Indication for surgery		Type of procedure		Gallbladder regional LN pathologic status	Other treatment	Outcomes
		histology	Breslow, mm	Clark		ulceration	incidentally (imaging)		symptoms	symptoms/Cholecystitis	resectable setting	open			
Martel, 2009, 1, [23]	At Dx	Completely regressed melanocytic lesion	NA		NA	X	None	Other: suspicion of gallbladder cancer	X	No	No	NA	None	No residual disease 18 months after surgery	
Samplaski, 2008, 2, [24]	24	NR	0.7	NR	NR	X	Distant LN, subcutaneous	X	X	No	No	NA	Chemo (not specified)	Alive 36 months after surgery	
	96		1.3												
	At Dx	Unknown primary			NA	X	Axillary LN, subcutaneous	X	X	No	No	NA	Neoadjuvant chemo (not specified)	No residual disease 14 months after surgery, then Axillary LN dissection	
Tuveri, 2007, 1, [14]	12	SSM	0.82	II	NR	X	None	X	X	Locoregional lymphadenectomy	Neg	Neg	None	No residual disease 60 months after surgery	
Nelms, 2007, 1, [25]	24	NR	NR	IV	Stage IIIIC	X	None	X	X	No	No	NA	None	Alive 20 months after surgery	
Marone, 2007, 1, [26]	8	NR	6.1	IV	SLN neg	X	Abdominal LN, peritoneum	X	X	Removal of suspicious LN only (surgical findings)	Pos	Pos	None	Death 11 months after surgery of intestinal then widespread metastatic disease	

Table 1 (continued)

Author, year, number of cases, reference	Time since melanoma diagnosis, months	Melanoma characteristics			SLN status or Stage	Presentation		Other synchronous sites of recurrence	Indication for surgery		Type of procedure		Gallbladder regional LN pathologic status	Other treatment	Outcomes	
		histology	Breslow, mm	Clark		ulceration	incidentally (imaging)		symptoms	symptoms/Cholecystitis	resectable setting	open				endoscopic
Gogas, 2003, 1, [27]	21	Nodular	3	IV	NR	NR	NR	NR	X	None	X	Retrograde	No	NA	Adjuvant chemo (DTIC)	Soft tissue and brain progression 12 months after surgery
Guida, 2002, 1, [28]	45	NR	1.9	IV	Stage I	NR	NR	Gallbladder hilus LN	X	X	X	X	Locoregional lymphadenectomy (radiological findings)	Pos	None	Death few months after surgery of widespread disease

Chemo, chemotherapy; Dx, diagnosis; IO, immunotherapy; Ipi, ipilimumab; LN, lymph node; mm, millimeters; NA, not applicable; neg, negative; Nivo, nivolumab; NR, not reported; Pembro, pembrolizumab; pre-op, preoperative; RT, radiotherapy; SLN, sentinel lymph node biopsy; SSM, superficial spreading melanoma.

had a laparoscopic procedure, and 1 had an endoscopic surgery that was converted to an open procedure), it is worth mentioning that, unlike for our patient, all surgeries were carefully planned and performed with oncological precautions. Of note, only 3 of the 11 favorable post-operative outcome patients had adjuvant immunotherapy [13, 15, 17]. Pivotal randomized control trials have shown that adjuvant immunotherapy could significantly increase recurrence-free survival in resected stage IV melanoma patients [9, 10], possibly improving these already favorable outcomes post gallbladder resection. Only 1 patient did not present a favorable post-operative outcome among the 14 presenting with solitary gallbladder metastasis [27]. He probably had an open surgery (although it is not clearly mentioned) and had an unusual retrograde dissection. Finally, outcomes were not reported for 2 patients [3, 5].

There could also be a place for surgery in the diffuse metastatic context [18, 19, 22, 24, 26, 28], as cholecystectomy can prevent further dissemination via bile, relieve symptoms, and minimize the risk of biliary complications [6, 13].

Whereas there are few doubts concerning the place of surgery, to prolong survival in cases of isolated gallbladder metastasis or in otherwise stable metastatic disease, and for symptom relief purposes in widespread metastatic situations, there is no agreement regarding the optimal surgical approach to remove the metastatic melanoma gallbladder. Two types of cholecystectomy are described in this context: open surgery and endoscopic technique.

The laparoscopic approach is less morbid, as it is associated with less intraoperative blood loss, less pain and analgesic requirement, shorter length of hospital stay, and brief convalescence. Besides, fast recovery after minimally invasive procedures could allow patients to rapidly initiate adjuvant immunotherapy [7]. The major risk of this approach however is the occurrence of port-site or intra-abdominal metastases due to intraperitoneal bile spillage from the gallbladder, as in the presented case. Being initially diagnosed with acute cholecystitis, our patient underwent a laparoscopic cholecystectomy performed with no oncological precaution. Surgeons inadvertently perforated the gallbladder during its manipulation and removed it through the supra-umbilical trocar site, where 6 weeks later a metastatic deposit was detected. In general, if a metastasis is suspected based on the preoperative imaging findings, precautions such as gentle manipulation, avoidance of perforation, and use of an isolation bag for the removal of the gallbladder are practiced during surgery, but do not always prevent an intraperitoneal seeding event [2, 3]. In a small series of melanoma metastatic to the gallbladder patients [11], 2 of the 3 patients who underwent laparoscopic cholecystectomy presented port-site recurrence, despite the absence of perforation and the use of retrieval bags to remove the specimen through the trocar site. To our knowledge, our case is the third in the literature to report the occurrence of trocar implantation metastasis after laparoscopic removal of a gallbladder metastasis of melanoma.

Open surgery is associated with higher morbidity but is safer regarding the risk of trocar recurrence and enables a manual exploration of the abdominal cavity, useful to reveal bowel metastatic lesions not always identifiable by preoperative imaging examinations [15, 16, 26]. There are too few cases to recommend a certain type of surgical approach, and decision has to be made on an individual basis, based on patient's clinical status and disease extension. It seems reasonable to recommend a minimally invasive laparoscopic procedure in a palliative setting for symptom relief, whereas a fit patient presenting isolated metastasis to the gallbladder could be treated with curative (or at least life-prolonging) intent with an open cholecystectomy.

The question remains of whether to operate the regional gallbladder lymph nodes or not. Since the majority of melanoma metastases to the gallbladder are intraluminal, lymphadenectomy in the region of the hepatoduodenal ligament does not appear to be indicated

[3, 13, 26] and is in most cases not performed (as shown in Table 1). However, a regional lymphadenectomy could be considered in fit patients with large tumor or nodal involvement suspected on preoperative radiologic examinations or intraoperative findings [2].

Conclusion

Nowadays, resected stage IV melanoma patients are being treated with adjuvant immunotherapy with improved long-term outcomes, but only in cases of oncologically optimal and complete surgery. To allow such a surgery, clinicians should maintain a high level of suspicion of metastatic deposit when a patient with a current or past history of melanoma presents with biliary symptoms, and radiologists should remain aware of ultrasound doubtful findings that warrant further examinations. After considering the patient's age and general condition, this case highlights the importance of a planned and open surgery for resectable melanoma gallbladder metastasis rather than a laparoscopic approach. In case of a laparoscopic intra-abdominal procedure, we recommend not only precautions such as gentle manipulation, avoidance of perforation, and use of an isolation bag for removal of the gallbladder but also a close clinical follow-up of the trocar insertion sites, as well as abdomen imaging, to exclude the occurrence of intraperitoneal seeding or port-site metastases.

Statement of Ethics

Written informed consent was obtained from the patient for publication of the details of their medical case and any accompanying images prior to their passing away. No patient-identifying information is included in this study. This research was conducted in accordance with the World Medical Association Declaration of Helsinki. This retrospective review did not require ethical approval in accordance with local guidelines.

Conflict of Interest Statement

The authors have no conflicts of interest to declare.

Funding Sources

No funding was received.

Author Contributions

Céline Sergeant conducted the literature review and wrote the manuscript (including the table). Mireille Langouo was the patient's medical oncologist, she reviewed the manuscript. François Sales performed the resection of the primary cutaneous melanoma and reviewed the paragraphs related to surgical procedures. Annie Drowart and Joseph Kerger are melanoma-trained medical oncologists who read and approved the final version of the manuscript.

Data Availability Statement

All data generated or analyzed during this study are included in this article and its online supplementary material. Further inquiries can be directed to the corresponding author.

References

- 1 Liang KV, Sanderson SO, Nowakowski GS, Arora AS. Metastatic malignant melanoma of the gastrointestinal tract. *Mayo Clin Proc.* 2006 Apr;81(4):511–6.
- 2 Jeon HJ, Kwon HJ, Kim SG, Hwang YJ. Malignant melanoma of the gallbladder: a case report and literature review. *Ann Hepatobiliary Pancreat Surg.* 2021 Aug;25(3):445–9.
- 3 Di Buono G, Maienza E, Rinaldi G, Buscemi S, Romano G, Agrusa A. Malignant metastatic melanoma to the gallbladder: report of a peculiar case. *Int J Surg Case Rep.* 2020 Sep;77S(Suppl):S37–9.
- 4 Meyer JE. Radiographic evaluation of metastatic melanoma. *Cancer.* 1978 Jul;42(1):127–32.
- 5 Khan A, Patel S, Zaccarini DJ, McGrath M. Metastatic melanoma of the gallbladder in an asymptomatic patient. *Case Rep Gastrointest Med.* 2017;2017:1767418.
- 6 Patel D, Sohrawardy S, Sedhai YR, Basnyat S, Daxini A, Basu A, et al. Metastatic cutaneous melanoma of the gallbladder. *Case Rep Gastrointest Med.* 2017;2017:8532379.
- 7 Bangeas PI, Bekiaridou A, Tsolakidis A, Efthymiadis KG, Drevelegkas K, Giakoustidis D, et al. Role of minimally invasive surgery in the treatment of gallbladder metastatic melanoma. A review of the literature and a case report. *Cancer Rep.* 2022 Jul;5(7):e1549.
- 8 Nelson DW, Fischer TD, Graff-Baker AN, Dehal A, Stern S, Bilchik AJ, et al. Impact of effective systemic therapy on metastasectomy in stage IV melanoma: a matched-pair analysis. *Ann Surg Oncol.* 2019 Dec;26(13):4610–8.
- 9 Zimmer L, Livingstone E, Hassel JC, Fluck M, Eigentler T, Loquai C, et al. Adjuvant nivolumab plus ipilimumab or nivolumab monotherapy versus placebo in patients with resected stage IV melanoma with no evidence of disease (IMMUNED): a randomised, double-blind, placebo-controlled, phase 2 trial. *Lancet.* 2020 May;395(10236):1558–68.
- 10 Ascierto PA, Del Vecchio M, Mandalá M, Gogas H, Arance AM, Dalle S, et al. Adjuvant nivolumab versus ipilimumab in resected stage IIIB–C and stage IV melanoma (CheckMate 238): 4-year results from a multicentre, double-blind, randomised, controlled, phase 3 trial. *Lancet Oncol.* 2020 Nov;21(11):1465–77.
- 11 Katz SC, Bowne WB, Wolchok JD, Busam KJ, Jaques DP, Coit DG. Surgical management of melanoma of the gallbladder: a report of 13 cases and review of the literature. *Am J Surg.* 2007 Apr;193(4):493–7.
- 12 Sawyer E, Tran K, Kalpakos L, Ratnayake S. Metastatic melanoma of the gallbladder in a patient with acute cholecystitis: a case report and review of the literature. *Int Surg J.* 2022 Feb;9(3):664–70.
- 13 Giannini I, Cutrignelli DA, Resta L, Gentile A, Vincenti L. Metastatic melanoma of the gallbladder: report of two cases and a review of the literature. *Clin Exp Med.* 2016 Aug;16(3):295–300.
- 14 Tuveri M, Tuveri A. Isolated metastatic melanoma to the gallbladder: is laparoscopic cholecystectomy indicated?: a case report and review of the literature. *Surg Laparosc Endosc Percutan Tech.* 2007 Apr;17(2):141–4.
- 15 D'Urso Vilar GG, Iriarte F, Speisky D, Bregante ML, Quidrian SD. Isolated gallbladder metastasis of melanoma: case report. *Int J Surg Case Rep.* 2020 May;71:311–4.
- 16 Hess GF, Glatz K, Rothschild SI, Kollmar O, Soysal SD, Boll DT, et al. Malignant melanoma metastasis in the gallbladder. A case report of an unusual metastatic site. *Int J Surg Case Rep.* 2020 Sep;75:372–5.
- 17 Saraswat NB, DeVoe WB. Metastatic melanoma of the gallbladder presenting as polyp in acute cholecystitis. *J Surg Case Rep.* 2019;2019(12):rjz324.
- 18 Hall N, Grenier NL, Shah SA, Gold R, Feller E. Metastatic gallbladder melanoma presenting as acute emphysematous cholecystitis. *Case Rep Med.* 2018;2018:5726570.
- 19 Onozawa H, Saito M, Yoshida S, Sakuma T, Matsuzaki M, Katagata N, et al. Multiple metastatic malignant melanoma presenting intraluminal gallbladder bleeding. *Int Surg.* 2014 Sept;99(5):600–5.
- 20 Christou D, Katodritis N, Decatris MP, Katodritou A, Michaelides I, Nicolaou N, et al. Melanoma of the gallbladder: appropriate surgical management and review of the literature. *Clin Case Rep.* 2014 Dec;2(6):313–8.
- 21 Furumoto K, Miyauchi Y, Ito D, Kitai T, Kogire M. Solitary metastatic gallbladder malignant melanoma originated from the nasal cavity: a case report. *Int J Surg Case Rep.* 2013 Aug;4(11):965–8.
- 22 Vernadakis S, Rallis G, Danias N, Serafimidis C, Christodoulou E, Troullinakis M, et al. Metastatic melanoma of the gallbladder: an unusual clinical presentation of acute cholecystitis. *World J Gastroenterol.* 2009 Jul;15(27):3434–6.
- 23 Martel JPA, McLean CA, Rankin RN. Melanoma of the gallbladder. *Radiographics.* 2009 Jan;29(1):291–6.
- 24 Samplaski MK, Rosato EL, Witkiewicz AK, Mastrangelo MJ, Berger AC. Malignant melanoma of the gallbladder: a report of two cases and review of the literature. *J Gastrointest Surg.* 2008 Jun;12(6):1123–6.
- 25 Nelms JK, Patel JA, Atkinson DP, Raves JJ. Metastatic malignant melanoma of the gallbladder presenting as biliary colic: a case report and review of literature. *Am Surg.* 2007 Aug;73(8):833–5.

- 26 Marone U, Caracò C, Losito S, Daponte A, Chiofalo MG, Mori S, et al. Laparoscopic cholecystectomy for melanoma metastatic to the gallbladder: is it an adequate surgical procedure? Report of a case and review of the literature. *World J Surg Oncol*. 2007 Dec;5(1):141–7.
- 27 Gogas J, Mantas D, Gogas H, Kouskos E, Markopoulos C, Vgenopoulou S. Metastatic melanoma in the gallbladder: report of a case. *Surg Today*. 2003 Feb;33(2):135–7.
- 28 Guida M, Cramarossa A, Gentile A, Benvestito S, De Fazio M, Sanbiasi D, et al. Metastatic malignant melanoma of the gallbladder: a case report and review of the literature. *Melanoma Res*. 2002;12(6):619–25.
- 29 Dong XD, DeMatos P, Prieto VG, Seigler HF. Melanoma of the gallbladder: a review of cases seen at Duke University Medical Center. *Cancer*. 1999 Jan;85(1):32–9.
- 30 Jones MW, Kashyap S, Ferguson T. Gallbladder imaging [updated 2022 Sep 19]. *StatPearls [Internet]*. Available from: <https://www.ncbi.nlm.nih.gov/books/NBK470366/>.
- 31 Oppenheimer DC, Rubens DJ. Sonography of acute cholecystitis and its mimics. *Radiol Clin North Am*. 2019 May;57(3):535–48.
- 32 Cocco G, Delli Pizzi A, Basilico R, Fabiani S, Taraschi AL, Pascucci L, et al. Imaging of gallbladder metastasis. *Insights Imaging*. 2021;12(1):100.