

# Postoperative Swallowing Function in Patients with Deep Neck Infection

Shohei Ashizawa<sup>a</sup> Takuma Hisaoka<sup>a</sup> Ryoukichi Ikeda<sup>b</sup> Rina Kamihata<sup>a</sup>  
Jun Suzuki<sup>a</sup> Ai Hirano-Kawamoto<sup>a</sup> Jun Ohta<sup>a</sup> Yukio Katori<sup>a</sup>

<sup>a</sup>Department of Otolaryngology and Head and Neck Surgery, Tohoku University Graduate School of Medicine, Sendai, Japan; <sup>b</sup>Department of Otolaryngology and Head and Neck Surgery, Iwate Medical University School of Medicine, Morioka, Japan

## Keywords

Computed tomography · Functional Oral Intake Scale · Inflammation · Anterior cervical space · Dysphagia

## Abstract

**Introduction:** Early detection of dysphagia risk, initiating rehabilitation, and resumption of appropriate diet based on swallowing function is important during deep neck infection (DNI) control. This study aimed to evaluate the extent of cervical abscess development, particularly in the deep neck space, and its relationship to postoperative swallowing function. **Methods:** A retrospective chart review was performed for all DNI cases treated between April 2015 and April 2021. Deep neck spaces were divided into categories based on computed tomography findings. Functional Oral Intake Scale (FOIS) scores of 4 or higher was defined as normal or slight swallowing disorder and 3 or lower as dysphagia. **Results:** Seventeen cases were included in the analysis. Based on FOIS, 14 cases were classified into the dysphagia group at 2 weeks after surgery, 11 cases at 4 weeks, and 8 cases at 8 weeks. There was no significant difference between the location of the abscess and dysphagia at 2 weeks after surgery. Patients with anterior cervical space abscess significantly increased dysphagia 4 weeks ( $p = 0.018$ ) and 8 weeks ( $p = 0.036$ ) after surgery. **Conclusion:** Abscess formation in the anterior cervical space

may be associated with prolonged dysphagia after treatment due to inflammation and scarring of the muscles associated with swallowing.

© 2023 The Author(s).  
Published by S. Karger AG, Basel

## Introduction

Deep neck infection (DNI) occurs in the potential spaces in the cervical fascial planes of head and neck lesions [1, 2]. Since these infections are potentially fatal due to loss of airway patency, spread of infection, development of necrotizing fasciitis, and sepsis, it is essential to detect and treat them promptly [3, 4]. The proper diagnosis of DNIs first depends on identifying the correct anatomical location. This will provide clues to the disease origin, determine which structures are at risk, and guide treatment. By understanding which deep neck spaces are involved and how they interact, a more accurate assessment of potential etiology, clinical risk, and appropriate treatment can be formulated [5]. DNI treatment includes life-supporting measures, surgical drainage, and appropriate use of antibiotics. It is also known that prolonged delays in resuming oral intake can cause progressive fibrosis of swallowing-related muscles and result in impair swallowing function [6]. Therefore, early detection of dysphagia risk, combined with proper

swallowing function, rehabilitation training is important to recovery during infection treatment. For that purpose, the index to predict dysphagia before surgery or in the early postoperative period is necessary. However, there have been no reports on the detailed relationship between the extent of DNI and dysphagia. This study will focus on the extent of cervical abscess development, particularly in the deep neck space, and its relationship to postoperative swallowing function.

## Materials and Methods

### Patient Selection

A retrospective case series was conducted in accordance with the Helsinki Declaration and was approved by the Tohoku University Hospital Institutional Review Board (IRB) (Reference number: 2014-1-274). A retrospective chart review was performed for all DNI cases treated between April 2015 and April 2021. Inclusion criteria would be a person that could be followed, at least, for 8 weeks in review chart. Exclusion criteria would be a person that be diagnosed at our hospital but were treated at other facilities. Seventeen patients (12 males and 5 female subjects, median age 69 [62–80] years old) were included our study. Diagnosis of DNI is based on clinical and radiological findings. Surgery was indicated after failure of clinical treatment (antibiotic therapy only) and airway impairment caused by infection.

### Assessment of Swallowing Function

We used the Functional Oral Intake Scale (FOIS) to assess oral intake status. Since the timing of the videofluorographic swallowing study (VFSS) and the flexible endoscopic evaluation of swallowing were different for each case, it was not possible to compare the results at the same time. The FOIS scores were generated for patients with available data at 1, 2, 4, and 8 weeks after surgery. The FOIS was initially developed and validated to estimate and document changes in the functional eating abilities of stroke patients over time [7]. However, the FOIS has been published in various research settings for other patients with head and neck lesion disease-experiencing dysphagia [8]. The FOIS is a seven-point scale of oral dietary tolerance, which categorizes patients into 7 levels: (1) no oral intake, (2) tube-dependent with minimal oral intake, (3) oral intake with tube supplementation, (4) total oral intake with only 1 consistency of food, (5) total oral intake with multiple consistencies but with special preparation, (6) total oral intake with avoidance of specific foods or drinks, (7) total oral intake with no restrictions [7]. In this study, the patients were divided into two groups: those on tube feeding and those on oral intake only. In other words, an FOIS score of 4 or higher was defined as normal or slight swallowing disorder and 3 or lower as having dysphagia.

The VFSS were performed as follows. Three and five milliliters of diluted barium were given to the patients to swallow. The same tests were then conducted using standardized rice, yogurt, puddings, rice porridge, and other items with standardized viscosity and quality. The entire investigation was documented using AVI files (30 frames per second).

### Deep Neck Spaces

Figure 1 shows deep neck spaces were divided into the following categories based on computed tomography (CT) findings and previous literature [5, 9]: masticator space, parotid space, submandibular space, sublingual space, parapharyngeal space, anterior cervical space, visceral space, carotid space, retropharyngeal space, prevertebral space, and mediastinal space. In the subject patients, the extent of deep fascial neck spaces affected by infection was defined by CT and surgical findings (the presence of pus at the surgery). Two physiatrists analyzed the CT images. Conclusions were drawn by consensus.

### Statistical Analysis

Fisher's exact test and Mann-Whitney's *U* test were performed using the statistical software SPSS version 27 (IBM, Chicago, IL, USA). Differences with a corrected *p* value of less than 0.05 were considered significant.

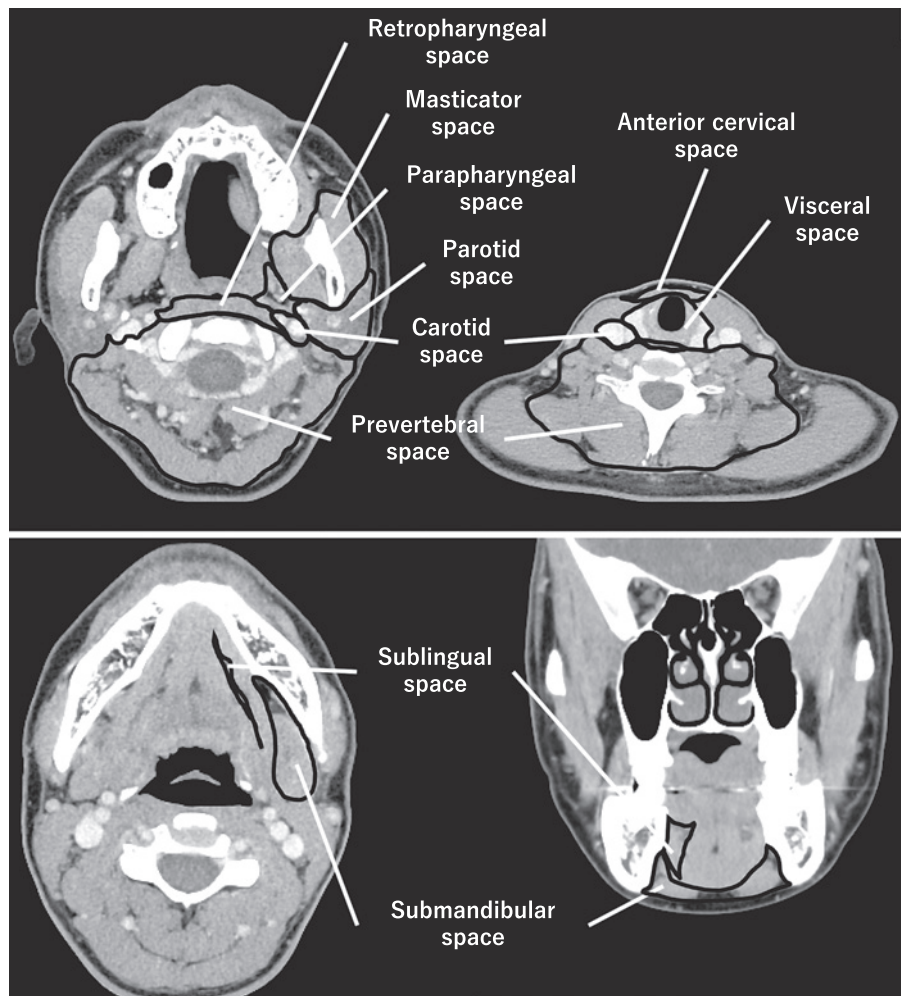
## Results

### Patients' Characteristics

Table 1 shows the patients' characteristics. The median age was 69 (62–80) years old. There were 12 (70.6%) males and 5 (29.4%) females. Eight patients (47.1%) had diabetes. The average number of operations was 1.4, and 15 patients (88.2%) underwent tracheostomy. All case was performed cervicectomy drainage. Of the 8 patients with mediastinal abscesses, 4 cases underwent thoracoscopic drainage and the remaining 4 cases underwent thoracotomy drainage. Retropharyngeal abscess (4 cases) and decay (3 cases) were major sources of infection. The source of infection could not be identified in 4 cases. The intensive care after surgery and the extent of abscess development in the CT images of each patient are shown in Table 1.

### FOIS Score after DNI Surgery

Chronological changes of FOIS scores of all patients are described in Table 2. Table 3 shows the patients' characteristics between the normal or slight swallowing disorder and dysphagia group at 8 weeks after surgery. The dysphagia group had more cases of abscesses spreading to the anterior cervical space ( $p = 0.036$ ). The median time of stay in the intensive care unit was 13.5 days in the dysphagia group and 0 days in the normal or slight swallowing disorder group and was significantly longer in the dysphagia group ( $p = 0.02$ ). The mean time to resumption of oral intake was significantly longer in the dysphagia group, 74 days in the dysphagia group and 28 days in the normal or slight swallowing disorder group ( $p = 0.001$ ). Compared to the normal or slight swallowing disorder group,



**Fig. 1.** Deep neck spaces in the CT image: masticator space, parotid space, submandibular space, sublingual space, parapharyngeal space, anterior cervical space, visceral space, carotid space, retropharyngeal space, prevertebral space, and mediastinal space.

hospital stay was significantly longer in the dysphagia group ( $p = 0.02$ ). More patients were transferred to the hospital ( $p = 0.043$ ), and conversely, fewer patients were discharged home in the dysphagia group ( $p = 0.043$ ).

#### *Videofluorographic Swallowing Study Analysis*

The VFSS were performed in 8 patients with abscesses developing in the anterior cervical region. Six of the eight patients had poor laryngeal elevation (see online supplementary video at <https://doi.org/10.1159/000533526>).

#### **Discussion**

This study revealed that abscess formation in the anterior cervical space of the larynx might lead to prolonged postoperative dysphagia. The deep cervical fascia consists of the superficial, middle, and deep layers. The

anterior cervical space lies between the superficial layer and the middle layer. It is surrounded by strap muscles, sternocleidomastoid muscle, visceral space, and carotid sheath [10]. The anterior cervical space is anatomically continuous and inferior to the anterior compartment of the mediastinum.

Adovica et al. [11] reviewed 263 cases of DNIs. The submandibular space was the most common space for abscess formation (36.3%), followed by the pterygomandibular space (included in the masticatory muscle space in our study) (14.1%), the parapharyngeal space (6.49%), and the postpharyngeal space (4.2%). However, since dental infections accounted for 70.6% of deep cervical infections in their study, many cases likely resulted in abscess formation in the mandibular space adjacent to the teeth. The mean age of the patients was 44 years, which is younger than that of patients in our study. As pharyngitis and tonsillitis are more common causes of abscess formation in the elderly as described by Adovica

**Table 1.** Characteristics of study patients with DNI

	Median (interquartile range)	Cases, <i>n</i> (%)
Cases, <i>n</i>		17
Age, years	69 (62–80)	
Sex		
Male		12 (70.6)
Female		5 (29.4)
Etiology of neck infection		
Retropharyngeal abscess		4 (23.5)
Decay		3 (17.6)
Peritonsillar abscess		2 (11.8)
Acute epiglottitis		2 (11.8)
Mandibular osteomyelitis		1 (5.9)
Foreign body		1 (5.9)
Unclear		4 (23.5)
Diabetes		8 (47.1)
Number of operations	1 (1–2)	
Tracheostomy		15 (88.2)
Cervicectomy drainage		17 (100)
Thoracoscopic mediastinal drainage		4 (23.5)
Thoracotomy drainage		4 (23.5)
Intensive care, days	5 (0–17)	
Vasoactive drugs		4 (23.5)
Ventilation supportive care, days	2 (0–5)	
Rehabilitation		13 (76.5)
Extent of abscess development		
Masticator space		5 (29.4)
Parotid space		5 (29.4)
Submandibular space		9 (52.9)
Sublingual space		0 (0.0)
Parapharyngeal space		9 (52.9)
Anterior cervical space		10 (58.8)
Visceral space		10 (58.8)
Carotid space		8 (47.1)
Retropharyngeal space		12 (70.6)
Prevertebral space		2 (11.8)
Mediastinal space		8 (47.1)
Number of deep neck spaces	4 (4–7)	
FOIS		
2 W	1 (1–2)	
4 W	2 (1–6)	
8 W	5 (1–7)	
Outcomes		
Time to oral intake, days	35 (35–50)	
Mortality		0 (0)
Hospital stay, days	53 (40–110)	
The other hospital		6 (35.3)
Home		11 (64.7)

et al. [11], it would explain the high incidence of abscess formation in the parapharyngeal and retropharyngeal spaces in our study.

Most mediastinum abscesses progress from the anterior cervical space and is therefore important in mediastinal extension of pharyngeal abscesses [12]. The extent of the infections as the number of spaces is also

considered as importance for swallowing function. In this study, no meaningful results such as FOIS and outcomes were found for the number of deep neck spaces.

Tracheostomy can affect aspiration pneumonia and mortality in patients with dysphagia [13, 14]. There was no significant difference between patients with and those without tracheostomy in our study. DNI is a severe disease

**Table 2.** Time course in FOIS score

Patient No.	1 W	2 W	4 W	8 W
1	1	1	1	1
2	1	1	1	1
3	1	1	1	1
4	1	1	1	1
5	1	1	1	1
6	1	1	1	2
7	1	1	1	3
8	1	1	2	3
9	2	2	3	5
10	1	4	4	6
11	1	1	6	6
12	1	2	6	6
13	1	1	1	7
14	1	1	2	7
15	1	3	7	7
16	1	6	7	7
17	6	7	7	7

W, week(s).

that can lead to airway obstruction. Tracheostomy is recommended for older patients ( $\geq 65$  years old), when multiple spaces are involved ( $\geq 3$  spaces), or when mediastinitis is present [15]. Most of the cases met these conditions, and tracheostomy was performed in 15 of 17 cases. Because of the small number of cases in which a tracheostomy was not performed, it was not possible to evaluate the effect of tracheostomy in this study. Our group has previously reported that descending necrotizing mediastinitis and/or DNI patients' extension of infections below the hyoid bone and tracheostomy were significantly associated with delayed oral dietary intake [16].

Laryngeal movement during swallowing is caused by the action of the suprahyoid and extrinsic laryngeal muscles. The geniohyoid and thyrohyoid muscles play a predominant role [17]. In our study, most of the patients with abscesses developing in the anterior cervical region had poor laryngeal elevation. It is presumed that the anterior cervical space abscess causes inflammation that spreads to the muscles around the hyoid bone, centering on the thyrohyoid muscle, and suppressing muscle activity and laryngeal elevation. Yamano et al. [17] reported three cases of dysphagia after treating a DNI. All 3 patients showed evidence of a laryngeal disorder in videofluorography swallowing study due to scar contracture [17]. The delay in anterior laryngeal movements causes a delay in the pressure fall at the upper esophageal sphincter (UES) and resistance to bolus entry into the UES [18]. Aging prolonged the onset of laryngeal elevation. In this study, delayed laryngeal elevation may lead to difficult transport the bolus to the esophagus, resulting in dysphagia.

Although it has been reported that resumption of oral intake is delayed in patients with descending necrotizing mediastinitis, there was no significant difference in FOIS for each period between patients with and those without mediastinal abscess in this study [13]. Thoracoscopic or thoracotomy drainage also did not affect FOIS in our study. The number of cases in this study was small, and this may have prevented a significant difference between the two groups.

There are a few case reports of dysphagia in cervical abscesses. A patient who suffered perilaryngeal and mediastinal abscess involving the anterior neck space required 6 months of a comprehensive rehabilitation to improve swallowing function [15]. The CT revealed that the abscess had spread to the submandibular, submental, parapharyngeal, paratracheal, and mediastinum spaces. The patient continued to have dysphagia after completion of treatment, and VFSS showed impairment in the pharyngeal phase. In addition, there was a similar case report in which swallowing function did not be improved with rehabilitation, and laryngeal elevation and cricopharyngeal myotomy were performed, resulting in improvement of the pharyngeal swallowing stage [18]. The CT showed abscess formation, including emphysema in the retropharyngeal, paratracheal, paraesophageal, perilaryngeal, submandibular, both carotid spaces, and the upper mediastinum. Two surgeries were performed, and the tracheal cannula and drains were removed 24 days after surgery, but VFSS revealed poor laryngeal elevation, inadequate UES opening, residue in the pharyngeal cavity, aspiration, and poor pharyngeal constrictor function. These case reports seemed to support the findings of this study that abscess formation in the anterior laryngeal space may lead to prolonged dysphagia.

In laryngeal elevation surgery, a hole is drilled in the thyroid cartilage and mandible, and a thread or tape is passed through the hole to raise the larynx forward and upward. It can strengthen the laryngeal closure and open the esophageal entrance. The cricopharyngeal myotomy relaxes the esophageal inlet and reduces the resistance to esophageal inflow. These techniques improve the pharyngeal phase of swallowing and are particularly useful in cases of deep cervical abscess with inadequate opening of the esophageal inlet due to inflammatory scarring.

### Limitations

The number of cases in this study was small, and it is necessary to examine more cases in the future. In addition, for the 10 patients with abscess formation in the

**Table 3.** Patient characteristics between the normal (FOIS  $\geq 4$ ) and dysphagia (FOIS  $\leq 3$ ) group at 2, 4, and 8 weeks postoperatively

	FOIS $\leq 3$	FOIS $\geq 4$	
Cases, <i>n</i>	8	9	
Age, years	73.5 (64.3–83.3)	69 (56–71)	0.321
Sex, <i>n</i> (%)			
Male	5 (62.5)	7 (66.7)	0.437
Female	3 (37.5)	2 (33.3)	
Diabetes, <i>n</i> (%)	3 (37.5)	5 (55.6)	0.399
Number of operations	2 (1–2)	1 (1–1)	0.074
Tracheostomy, <i>n</i> (%)	8 (100)	7 (77.8)	0.265
Thoracoscopic mediastinal drainage, <i>n</i> (%)	3 (37.5)	1 (11.1)	0.24
Thoracotomy drainage, <i>n</i> (%)	2 (25)	2 (22.2)	0.90
Rehabilitation, <i>n</i> (%)	7 (87.5)	6 (66.7)	0.335
Extent of abscess development, <i>n</i> (%)			
Masticator space	3 (37.5)	2 (22.2)	0.437
Parotid space	4 (50.0)	1 (11.1)	0.111
Submandibular space	5 (62.5)	4 (44.4)	0.399
Sublingual space	0 (0.0)	0 (0.0)	
Parapharyngeal space	5 (62.5)	4 (44.4)	0.399
Anterior cervical space	7 (87.5)	3 (33.3)	0.036*
Visceral space	6 (75.0)	4 (44.4)	0.218
Carotid space	5 (62.5)	3 (33.3)	0.238
Retropharyngeal space	5 (62.5)	7 (77.8)	0.437
Prevertebral space	2 (25.0)	0 (0)	0.206
Mediastinal space	5 (62.5)	3 (33.3)	0.238
Number of deep neck spaces	5.5 (3.5–9)	2 (1–6)	0.114
FOIS			
2 W	1 (1–1)	2 (1–4)	0.021*
4 W	1 (1–1)	6 (3–7)	0.002*
8 W	1 (1–2.3)	7 (6–7)	<0.001*
Intensive care, days	8 (4.5–21.5)	0 (0–7)	0.15
Vasoactive drugs, <i>n</i> (%)	3 (37.5)	1 (11.1)	0.24
Ventilation supportive care, days	2 (1.75–9.75)	0 (0–3)	0.19
Outcomes			
Time to oral intake	74 (52–78)	28 (17–32)	0.001*
Mortality, <i>n</i> (%)	0 (0.0)	0 (0.0)	
Hospital stays, days	112.5 (94.5–196)	40 (22–48)	0.02*
The other hospital, <i>n</i> (%)	5 (62.5)	1 (11.1)	0.043*
Home, <i>n</i> (%)	3 (37.5)	8 (88.9)	0.043*

FOIS, Functional Oral Intake Scale. \* $p < 0.05$ .

anterior cervical space, 2 patients developed cerebral infarction during the study, which may have influenced the analysis results.

In this study, the timing and number of videofluorographic swallowing study and flexible endoscopic evaluation of swallowing performed on each patient were not uniform, and the main assessment of swallowing function was dependent on FOIS. It would be desirable to perform swallowing function tests at predetermined times for further study.

## Conclusion

It was suggested that abscess formation in the anterior cervical space might lead to prolonged dysphagia after treatment due to inflammation and scarring of the muscles associated with swallowing. Early assessment of swallowing function and initiation of rehabilitation may be desirable in patients with anticipated prolonged dysphagia.

## Statement of Ethics

This study was approved by the Tohoku University Hospital Institutional Review Board (IRB protocol number: 2014–1-274), and the requirement for informed patient consent was waived.

## Conflict of Interest Statement

The authors declare no financial relationships or conflict of interest.

## Funding Sources

This work was supported by the Takeda Science Foundation.

## References

- 1 Bakir S, Tanriverdi MH, Gun R, Yorgancilar AE, Yildirim M, Tekbaş G, et al. Deep neck space infections: a retrospective review of 173 cases. *Am J Otolaryngol*. 2012 Jan–Feb;33(1):56–63.
- 2 O'Brien KJ, Snapp KR, Dugan AJ, Westgate PM, Gupta N. Risk factors affecting length of stay in patients with deep neck space infection. *Laryngoscope*. 2020 Sep;130(9):2133–7.
- 3 Uwa N, Terada T, Saeki N, Sagawa K, Ogino K, Sakagami M. Clinical features of 5 patients with descending necrotizing mediastinitis originating from deep neck infection. *Auris Nasus Larynx*. 2010 Aug;37(4):530–4.
- 4 Ishinaga H, Otsu K, Sakaida H, Miyamura T, Nakamura S, Kitano M, et al. Descending necrotizing mediastinitis from deep neck infection. *Eur Arch Otorhinolaryngol*. 2013 Mar;270(4):1463–6.
- 5 Hansen BW, Ryndin S, Mullen KM. Infections of deep neck spaces. *Semin Ultrasound CT MR*. 2020 Feb;41(1):74–84.
- 6 Maeda K, Koga T, Akagi J. Tentative nil per os leads to poor outcomes in older adults with aspiration pneumonia. *Clin Nutr*. 2016 Oct;35(5):1147–52.
- 7 Crary MA, Mann GD, Groher ME. Initial psychometric assessment of a functional oral intake scale for dysphagia in stroke patients.

- Arch Phys Med Rehabil*. 2005 Aug;86(8):1516–20.
- 8 Kalavrezos N, Cotrufo S, Govender R, Rogers P, Pargousis P, Balasundram S, et al. Factors affecting swallow outcome following treatment for advanced oral and oropharyngeal malignancies. *Head Neck*. 2014 Jan;36(1):47–54.
- 9 Guidera AK, Dawes PJ, Fong A, Stringer MD. Head and neck fascia and compartments: no space for spaces. *Head Neck*. 2014 Jul;36(7):1058–68.
- 10 Smoker WR, Harnsberger HR. Differential diagnosis of head and neck lesions based on their space of origin. 2. The infrahyoid portion of the neck. *AJR Am J Roentgenol*. 1991 Jul;157(1):155–9.
- 11 Adoviča A, Veidere L, Ronis M, Sumeraga G. Deep neck infections: review of 263 cases. *Otolaryngol Pol*. 2017 Oct 30;71(5):37–42.
- 12 Ojiri H, Tada S, Ujita M, Ariizumi M, Ishii C, Mizunuma K, et al. Infrahyoid spread of deep neck abscess: anatomical consideration. *Eur Radiol*. 1998;8(6):955–9.
- 13 Hidaka H, Tarasawa K, Fujimori K, Obara T, Fushimi K, Sakagami T, et al. Identification of risk factors for mortality and delayed oral dietary intake in patients with open drainage

## Author Contributions

Shohei Ashizawa and Ryoukichi Ikeda contributed to the design and implementation of the research, to the analysis of the results, and to the writing of the manuscript. Takuma Hisaoka and Rina Kamihata contributed to the analysis of the results. Jun Suzuki, Ai Hirano-Kawamoto, Jun Ohta, and Yukio Katori contributed amendments to the manuscript and revised it critically. Shohei Ashizawa, Takuma Hisaoka, Ryoukichi Ikeda, Rina Kamihata, Jun Suzuki, Ai Hirano-Kawamoto, Jun Ohta, Yukio Katori approved the final version of the manuscript to be published.

## Data Availability Statement

Data are not publicly available due to ethical reasons. Further inquiries can be directed to the corresponding author.

- due to deep neck infections: nationwide study using a Japanese inpatient database. *Head Neck*. 2021 Jul;43(7):2002–12.
- 14 Suzuki J, Ikeda R, Kato K, Kakuta R, Kobayashi Y, Ohkoshi A, et al. Characteristics of aspiration pneumonia patients in acute care hospitals: a multicenter, retrospective survey in Northern Japan. *PLoS One*. 2021;16(7):e0254261.
- 15 Glen P, Morrison J. Diffuse descending necrotizing mediastinitis and pleural empyema secondary to acute odontogenic infection resulting in severe dysphagia. *BMJ Case Rep*. 2016 Mar 24:2016.
- 16 Hidaka H, Ozawa D, Kuriyama S, Obara T, Nakano T, Kakuta R, et al. Risk factors for delayed oral dietary intake in patients with deep neck infections including descending necrotizing mediastinitis. *Eur Arch Otorhinolaryngol*. 2017 Nov;274(11):3951–8.
- 17 Yamano T, Miuyagi M, Higuchi H, Ichikawa D, Murakami T, Fukaura J, et al. Dysphagia after treatment for deep neck infection. *De-glutition*. 2012;1(2):342–8.
- 18 Fujiwara K, Koyama S, Fukuhara T, Takeuchi H. Successful surgical treatment for dysphagia secondary to descending necrotizing mediastinitis. *Yonago Acta Med*. 2019 Sep;62(3):253–7.