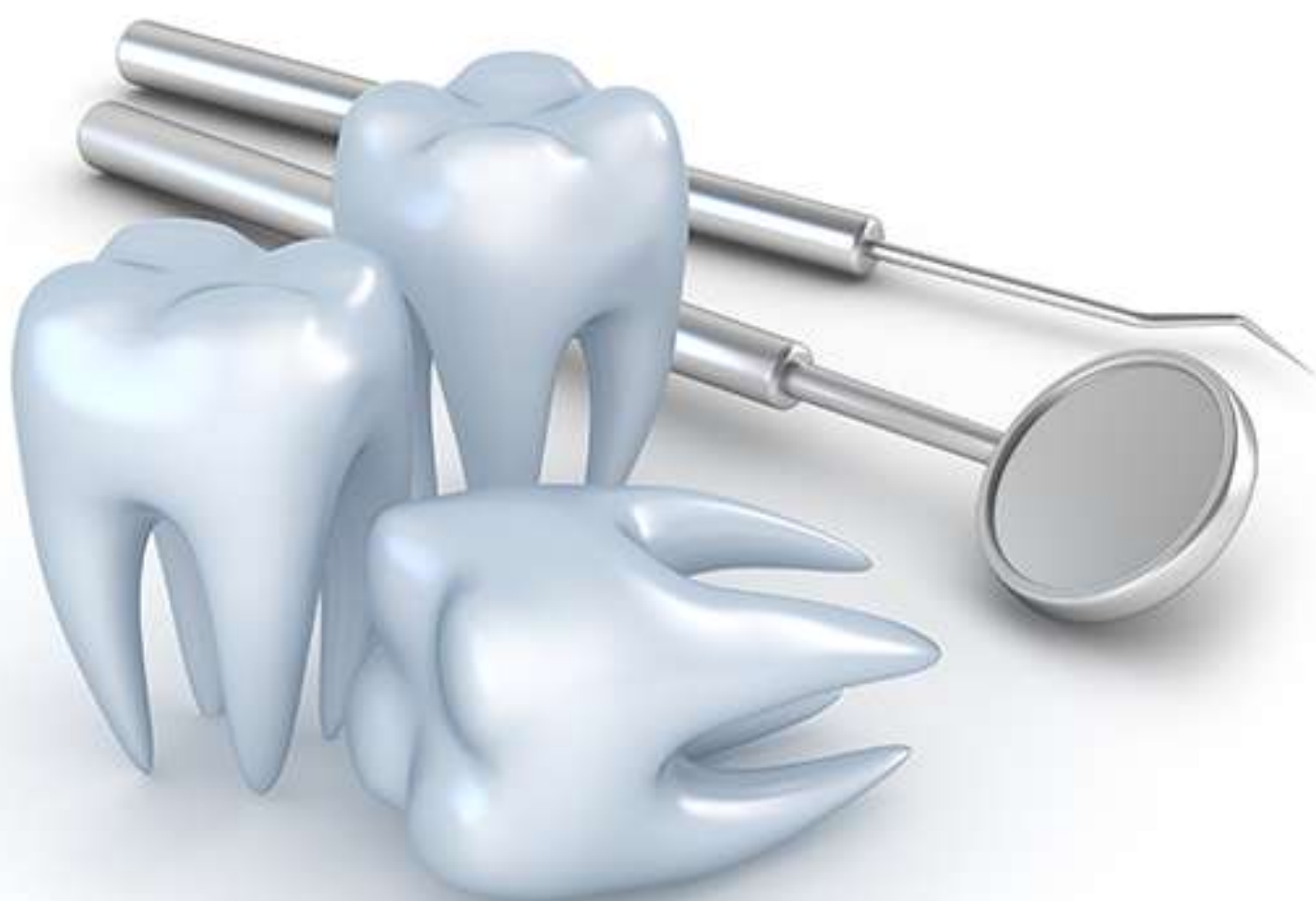

Acta Scientific  
**Dental Sciences**

(ISSN: 2581-4893)

Impact Factor: 1.278



**ACTA SCIENTIFIC**  
International Open Library



(index.php)

Home (index.php)

About Us (international-open-library.php)

Journals (journals.php)

Guidelines ▾

Join as ▾

Membership (membership.php)

Peer Review System (peerreview.php)

Article Submission (submission.php)

Testimonials

+91 9154870046 (tel:9154870046)

## ACTA SCIENTIFIC DENTAL SCIENCES EDITORIAL BOARD

### Editor-in-Chief



Prof. Amit Nagar  
Department of Orthodontics  
K.Gs' Medical University  
India



Prof. Dharam M. Hinduja  
Department of Conservative Dentistry and Endodontics  
SJM Dental College and Hospital  
India



Prof. Moustafa Nabil Aboushelib  
Department of Dental Biomaterials  
Alexandria University  
Egypt



Prof. Adel Ekladios (ASDS/Editor\_in\_Chief\_Ekladios.php)

Department of Medicine

Bunbury Hospital in Western Australia

Australia

Biodata

(ASDS/Editor\_in\_Chief\_Ekladios.php)

Testimonials

## Deputy Editor in Chief



Prof. Jayachandra M.G.

Department of Public Health Dentistry

S.J.M.Dental College and Hospital

India



Prof. Yash Kapadia.

Department of Rehabilitative and Reconstructive Dentistry

University of Louisville School of Dentistry


USA

## Advisory Board Members

Dr. Sonu Acharya	Professor	Department of Pediatric Dentistry	SOA University	India	<a href="#">View</a>
Dr. Kursat ER	Professor	Department of Endodontics	Akdeniz University	Turkey	<a href="#">View</a>
Dr. Adnan Catovic	Professor	Department of Fixed Prosthodontics and Geriatric Dentistry	School of Dental Medicine University of Zagreb	Croatia	<a href="#">View</a>
Dr. Hamit Serdar Cotert	Professor	Department of Prosthodontics	Ege University	Turkey	<a href="#">View</a>

Dr. Amrita Pandita Bhatia	Professor and HOD	Department of Prosthodontics	YCM and RDF Dental College and Hospital Ahmednagar	India	<a href="#">View</a>
Dr. Bruno Nikolovski in the panel	Associate Professor	Department of Oral and Maxillofacial Surgery	Goce Delcev University, Stip	North Macedonia	<a href="#">View</a>
Dr. Sowmya Gujjar Vishnu Rao	Professor	Department of Oral Medicine & Radiology	Bareilly International University, Institute of Dental Sciences	India	<a href="#">View</a>
Dr. Marija S. Milic	Assistant Professor	Department of General and Oral Physiology	University of Belgrade School of Dental Medicine	Serbia	<a href="#">View</a>

### Contact us

 **+91 9154870047**

**(<https://wa.me/9154870047>)**

### Journal Menu

ASDS Home

(../ASDS.php)

Editorial Board (../ASDS-

EB.php)

Review Board (../ASDS-

RB.php)

Current Issue (../ASDS-7-

10.php)

Articles in Press (../ASDS-

Article-Inpress.php)

Archive (../ASDS-

Archive.php)

Special Issue Archive

(../ASDS-

Leave a message 

Specialissue_Archive.php)
Cover Letter (../CoverLetter.docx)
Manuscript Template (../manuscript_template.docx)

Testimonials  
**Metrics**

Acceptance ~~30%~~  
 Acceptance to  
 publication **20-30 days**  
 Impact Factor **1.278**

👍 Indexed In


   
 (<https://www.crossref.org/06members/50go-live.html>)  
 ([https://publons.com/journal/?order\\_by=reviews&publisher=6275](https://publons.com/journal/?order_by=reviews&publisher=6275))

   
 (<https://www.icmje.org/journals-following-the-icmje-recommendations/>)  
 (<https://olddrji.lbp.world/justincluded.aspx>)

   
 (<https://scholar.google.co.in/citations?user=s9ZCyI0AAAAJ&hl=en>)  
 (<https://isindexing.com/isi/>)

  
 ([https://www.scilit.net/journals?publisher\\_group\\_id=9577](https://www.scilit.net/journals?publisher_group_id=9577))

Subscribe To Our

Leave a message 



## Comparative Evaluation of Clinical Effects After Operative Extraction of Impacted Mandibular Third Molars Using Piezosurgery and Rotary Instruments

Ana Gigovska Arsova<sup>1</sup>, Bruno Nikolovski<sup>1,2\*</sup>, Biljana Evrosimovska<sup>1</sup>, Nikola Gigovski<sup>3</sup> and Boris Velickovski<sup>4</sup>

<sup>1</sup>University Dental Clinical Center "St. Pantelejmon", Clinic for Oral Surgery and Implantology, Skopje, North Macedonia

<sup>2</sup>Faculty of Medical Sciences, Goce Delcev University, Stip, North Macedonia

<sup>3</sup>Faculty of Dentistry, Department for Prosthodontics, Ss. Cyril and Methodius University, Skopje, North Macedonia

<sup>4</sup>Faculty of Dentistry, Department for Oral Surgery, Ss. Cyril and Methodius University, Skopje, North Macedonia

\*Corresponding Author: Bruno Nikolovski, University Dental Clinical Center "St. Pantelejmon", Clinic for Oral Surgery and Implantology, Skopje, North Macedonia.

Received: July 17, 2023

Published: August 04, 2023

© All rights are reserved by Bruno Nikolovski, et al.

### Abstract

**Background:** Impacted mandibular third molars are frequently encountered in daily oral surgery practice. Surgical extraction of these teeth is indicated when they cause multiple problems that interfere with the normal functioning of the masticatory system, or as a prophylactic measure to prevent clinical symptoms. Due to the shortcomings of traditional rotary instruments, piezosurgery appears as an alternative technique to osteotomy whose main benefits are that it is inert to soft anatomical structures and it reduces the risk of damage or thermal necrosis of osteocytes.

**Aim:** The aim of this study is to compare piezosurgical and conventional osteotomy with hand piece and burs evaluating the time needed for the osteotomy and the intensity of postoperative complications, including pain and trismus.

**Materials and Methods:** Intraoperative and postoperative aspects were evaluated for the comparison between piezosurgical osteotomy and osteotomy with rotary instruments in the surgical removal of mandibular impacted wisdom teeth in total of 15 young patients through a split-mouth study.

**Results:** It takes more time to perform an osteotomy using piezosurgery compared to the conventional technique with rotary instruments, but statistically non-significant. Postoperative pain and trismus were lower in the test group where the osteotomy was performed piezosurgically, also without statistical significance.

**Conclusion:** Due to the lower intensity of postoperative symptoms, piezosurgery is a good therapeutic option for osteotomy, especially in cases where there is a high risk of injury to adjacent soft tissues.

**Keywords:** Impacted Mandibular Third Molars; Rotary Instruments; Piezosurgery; Osteotomy

### Introduction

Surgical extraction of impacted mandibular third molars is one of the most common and routine interventions in the daily oral surgery practice. Surgical removal is recommended and often necessary because they can cause several problems in the normal functioning of the masticatory system: pericoronitis, regional pain, limited mouth opening and trismus, acute odontogenic infection, caries on the distal surface of the mandibular second molar, appearing of a periodontal pocket formation, root resorption of the second mandibular molar, development of a follicular cyst, crowd-

ing in the mandibular frontal region, etc. Partially or fully impacted third molars may be associated with pericoronitis, pain, odontogenic infections, cysts and even tumors [1]. However, even though they are classified as routine interventions, in a certain number of cases they can be followed by intraoperative and postoperative complications, of which, according to Bouloux, et al., the most common in the literature are described as: alveolitis, bleeding and hematoma, infection, nerve injury and paraesthesia [2]. Pain, swelling and trismus are some of the most common postoperative sequels after these interventions. Wayland states that, although less com-

monly, mandibular fracture can also occur, as well as osteomyelitis, injury of the neighbouring tooth, displacement of impacted molar into adjacent soft tissue structures, wisdom tooth swallowing, aspiration, periodontal defects of adjacent tooth, temporomandibular joint (TMJ) injury, etc. [3].

In order to avoid or reduce these postoperative symptoms, different methods are applied such as preoperative and/or postoperative use of antibiotics, application of platelet rich fibrin (PRF), cryotherapy, drainage, use of corticosteroids, implementation of different flap techniques or osteotomy techniques. The main cause of postoperative complications is the acute inflammation that is a result of the bone and soft tissue manipulation. The intensity of the postoperative sequels and their expression depends on several factors, including the difficulty index of the impacted tooth, the duration of the intervention, the choice of the removal technique, perioperative application of antibiotics, etc. [4].

Regarding the operative protocol, the removal of impacted molars requires surgical exposure of the impacted tooth, which means an osteotomy procedure or partial removal of the surrounding bone, which can be performed by several surgical methods. The most commonly applied conventional method is based on the use of rotating burs and drills and results in creating a certain degree of surgical soft tissue and bone trauma. Consequently, postoperative morbidity contains clinical signs and symptoms with varying degrees of clinical manifestation, which directly affect the caused discomfort and can result with prolonged recovery process. With the development of modern dentistry and especially, the new minimally invasive tendencies, the method of piezo surgery can be counted as a promising alternative technique for osteotomy in the field of oral and maxillofacial surgery.

Piezosurgery is a periodontal and implant surgical technique that is used to complement the traditional oral surgical procedures, and in some cases completely to replace them. The low pressure applied to the piezosurgical instrument allows precise and selective removal of the bone only, with no damage of the surrounding soft-tissue anatomical structures. Indications for piezosurgery are: extraction of teeth, surgical extraction of impacted teeth, endodontic surgery, cystectomies, harvesting of autologous bone, etc. Transposition of n. alveolaris inferior, sinus maxillaris floor elevation, distraction osteogenesis, bone blocks harvesting are procedures presented in the literature as well. Piezosurgically assisted orthodontic treatment and other sensitive procedures can be performed more safely and precisely with the help of piezosurgery. As a result, even less experienced but properly trained surgeons can perform these techniques more efficiently [5].

The term piezo comes from the Greek word "piezein" which means "presses hard, squeezes" [6]. Piezosurgery is used in dentistry, traumatology, orthopedics, otorhinolaryngology, neurosurgery,

ophthalmology. Although the piezoelectric effect was invented by Pierre and Marie Curie in 1880, Zara., *et al.* report that this technique in dentistry was first used by Horton in 1975, and then by the Italian maxillofacial surgeon Tomaso Vercellotti in 1988 in order to overcome the limitations that appear when using traditional (burr) osteotomy by modifying conventional ultrasound technology [7]. Piezosurgery uses a frequency of 25-30 kHz, micro-movements with an amplitude of 60-210 µm and a power of the handpiece above 5 W, during which only bone tissues can be removed, because a frequency of 50 kHz is needed to cut soft-tissue anatomical structures. For those reasons, the piezosurgical technique of operation is recommended in cases when there is a greater risk of injury of the Schneiderian membrane, nerves, blood vessels or periosteum. Cooling during the removal of bone tissue is provided by the built-in cooling system. Various extensions can be used in the piezosurgical handpiece for osteoplasty, osteotomy, and separation of the soft tissue from the bone. Apart from sparing the soft anatomical structures, another advantage of this technique is that when working with a piezotome there is less bleeding in the operative field and greater visibility gained as a result of the cavitation phenomenon that is created by the distribution of the cooling fluid used during the work and the vibrations generated by the instrument [5]. In contrast to piezosurgery, with the conventional technique of osteotomy with rotating instruments, blood flows in and out of the operative field, while in piezosurgery it is completely removed due to high-frequency vibrations in all directions. Literature data show that with piezosurgery the damage at the structural and cellular level is less in comparison to other surgical techniques [8,9]. Currently, the gold standard for reconstruction of bone defects is still autologous bone despite the existence of different groups of bone substitutes, and its main benefit is maintaining the vitality of the transplanted cells. Numerous studies show that cell damage is significantly less and cell vitality is preserved in autologous bone grafts that are provided by manual instrumentation and piezosurgery compared to grafts harvested with rotary instruments, due to higher risk of thermal and mechanical trauma. According to that, lower osteogenic potential of those autografts taken in a conventional way can be expected [8]. Histological and histomorphometric analyses regarding the healing process of the surgical wound and the formation of bone tissue in experimental animal models show that the tissue response is more favorable when using piezo surgery than cutting the bone with a conventional technique using rotary instruments and diamond or carbide burs [9].

#### Aim

The aim of our trial is to determine the clinical efficacy and safety and to assess the potential benefits of using piezosurgery in the extraction of impacted mandibular third molars. Taking into account the experiences from the literature in which the positive and negative aspects of the classic technique (burr) and alternative techniques of osteotomy (laser, piezoelectric technique) and own initial experiences are elaborated, the following objectives were set:

- To compare the duration of the operative interventions from the beginning (first incision) to the removal of the tooth, which would give an idea of the length of the osteotomy realized by applying two different methods;
- To compare postoperatively, the consequences of the applied techniques, where the notation of the parameters was carried out in three stages - 1<sup>st</sup>, 3<sup>rd</sup> and 7<sup>th</sup> day after the intervention through the numerical determination of the following clinical indicators - trismus and pain.

### Material

The research was carried out at the University Dental Clinical Center "St. Panteleimon" -a Clinic for Oral Surgery and Implantology, Skopje. For the realization of the objectives mentioned above, 15 healthy male and female patients were included in this study, where a presence of bilaterally impacted mandibular third molars was diagnosed by clinical and radiological examination. Only those patients with same angulation of the wisdom teeth, same depth from the occlusal surface of the adjacent second molar, and same relationship with the ramus, that is, the same index of difficulty bilaterally, described by Pederson, were selected for the research [10]. In each of the patients, it was randomly determined which of the impacted molars would be extracted in which way, and all patients were verbally informed about the two interventions and signed an Informed consent.

### Inclusion criteria

- Patients in good health (ASA I - normal healthy patients; ASA II-patients with mild systemic diseases).
- Patients aged 18-40 years (of both genders).
- Patients with indication for extraction of bilateral symmetrically impacted mandibular wisdom teeth with completely developed roots with mesioangular, vertical or distoangular position according to Winter's classification.
- For each patient individually, there should be a symmetrical placement of the wisdom teeth on both sides and the same degree of difficulty of the surgical intervention.
- Patients who will agree to be part of the study, who are cooperative and will be available for regular postoperative follow up.
- Have not received antibiotics in the last two months.

### Exclusion criteria

- Patients with systemic diseases (ASA III - patients with severe and uncontrolled systemic diseases; ASA IV – patients with severe systemic diseases that are a constant threat to life; ASA V - terminally ill patients who are not expected to survive without surgery; ASA VI - patients with confirmed brain death whose organs have been removed for donation purposes).
- Smokers, alcoholics and drug addicts.
- Patients with pericoronitis or acute odontogenic infections.

- Pregnancy and breastfeeding at female candidates.
- Inability and unwillingness to participate in the surgical protocol and post-operative controls.

All patients were informed about the possible risks and benefits of the surgical intervention and all signed the informed consent before the beginning of the study, after taking a thorough anamnesis.

### Methods

In the control group, the osteotomy was performed using a KaVo INTRAmatic 10ES surgical powder handpiece, Biberach an der Riss, Germany and a drill with rotational speed of 35,000-40,000 rev/min, while in the study group, a piezo-surgical device Woodpecker surgical Touch LED, (Woodpecker Medical Instruments Co. Ltd, Guilin, Guangxi, P.R. China) and extensions US2 and US3 was used for the same purpose. There was a period of at least 6 weeks between the two interventions. In all cases where separation of the impacted molar was required, regardless of whether it was for the study or control group, it was done with a surgical handpiece and a fissure drill. All clinical and paraclinical examinations were performed individually and identically to all subjects. The obtained data were entered into a survey form designed for that purpose.

### Clinical trials

- Anamnestic data and clinical examination; the comparison between the two applied operating techniques will be based on the following parameters:
  - Primary parameter (evaluated during the surgical intervention) - recorded time from the first incision to the removal of the tooth, in order to determine the time duration of the osteotomy.
  - Secondary parameters (detected on the 1<sup>st</sup>, 3<sup>rd</sup> and 7<sup>th</sup> day postoperatively)
- Several parameters were monitored in all patients; the interincisal distance recorded using a measuring tape to measure the distance between the mesioincisal corners of the maxillary and mandibular right central incisor at maximum mouth opening preoperatively, on the first, third and seventh day after surgery. The difference between the preoperative dimension and each postoperative measure indicates the trismus for that day [11].

The pain was noted through the well-known visual analogue scale (VAS) which consists of 10 units, on the day after the intervention, the first, the third and the seventh day postoperatively.

X-ray examinations - were conducted at the University Dental Clinical Center "St. Panteleimon" on the Owandy Radiology 3D I-max device for 2D Panoramix images. Radiographs are taken of patients in order to determine the presence of bilaterally placed mandibular impacted third molars, their relationship with the canalis mandibulae, with the adjacent tooth, and to determine to



which classification group they belong. Impacted mandibular third molars with vertical, mesioangular and distoangular position according to Winter's classification will be included in this study.

### Surgical protocol

A painless operative field was provided by applying mandibular block anesthesia. Mepivacaine Hydrochloride 2%, with Adrenaline (Scandonest 2%, Septodont) was used. The operative field includes the innervation zones of n. alveolaris inferior, n. lingualis and n. buccalis. Adequate flap design - triangular flap (Ward's incision or modified Ward's incision) was created with an initial incision using disposable surgical scalpel #15 blade. After mobilization of the mucoperiosteal flap, the surrounding bone was removed using a standard osteotomy technique - Moore-Gillbe Collar technique. In the control group, the removal of bone on the buccal, occlusal and distal aspects of the tooth was performed using a straight surgical handpiece and drill accompanied by abundant irrigation with saline solution, while in the test group the osteotomy was performed using a piezo device Woodpecker Surgical touch (LED) and extensions US2 and US3. In a need for additional separation of the tooth, a fissure drill was used in both groups. After the extraction procedure was completed, definitive hemostasis was established and the operative wound was irrigated with saline, a 3-0 non-resorbable silk thread and simple interrupted sutures were used for its "per primam" closure.

### Postoperative care

All patients included in this trial were given written instructions for postoperative care regarding oral hygiene and application of ice packs. After the control and recording of pain and trismus on the first postoperative day, all patients were prescribed antibiotic therapy amoxicillin+clavulanic acid 875/125mg for a duration of 7 days, and metamizole sodium monohydrate 500 mg (Analgin, Alkaloid, Skopje) as needed. The sutures were removed on the 7<sup>th</sup> postoperative day.

## Results

### Statistical processing

The data were processed with the SPSS software package, version 22.0 for Windows (SPSS, Chicago, IL, USA). The analysis of the qualitative series was done by determining the coefficient of relations, proportions and rates. Quantitative features were analyzed with measures of central tendency, and with measures of dispersion. Difference test was used to compare gender proportions. Frequency distribution was tested with the Shapiro-Wilk W test. The Mann Whitney U test was used to test the significance of the difference between the groups in terms of the selected parameters. The intragroup comparison was done with Friedman test and Wilcoxon signed rank test with Bonferroni correction. A significance level of  $p < 0.05$  was used to determine statistical significance.

## Results

The research sample numbered a total of 15 patients, of which 6 (40%) were male and 9 (60%) were female with a gender ratio of 0.7:1. The percentage difference between the representation of respondents from both sexes was insignificant (Difference 7.15% [(-14.28-48.53) CI 95%].;  $p = 0.2815$ ).

The average age of the subjects in the sample was  $22.13 \pm 3.36$  years with a min/max age of 18/29 years and 50% patients aged  $\leq 33$  years. Male and female patients had an average age of  $20.33 \pm 1.37$  vs.  $20.22 \pm 3.81$  years and min/max age in men of 19/23 years, and in women of 18/29 years. About 50% of men and women were  $<20$  vs.  $<23$  years, no significant difference between sexes in terms of age ( $Z = -1.1532$ ;  $p = 0.1255$ ).

The intergroup comparison of the two methods in relation to the duration of the osteotomy indicated a non-significantly higher average value in patients treated with piezosurgery -  $19.41 \pm 13.37$  minutes compared to those treated with a drill -  $14.25 \pm 11.16$  minutes. In 50% of patients with piezosurgery, i.e., a drill, the osteotomy was  $<13$  vs.  $<9.2$  minutes respectively ( $p = 0.1914$ ). (Table 1).

The analysis of pain intensity (VAS 1-10) in patients treated with one of the two methods at three times after the intervention, indicated a non-significantly lower pain at all times of measurement in patients treated with piezosurgery compared to those treated with a drill i.e. at 1<sup>st</sup> day ( $p = 0.1103$ ), 3<sup>rd</sup> day ( $p = 0.1466$ ) and 7<sup>th</sup> day ( $p = 0.2717$ ). (Table 1).

At each of the three measurement times, trismus in patients treated with piezosurgery was non-significantly lower compared to the one in patients treated with a drill, and that for 1<sup>st</sup> day ( $p = 0.0649$ ), 3<sup>rd</sup> day ( $p = 0.3401$ ) and 7<sup>th</sup> day ( $p = 0.2997$ ) (Table 1).

In 50% of the patients treated with piezosurgery/burr, the trismus was consistent on 1<sup>st</sup> day  $<1.2$  vs.  $\leq 1.8$  cm, and on 3<sup>rd</sup> day  $<0$  vs.  $<0.3$  cm. On 7<sup>th</sup> day after the intervention, 50% of patients from both groups did not have trismus, i.e. in 25% of the group with piezosurgery/borer trismus was consistently  $>0.8$  vs.  $>1.3$  cm (Table 1).

A significant difference was found between the three measurement time intervals (1<sup>st</sup>, 3<sup>rd</sup> and 7<sup>th</sup> day postoperatively) in terms of pain intensity, both in patients from the piezosurgery group ( $p = 0.00001$ ) and in those from the control group ( $p = 0.00001$ ) - in addition to the significantly lowest pain on day 7 after the surgery (Table 2).

The additional analysis according to the Bonferonni correction ( $p < 0.012$ ) indicated that: a) in the group with piezosurgical oste-

Parameters	Comparison between groups						1p
	N	Mean ± SD	Min/Max	Percentiles			
				25 <sup>th</sup>	50 <sup>th</sup> (Median)	75 <sup>th</sup>	
DURATION OF OSTEOTOMY (minutes)							
Piezosurgery	15	19.41 ± 13.37	6.3/45.4	8.2	13	29	Z = -1.306; p = 0.1914
Burr	15	14.25 ± 11.16	4.0/38.0	5.3	9.2	18	
PAIN (VAS 1-10)							
Pain-day 1							
Piezosurgery	15	4.73 ± 2.31	0/9	3	4	7	Z = -1.597; p = 0.1103
Burr	15	6.07 ± 2.25	3/10	4	5	8	
Pain-day 3							
Piezosurgery	15	1.33 ± 1.68	0/5	0	1	2	Z = -1.452; p = 0.1466
Burr	15	2.47 ± 2.36	0/7	1	2	4	
Pain-day 7							
Piezosurgery	15	0.47 ± 0.91	0/3	3	0	1	Z = -1.099; p = 0.2717
Burr	15	1.07 ± 1.39	0/4	4	0	2	
INTERINCISAL DISTANCE (cm)							
Piezosurgery	15	5.02 ± 0.79	3.3/6.3	4.3	5.1	5.5	Z = -0.021; p = 0.9834
Burr	15	5.03 ± 0.76	3.5/6.3	4.3	5.1	5.5	
TRISMUS (cm)							
Trismus-day 1							
Piezosurgery	15	1.23 ± 1.03	0/3.5	0.4	1.2	2.1	Z = -1.846; p = 0.0649
Burr	15	2.02 ± 1.15	0.2/4.5	1.0	1.8	2.7	
Trismus-day 3							
Piezosurgery	15	0.45 ± 0.75	0/2.8	0	0	0.8	Z = -0.954; p = 0.3401
Burr	15	0.81 ± 1.15	0/3.5	0	0.3	1.3	
Trismus-day 7							
Piezosurgery	15	0.09 ± 0.17	0/0.5	0	0	0.2	Z = -1.037; p = 0.2997
Burr	15	0.37 ± 0.66	0/2.3	0	0	0.4	
Piezosurgery = test group; Burr = control group with conventional osteotomy 1Mann Whitney U test * statistical significance for p-value (p < 0.05)							

**Table 1:** Comparison between groups treated by piezosurgery vs rotary instruments.

Parameters	Intragroup comparison						1p
	N	Mean ± SD	Min/Max	Percentiles			
				25 <sup>th</sup>	50 <sup>th</sup> (Median)	75 <sup>th</sup>	
PAIN (VAS 1-10)							
Piezosurgery							
Pain-day 1	15	4.73 ± 2.31	0/9	3	4	7	X <sup>2</sup> <sub>(N = 15; df = 2)</sub> = 26.011; p = 0.00001*
Pain-day 3	15	1.33 ± 1.68	0/5	0	1	2	
Pain-day 7	15	0.47 ± 0.91	0/3	3	0	1	
Burr							
Pain-day 1	15	6.07 ± 2.25	3/10	4	5	8	X <sup>2</sup> <sub>(N = 15; df = 2)</sub> = 26.218; p = 0.00001*
Pain-day 3	15	2.47 ± 2.36	0/7	1	2	4	
Pain-day 7	15	1.07 ± 1.39	0/4	4	0	2	
TRISMUS							
Piezosurgery							

Pain-day 1	15	1.23 ± 1.03	0/3.5	0.4	1.2	2.1	X <sup>2</sup> <sub>(N = 15; df = 2)</sub> = 24.133; p = 0.00001*
Pain-day 3	15	0.45 ± 0.75	0/2.8	0	0	0.8	
Pain-day 7	15	0.09 ± 0.17	0/0.5	0	0	0.2	
Burr							
Pain-day 1	15	2.02 ± 1.15	0.2/4.5	1.0	1.8	2.7	X <sup>2</sup> <sub>(N = 15; df = 2)</sub> = 26.037; p = 0.00001*
Pain-day 3	15	0.81 ± 1.15	0/3.5	0	0.3	1.3	
Pain-day 7	15	0.37 ± 0.66	0/2.3	0	0	0.4	
<sup>1</sup> Fridman test * statistical significance for p-value (p < 0.05)							

**Table 2:** Intragroup comparison in piezosurgery/burr group for pain and trismus between three time intervals.

otomy, the significance between the three times of pain measurement, i.e. trismus, is due to a significant difference between 3<sup>rd</sup>/1<sup>st</sup> day and 7<sup>th</sup>/1<sup>st</sup> day, and no significant difference between 7<sup>th</sup>/3<sup>rd</sup> day; and b) in the control group (burr osteotomy), the significance between the three times of pain measurement, i.e. trismus, was

due to a significant difference between 3<sup>rd</sup>/1<sup>st</sup> day; 7<sup>th</sup>/1<sup>st</sup> day, and 7<sup>th</sup>/3<sup>rd</sup> day. The fact that there is no significant difference in the piezo group between 7<sup>th</sup> vs. 3<sup>rd</sup> day indicates that there is a faster recovery from trismus in this group compared to the control group (Table 3).

Parameters	Intragroup comparison		
	3 day/1 day	7 day/1 day	7 day/3 day
Pain (VAS 1-10)-Piezosurgery			
Z - Asymp. Sig. (2-tailed)	3.296; p = 0.0009*	3.256; p = 0.0009*	2.366; p = 0.0179
Pain (VAS 1-10)-Burr			
Z - Asymp. Sig. (2-tailed)	3.294; p = 0.0008*	3.408; p = 0.0006*	2.712; p = 0.0066*
Trismus-Piezosurgery			
Z - Asymp. Sig. (2-tailed)	3.179; p = 0.0015*	3.176; p = 0.0014*	2.201; p = 0.0277
Trismus-Burr			
Z - Asymp. Sig. (2-tailed)	3.293; p = 0.0007*	3.408; p = 0.0006*	2.548; p = 0.0108*
* Wilcoxon Signed Ranks Test: according to Bonferroni correction significant for p < 0.012			

**Table 3:** Intragroup comparison in piezosurgery/burr group for pain and trismus between three time measurements.

### Discussion

In order to ensure high surgical efficiency and less physical and psychological trauma for the patient, as well as to reduce the risk of intraoperative complications, alternative techniques to the conventional osteotomy technique have appeared in recent years [12].

Piezosurgery is based on the principle of oscillations while precise and sharp osteotomies are performed but the integrity of soft structures is preserved because the piezotome stops as soon as it comes into contact with non-mineralized tissues [13].

In 1975, in the first study dealing with piezosurgery, Horton, *et al.* conducted an experimental study to compare the effects of alveolar bone healing when osteotomy was performed with different methods: manual instruments, implanted instruments, and ultrasonic instruments [14]. The results he obtained present that best bone healing occurs after the osteotomy made with a chisel, then piezosurgery, and the weakest with the conventional osteotomy.

Labanca, *et al.* claim that piezosurgery is more effective in the first stages of bone healing, including earlier release of bone morphogenetic protein (BMPs), which better controls the inflammatory process and stimulates bone remodelling only fifty days after treatment [15].

Piezosurgery has certain advantages over conventional osteotomy primarily because it avoids injury to soft tissue structures, which can help reduce postoperative morbidity [4]. In a study by Shetty, *et al.* it is stated that the fact that piezosurgery is inert to soft tissues is the reason for the lower values of CRP and the VAS scale compared to the control group with implanted instruments, which is also confirmed in our study in relation to the VAS scale [4].

In the meta-analysis by Jiang, *et al.*, data show that facial oedema and pain are reduced during operative extraction of impacted third molars using piezoelectric surgical technique, which is also confirmed in this research [16].

Al Moraissi, *et al.* state that there is a significantly lower incidence of postoperative sequels with the piezoelectric surgical technique compared to the conventional one [17]. According to them, it is a result of less bone injury and better haemostasis, which reduces the risk of oedema. The meta-analysis shows that pain, swelling, trismus, and the numbers of pain killers are significantly reduced during piezosurgery, but significantly longer time is required performing surgery of impacted mandibular third molars compared to conventional surgery. These findings correlate with our results regarding pain and trismus.

Certain authors claim that the duration of the intervention has a direct impact on the postoperative sequelae, however others claim that the postoperative findings were independent of the length of the operation [18,19]. Our research shows that despite the fact that the procedure of osteotomy with a piezotome (19.41 ± 13.37 minutes) is slower compared to rotary instruments (14.25 ± 11.16) but without statistical significance, however there is a reduction in postoperative pain and trismus, also with no statistical significance. In Barone's study, the duration of time spent in the piezosurgical group is almost same as ours, a bit longer but statistically non-significant, which might be due to the fact that after the therapist has gained skills and practice this technique, it does not take significantly more time compared to the conventional osteotomy technique [20,21]. Another reason for this, as stated by Rullo, *et al.* may be that for the "simple operative extractions", there is no statistically significant difference in the duration in the two groups, with significantly less pain in the piezo group, while for the "complex extractions" is a statistically significant difference in the duration of the intervention in both groups, with a longer duration but also greater pain in the piezo group [22]. Saraiva Amaral, *et al.* noted that regardless of the degree of surgical difficulty according to the Parant scale, the average duration of the group with the ultrasonic intervention was 30.8 min., and with the conventional technique 26.8 min [11,23]. The difference between the 4-min techniques has no statistical significance ( $t(28) = -1.12$ ;  $p = 0.271$ ).<sup>11</sup> The meta-analyses of Cicciù, *et al.* Jiang, *et al.* Al-Moraissi, *et al.* and Liu, *et al.* confirm these results regarding the length of the intervention [12,16,17,24]. Regardless of the fact that the working time is increased compared to conventional surgery with rotary instruments, during piezosurgical removal of impacted mandibular third molars, postoperative complications are reduced and thus the patient's quality of life is improved. Piezosurgery is recommended when the wisdom tooth has a particularly risky or unusual position [25].

Zara, *et al.* in their 2020 study did not obtain a statistically significant reduction in postoperative clinical symptoms, but the time required for piezosurgical osteotomy was significantly longer [7].

The study of Barone, *et al.* as well as Sivoleda, *et al.* are in agreement with our obtained results for greater pain in the control group compared to the piezo group but without statistical significance [20,26]. Mantovani, whose study seems to be the largest split mouth study of piezosurgical removal of mandibular impacted third molars involving 100 patients, which also included surgeons with varying levels of experience for using piezosurgery, concludes that despite that more time is required for piezosurgical osteotomy, VAS is lower in the piezo group which ascribes to minimal soft tissue damage during the surgery where piezotome is used. [27]. Saraiva Amaral, *et al.* obtained higher pain values on the first postoperative day in the group with conventional technique, and on the 7<sup>th</sup> postoperative day higher values in the piezo group, but without statistical significance [11]. The same authors show better results for trismus in the piezo group, except for the third postoperative day when patients had a greater limitation of mouth opening in the test group.

In the study of Mistry, *et al.*, the results show that there is a statistically significant greater maximum interincisal distance in the piezosurgical group on the 1<sup>st</sup>, 3<sup>rd</sup>, 5<sup>th</sup> and 7<sup>th</sup> postoperative day [13]. Menziletoglu, on the other hand, obtains a smaller reduction in the maximum interincisal distance in the test group in which piezosurgery is used, but without statistical significance ( $p = 0.393$ ), which corresponds to our results [1].

The most recent meta-analysis by Nogueira, *et al.* from 2023, includes 18 randomized clinical publications and the obtained results demonstrate a significant reduction in pain level -0.95 [CI 95% = -1.23 to -0.67]. with a high clinical impact ( $P < .001$ ) and a significant increase in mouth opening in the piezo group of 4.29 [CI 95% = 2.33 to 6.25]. mm ( $P < .001$ ) [28].

Our results for all the investigated parameters are according to the results of the studies mentioned above, with only difference if there is statistical significance or not, which might rely to the size of the investigated samples.

## Conclusion

Despite the increased operative time in the group where the osteotomy was performed piezosurgically, we observe reduced postoperative pain and postoperative trismus, but with no significant relationship. Further research and studies with larger sample sizes are needed to address this aspect and validate these findings. We recommend this method for extraction of impacted mandibular third molars especially in cases where there is a greater risk of injury to surrounding soft tissue structures.

## Bibliography

1. Menziletoglu D., et al. "A prospective split-mouth clinical study: comparison of piezosurgery and conventional rotary instruments in impacted third molar surgery". *Oral and Maxillofacial Surgery* 24.1 (2020): 51-55.
2. Bouloux GF, et al. "Complications of third molar surgery". *Oral and Maxillofacial Surgery Clinical North America* 19.1 (2007): 117-128.
3. Wayland J. "Impacted third molars". WileyBlackwell, John Wiley and Sons, Inc (2018).
4. Shetty L., et al. "Comparison of the C-Reactive Protein Level and Visual Analog Scale Scores between Piezosurgery and Rotatory Osteotomy in Mandibular Impacted Third Molar Extraction". *Life (Basel)* 12.6 (2022): 923.
5. Schlee M., et al. "Piezosurgery: Basics and Possibilities". *Implant Dentistry* 15.4 (2006): 334-340.
6. Aly LAA. "Piezoelectric Surgery: Applications in oral and Maxillofacial Surgery". *Future Dental Journal* 4 (2018): 105-111.
7. Zara F, et al. "A split-mouth study comparing piezo electric surgery and traditional rotary burs on impacted third molars in young patients: an intraoperative and postoperative evaluation". *Minerva Stomatologica* 69.5 (2020): 278-285.
8. Moradi Haghgoo J., et al. "Comparison of the effect of three autogenous bone harvesting methods on cell viability in rabbits". *Journal of Dental Research, Dental Clinics, Dental Prospects* 11.2 (2017): 73-77.
9. Vercellotti T, et al. "Osseous response following resective therapy with piezosurgery". *International Journal of Periodontics and Restorative Dentistry* 25 (2005): 543-549.
10. Pederson GW. "Oral Surgery". Philadelphia: WB Saunders (1988).
11. Saraiva Amaral J., et al. "A Pilot Randomized Controlled Clinical Trial Comparing Piezo Versus Conventional Rotary Surgery for Removal of Impacted Mandibular Third Molars". *Bioengineering (Basel)* 9.7 (2022): 276.
12. Ciccù M., et al. "Piezoelectric Bone Surgery for Impacted Lower Third Molar Extraction Compared with Conventional Rotary Instruments: A Systematic Review, Meta-Analysis, and Trial Sequential Analysis". *International Journal of Oral and Maxillofacial Surgery* 50 (2021): 121-131.
13. Mistry FK, et al. "Postsurgical consequences in lower third molar surgical extraction using micromotor and piezosurgery". *Annals of Maxillofacial Surgery* 6.2 (2016): 251-259.
14. Horton JE., et al. "The healing of surgical defects in alveolar bone produced with ultrasonic instrumentation, chisel, and rotary bur". *Oral Surgery, Oral Medicine, Oral Pathology* 39 (1975): 536-546.
15. Labanca M., et al. "Piezoelectric surgery: Twenty years of use". *British Journal of Oral and Maxillofacial Surgery* 46 (2008): 265-269.
16. Jiang Q., et al. "Piezoelectric Versus Conventional Rotary Techniques for Impacted Third Molar Extraction: A Meta-Analysis of Randomized Controlled Trials". *Medicine* 94 (2015): e1685.
17. Al-Moraissi EA., et al. "Does the Piezoelectric Surgical Technique Produce Fewer Postoperative Sequelae after Lower Third Molar Surgery than Conventional Rotary Instruments? A Systematic Review and Meta Analysis". *International Journal of Oral and Maxillofacial Surgery* 45 (2016): 383-391.
18. Oikarinen K. "Postoperative pain after mandibular third-molar surgery". *Acta Odontologica Scandinavica* 49 (1991): 7-13.
19. Benediktsdóttir IS., et al. "Mandibular third molar removal: Risk indicators for extended operation time, postoperative pain, and complications". *Oral Surgery, Oral Medicine, Oral Pathology, Oral Radiology, and Endodontology* 97 (2004): 438-446.
20. Barone A., et al. "A randomized clinical evaluation of ultrasound bone surgery versus traditional rotary instruments in lower third molar extraction". *Journal of Oral and Maxillofacial Surgery* 68 (2010): 330-336.
21. Troedhan A., et al. "Ultrasonic piezotome surgery: Is it a benefit for our patients and does it extend surgery time? A retrospective comparative study on the removal of 100 impacted mandibular 3rd molars". *Open Journal of Stomatology* 1 (2011): 179-184.
22. Rullo R., et al. "Piezoelectric device vs. conventional rotative instruments in impacted third molar surgery: Relationships between surgical difficulty and postoperative pain with histological evaluations". *Journal of Cranio-Maxillofacial Surgery* 41 (2013): e33-38.
23. Thibault R., et al. "L'Expansion Scientifique Française". Paris, France (1974).
24. Liu J., et al. "Piezosurgery vs Conventional Rotary Instrument in the Third Molar Surgery: A Systematic Review and Meta-Analysis of Randomized Controlled Trials". *Journal of Dental Sciences* 13 (2018): 342-349.
25. Nehme W., et al. "Piezo-surgery technique and intramuscular dexamethasone injection to reduce postoperative pain after impacted mandibular third molar surgery: a randomized clinical trial". *BMC Oral Health* 21.1 (2021): 393.

26. Sivoilella S., *et al.* "Osteotomy for lower third molar germectomy: Randomized prospective crossover clinical study comparing piezosurgery and conventional rotatory osteotomy". *Journal of Oral and Maxillofacial Surgery* 69 (2011): e15-23.
27. Mantovani E., *et al.* "A split-mouth randomized clinical trial to evaluate the performance of piezosurgery compared with traditional technique in lower wisdom tooth removal". *Journal of Oral and Maxillofacial Surgery* 72 (2014): 1890-1897.
28. Nogueira DGM., *et al.* "Piezoelectric Surgery Is Effective in Reducing Pain, Swelling, and Trismus After Removal of Impacted Lower Third Molars: A Meta-Analysis". *Journal of Oral and Maxillofacial Surgery* 81.4 (2023): 483-498.