








Extended partial laryngectomy with functional preservation using the rotational crico-thyrotracheopexy

László Rovó MD, PhD¹  | László Szakács MD, PhD¹  |
Paul F. Castellanos MD, FCCP² | Zoltán Tóbiás MD¹  | Péter Pfišterer MD¹  |
Andrea Ambrus MD¹  | Miklós Csanády MD, PhD¹  | Ádám Bach MD, PhD¹ 

¹Department of Otorhinolaryngology—Head and Neck Surgery, Albert Szent-Györgyi Faculty of Medicine, University of Szeged, Szeged, Hungary

²Division of Otolaryngology, Department of Surgery, St. Rita's Mercy Hospital, Lima, Ohio, USA

Correspondence

Ádám Bach, Department of Otorhinolaryngology—Head and Neck Surgery, Albert Szent-Györgyi Faculty of Medicine, University of Szeged, Tisza Lajos krt. 111, 6725 Szeged, Hungary.
Email: bach.adam@med.u-szeged.hu

Funding information

Szent-Györgyi Albert Orvostudományi Kar, Szegedi Tudományegyetem, Grant/Award Number: 6356

Abstract

Objectives: Glottic tumors with infiltration of the anterior/posterior commissure, and lesions with subglottic, cricoid, or cricoarytenoid joint infiltration have been highly controversial in the past, from the perspective of oncological safety. Although conservation laryngeal resection options exist, most are limited by the extent of resection proscribed by the technique and the postoperative functional results. Oncologically speaking, extended vertical hemilaryngectomy is often the optimal solution. However, limited reconstruction methods often compel total laryngectomy.

Methods: Eight patients with vocal fold malignancy, which infiltrated the anterior and sometimes the posterior commissure and with subglottic extension and resultant uni/bilateral vocal fold motion impairment, were treated by single stage extended vertical partial laryngectomy with rotational crico-thyrotracheopexy as a functional reconstruction of the laryngeal framework. Patients were evaluated with objective and subjective function tests.

Results: Histologic examination demonstrated tumor-free margins in every case. Definitive decannulation was successful in all cases within 2 weeks. All patients had a stable and adequate airway during follow-up and reported socially acceptable voice. Oral feeding was possible in seven patients.

Conclusion: Rotational crico-thyrotracheopexy, as a single stage reconstruction technique, is based on well-vascularized, readily available, appropriately shaped local tissues, without significant donor site morbidity or need for long-term stenting to reconstruct large laryngeal defects after extended vertical hemilaryngectomy for advanced unilateral glottic tumors and is applicable even with supra/subglottic invasion or infiltration of the contralateral vocal fold. An adequate airway can be achieved with socially acceptable voice and safe swallowing without compromising oncologic reliability.

Level of Evidence: 4 (retrospective case series review).

This is an open access article under the terms of the [Creative Commons Attribution-NonCommercial-NoDerivs](https://creativecommons.org/licenses/by-nc-nd/4.0/) License, which permits use and distribution in any medium, provided the original work is properly cited, the use is non-commercial and no modifications or adaptations are made.

© 2023 The Authors. *Laryngoscope Investigative Otolaryngology* published by Wiley Periodicals LLC on behalf of The Triological Society.

KEYWORDS

extended vertical hemilaryngectomy, glottic cancer, rotational crico-thyrotacheopexy, single-stage reconstructive surgery, tracheal graft

1 | INTRODUCTION

Surgical treatment strategies for laryngeal malignancies follow well-defined, internationally accepted guidelines.^{1,2} Oncological safety is paramount regarding these surgical interventions, but there has always been a constant effort to push the boundaries of function-preserving solutions as even small impairment of laryngeal functions can have significant impact on patients' quality of life and safety.^{3,4} Still, if the tumor size or certain anatomical boundaries exceed the capabilities of standard resection techniques, the limits to reconstruct by previously described methods compels total laryngectomy in many cases.⁵ By partially sacrificing laryngeal function, certain techniques (Leroux-Robert, Hautant, Gluck-Soerensen, and Pearson, etc.) are suitable for successfully treating advanced laryngeal tumors in selected cases; these trade laryngeal function for oncological efficacy.⁶

Certain T2 and T3 glottic tumors with infiltration of the anterior/posterior commissure, subglottic extension, cricoid invasion, and/or cricoarytenoid joint infiltration are considered controversial indications for conservation surgery from the perspective of oncological safety and limits to reconstruction.⁷⁻⁹ Due to the complex anatomical and structural features of these subregions, obtaining an adequate surgical margin can be challenging.^{10,11} Moreover, the loss of significant parts of the cricoid and thyroid cartilages can lead to structural instability of the laryngeal framework: both static and dynamic laryngeal components can be impaired including the voice, respiration, and sphincter function. Each must be sustained within a small range of tolerance to sustain a delicate balance between the “tripod” of roles the larynx provides.

Muscle, neck skin, local or free graft mucosa, and thyroid gland flaps are described as useful for reconstructive techniques after partial laryngectomy.¹²⁻¹⁴ Unfortunately, with extended resections, these soft tissue grafts are structurally unsuitable for maintaining an adequate airway let alone voice and swallowing. For larger resection defects, we propose that the trachea, as a readily available, vascular, and mucosa-covered local graft seems to be an obvious option. Dealare et al. pioneered this field and introduced the technique of free tracheal autotransplantation in 1998 to repair extended laryngeal defects.¹⁵ Since his reports, few novel surgical concepts have been published.¹⁶⁻²⁰ Nonvascularized donor tracheas and synthetic trachea were not found reliable, thus the pursuit of the ideal graft and reconstructive surgical technique has continued.²¹

In a former study, we demonstrated that even after total cricoideotomy, a stable airway, socially acceptable voice, and good swallowing function can be restored with rotational thyrotacheopexy.⁹ Adapting this earlier method to this specific need, we report a novel, single-stage reconstruction technique that is useful after extended partial vertical hemilaryngectomy for cases of advanced laryngeal malignancies that obviates the need for total laryngectomy.

2 | MATERIALS AND METHODS

2.1 | Patients

In eight patients (six males and two females) with an average age of 58 years (range: 48–75), extended vertical partial laryngectomy was performed for a vocal fold malignancy, which infiltrated the anterior commissure and the subglottis in all the patients; these patients all had resultant unilateral or bilateral vocal fold motion impairment preop. In cases #1, #3, and #5, the tumor reached the posterior commissure as well. Extension onto the contralateral side was present in cases #1, #2, and #7. In patients #3, #6, #7, and #8, the tumor spread into the supraglottic region; the most widely infiltrating was case #4, with involvement of the first two tracheal rings. The extent of the lesions was preoperatively evaluated in all cases by computed tomography (CT) or magnetic resonance imaging (MRI). Additional patient data are reported in Table 1.

In patients #1 and #2, a European Union Type III laser cordectomy had previously been performed, in another institution before our open partial laryngectomy.²² Due to severe dyspnea, the airway was secured by tracheotomy and laser debulking in patients #3 and #4. Histopathology was positive for squamous cell carcinoma in patients #2, #3, #5, #6, #7, and #8. In the first case, histopathology found poorly differentiated leiomyosarcoma; whereas in case #4 it confirmed Hürthle cell thyroid tumor (which developed 8 years after total thyroidectomy and radioiodine therapy).

2.2 | Surgical technique

The operation started with a direct endoscopic examination of the airway for the appropriate evaluation of the tumor extension. Micro-laryngoscopy (MLS) was performed under total intravenous anesthesia and supraglottic jet ventilation except in patient #3 who had an existing tracheostomy. After endotracheal intubation, a horizontal incision was made at the level of the cricoid cartilage. Ipsilateral modified radical neck dissection of levels I–IV, and VI were performed in all patients. A paratracheal neck dissection was performed bilaterally in every case preserving the recurrent laryngeal nerve on the non-affected side. The trachea was also prepared by the dissection for later mobilization. The laryngotracheal complex was explored via the mobilization of the prelaryngeal muscles and the dissection of the thyroid gland.

According to the MLS findings, the tumor was removed by extended vertical partial laryngectomy as follows. First, the strap muscles with the thyrohyoid membrane were incised along the upper rim of the thyroid cartilage, and the superior horns of the thyroid cartilage were detached on each side for the laryngeal release (Figures 1A and 2A). Thereafter, an

TABLE 1 Patient data and specifications of the lesions.

Patient/ age/sex	#1/57 years/m	#2/52 years/m	#3/48 years/m	#4/75 years/f	#5/63 years/m	#6/59 years/m	#7/61 years/m	#8/49 years/f
Max. diameter of the tumor	32 mm	30 mm	27 mm	35 mm	28 mm	17 mm	35 mm	25 mm
Extension of the tumor	LVF, anterior quarter of the RVF, AC, PC, ipsilateral SG	RVF, AC, bilateral SG	RVF, RFVF, AC, PC, ipsilateral SG	RVF, AC, ipsilateral SG, ipsilateral thyroid ala, first and second tracheal cartilages	LVF, AC, PC, ipsilateral SG	LVF, LFVF, AC, ipsilateral SG	RVF, RFVF, AC, anterior quarter of LFVF, ipsilateral SG	RVF, AC, RFVF, ipsilateral SG, AC
Vocal fold mobility	Left-sided impairment	Bilateral impairment	Right-sided immobility	Right-sided impairment	Left-sided immobility	Left-sided impairment	Right-sided immobility	Right-sided impairment
Histology	High-grade leiomyosarcoma	Moderately differentiated SCC	Well- differentiated SCC	Hürtle cell carcinoma of the thyroid	Well- differentiated SCC	Moderately differentiated SCC	Well- differentiated SCC	Moderately differentiated SCC
Previous surgery	Laser cordectomy (type III)	Laser cordectomy (type III)	MLS, tracheotomy	MLS, laser debulking	MLS	MLS	MLS	MLS

Abbreviations: AC, anterior commissure; f, female; LFVF, left false vocal fold; LVF, vocal fold; m, male; MLS, microlaryngeal surgery; PC, posterior commissure; RFVF, right false vocal fold; RVF, right vocal fold; SCC, squamous cell carcinoma; SG, subglottis.

anterior laryngofissure was performed with a monopolar needle-knife or circular saw. The resection line was placed with 5–6 mm contralateral extension regarding the thyroid and cricoid cartilage (Figures 1A and 2A). Being attentive of the extension of the lesion, a horizontal and a vertical incision was made on the ipsilateral thyroid ala, sparing the upper and posterior edge of it, if possible (Figures 1B and 2A). The larynx was then opened and split at the anterior incision line of the contralateral side (Figures 1C and 2A). This exploration provided excellent visualization of the laryngeal lumen and the tumor, as well. The pyriform sinus was subsequently peeled away from the posterior aspect. This step is important to avoid a pharyngocutaneous fistula. The resection specimen included the true and false vocal fold, the entirety of the paraglottic space, the arytenoid cartilage, the thyroid ala (as mentioned above), and the cricoid cartilage on the side of the lesion (Figures 1D and 2A–C). If the tumor infiltrated the cricoarytenoid joint or the posterior commissure, the posterior medial incision was placed in the midline of the interarytenoid space. The integrity of the aryepiglottic fold was preserved as much as possible. The next steps of the surgery proceeded only after a negative intraoperative report of the frozen sections taken from the critical margins. The ipsilateral part of the pharyngeal constrictor muscle was preserved in all cases. At the end of the resection, the cricotracheal membrane was completely dissected (except case #4) and the orotracheal tube was replaced directly into the trachea (Figures 1D and 2A,B). A nasogastric feeding tube was also introduced.

2.3 | Resection variations in specific cases

In patients #1, #2, and #7, the anterior resection was even more extended (+5 mm) beyond the midline to the contralateral side of the cricoid arch and thyroid cartilage, respectively (Figures 1C and 2C). Meanwhile, the localization of the tumor required complete removal of the right thyroid ala and the petiole of the epiglottis in cases #6 and #7. Recurrence of the thyroid tumor and the first and second tracheal rings were also removed in patient #4.

2.4 | Laryngotracheal anastomosis

The earlier partially dissected trachea was further bluntly mobilized from the superior mediastinum, keeping strictly in the plane of the tracheal wall (Figure 3A). After assessing the length of the required graft, the trachea was carefully separated from the esophagus on the side of the laryngeal reconstruction, till the fourth–fifth tracheal cartilage could reach the inferior edge of the thyroid/hyoid remnant without tension. The membranous part of the trachea was incised on the opposite side of the lesion along the entire length of the laryngotracheal separation (Figures 2B and 3B). At this point, the distal trachea was moved upward and rotated 90° for the anastomosis, clockwise for the right-sided resection (viewing from above) and counterclockwise for the left-sided resection, toward the laryngeal defect (Figures 3B,C and 4A,B).

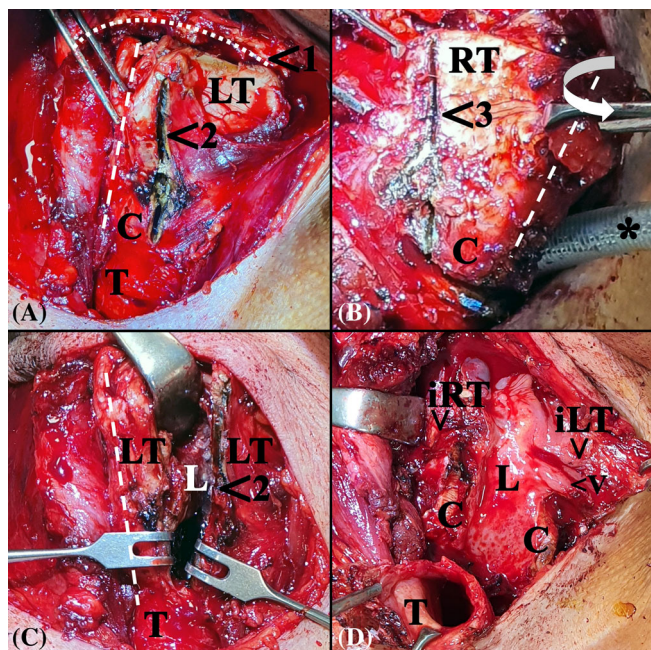


FIGURE 1 Right-sided extended vertical hemilaryngectomy (intraoperative pictures, patient #2). LT, left thyroid ala; RT, right thyroid ala; C, cricoid cartilage; T, trachea; iLT, the inner surface of the remnant of left thyroid ala; iRT, the inner surface of the remnant of right thyroid ala; L, laryngeal lumen; V, remnant of the left vocal fold; 1: line of the suprathyroid incision; 2: incision of the thyroid and cricoid cartilage on the contralateral side of the tumor; 3: incision of the thyroid and cricoid cartilage on the ipsilateral side of the tumor; *endotracheal tube; white dashed line represents the midline of the larynx. (A) After the suprathyroid mobilization of the larynx, the LT and the cricoid cartilage is incised on the contralateral side of the tumor. (B) During the resection, only the posterior edge of the RT could be preserved. The larynx is rotated to the left. (C) The exploration of the laryngeal lumen. (D) The final stage of the resection after right-sided extended vertical partial laryngectomy.

Then, the rotated tracheal cartilages were sutured posteriorly to the remaining cricoid plate with three to four interrupted, absorbable sutures (2-0 PDS Ethicon, Somerville, NJ), (Figures 3C,E and 4B). The membranous wall of the trachea was meticulously fitted to the relatively loose interarytenoid and supraglottic mucosa with interrupted sutures (Vicryl 2.0, Ethicon) (Figure 3E). The horizontal and vertical cut edges of the rotated trachea were then anastomosed to the anterior and inferior edges of the preserved contralateral thyroid ala although great attention was paid to maintaining the complete integrity of the C-shaped rings (Figures 3D,F and 4A-C). Before the closing of the anterior wall, a tracheostomy was performed (at the previously lateral side of the rotated trachea) and a Montgomery T-tube was placed into the airway cavity within the reconstruction (Figure 3E). Finally—adapted to the extension of the resection—the superior edge of the mobilized trachea was sutured (2-0 PDS, interrupted sutures) to the inferior and medial edges of the thyroid remnants (or the hyoid bone and remnant of

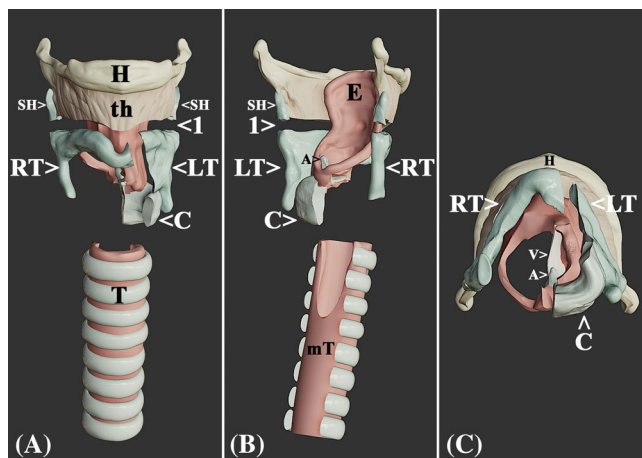


FIGURE 2 3D model of the laryngotracheal complex after right-sided extended vertical hemilaryngectomy. H, hyoid bone; th, thyrohyoid membrane; SH, superior horn of the thyroid cartilage; LT, left thyroid ala; RT, right thyroid ala; C, cricoid cartilage; T, trachea; E, epiglottis; mT, membranous wall of the trachea; V, left vocal fold; A, left arytenoid cartilage; 1: incision of the thyrohyoid membrane and the superior horns of the thyroid cartilage. (A) The right hemilarynx is resected with a significant contralateral extension on the thyroid and cricoid cartilage (anterior view). (B) The membranous part of the trachea is partially resected/incised depending on the size of the laryngeal defect (posterolateral view). (C) The true and false vocal fold, the paraglottic space and the cricoid cartilage is also resected on the right side (inferior view).

the epiglottis in case #6) (Figures 3E,F and 4A). Before closing the surgical site, heavy traction sutures were placed into the prelaryngeal muscles protecting against dehiscence of the laryngotracheal anastomosis due to wound tension or hyperextension during the early postoperative period.

Parenteral antibiotic (commonly amoxicillin/clavulanic acid or depending on the bacteriologic aspirate) was administered in all cases at least for 7 days.

2.5 | Evaluation of functional results

As the adverse effects of oncological therapy can be progressive, the assessment of the functional results was performed at the end of each patient's follow-up period. The evaluation of the voice quality was performed according to our previously published protocol, which was based on the guidelines described by the Committee on Phoniatrics of the European Laryngological Society.^{23,24} Maximum phonation time, fundamental frequency, harmonics-to-noise ratio, Jitter %, and Shimmer % were analyzed using Praat 6.1.03 software (www.praat.org). The patients' voice-related quality of life was assessed by the Hungarian version of the voice handicap index (VHI).²⁵ Peak inspiratory flow was measured for the objective assessment of the respiratory function.²⁶ From the subjective point of view, the functional outcome of the surgery in terms of voice, breathing,

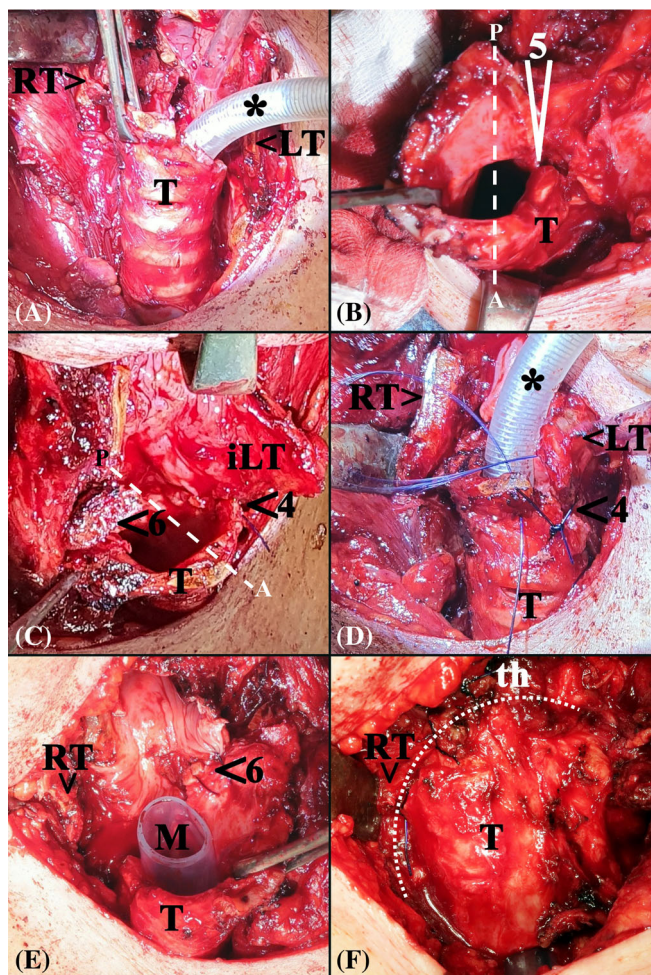


FIGURE 3 The steps of rotational crico-thyrotacheopexy (intraoperative pictures, [A–D]: patient #2; [E, F]: patient #6). LT, left thyroid ala; RT, right thyroid ala; T, trachea; iLT, the inner surface of the remnant of LT; th, thyrohyoid membrane; M, Montgomery T-tube; *endotracheal tube; 4: anterior cricotracheal anastomosis 5: incision/resection of the membranous wall of the trachea; 6: posterior cricotracheal anastomosis; the white dashed line represents the antero-posterior axis; dotted white line: line of the superior anastomosis in case of complete resection of the LT. (A) The trachea is mobilized and elevated. (B) The mobilized trachea is rotated and the membranous part of it is partially resected/incised depending on the size of the laryngeal defect. The dashed white line represents the antero-posterior axis. (C) First the posterior (6), then the anterior cricotracheal (4) anastomosis is sutured. (D) The inferior edges of the right and left thyroid remnants are sutured to the superior edge of the thyroid trunk, then the divided thyroid cartilage is reunited in the midline. (E) In patient #6, the LT was completely resected. The posterior cricotracheal anastomosis is sutured and a Montgomery T-tube is inserted for better mucosal healing. (F) After the anterior cricotracheal anastomosis, the superior edge of the trachea is directly sutured to the remnant of the RT, the thyrohyoid membrane and the hyoid bone.

swallowing, and overall satisfaction was evaluated by a quality of life questionnaire.²⁷ Paying special attention to the swallowing problems, the patients also completed the M.D. Anderson Dysphagia Inventory questionnaire (MDADI).²⁸

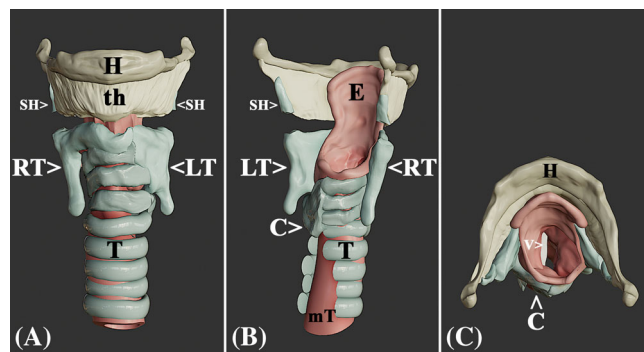


FIGURE 4 3D model of the reconstruction by rotational crico-thyrotacheopexy after right-sided extended vertical hemilaryngectomy. H, hyoid bone; th, thyrohyoid membrane; SH, superior horn of the thyroid cartilage; LT, left thyroid ala; RT, right thyroid ala; C, cricoid cartilage; T, trachea; E, epiglottis; mT, membranous wall of the trachea; V, left vocal fold. (A) The interposed tracheal graft maintains the cartilaginous framework of the larynx (anterior view). (B) The elevated and rotated tracheal flap stabilizes the supraglottic soft tissues as well (posterolateral view). (C) The C-shaped tracheal cartilages create a sufficiently wide glottic gap (superior view).

3 | RESULTS

There were no major peri- and postoperative complications. The events of the postoperative period are summarized in Table 2. The Montgomery T-tube was removed in the operating theater under general anesthesia on the 6th–13th postoperative day. In 5/8 cases, definitive decannulation was feasible simultaneously. No later than 4 days after stent removal, definitive decannulation was successfully performed in the remaining cases. Per oral feeding could be started progressively 7–20 days after the surgery. The tracheostomy closed spontaneously in all patients.

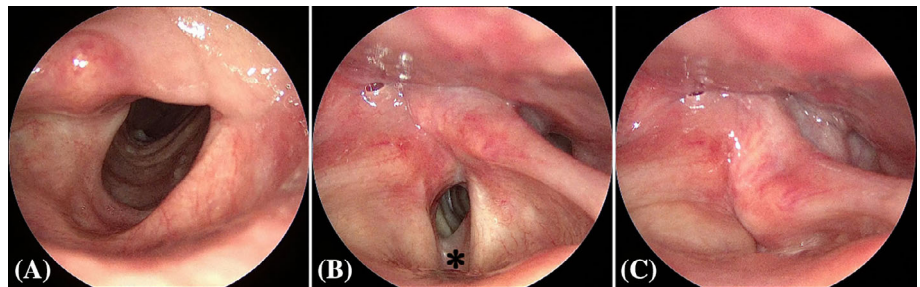
Permanent histology verified tumor-free margins in every case. Due to the advanced stage of the tumors, all but patient #4 underwent postoperative irradiation therapy based on the Hungarian oncology protocol. In case #4, no further oncological treatment was necessary. In cases #4 and #8, microscopic laryngeal surgeries were performed in the 11th and 14th postoperative week due to increasing dyspnea caused by a synechia of the anterior commissure; this was vaporized by CO₂ laser (Figure 5B,C). No further airway intervention was required in the other patients. Patient #1 developed pulmonary metastatic leiomyosarcoma by the fourth month after the laryngeal surgery. He underwent multimodality oncologic therapy, but no local or loco-regional metastasis was found during a 51-month follow-up period. Patient #4 died in acute myocardial ischemia in the seventh postoperative month. The autopsy confirmed no recurrent malignancy. During the follow-up time of 50, 47, 48, 22, 15, and 11 months, patients #2, #3, #5, #6, #7, and #8 were free from local and distant recurrences and were able to return to premorbid activities of daily living. All patients reported socially acceptable voice. Oral feeding without any dietary restriction was ensured in seven patients. In case of patient #7, percutaneous endoscopic gastrostomy was inserted due to inability to ingest solid foods (Table 3).

TABLE 2 Postoperative care after rotational crico-thyrotracheopexy.

Patient/age/sex	#1/57 years/m	#2/52 years/m	#3/48 years/m	#4/75 years/f	#5/63 years/m	#6/59 years/m	#7/61 years/m	#8/49 years/f
Removing of the Montgomery T-tube (postoperative day)	8	7	7	6	7	12	12	13
Decannulation (postoperative day)	8	7	8	6	11	13	12	13
Oral feeding (postoperative day)	9	9	9	7	12	14	20	15
Length of hospitalization (day)	17	12	13	13	16	23	21	16
Additional intervention (postoperative week)	-	-	-	Laser MLS (11)	-	-	PEG (8)	Laser MLS (14)

Abbreviations: f, female; m, male; MLS, microlaryngeal surgery; PEG, percutaneous endoscopic gastrostomy.

FIGURE 5 Postoperative endoscopic pictures (sixth postoperative month). (A) The interposed tracheal graft on the left side provides an appropriate airway (patient #6). (B) A mild subglottic synechia (*) was observed beneath the former anterior commissure (patient #4). (C) The active movements of the preserved left vocal fold ensure a good phonatory closure (patient #4).



4 | DISCUSSION

Surgical treatment of advanced laryngeal cancer with predominantly glottic-subglottic extension, glottic tumors with impaired vocal fold mobility, and malignancies infiltrating the anterior commissure and/or the cricoid cartilage have long been a matter of extensive debate. The deficient anatomical barriers (lack of a sufficient perichondrial barrier at the anterior commissure, the cricothyroid gap, and the extensive lymphatic supply of the subglottis) may facilitate local tumor invasion, thus mandating strictly radical surgery.²⁹ From an oncological point of view, (extended) vertical hemilaryngectomy would be a preferable solution.^{30,31} However, tumor volume and degree of extension with the consequent laryngeal structural defects can make total laryngectomy inevitable. Salvage or narrow field completion total laryngectomy may also be indicated sequentially due to a compromised airway and/or dysphagia, aspiration, or incurable fistula in the event of a failed transoral/open partial laryngectomy.⁵ Reconstruction procedures need to solve three important challenges: to definitively close the extended laryngeal/laryngotracheal defects; to maintain the structure and support of the laryngeal skeleton; to enable the mucosal lining of the interior of the larynx that suppresses the formation of cicatricial scar tissue.²¹ An adequate airway should be provided in the glotto-subglottic space, meanwhile, supraglottic soft tissues must be stabilized by replacing the cricoid (and arytenoid) cartilage. Furthermore, the larynx must provide a safe sphincteric function. To enable this, at least the following three laryngeal components must be preserved or restored: the posterior glottic area to prevent aspiration; a

reasonable anteroposterior diameter of the laryngeal airway and one normally mobile arytenoid cartilage.³² Accordingly, the resection should respect the posterior midline to maintain the inferior support of the arytenoid cartilage on the healthy side of the larynx.

The tissue used for reconstruction must meet numerous requirements. The graft should be rigid enough to withstand the decreased static pressure of the fast-flowing air or any potential external pressure. Simultaneously, it must be easy to shape and suture, readily available and epithelialized.³³ The originally flexible, arched C-cartilages, forced and fixated into a rigid frame of the remaining laryngeal framework, covered with respiratory mucosa make the trachea an ideal candidate for the reconstruction of extensive laryngeal defects. The mature cartilage is an avascular, bradytroph tissue with slow metabolic activity.³⁴ Even despite radiation, the cartilage retains its semirigid structure making the long-term results more predictable.³⁵ However, due to the vulnerable airway mucosa, proper vascularization of the graft is critical. The use of isolated segments of the trachea presents problems of revascularization because the small tracheal vessels are not adequate for microvascular anastomoses nor is it possible to induce neovascularization.^{36,37} During rotational crico-thyrotracheopexy the segmental tracheoesophageal arteries must be sacrificed on the anterior side (after rotation) down to the proximal three to four tracheal rings. Thus, the appropriate blood supply of the graft relies on the small branches of the tracheal arteries which supply trachealis muscle and membranous trachea as well as the transverse

TABLE 3 Functional results.

Patient/age/sex	#1/57 years/m	#2/52 years/m	#3/48 years/m	#4/75 years/f	#5/63 years/m	#6/59 years/m	#7/61 years/m	#8/48 years/f	Physiological range
Mean fundamental frequency (Hz)	128.3	142.5	90.2	99.1	106.5	92.8	138.9	101.2	f: 155–334; m: 85–196
Mean phonation time (s)	4.1	2.8	5.1	4.4	4.9	3.0	3.9	3.3	15<
Jitter (%)	10.3	7.7	9.4	1.5	10.3	6.0	9.9	8.9	<1.04
Shimmer (%)	17.0	14.3	12.2	18.9	17.4	13.5	22.9	15.0	<3.81
Harmonics-to-noise ratio (dB)	1.9	5.4	2.3	2.0	4.7	4.3	1.6	2.9	20<
Voice handicap index	15	29	44	21	52	58	26	75	0–120
MDADI	94.7	95.8	98.9	92.6	88.4	94.7	PEG	86.3	0–100
Peak inspiratory flow (l/s)	1.5	1.5	3.1	2.6	1.7	3.3	2.0	1.3	-
Quality of life	7	8	8	8	11	7	13	17	6–25
Follow-up (month)	51	50	47	6	48	22	15	11	

Abbreviations: f, female; m, male; MDADI, M.D. Anderson Dysphagia Inventory; PEG, percutaneous endoscopic gastrostomy.

intercartilaginous feeder vessels.³⁸ Morbidity and mortality in laryngotracheal surgery clearly relate to anastomotic tension or devascularization, furthermore, anastomotic complications arise proportionally with the length of the mobilized tracheal segment.^{39,40} Because the trachea can be elevated only about 2 cm without releasing maneuvers, several releasing techniques (blunt dissection of the anterior and posterior tracheal wall, infrahyoid and/or suprahyoid release, inferior pulmonary ligament lysis, pericardial dissection, and mediastinoscopy based tracheal and bilateral mainstem bronchial release) have been described to gain tracheal and laryngeal mobility, and decrease tension at the suture line to reduce complications.⁴¹ A combination of suprathyroid laryngeal release, blunt dissection of the trachea from the superior mediastinum and the heavy traction sutures of the prelaryngeal muscles proved to be sufficient in our cases. We did not encounter any anastomosis dehiscence our series. However, the reconstructed laryngotracheal lumen is immediately rigid enough to maintain its structure and support the supraglottic soft tissues, short-term stenting is highly recommended for better mucosal healing and due to the potential supraglottic edema. A Montgomery T-tube was preferred because it allows normal airway humidification, and the stomal area is typically less damaged than with tracheostomy.⁴²

Laryngeal release maneuvers hinder the physiological movement of the larynx during swallowing. Additionally, extended tracheal grafting serves a similar effect by pulling downwards the larynx, thereby limiting its elevation during swallowing. Potential recurrent laryngeal nerve injury (on the healthy side) may cause aspiration as well. To minimize the impairment of swallowing function, the hyoid bone should be involved by the resection to the smallest extent possible. Meanwhile, the removed section of the trachea should be kept sufficiently short so as not to compromise oncological safety. In our patients, the nasogastric feeding tube was removed within 20 days. The MDADI scores of dysphagia showed only minimal negative impact on swallowing-related quality of life in seven patients. After the procedure, the epiglottis, the aryepiglottic folds, and the posterior glottic area remained intact on the contralateral side of the surgery. These structures not only serve as mechanical barriers but also give place to the mechanoreceptors which are essential for safe, aspiration-free swallowing.⁴³ The mostly intact contralateral vocal fold may partially compensate for the inadequate glottic closure via the experience-dependent plasticity of the central nervous system controlling swallowing and voicing.⁴⁴ However, the significant extension of simultaneous supraglottic and contralateral resection may limit the rehabilitation of swallowing function, as seen in the case of patient #7.

The objective aerodynamic and acoustic parameters obviously differed from the normal values; however this voice impairment was not reflected entirely in the values of the VHI. Postoperative voice can be later improved with augmentation of the tracheal mucosa on the glottic level or with modified imbrication laryngoplasty.⁴⁵

The contraindications of extended vertical hemilaryngectomy must be closely followed such as: incurable neck metastasis, inability

to reconstruct the esophageal inlet, low pulmonary reserve, poor general health, poor mental status, etc. Furthermore, hypomobility of the cervical spine (with kyphoscoliosis), and prior tracheal or mediastinal surgery also reduces the chances of success.

5 | LIMITATIONS

The drawbacks of this study include its small sample size, and single-center nature. Nonetheless, further studies are warranted to explore the potential benefits and limitations of this novel surgical technique, such as comparing our results with patients who underwent primary chemoradiation for treatment. Fiberoptic endoscopic evaluation of swallowing could provide further information about the functional results as well.

6 | CONCLUSION

The presented single-stage reconstruction technique—the rotational crico-thyrotacheopexy—uses well-vascularized, readily available, appropriately shaped local tissues, without donor site morbidity or need for long-term stenting to reconstruct large laryngeal defects in selected cases after extended vertical hemilaryngectomy for advanced unilateral glottic tumors even with arytenoid involvement, supra/subglottic invasion or infiltration of the contralateral vocal fold. With this addition to the surgical armamentarium, an adequate airway can be achieved with socially acceptable voice and safe swallowing without compromising oncologic reliability in cases of advanced laryngeal tumors.

ACKNOWLEDGMENTS

The authors wish to thank Dr. Kathleen I. Castellanos for reviewing the article. Her assistance is greatly appreciated.

CONFLICT OF INTEREST STATEMENT

The authors have no conflicts of interest to disclose.

CONSENT FOR PUBLICATION

Each author listed on the manuscript has seen and approved the submission of this version of the manuscript and takes full responsibility for the manuscript. Written informed consent was obtained from the participants.

ORCID

László Rovó  <https://orcid.org/0000-0003-1782-1756>

László Szakács  <https://orcid.org/0000-0003-2217-2033>

Zoltán Tóbiás  <https://orcid.org/0000-0003-4871-9906>

Péter Píszterer  <https://orcid.org/0000-0003-3964-4295>

Andrea Ambrus  <https://orcid.org/0000-0003-2530-7175>

Miklós Csanády  <https://orcid.org/0000-0002-5639-9546>

Ádám Bach  <https://orcid.org/0000-0001-9265-1043>

REFERENCES

- National Comprehensive Cancer Network. Clinical practice guidelines in oncology: head and neck cancers. Version 1.2022. December 8, 2021. Accessed January 22, 2022. https://www.nccn.org/professionals/physician_gls/pdf/head-and-neck.pdf
- Pazdur R, Wagman LD, Camphausen KA, Hoskins WJ. *Cancer Management: A Multidisciplinary Approach*. UBM Medica; 2010.
- Pfister D, Laurie S, Weinstein G, et al. American Society of Clinical Oncology clinical practice guideline for the use of larynx-preservation strategies in the treatment of laryngeal cancer. *J Clin Oncol*. 2006;24:3693-3704.
- Terrell JE, Fisher SG, Wolf GT. Long-term quality of life after treatment of laryngeal cancer. The veterans affairs laryngeal cancer study group. *Arch Otolaryngol Head Neck Surg*. 1998;124(9):964-971.
- Hoffmann TK. Total laryngectomy—still cutting-edge? *Cancers*. 2021;13(6):1405.
- Thomas L, Drinnan M, Natesh B, Mehanna H, Jones T, Paleri V. Open conservation partial laryngectomy for laryngeal cancer: a systematic review of English language literature. *Cancer Treat Rev*. 2012;38(3):203-211.
- Prades JM, Peoc'h M, Petcu C, Karkas A, Dumollard JM, Gavid M. The anterior commissure of the human larynx revisited. *Surg Radiol Anat*. 2017;39(8):871-876.
- Komatsubara Y, Tachibana T, Orita Y, et al. Clinical characteristics of subglottic cancer: emphasis on therapeutic management strategies for stage II subglottic cancer. *Acta Otolaryngol*. 2020;140(9):773-778.
- Rovó L, Bach Á, Sztanó B, Matievics V, Szegedi I, Castellanos PF. Rotational thyrotacheopexy after cricoideotomy for low-grade laryngeal chondrosarcoma. *Laryngoscope*. 2017;127(5):1109-1115.
- Dedo HH. *Surgery of the Larynx and Trachea*. 1st ed. BC Decker; 1990.
- Sandhu GS, Reza Nouraei SA. *Laryngeal and Tracheobronchial Stenosis*. 1st ed. Plural Publishing; 2016.
- Amin MR, Koufman JA. Hemircricoidectomy for voice rehabilitation following hemilaryngectomy with ipsilateral arytenoid removal. *Ann Otol Rhinol Laryngol*. 2001;110:514-518.
- Conley JJ. Glottic reconstruction and wound rehabilitation procedures in partial laryngectomy. *Arch Otolaryngol*. 1961;74:239-242.
- Kojima H, Omori K, Fujita A, Nonomura M. Thyroid gland flap for glottic reconstruction after vertical laryngectomy. *Am J Otolaryngol*. 1990;11:328-331.
- Delaere PR, Poorten VV, Goeleven A, Feron M, Hermans R. Tracheal autotransplantation: a reliable reconstructive technique for extended hemilaryngectomy defects. *Laryngoscope*. 1998;108(6):929-934. doi:10.1097/00005537-199806000-00025
- Delaere O, Goeleven A, Poorten VV, Hermans R, Hierner R, Vranckx J. Organ preservation surgery for advanced unilateral glottic and subglottic cancer. *Laryngoscope*. 2007;117(10):1764-1769.
- Fujiwara T, Maeda M, Kuwae K, Nakagawa T, Nakao K. Free-prefabricated auricular composite graft: a new method for reconstruction following extended hemilaryngectomy. *Br J Plast Surg*. 2005;58(2):153-157.
- Brandariz JA, Grau M. Tracheal wall for the reconstruction of extended hemilaryngectomy in the rabbit model. *Otolaryngol Head Neck Surg*. 2005;132(5):770-775.
- Guinchard AC, Monnier P, Jaquet Y, Monnier Y, Ikonomidis C. Modified technique of functional vertical hemilaryngectomy for cancer invading 1 hemircricoid. *Head Neck*. 2016;38(11):1722-1727.
- Delaere PR, Van Raemdonck D. Commentary: the sobering truth about tracheal regeneration. *J Thorac Cardiovasc Surg*. 2020;159(6):2537-2539.
- Leong SC, Upile N, Lau A, et al. Extended vertical hemilaryngectomy and reconstruction with a neovascularised tracheal autograft for advanced unilateral laryngeal tumours: a learning curve. *Eur Arch Otorhinolaryngol*. 2014;271(6):1729-1735.
- Remacle M, Eckel HE, Antonelli A, et al. Endoscopic cordectomy. A proposal for a classification by the Working Committee, European Laryngological Society. *Eur Arch Otorhinolaryngol*. 2000;257:227-231.
- Dejonckere PH, Bradley P, Clemente P, et al. A basic protocol for functional assessment of voice pathology, especially for investigating

- the efficacy of (phonosurgical) treatments and evaluating new assessment techniques. Guideline elaborated by the Committee on Phoniatics of the European Laryngological Society (ELS). *Eur Arch Otorhinolaryngol*. 2001;258:77-82.
24. Matievics V, Bach Á, Sztanó B, et al. Functional outcomes of endoscopic arytenoid abduction lateropexy for unilateral vocal cord paralysis with dyspnea. *Eur Arch Otorhinolaryngol*. 2017;274:3703-3710.
 25. Jacobson BH, Johnson A, Grywalski C, et al. The voice handicap index (VHI) development and validation. *Am J Speech Lang Pathol*. 1997;6:66-70.
 26. Cantarella G, Fasano V, Bucchioni E, Domenichini E, Cesana BM. Spirometric and plethysmographic assessment of upper airway obstruction in laryngeal hemiplegia. *Ann Otol Rhinol Laryngol*. 2003;112:1014-1020.
 27. Jaquet Y, Lang F, Pilloud R, Savary M, Monnier P. Partial cricotracheal resection for pediatric subglottic stenosis: long-term outcome in 57 patients. *Thorac Cardiovasc Surg*. 2005;130:726-732.
 28. Chen AZ, Frankowski R, Bishop-Leone J, et al. The development and validation of a dysphagia-specific quality-of-life questionnaire for patients with head and neck cancer: the M. D. Anderson dysphagia inventory. *Arch Otolaryngol Head Neck Surg*. 2001;127(7):870-876.
 29. Castelijns JA, Snow GB, Valk J. *MR Imaging of Laryngeal Cancer: 23 (Series in Radiology)*. 1st ed. Springer; 1991.
 30. Marks SC. Conservation laryngeal surgery. *Curr Oncol Rep*. 1999;1(2):99-104.
 31. Kaanders JHAM, Lenarz T, Pop LAM, Schmol HJ, de Mulder PHM, Marres HAM. Larynxkarzinom. *Kompndium Internistische Onkologie*. Springer; 2006:3397-3420.
 32. Friedman WH, Katsantonis GP, Siddoway JR, Cooper MH. Contralateral laryngoplasty after supraglottic laryngectomy with vertical extension. *Arch Otolaryngol*. 1981;107:742-745.
 33. Forsen JW Jr, Lusk RP, Huddleston CB. Costal cartilage tracheoplasty for congenital long-segment tracheal stenosis. *Arch Otolaryngol Head Neck Surg*. 2002;128(10):1165-1171.
 34. Mescher AL. *Junqueira's Basic Histology: Text and Atlas*. 15th ed. McGraw-Hill Education; 2018.
 35. Alraiyes AH, Alraiyes MC, Abbas A. Radiation-associated airway necrosis. *Ochsner J*. 2013;13(2):273-275.
 36. Salassa JR, Pearson BW, Payne WS. Gross and microscopic blood supply of the trachea. *Ann Thorac Surg*. 1977;24:100-107.
 37. Delaere PR, Liu ZY, Pauwels P, Feenstra L. Experimental revascularization of airway segments. *Laryngoscope*. 1994;104:736-740.
 38. Monnier P. *Pediatric Airway Surgery; Management of Laryngotracheal Stenosis in Infants and Children*. Springer Verlag; 2011.
 39. Wright CD, Grillo HC, Wain JC, et al. Anastomotic complications after tracheal resection: prognostic factors and management. *J Thorac Cardiovasc Surg*. 2004;128:731-739.
 40. Blasberg JD, Wright CD. Surgical considerations in tracheal and carinal resection. *Semin Cardiothorac Vasc Anesth*. 2012;16:190-195.
 41. Broussard B, Mathisen DJ. Tracheal release maneuvers. *Ann Cardiothorac Surg*. 2018;7(2):293-298.
 42. Saghebi SR, Zangi M, Tajali T, et al. The role of T-tubes in the management of airway stenosis. *Eur J Cardiothorac Surg*. 2013;43(5):934-939.
 43. Crumley RL. Endoscopic laser medial arytenoidectomy for airway management in bilateral laryngeal paralysis. *Ann Otol Rhinol Laryngol*. 1993;102:81-84.
 44. Ruth EM. Neuroplasticity and swallowing. *Dysphagia*. 2009;24:218-229.
 45. Har-El G, Paniello RC, Abemayor E, Rice DH, Rassekh C. Partial laryngectomy with imbrication laryngoplasty for glottic carcinoma. *Arch Otolaryngol Head Neck Surg*. 2003;129(1):66-71.

How to cite this article: Rovó L, Szakács L, Castellanos PF, et al. Extended partial laryngectomy with functional preservation using the rotational crico-thyrotacheopexy. *Laryngoscope Investigative Otolaryngology*. 2023;8(5):1328-1336. doi:[10.1002/lio2.1155](https://doi.org/10.1002/lio2.1155)