



Title	Balloon pulmonary angioplasty for chronic thromboembolic pulmonary hypertension: its history and development, and regional medical cooperation in Fukushima
Author(s)	Nakazato, Kazuhiko; Sugimoto, Koichi; Oikawa, Masayoshi; Takeishi, Yasuchika
Citation	Fukushima Journal of Medical Science. 69(3): 167-176
Issue Date	2023
URL	http://ir.fmu.ac.jp/dspace/handle/123456789/2198
Rights	© 2023 The Fukushima Society of Medical Science. This article is licensed under a Creative Commons [Attribution-NonCommercial-ShareAlike 4.0 International] license.
DOI	10.5387/fms.2023-09
Text Version	publisher

This document is downloaded at: 2023-12-10T06:13:28Z



Balloon pulmonary angioplasty for chronic thromboembolic pulmonary hypertension : its history and development, and regional medical cooperation in Fukushima

Kazuhiko Nakazato^{1,2)}, Koichi Sugimoto^{2,3)}, Masayoshi Oikawa²⁾ and Yasuchika Takeishi²⁾

¹⁾Regional Medical Support Center, Fukushima Medical University, Fukushima, Japan, ²⁾Department of Cardiovascular Medicine, Fukushima Medical University, Fukushima, Japan, ³⁾Futaba Emergency and General Medicine Support Center, Fukushima Medical University, Fukushima, Japan

(Received March 22, 2023, accepted August 7, 2023)

Abstract

Chronic thromboembolic pulmonary hypertension (CTEPH) is designated as an intractable disease by the Ministry of Health, Labour and Welfare of Japan, and has an extremely poor prognosis if untreated. Surgical pulmonary endarterectomy is the curative treatment for cases in which the organized thrombi are located in the central part of the pulmonary artery, but there had been no effective treatment for cases in which the thrombi are located in the peripheral part of the pulmonary artery. Recently, balloon pulmonary angioplasty (BPA), a transcatheter procedure to dilate stenotic or occluded lesions in the peripheral pulmonary artery, has been rapidly developed. Although BPA was once a globally abandoned procedure due to hemorrhagic complications, Japanese experts have improved the technique, and its safety and efficacy have been enhanced. As a result, BPA is now being reevaluated worldwide. This review describes the history and development of BPA in the treatment of CTEPH, as well as the status of this treatment in Fukushima Prefecture.

Key words : chronic thromboembolic pulmonary hypertension (CTEPH), pulmonary hypertension, balloon pulmonary angioplasty (BPA), regional medical cooperation

Introduction

Chronic thromboembolic pulmonary hypertension (CTEPH) is a serious disease in which blood flow is obstructed by organized thrombi in the pulmonary artery, resulting in increased pulmonary vascular resistance, elevated pulmonary artery pressure, and decreased cardiac output, leading to severe right heart failure in the terminal stage¹⁾.

It is one of the government-designated intractable diseases, and the prognosis for patients with untreated CTEPH has been very poor²⁾. Annual trends of the number of patients with CTEPH in Japan show a gradual increase, and the number of patients in 2021 exceeded 4,800³⁾.

This disease is classified into “central” and “peripheral” types according to the main location of the

organized thrombi. While pulmonary endarterectomy (PEA) has been established as a treatment for the central type^{1,2)}, until recently there have been no effective therapeutic interventions for the peripheral type of CTEPH. However, since three papers were reported from Japan in 2012, catheter-based balloon pulmonary angioplasty (BPA) has become increasingly popular worldwide⁴⁻⁶⁾. In the meantime, two pulmonary vasodilators, riociguat and celexipag, have been approved for use in the treatment of this disease^{7,8)}, and the treatment strategy of CTEPH has undergone a major transformation⁹⁾. This review will outline the diagnosis and treatment of CTEPH with a focus on BPA. We will also discuss our efforts to manage a rare disease such as CTEPH in sparsely populated areas such as Fukushima Prefecture.

Corresponding author : Kazuhiko Nakazato E-mail : nakazato@fmu.ac.jp

©2023 The Fukushima Society of Medical Science. This article is licensed under a Creative Commons [Attribution-NonCommercial-ShareAlike 4.0 International] license.
<https://creativecommons.org/licenses/by-nc-sa/4.0/>

Pathophysiology and clinical diagnosis of CTEPH

CTEPH is defined as chronic persistent pulmonary hypertension resulting from stenosis or obstruction of the pulmonary arteries caused by organized thrombi. The duration of “chronic persistent” used to be defined as 6 months, but recently it is often defined as 3 months¹⁰. Acute pulmonary thromboembolism (APTE) secondary to deep vein thrombosis is widely known as a thrombotic disease of the lungs. The transition from APTE to CTEPH has been reported to be 0.97% at 2 years¹¹, and 0.56% in a meta-analysis¹². The association between APTE and CTEPH is not as strong as we might imagine. Early diagnosis of CTEPH is not easy, since the initial symptoms of this disease are nonspecific, such as shortness of breath and fatigue on exertion. Therefore, it is very important for physicians to suspect the disease based on those common symptoms. Ventilation/perfusion (V/Q) lung scintigraphy is very useful in differential diagnosis¹³. As shown in Figure 1, this examination reveals multiple perfusion defects in areas where ventilation is preserved (ventilation-perfusion mismatch). Pulmonary arteriography shows findings such as bands and webs, which are characteristic of CTEPH (Figure 2). The terms “band” and “web” have been used by pathologists for a long time in their publications, showing spiderweb-like networks macroscopically and lotus root-like cross-sectional images histopathologically¹⁴. Figure 3 shows optical coherence tomography images of a pulmonary artery web lesion. This type of orga-

nized thrombi obstructs the blood flow in the pulmonary arteries. A plain CT image of the lung field shows a mosaic pattern of high-density areas with rich blood flow and low-density areas with poor blood flow (Figure 4). The presence of those conditions and pulmonary hypertension (currently defined as a mean pulmonary arterial pressure of 25 mmHg or greater) on right heart catheterization is the definitive diagnosis of CTEPH².

History and development of BPA

BPA, as the name implies, is a balloon-assisted dilatation of stenotic lesions in the pulmonary artery. In practice, the only devices used are guiding catheters, guidewires, and classic balloons. Therefore, it has been technically feasible for a long time, with the first published case report in 1988¹⁵. However, BPA's efficacy and safety have been questioned since 2001, when Feinstein *et al.* reported a series of cases¹⁶. The efficacy of BPA in lowering mean pulmonary artery pressure did not match the efficacy of PEA, and there were cases of pulmonary hemorrhage following balloon dilatation that required ventilation, resulting in the death of one patient¹⁶. Since then, BPA had not been widely accepted. However, patients with “peripheral” CTEPH who are not eligible for PEA account for about half of all patients, and the percentage is even higher in Japan than in Western countries¹⁷. As the only treatment for these patients, BPA has been gradually implemented at a limited number of facilities in Japan since the mid-2000s. In 2012, three Japanese institutions reported on the results of BPA treat-

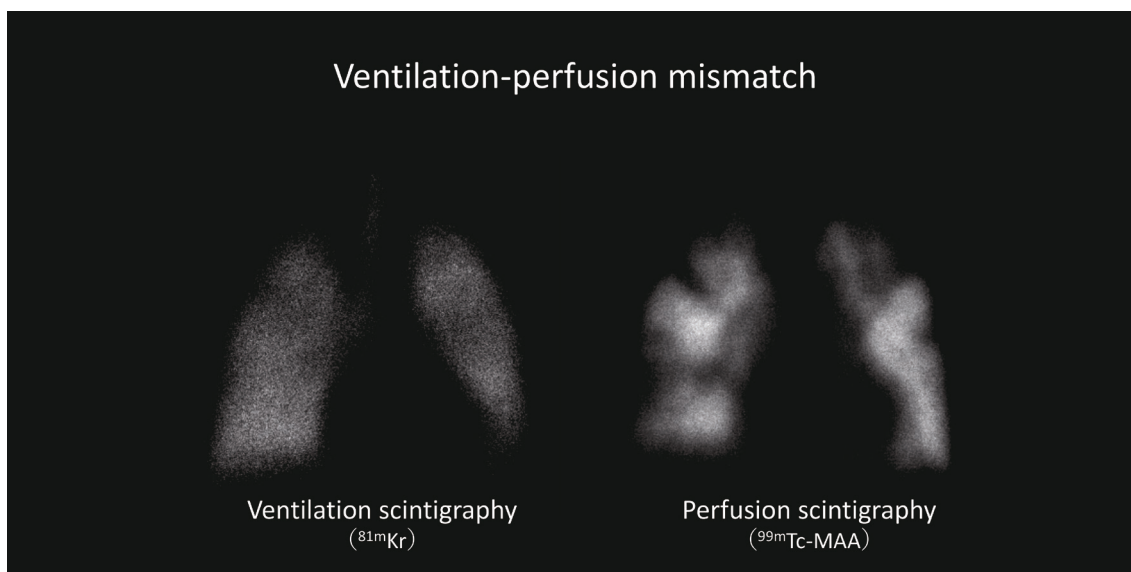


Fig. 1. Ventilation and perfusion scintigraphy in patient with CTEPH

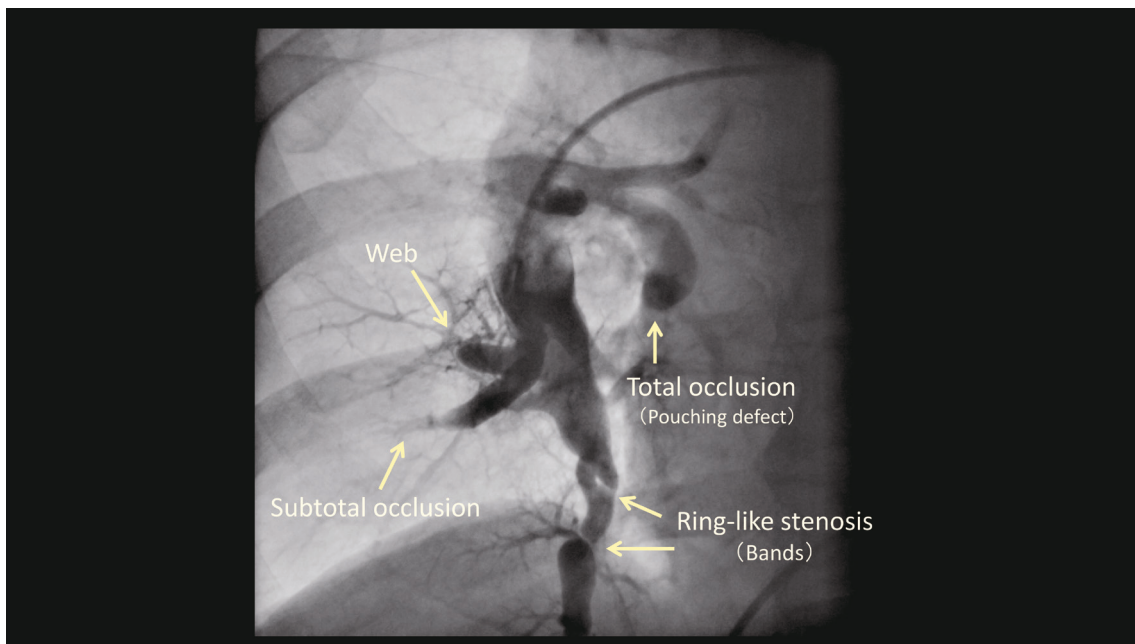


Fig. 2. Selective pulmonary angiography and various lesion morphologies

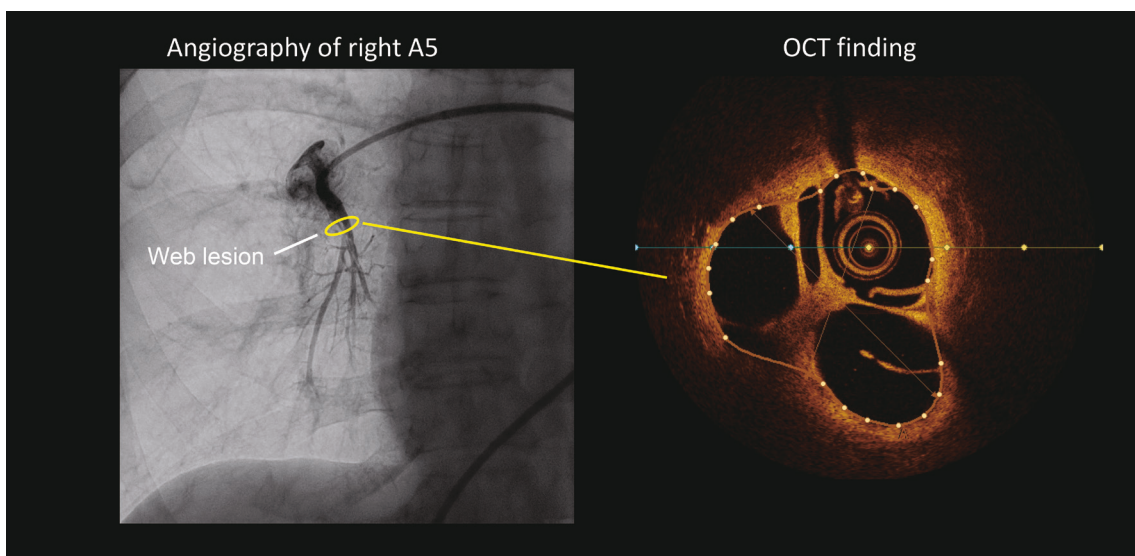


Fig. 3. Optical coherence tomography image of a web lesion of the pulmonary artery
OCT: optical coherence tomography.

ment⁴⁻⁶). Since the publication of those papers came at a time when the BPA procedure was generally considered contraindicated, it had a significant impact worldwide. However, a small number of patients still died from treatment-related complications, mainly pulmonary bleeding, so that further safety improvements were needed^{18,19}.

Practical techniques of BPA

The femoral vein is the basic approach site be-

cause of its superior location to the X-ray system and ease of catheter manipulation by the operators. After puncturing the femoral vein with an 8-French introducer sheath, a 6-French, 75 cm-long guiding sheath (Parent Plus 60, Medikit Co., Ltd., Tokyo, Japan) is advanced to the main pulmonary artery using a 0.035-inch guidewire. A 6-French, 100 cm guiding catheter (e.g., Mach1™, Boston Scientific, Marlborough, MA) is then advanced into either the left or right pulmonary artery to be treated²⁰. The shape of this guiding catheter is basically

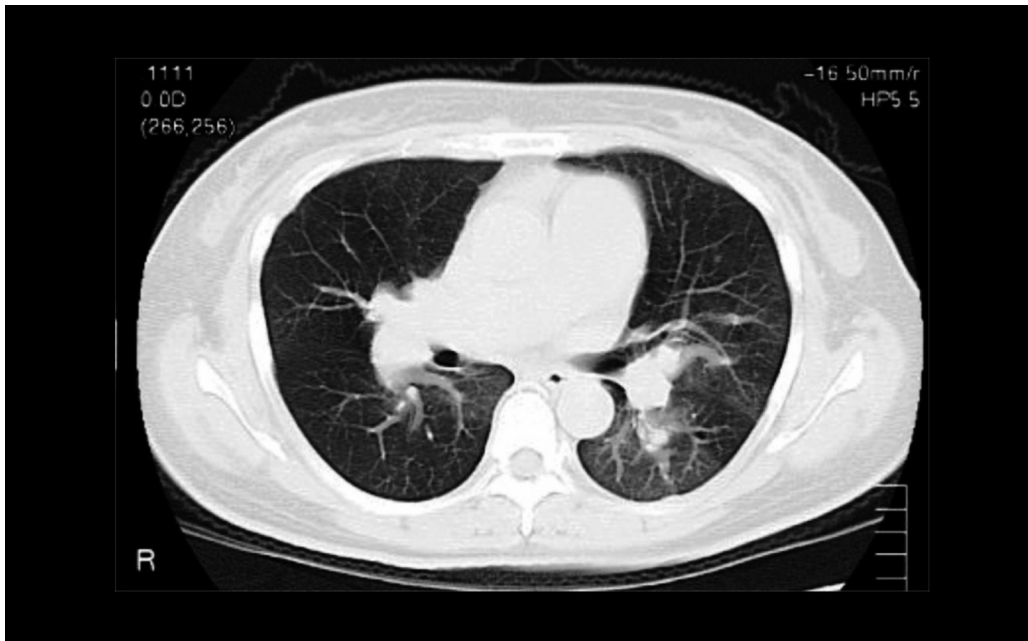


Fig. 4. Plain CT image of the lung field in a patient with CTEPH

the Judkins Right type for coronary arteries. Because CTEPH involves multiple branches of the pulmonary artery, it is necessary to decide which branch to start treating and how many branches to treat in a single session of BPA. It is helpful to obtain useful images of the distribution of the lesions and the branching pattern of the vessels by performing 3D imaging of the entire pulmonary artery in advance (Figure 5). For acquiring detailed lesion morphology, nothing is better than selective angiography from a guiding catheter. As shown in Figure

2, typical lesions are classified as ring-like stenosis (band), web, subtotal occlusion, and total occlusion (pouching defect), each with different degrees of difficulty in treatment techniques²¹. In general, ring-like stenosis (band) < web < subtotal occlusion < total occlusion are progressively more difficult for passing the guidewire, and the risk of complications after balloon dilation increases in that order. Total occlusion lesions of the pouching type are often located in proximal portions of the pulmonary artery, and are generally considered to be an indication for

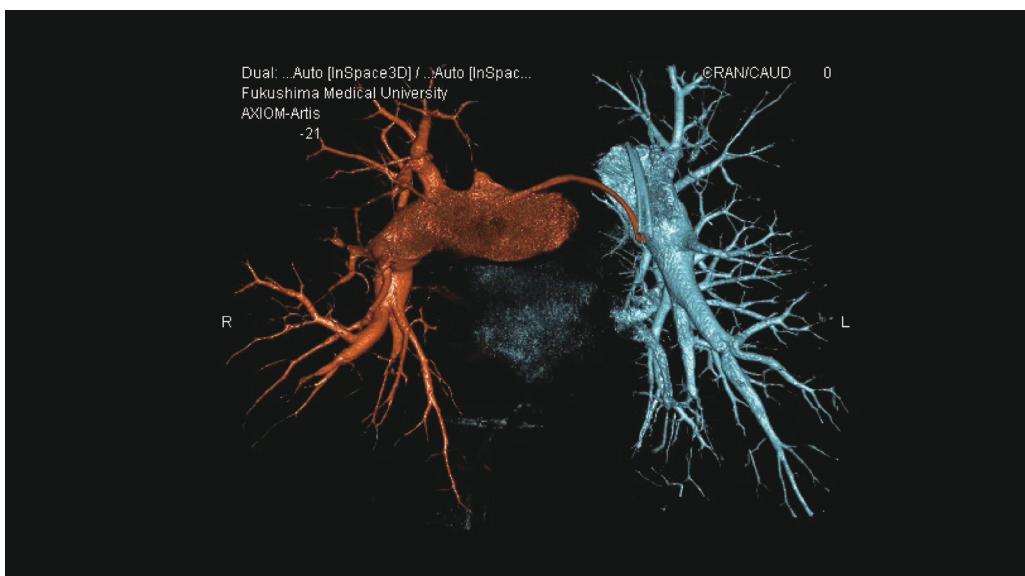

Fig. 5. Three-dimensional image of the entire pulmonary artery
Red : right pulmonary artery, Blue : left pulmonary artery.

surgery (PEA) in terms of the large amount of thrombus. A 0.014-inch peripheral guidewire is usually used for BPA. At our institution, the first choice is a wire with a 0.6 g tip load (B-pahm 0.6, Japan Lifeline, Tokyo, Japan), modified specifically for BPA. This guidewire intentionally lacks a hydrophilic coating at the tip to reduce the risk of vascular perforation. However, some lesions are difficult to pass with it and heavier tip loads or plastic jacket wires with high sliding performance may be selected, but the risk of vascular injury at the guidewire tip is higher. It has become clear in recent years that the size selection of the balloon used for lesion dilation is extremely important¹⁹. While percutaneous coronary intervention (PCI) and endovascular treatment (EVT) of peripheral arteries often warrant a balloon size that matches the diameter of the diseased artery (balloon : vessel diameter ratio = 1 : 1), this is not always suitable for BPA. In particular, an undersized balloon is preferentially selected for treatment of high pulmonary artery pressure conditions, which have increased risk of pulmonary hemorrhage. When treated according to these principles, the immediate post-dilatation angiographic findings are often not so beautiful, and when examined with a pressure wire, the procedure ends up leaving a pressure gradient between the proximal

and distal portions of the lesion²². Although not an acceptable endpoint in PCI, in BPA the possibility of chronic phase occlusion is very low. Conversely, once blood flow is restored, the vessel diameter is often wider in the chronic phase than it was immediately after dilation. If this is still considered inadequate, additional dilation with a bigger balloon should be performed at a time (after several BPA sessions) when pulmonary artery pressure has decreased.

Complications of BPA and preventive countermeasures

The most significant complication of BPA is intraoperative and postoperative pulmonary hemorrhage^{4,5,16,23}. The more severe the case, with hypoxemia and/or right heart failure, the more adverse the complications are when they occur. When pulmonary arteries, which are low-pressure vessels by nature, are exposed to high pressure due to “pulmonary hypertension,” even minor vascular injuries that would be negligible in the case of coronary arteries or peripheral arteries can result in hemorrhagic complications. Preventive countermeasures can be summarized in three points : 1) pay close attention to guidewire selection and manipulation to prevent vessel perforation, 2) carefully select the

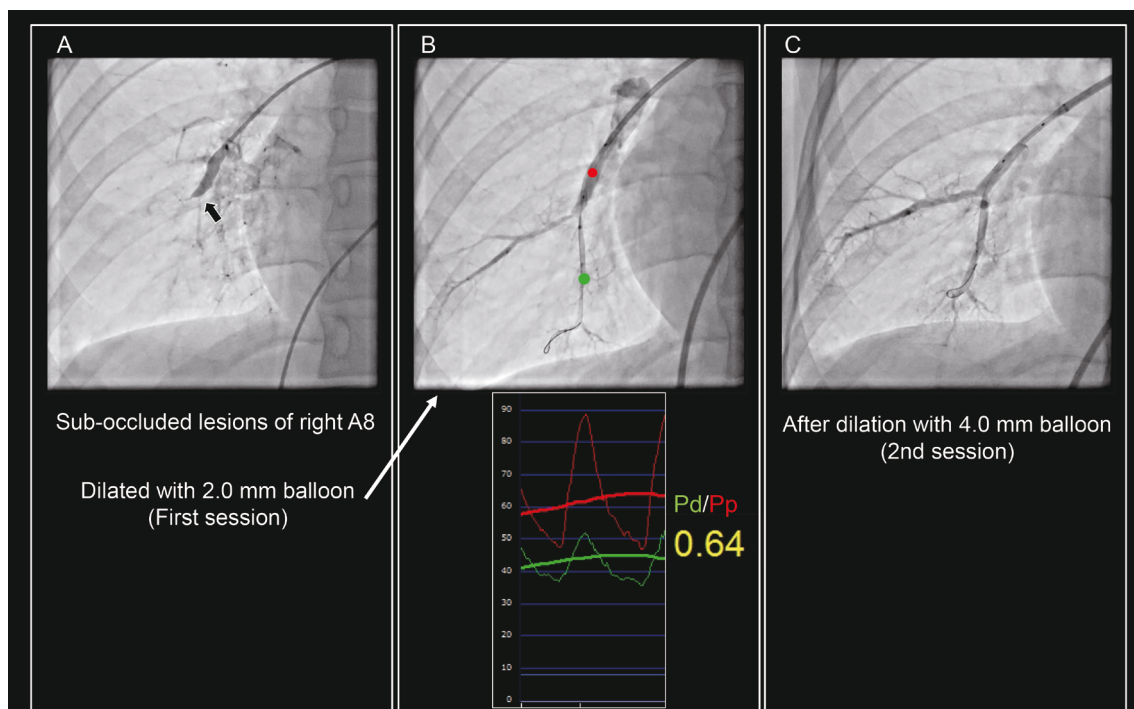


Fig. 6. Example of BPA for sub-total occluded lesions

A : Sub-total occluded lesions of right A8. B : Angiography of post dilation with 2.0 mm balloon (upper panel). Pressure gradients between the distal (green) and proximal (red) points of the lesion (lower panel). C : Angiography of post dilation with 4.0 mm balloon.

balloon size, and 3) treat stepwise rather than dilating all pulmonary arteries at one time. Regarding 2), higher pulmonary artery pressures call for correspondingly smaller balloon sizes and more attention to lesion morphology^{21,24}.

Figure 6 shows an example of initial treatment. Sub-totally occluded branches of A8 in the right inferior lobe (A) were dilated with a balloon catheter about half the size (2.5 mm in diameter) of the lesion vessel, which was 5.0 mm in diameter. Measurement of intravascular pressure at the distal and proximal portions of the lesion after balloon dilatation left a significant pressure gradient (Figure 6B). This would be a very poor endpoint for coronary artery intervention, but in contrast, as the first BPA (with still high pulmonary artery pressure), this is safer. If the lesion is typical, there is very little risk of restenosis. Since there are many pulmonary artery branches with lesions, treating many branches at once with a small balloon is more effective in lowering overall pulmonary artery pressure than treating only one or two branches. In cases where the pulmonary artery pressure has decreased after several sessions of BPA, the risk of pulmonary hemorrhage is reduced even if the lesion is dilated with a bigger size (close to the vessel diameter) balloon (Figure 6C).

If bleeding occurs that adversely affects the patient's general condition, hemostasis should be achieved by transcatheter hemostatic coiling²⁵ or using gelatin sponges²⁶. Hemostasis with freeze-dried porous gelatin sponges (Sponzel®, Astellas Pharma Inc., Tokyo, Japan) is a particularly useful

technique to learn, as it allows for recanalization of the occluded vessel at a later date. Although extremely rare, there have been reports of acute hemorrhage caused by a vessel wall rupture treated with covered stents^{27,28}. We have experienced such a complication and its bailout, and were the first in the world to report intravascular ultrasound images of ruptured pulmonary artery caused by BPA²⁹.

Improvement of the BPA techniques and its dissemination to the world

As mentioned above, BPA had been considered contraindicated since around 2001, but in Japan, this treatment has been applied to peripheral type CTEPH since about 2004, mainly at Okayama Medical Center. In 2012, publications from Japan brought BPA to the world's attention again⁴⁻⁶. From 2013 to 2014, experts in this field from all over the world visited Japan to observe actual BPA procedures at specialized facilities. Subsequently, Japanese physicians were invited to other countries to teach BPA techniques. In this way, BPA has improved in efficacy and safety, and has spread throughout the world (Table 1)^{4,5,21,23,24,30-38}. The CTEPH treatment algorithm published by WHO in 2018 finally placed BPA in the same line of treatment as PEA¹. This means that BPA is recommended for patients with inoperable CTEPH.

We also started this treatment for eligible patients in Fukushima Prefecture in 2011 and performed a total of 223 sessions of BPA on 58 patients through the end of 2022 (Table 2). The average

Table 1. Major BPA reports on CTEPH worldwide

Year	Author	Pt. number	Sessions	sessions /Pt.	Mean PAP (mmHg±SD)		Survival	Country	Reference
					Pre	Post			
2012	Mizoguchi	68	255	4	45.4±9.6	24.0±6.4	97.1%	Japan	4
2012	Kataoka	29	51	1.8	45.3±9.6	31.8±10	96.6%	Japan	5
2013	Anderssen	20	73	3.7	45±11	33±10	85%	Norway	19
2016	Kawakami	97	500	5.2	45.1±10.8	23.3±6.4	95%	Japan	22
2017	Kurzyna	31	117	3.8	50.7±10.8	35.6±9.3	94.6%	Poland	23
2017	Ogo	80	385	4.8	42±11	23±5	100%	Japan	28
2017	Olsson	56	266	4.8	40±12	33±11	98.2%	Germany	29
2017	Aoki	84	424	5.0	41±10	23±6	98.4%	Japan	30
2017	Ogawa	308	1,408	4.6	43.2±11.0	24.3±6.4	94.5%	Japan	31
2019	Velázquez	46	156	3.4	49.5±12	37.8±9	97.8%	Spain	32
2019	Bernot	184	1,006	5.5	43.9±9.5	31.6±9.0	96.2%	France	33
2019	Anand	31	75	2.4	40	29	96.8%	USA	34
2022	Kawakami	31	(not listed)	4.7	38.1±7.9	21.4±4.7	100%	Japan	35
2022	Jais	52	400	7.7	46.5±8.4	-18.7±9.3 (change)	100%	France	36

Table 2. List of patients treated with BPA at Fukushima Medical University Hospital

No.	Sex	Age	Admission	PAP (mmHg)	WHO-FC	Sessions	No.	Sex	Age	Admission	PAP (mmHg)	WHO-FC	Sessions
1	M	50's	2011. 7	88/36 (55)	III	6	30	F	40's	2019. 5	70/24 (40)	III	7
2	F	40's	2011.11	47/18 (30)	III	3	31	F	60's	2019. 2	72/36 (51)	III	1
3	F	50's	2012. 3	103/32 (62)	III	10	32	F	70's	2019. 6	67/24 (40)	III	4
4	F	60's	2012. 9	77/29 (46)	III	4	33	F	70's	2019. 9	86/26 (48)	III	5
5	F	70's	2012.10	74/17 (40)	III	3	34	F	70's	2018. 9	63/21 (36)	II	4
6	M	50's	2012.12	105/57 (75)	IV	3	35	F	80's	2019. 7	74/25 (44)	III	3
7	F	60's	2013. 3	85/29 (46)	III	7	36	F	50's	2019.11	75/31 (45)	III	4
8	F	70's	2013. 8	94/28 (56)	III	3	37	F	50's	2019.12	77/34 (48)	II	4
9	F	50's	2013.10	98/30 (56)	II	2	38	F	70's	2020. 2	51/19 (31)	III	5
10	F	50's	2014. 1	85/35 (55)	III	4	39	M	70's	2020. 4	68/24 (41)	III	5
11	F	70's	2014. 9	78/22 (40)	III	4	40	F	70's	2020. 5	75/26 (41)	III	2
12	F	40's	2014.10	98/50 (65)	II	5	41	F	60's	2020. 5	53/20 (34)	III	3
13	F	60's	2014.12	87/43 (59)	IV	3	42	F	30's	2016. 6	89/37 (57)	III	2
14	F	50's	2015. 1	74/21 (40)	II	8	43	F	60's	2019.11	54/23 (36)	II	4
15	F	60's	2015. 1	51/18 (31)	II	2	44	F	60's	2020. 7	82/19 (46)	II	3
16	F	70's	2015. 4	64/20 (37)	III	2	45	F	70's	2020. 8	56/17 (32)	III	1
17	F	70's	2015. 4	67/22 (38)	III	1	46	M	40's	2021. 1	84/33 (53)	III	6
18	F	60's	2015. 9	78/25 (44)	II	4	47	F	80's	2021. 2	73/16 (38)	III	3
19	F	60's	2015.10	79/31 (49)	III	1	48	F	40's	2021. 6	63/30 (41)	III	7
20	F	50's	2015.12	76/25 (45)	III	2	49	F	60's	2021. 6	76/34 (47)	II	3
21	M	70's	2016.10	75/25 (41)	III	6	50	F	70's	2021.10	50/20(34)	III	3
22	M	60's	2017. 5	91/28 (55)	III	2	51	F	70's	2021.10	67/22 (41)	III	1
23	M	70's	2017.10	76/21 (40)	III	4	52	M	70's	2021.11	72/17 (41)	III	2
24	F	40's	2018. 4	71/29 (44)	III	2	53	F	70's	2022. 1	54/20 (32)	III	3
25	F	80's	2018.10	76/32 (46)	III	2	54	F	40's	2022. 1	78/18 (40)	III	4
26	F	60's	2018. 8	35/17 (25)	II	2	55	F	60's	2022. 4	67/27 (43)	III	3
27	M	40's	2018. 7	74/34 (50)	III	7	56	F	60's	2022. 1	74/19 (37)	III	2
28	F	50's	2019. 2	97/30 (56)	III	6	57	F	30's	2022. 9	74/20 (43)	III	3
29	M	70's	2019. 2	76/23 (42)	III	9	58	F	20's	2022. 6	64/25 (39)	III	3

From 2011.7.15 to 2022.12.31

mean pulmonary arterial pressure and pulmonary vascular resistance decreased from 44.2 ± 8.1 mm Hg to 23.8 ± 6.1 mm Hg (Figure 7A) and from 9.7 ± 3.8 WU to 3.8 ± 1.0 WU (Figure 7B), respectively, after treatment. In addition, clinical symptoms also improved significantly (Figure 7C). Data collection and clinical follow-up of the patients were approved by the ethics committee of Fukushima Medical University (No. 2358 and No. 30022).

Establishment of a medical care system for rare diseases in local areas

The number of registered CTEPH patients in Fukushima Prefecture in 2021 was 87, which was far fewer than the 930 patients with systemic lupus erythematosus³⁾, for example. In addition, the number of registered patients increases by only 4 to 5 per

year, indicating that it is truly a rare disease. The initial symptoms of pulmonary hypertension, including CTEPH, are nonspecific, such as "shortness of breath," and it is difficult to make a definitive diagnosis from the symptom alone if a physician is not familiar with the disease. Early diagnosis and early initiation of treatment are very important to improve prognosis, but due to the low frequency of the disease, few physicians are familiar with the management of pulmonary hypertension, which is one of the reasons why it takes a long time from the onset of patient symptoms to definitive diagnosis. Therefore, we have established the "Pulmonary Hypertension Clinic" at Fukushima Medical University Hospital since 2015 to enhance the healthcare of patients with pulmonary hypertension. Since Fukushima is the third-largest prefecture in Japan and some patients live too far away to visit our clinic, we have

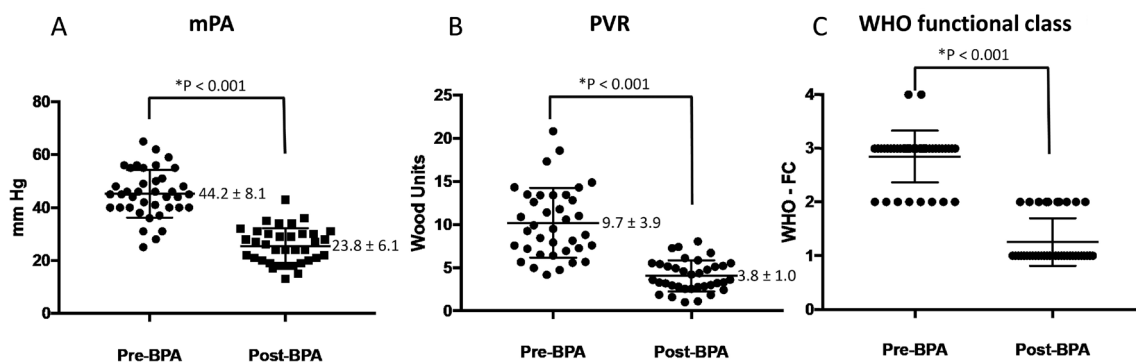


Fig. 7. Changes in parameters after balloon pulmonary angioplasty (BPA) Differences between variables measured at pre and post BPA were tested by the paired *t* test. A : Mean pulmonary arterial pressure (mPA). Data are expressed as the mean \pm SD. B : Pulmonary vascular resistance (PVR). Data are expressed as the mean \pm SD. C : World Health Organization (WHO) functional class.

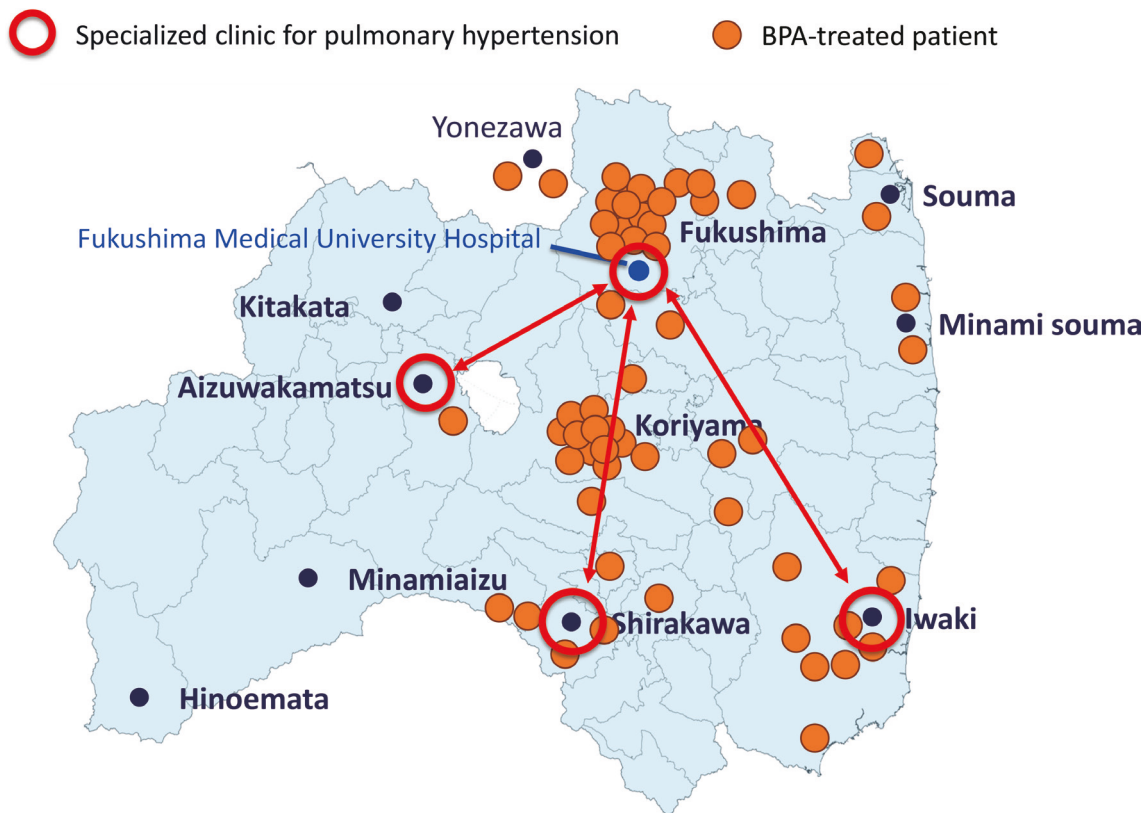


Fig. 8. Distribution of the patients treated with BPA in Fukushima prefecture Orange dots represent the residence of the patient who received BPA . Red circles represent pulmonary hypertension clinics.

also opened pulmonary hypertension clinics once a month at affiliated hospitals in Iwaki City and Shirakawa City, and specialists from our university hospital visit these clinics to provide specialized services. Since then, the number of patients referred from those areas has increased. Figure 8 shows the place of residence of patients who received BPA. In 2019, we added a pulmonary hypertension clinic in the (inland) Aizu area, where there had been

few referrals.

In Fukushima, the third largest of Japan’s 47 prefectures, professional travel can be time-consuming for university physicians visiting local hospitals. Our medical center is in a valley between mountain ranges, so even 100 km commutes can be a challenge. However, we believe that by connecting with regional medical staff in this way, we can disseminate knowledge and stir motivation for effec-

tive interventional pulmonology in each region. The novelty of this approach has attracted nationwide attention as the “Fukushima Model” for treating pulmonary hypertension in general, and CTEPH in particular.

Conflict of interest disclosure

All authors declare no conflicts of interest associated with this manuscript.

References

- Kim NH, Delcroix M, Jais X, *et al.* Chronic thromboembolic pulmonary hypertension. *Eur Respir J*, **53** : 1801915, 2019.
- Fukuda K. Guidelines for Treatment of Pulmonary Hypertension. JCS 2017/JPCPHS 2017 (in Japanese). 2018. (https://www.j-circ.or.jp/cms/wp-content/uploads/2017/10/JCS2017_fukuda_h.pdf)
- Number of recipients of designated intractable diseases in 2021 (Ministry of Health, Labour and Welfare Health Administration Report) (in Japanese). 2023.
- Mizoguchi H, Ogawa A, Munemasa M, Mikouchi H, Ito H, Matsubara H. Refined balloon pulmonary angioplasty for inoperable patients with chronic thromboembolic pulmonary hypertension. *Circ Cardiovasc Interv*, **5** : 748-755, 2012.
- Kataoka M, Inami T, Hayashida K, *et al.* Percutaneous transluminal pulmonary angioplasty for the treatment of chronic thromboembolic pulmonary hypertension. *Circ Cardiovasc Interv*, **5** : 756-762, 2012.
- Sugimura K, Fukumoto Y, Satoh K, *et al.* Percutaneous transluminal pulmonary angioplasty markedly improves pulmonary hemodynamics and long-term prognosis in patients with chronic thromboembolic pulmonary hypertension. *Circ J*, **76** : 485-488, 2012.
- Ghofrani HA, D’Armini AM, Grimminger F, *et al.* Riociguat for the treatment of chronic thromboembolic pulmonary hypertension. *N Engl J Med*, **369** : 319-329, 2013.
- Ogo T, Shimokawahara H, Kinoshita H, *et al.* Selexipag for the treatment of chronic thromboembolic pulmonary hypertension. *Eur Respir J*, **60** : 2101694, 2022.
- Delcroix M, Torbicki A, Gopalan D, *et al.* ERS statement on chronic thromboembolic pulmonary hypertension. *Eur Respir J*, **57** : 2002828, 2021.
- Galie N, Hoeper MM, Humbert M, *et al.* Guidelines for the diagnosis and treatment of pulmonary hypertension : the Task Force for the Diagnosis and Treatment of Pulmonary Hypertension of the European Society of Cardiology (ESC) and the European Respiratory Society (ERS), endorsed by the International Society of Heart and Lung Transplantation (ISHLT). *Eur Heart J*, **30** : 2493-2537, 2009.
- Coquoz N, Weilenmann D, Stolz D, *et al.* Multi-centre observational screening survey for the detection of CTEPH following pulmonary embolism. *Eur Respir J*, **51** : 1702505, 2018.
- Ende-Verhaar YM, Cannegieter SC, Vonk Noordegraaf A, *et al.* Incidence of chronic thromboembolic pulmonary hypertension after acute pulmonary embolism : a contemporary view of the published literature. *Eur Respir J*, **49** : 1601792, 2017.
- Frost A, Badesch D, Gibbs JSR, *et al.* Diagnosis of pulmonary hypertension. *Eur Respir J*, **53** : 1801904, 2019.
- Korn D, Gore I, Blenke A, Collins DP. Pulmonary arterial bands and webs : an unrecognized manifestation of organized pulmonary emboli. *Am J Pathol*, **40** : 129-151, 1962.
- Voorburg JA, Cats VM, Buis B, Brusckhe AV. Balloon angioplasty in the treatment of pulmonary hypertension caused by pulmonary embolism. *Chest*, **94** : 1249-1253, 1988.
- Feinstein JA, Goldhaber SZ, Lock JE, Ferndandes SM, Landzberg MJ. Balloon pulmonary angioplasty for treatment of chronic thromboembolic pulmonary hypertension. *Circulation*, **103** : 10-13, 2001.
- Lang IM, Madani M. Update on chronic thromboembolic pulmonary hypertension. *Circulation*, **130** : 508-518, 2014.
- Ikeda N. Balloon pulmonary angioplasty for chronic thromboembolic pulmonary hypertension. *Cardiovasc Interv Ther*, **35** : 130-141, 2020.
- Hirakawa K, Yamamoto E, Takashio S, *et al.* Balloon pulmonary angioplasty in chronic thromboembolic pulmonary hypertension. *Cardiovasc Interv Ther*, **37** : 60-65, 2022.
- Nakazato K. BPA technique and its complications (in Japanese). *Coronary Intervention*, **12** : 19-27, 2016.
- Kawakami T, Ogawa A, Miyaji K, *et al.* Novel Angiographic Classification of Each Vascular Lesion in Chronic Thromboembolic Pulmonary Hypertension Based on Selective Angiogram and Results of Balloon Pulmonary Angioplasty. *Circ Cardiovasc Interv*, **9** : e003318, 2016.
- Inami T, Kataoka M, Shimura N, *et al.* Pressure-wire-guided percutaneous transluminal pulmonary angioplasty : a breakthrough in catheter-interventional therapy for chronic thromboembolic pulmonary hypertension. *JACC Cardiovasc Interv*, **7** :

- 1297-1306, 2014.
23. Ogawa A, Satoh T, Fukuda T, *et al.* Balloon Pulmonary Angioplasty for Chronic Thromboembolic Pulmonary Hypertension : Results of a Multi-center Registry. *Circ Cardiovasc Qual Outcomes*, **10** : e004029, 2017.
 24. Ogo T, Fukuda T, Tsuji A, *et al.* Efficacy and safety of balloon pulmonary angioplasty for chronic thromboembolic pulmonary hypertension guided by cone-beam computed tomography and electrocardiogram-gated area detector computed tomography. *Eur J Radiol*, **89** : 270-276, 2017.
 25. Ando K, Mochizuki A, Kurimoto N, *et al.* Coil embolization for pulmonary arteriovenous malformation as an organ-sparing therapy : outcome of long-term follow-up. *Ann Thorac Cardiovasc Surg*, **17** : 118-123, 2011.
 26. Kaiser CA, Hugli RW, Haegeli LM, Pfisterer ME. Selective embolization of a pulmonary artery rupture caused by a Cournand catheter. *Catheter Cardiovasc Interv*, **61** : 317-319, 2004.
 27. Ejiri K, Ogawa A, Matsubara H. Bail-out technique for pulmonary artery rupture with a covered stent in balloon pulmonary angioplasty for chronic thromboembolic pulmonary hypertension. *JACC Cardiovasc Interv*, **8** : 752-753, 2015.
 28. Kataoka M, Inami T, Kawakami T, Fukuda K, Satoh T. Balloon Pulmonary Angioplasty (Percutaneous Transluminal Pulmonary Angioplasty) for Chronic Thromboembolic Pulmonary Hypertension : A Japanese Perspective. *JACC Cardiovasc Interv*, **12** : 1382-1388, 2019.
 29. Nakazato K, Sugimoto K, Kiko T, Kobayashi A, Takeishi Y. Angiographic and intravascular ultrasound images of pulmonary artery rupture during balloon pulmonary angioplasty. *Eur Heart J Cardiovasc Imaging*, **22** : 176, 2021.
 30. Andreassen AK, Ragnarsson A, Gude E, Geiran O, Andersen R. Balloon pulmonary angioplasty in patients with inoperable chronic thromboembolic pulmonary hypertension. *Heart*, **99** : 1415-1420, 2013.
 31. Kurzyna M, Darocha S, Pietura R, *et al.* Changing the strategy of balloon pulmonary angioplasty resulted in a reduced complication rate in patients with chronic thromboembolic pulmonary hypertension. A single-centre European experience. *Kardiol Pol*, **75** : 645-654, 2017.
 32. Olsson KM, Wiedenroth CB, Kamp JC, *et al.* Balloon pulmonary angioplasty for inoperable patients with chronic thromboembolic pulmonary hypertension : the initial German experience. *Eur Respir J*, **49** : 1602409, 2017.
 33. Aoki T, Sugimura K, Tatebe S, *et al.* Comprehensive evaluation of the effectiveness and safety of balloon pulmonary angioplasty for inoperable chronic thrombo-embolic pulmonary hypertension : long-term effects and procedure-related complications. *Eur Heart J*, **38** : 3152-3159, 2017.
 34. Velazquez M, Albarran A, Hernandez I, *et al.* Balloon Pulmonary Angioplasty for Inoperable Patients With Chronic Thromboembolic Pulmonary Hypertension. Observational Study in a Referral Unit. *Rev Esp Cardiol (Engl Ed)*, **72** : 224-232, 2019.
 35. Brenot P, Jais X, Taniguchi Y, *et al.* French experience of balloon pulmonary angioplasty for chronic thromboembolic pulmonary hypertension. *Eur Respir J*, **53** : 1802095, 2019.
 36. Anand V, Frantz RP, DuBrock H, *et al.* Balloon Pulmonary Angioplasty for Chronic Thromboembolic Pulmonary Hypertension : Initial Single-Center Experience. *Mayo Clin Proc Innov Qual Outcomes*, **3** : 311-318, 2019.
 37. Kawakami T, Matsubara H, Shinke T, *et al.* Balloon pulmonary angioplasty versus riociguat in inoperable chronic thromboembolic pulmonary hypertension (MR BPA) : an open-label, randomised controlled trial. *Lancet Respir Med*, **10** : 949-960, 2022.
 38. Jais X, Brenot P, Bouvaist H, *et al.* Balloon pulmonary angioplasty versus riociguat for the treatment of inoperable chronic thromboembolic pulmonary hypertension (RACE) : a multicentre, phase 3, open-label, randomised controlled trial and ancillary follow-up study. *Lancet Respir Med*, **10** : 961-971, 2022.