


CASE REPORT

Long-term outcome following successful endoscopic closure of tracheo-oesophageal fistulas with two cardiac amplatzer septal occluders in a patient with oesophageal cancer

Theresa Schreder¹  | Yves Borbély² | Stefan Christen² | Reiner Wiest² | Lorenz Räber³ | Gunar Günther^{1,4}

¹Department of Pulmonary Medicine and Allergology, Inselspital, Bern University Hospital, University of Bern, Bern, Switzerland

²Department of Visceral Surgery and Medicine, Inselspital, Bern University Hospital, University of Bern, Bern, Switzerland

³Department of Cardiology, Inselspital, Bern University Hospital, University of Bern, Bern, Switzerland

⁴Department of Human and Translational Medicine, School of Medicine, University of Namibia, Windhoek, Namibia

Correspondence

Theresa Schreder, Department of Pulmonary Medicine and Allergology, Inselspital, Bern University Hospital, University of Bern, Switzerland; Freiburgstrasse 8, CH – 3010 Bern, Switzerland.
Email: theresa.schreder@insel.ch

Associate Editor: Semra Bilaceroglu

Abstract

Acquired tracheo-oesophageal fistulas (TEFs) are rare and challenging complications in the course of oesophageal cancer. While surgery is the only curative treatment option for TEFs many patients are not eligible for surgery. Endoscopic treatment approaches such as tracheal- and/or oesophageal- stenting are available, but associated with complications like the development of new fistulas and mucus retention. Off-label-use of cardiac amplatzer occluder devices to close TEFs has been reported in few case-reports with inconsistent short-term outcomes. We report a case of successful closure of two adjacent TEFs with two partially overlapping cardiac amplatzer occluder devices. The insertion of a 12 mm and a 9 mm device was successful and without complications. The patient tolerated the cardiac amplatzer-devices well and could resume oral food uptake after 2 months. Two years after closure, the patient remained free of symptoms suggesting complete sealing of the fistulas.

KEYWORDS

Amplatzer, esophago-tracheal fistula, outcome, septal occluder

INTRODUCTION

Acquired tracheo-oesophageal fistulas (TEFs) are a regular complication in >10% of oesophageal cancer either caused by direct cancer infiltration into the airways or as a treatment consequence after radio- and/or chemotherapy or surgery. TEFs require prompt therapeutic interventions.¹

TEFs are suspected in patients presenting with symptoms such as cough associated with food intake, recurrent respiratory infections and chest pain. The diagnosis is based on chest computed tomography (CT) scan, gastroscopy and bronchoscopy. Treatment aims to maintain airway patency, prevent aspiration and secure oral food intake.²

Here we report the clinical outcome after 2 years of a patient with two TEFs successfully occluded by two cardiac amplatzer septal occlude (ASO) devices.

CASE REPORT

A 48-year-old woman was diagnosed with squamous-cell carcinoma of the oesophagus at 26–38 cm from incisors in stage T3, N2, M0 in March 2018. Combined radio-/chemotherapy led to complete remission. One year later she had a local recurrence treated surgically by esophagectomy and partial gastrectomy with cervical esophago-gastrostomy. Post-operatively she developed a tracheo-oesophageal-mediastinal fistula of 2 cm diameter with access to a necrotic mediastinal cavity at the site of the proximal anastomosis.

Placement of a self-expanding metal-stent in the trachea (site too proximal for an oesophageal stent) and an endo-SPONGE did not support fistula closure. Four months after surgery a second fistula occurred directly above the first, leading to two adjacent fistulas at 2.5 and 4 cm below the

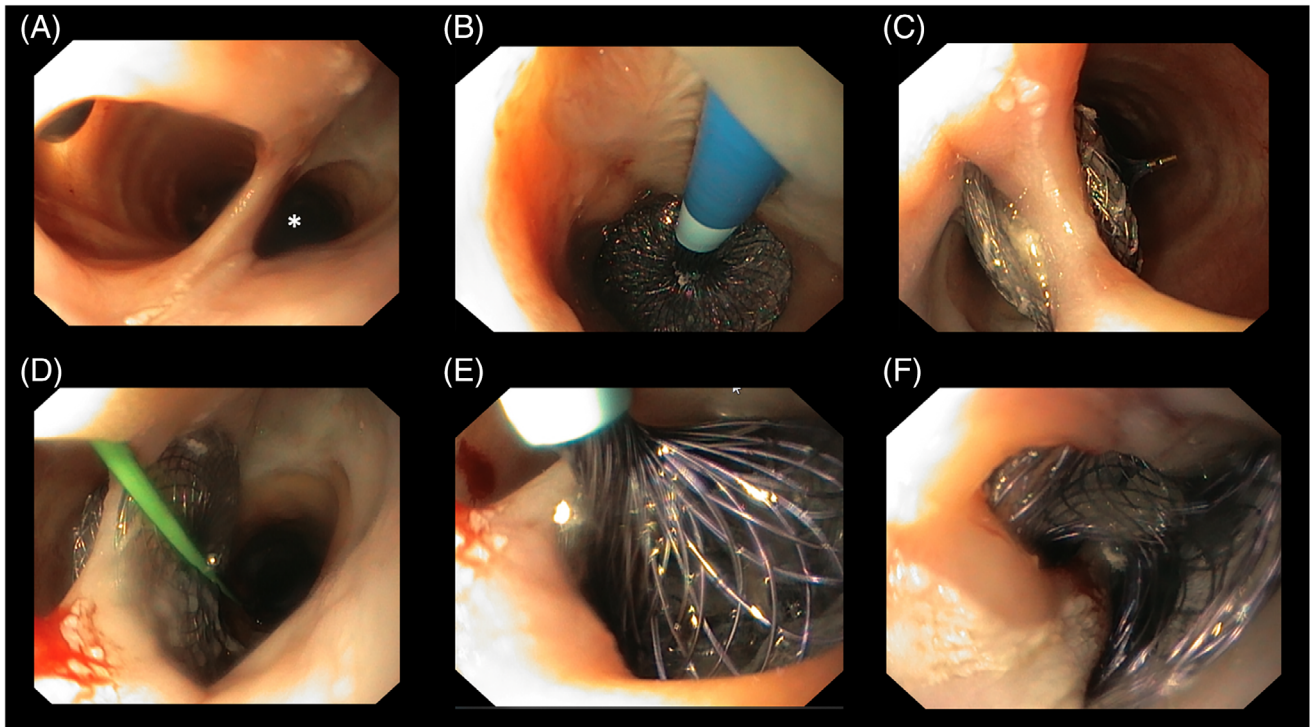


FIGURE 1 Insertion of the cardiac amplatzer septal occluder. (A) proximal and caudal (*) TEF—view from the oesophagus, (B) placement of caudal occluder via delivery sheath from the trachea to the oesophagus, (C) caudal occluder in situ, (D) guide wire in situ from the trachea to the oesophagus for the proximal occluder, (E) release of the proximal occluder, and (F) final positioning of the proximal occluder.

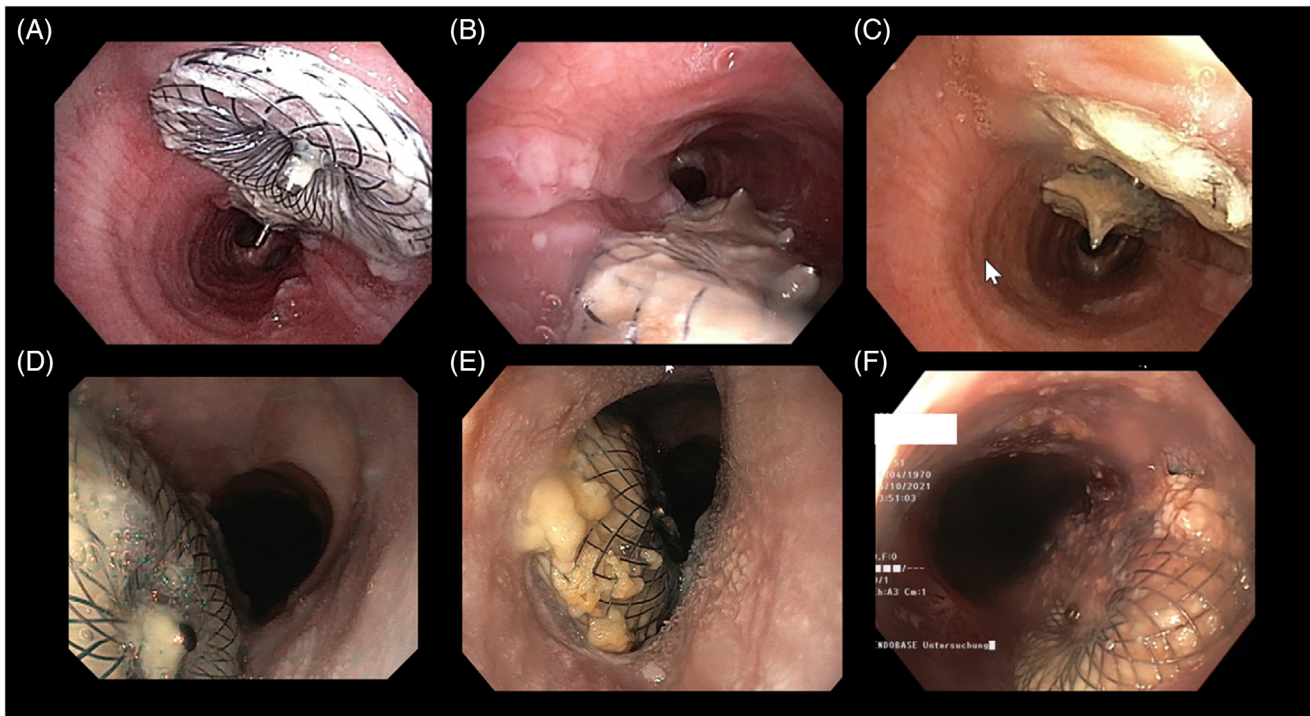


FIGURE 2 Post cardiac amplatzer septal occluder insertion—endoscopic imaging. Upper row—tracheal view (A) 6 weeks, (B) 3 months and (C) 6 months after placement; lower row—oesophageal view (D) 6 weeks, (E) 3 months and (F) 6 months after placement.

glottis, which were increasing in size (Figure 1A). Cancer recurrence was excluded.

The patient declined surgical options. Following interdisciplinary discussions we decided to attempt closure of the two fistulas by ASO about 9 months after the initial surgery, as previously described in the literature.³

The intervention was performed under combined rigid and flexible bronchoscopy as well as simultaneous gastroscopy. We used a 12 mm occluder (waist diameter) in the proximal fistula and a 9 mm occluder for the smaller, more distal fistula, resulting in good occlusion of the defect. The discs on the tracheal side resulted in an estimated 20% obstruction of the tracheal lumen.

Six weeks after the procedure the two ASO were in situ, there was no fistula visible on either side (Figure 2A,D). Oral liquids were tolerated well, a barium swallow showed normal results. The gastrostomy was removed and the patient could resume oral food intake after 2 months. In endoscopic follow-ups 3, 6 and 12 months after the procedure the ASO were covered with fibrin (Figure 2B,C,E,F).

During the latest clinical follow-up 2 years after the procedure the patient reported a good quality of life and no signs of cancer and/or fistula recurrence.

DISCUSSION

We present the successful treatment of two post-esophagectomy TEFs by cardiac ASO following intolerance of the initial fistula closure by bronchial stents. Two years after the procedure the devices remain in situ with clinical evidence of permanent sealing of the two fistulas, no signs of cancer recurrence, normal oral food intake and overall good quality of life.

Typically TEFs are managed by insertion of oesophageal and/or tracheal stents. Few case reports and small case series were published on the use of an ASO for repair of TEFs. However, there are no reports on the long-term efficacy and tolerability of these devices.³⁻⁶

A recent review of the literature suggests oesophageal stenting for malignant TEFs, tracheal stenting in case of tracheal stenosis or stenting of the oesophagus and the trachea in selected cases as the best-supported management approach for TEFs.⁷ The use of ASO is seen as critical, with evidence mostly based on a single case report.⁴ The review urges caution regarding the risk of fistula enlargement caused by the ASO and disc pressure on the tissue margins. Further concerns about mucus retention, formation of granulation tissue and reduction of the airway lumen are expressed. A Chinese case series reports the recurrence of four fistulas in four benign and two malignant TEFs between one and 12 months after insertion due to a cutting effect by the occluder's edge. In these cases, atrial septal, ventricular septal occluders and vascular plugs (Lifetech Scientific, Shenzhen, China) were used.⁵ A French single center case series reports technical feasibility of cardiac ASO placement (Abbott, Plymouth, Minnesota, USA) in

5/6 patients with benign TEFs, and clinical success after 9 months in 3/6 cases. The authors also raise concerns about mucosal erosion by the device.⁶ This risk could potentially be mitigated by using an optimally sized (i.e., ASO waist size equals largest fistula diameter size) ASO. A recent case report suggests the use of a CT scan with holographic 3D reconstruction of the fistula for optimized planning.⁸ Thereby the size of the waist of the ASO can be precisely selected, reducing instability shearing and improving the coverage of the fistula margins.

TEFs are difficult to manage. While oesophageal and/or tracheal stenting are recommended treatments, the use of septal occluders is described in very limited, but increasing number of cases, mostly with short term outcome. The case presented is the first case with placement of two ASO in TEFs and a favourable long-term outcome. It demonstrates the potential of the ASO approach to achieve long-term alleviation of symptoms and good quality of life in well-selected cases of TEFs with no further treatment alternatives. Current evidence bears the risk of publication bias due to mostly case reports. Larger multicenter registries are desirable to improve the knowledge about the method and optimal patient selection.

AUTHOR CONTRIBUTIONS

Gunar Günther and Theresa Schreder drafted the initial manuscript. All other authors critically reviewed, edited and approved the final manuscript.

CONFLICT OF INTEREST STATEMENT

None declared.

DATA AVAILABILITY STATEMENT

Data sharing is not applicable to this article as no new data were created or analyzed in this study.

ETHICS STATEMENT

The authors declare that appropriate written informed consent was obtained for the publication of this manuscript and accompanying images.

ORCID

Theresa Schreder  <https://orcid.org/0009-0005-4581-6841>

REFERENCES

1. Davydov M, Stilidi I, Bokyhan V, Arzykulov G. Surgical treatment of esophageal carcinoma complicated by fistulas. *Eur J Cardiothorac Surg*. 2001;20(2):405-8.
2. Couraud L, Ballester MJ, Delaisement C. Acquired tracheoesophageal fistula and its management. *Semin Thorac Cardiovasc Surg*. 1996;8(4):392-9.
3. Rabenstein T, Boosfeld C, Heinrich R, Ell C. First use of ventricular septal defect occlusion device for endoscopic closure of an esophagorespiratory fistula using bronchoscopy and esophagoscopy. *Chest*. 2006;130(3):906-9.
4. Elliott Miller P, Arias S, Lee H, Yarmus L, Feller-Kopman D. Complications associated with the use of the amplatzer device for the management of tracheoesophageal fistula. *Ann Am Thoac Soc*. 2014;11(9):1507-9.

5. Li J, Gao X, Chen J, Lao M, Wang S, Zeng G. Endoscopic closure of acquired oesophagorespiratory fistulas with cardiac septal defect occluders or vascular plugs. *Respir Med.* 2015;109(8):1069–78.
6. Belle A, Lorut C, Lefebvre A, Abou Ali E, Hallit R, Leblanc S, et al. Amplatzer occluders for refractory esophago- respiratory fistulas: a case series. *Endosc Int Open.* 2021;9(9):E1350–4.
7. Kim HS, Khemasuwan D, Diaz-Mendoza J, Mehta AC. Management of tracheo- oesophageal fistula in adults. *Eur Resp Rev.* 2020;29(158):200094.
8. Siboni S, D'Aiello A, Chessa M, Bonavina L. Tailored endoscopic treatment of tracheo- oesophageal fistula using preoperative holographic assessment and a cardiac septal occlude. *BMJ Case Rep.* 2022;15(3):e248981.

How to cite this article: Schreder T, Borbély Y, Christen S, Wiest R, Räder L, Günther G. Long-term outcome following successful endoscopic closure of tracheo-oesophageal fistulas with two cardiac amplatzer septal occluders in a patient with oesophageal cancer. *Respirology Case Reports.* 2023; 12:e01244. <https://doi.org/10.1002/rcr2.1244>