




illuminating and instructive clinical case



Paraneoplastic Anti-Tif1-gamma Autoantibody-positive Dermatomyositis as Clinical Presentation of Hepatocellular Carcinoma Recurrence

Marco Ferronato^{1,2}, Claudine Lalanne^{1,2}, Chiara Quarneti^{1,2}, Michele Cevolani¹, Chiara Ricci¹, Alessandro Granito^{2,3,4*} , Luigi Muratori^{1,2,3} and Marco Lenzi^{1,2,3}

¹Division of Internal Medicine and Immunorheumatology, IRCCS Azienda Ospedaliero-Universitaria di Bologna, Bologna, Italy; ²Center for the Study and Treatment of Autoimmune Diseases of the Liver and Biliary System, University of Bologna, Bologna, Italy; ³Department of Medical and Surgical Sciences, University of Bologna, Bologna, Italy; ⁴Division of Internal Medicine, Hepatobiliary and Immunoallergic Diseases, IRCCS Azienda Ospedaliero-Universitaria di Bologna, Bologna, Italy

Received: 20 December 2021 | Revised: 19 March 2022 | Accepted: 5 May 2022 | Published: 24 May 2022

Abstract

Hepatocellular carcinoma (HCC) is rarely associated with autoimmune paraneoplastic syndromes. We report a case of anti-transcriptional intermediary factor-1 gamma (TIF1- γ)-positive dermatomyositis (DM) as clinical presentation of HCC recurrence in a 72-year-old male patient admitted to our hospital due to fatigue, myalgia, and typical skin rash. His medical history was notable for hepatitis C-related cirrhosis, successful treatment with direct-acting antiviral agents, and previously efficacious treatment of HCC. Laboratory testing showed significant rhabdomyolysis with anti-TIF1- γ antibodies at high titer, and DM was diagnosed. After a careful diagnostic workup, HCC recurrence was diagnosed. After first-line corticosteroid treatment, azathioprine and intravenous immunoglobulin treatments were administered; unfortunately, he mounted only partial response. Owing to the compromised performance status, no HCC treatment was feasible, and, according to international guidelines, he received only best supportive care. Here, we discuss the diagnostic, prognostic, and pathogenic roles of anti-TIF1- γ antibodies associated with paraneoplastic DM and the scant literature data on its occurrence in HCC patients. Considering the TIF1 gene family's established role in oncogenesis, we also review the role of TIF1- γ as a tumor-related neantigen, leading to the development of clinically overt anti-TIF1- γ antibodies-positive DM.

Citation of this article: Ferronato M, Lalanne C, Quarneti C, Cevolani M, Ricci C, Granito A, *et al.* Paraneoplastic Anti-Tif1-

gamma Autoantibody-positive Dermatomyositis as Clinical Presentation of Hepatocellular Carcinoma Recurrence. *J Clin Transl Hepatol* 2023;11(1):253–259. doi: 10.14218/JCTH.2021.00573.

Introduction

Hepatocellular carcinoma (HCC) is the fifth most common cancer and the third most frequent cause of cancer-related death worldwide, with more than 900,000 new cases and more than 800,000 deaths in 2020 alone. Many patients have no symptoms related to the tumor, especially among those who have been undergoing regular surveillance and in whom HCC is detected at an early stage.¹ Limited data are available on the prevalence of paraneoplastic syndromes in HCC patients. However, the most frequently reported are hypercholesterolemia, hypoglycemia, hypercalcemia, and erythrocytosis.^{2–4} Other rarer conditions include erythema nodosum, polyarthritides, carcinoid syndrome, hemophagocytic syndrome, and porphyria cutanea tarda.^{5–8} It has been speculated that these syndromes might arise from tumor secretion of hormones, peptides, or cytokines, as well as immune cross-reactivity between malignant and normal tissues and are not directly related to the physical effects of the primary or metastasis tumors.⁵

The association between HCC and dermatomyositis (DM) has so far been sparsely reported (Table 1).^{9–20} We, herein, describe a case of a newly diagnosed and immunologically well-characterized paraneoplastic DM as the clinical presentation of recurrent HCC.

Case report

We report the case of a 72-years-old male patient admitted to our Internal Medicine and Immunorheumatology Unit in September 2020 due to severe fatigue, widespread myalgia, pain in his right shoulder exacerbated by movement, and itching.

The patient's medical history included hepatitis C virus

Keywords: Dermatomyositis; Anti-transcriptional intermediary factor-1 gamma (tif1- γ) antibodies; Hepatocellular carcinoma; Paraneoplastic syndrome.

Abbreviations: AFP, Alpha-fetoprotein; ANA, antinuclear antibodies; ANCA, anti-neutrophil cytoplasmic antibodies; BCLC, Barcelona Clinic Liver Cancer Staging System; CEUS, contrast-enhanced ultrasound; DM, dermatomyositis; HCC, hepatocellular carcinoma; TIF1- γ , transcriptional intermediary factor-1 gamma; TACE, trans-arterial chemoembolization.

***Correspondence to:** Alessandro Granito, Division of Internal Medicine, Hepatobiliary and Immunoallergic Diseases, IRCCS Azienda Ospedaliero-Universitaria di Bologna; Department of Medical and Surgical Sciences, University of Bologna, Via Albertoni 15, Bologna 40138, Italy. ORCID: <https://orcid.org/0000-0002-0637-739X>. Tel: +39-51-2142214, Fax: +39-51-2142725, E-mail: alessandro.granito@unibo.it

Table 1. Reported cases of DM in HCC patients, identified through literature review

Study	Etiology of underlying liver disease	Age	Sex	Autoantibody	Reference
1. Léaute-Labrière <i>et al</i>	HCV and HBV –ve ^o	14	M	ANA +ve	9 [^]
2. Gomez <i>et al</i>	HCV	73	M	ANA and anti-Jo-1 +ve	10
3. Inuzuka <i>et al</i>	HCV	51	M	Negative	11*
4. Cheng <i>et al</i>	HBV	50	F	Not reported	12
5. Kee <i>et al</i>	HCV	71	M	ANA +ve	13
6. Toshikuni <i>et al</i>	HCV	79	F	ANA +ve	14
7. Apostolidis <i>et al</i>	Alcoholic	61	M	Not reported	15
8. Kee <i>et al</i>	HBV	58	M	ANA +ve	16
9. Yang <i>et al</i>	HBV	55	M	ANA and SSA-Ro +ve	17
10. Miyata <i>et al</i>	HCV and HBV –ve ^o	61	M	Negative	18
11. Chou <i>et al</i>	HBV/Alcohol	55	M	ANA +ve	19
12. Han <i>et al</i>	HBV	62	M	Negative	5

[^]This patient had fibrolamellar HCC; ^oNo evidence of underlying liver disease; *This patient also developed an acquired ichthyosis. ANA, antinuclear antibodies; DM, dermatomyositis; HCC, hepatocellular carcinoma.

(HCV)-related cirrhosis that had been successfully treated 5 years earlier with direct-acting antiviral agents (ledipasvir/sofosbuvir). After the antiviral treatment, owing to the cirrhotic stage, he continued the imaging surveillance program. In April 2016, an HCC nodule (1.8 cm) was diagnosed at segment IV and successfully treated with percutaneous radiofrequency ablation. In March 2020, during the follow-up, a small recurrent HCC nodule (1.5 cm) was diagnosed at segment VI and treated with trans-arterial chemoembolization (TACE). There was no imaging evidence of persistent/recurrent HCC at the scheduled 1-month and 3-month imaging follow-up nor during the regularly programmed 6-month imaging follow-up after TACE. Alpha-fetoprotein (AFP) serum levels during the follow-up were persistently normal.

Physical examination revealed poikiloderma in photo-exposed areas of the face, upper back (“shawl sign”), and a rash on the anterior neck and upper chest (“V-sign”) associated with edema of the upper limbs and scratching injuries. The patient also presented symmetric and proximal muscle weakness, weak osteotendinous reflexes of the upper limbs, and muscle tenderness of the right shoulder.

At the clinical presentation, the patient’s laboratory data were as follows: aspartate aminotransferase (AST) 493 U/L [upper normal level (UNL) 50 U/L]; alanine aminotransferase (ALT) 94 U/L (UNL <50 U/L); gamma-glutamyl transferase (γ GT) 82 U/L (UNL <55 U/L); alkaline phosphatase 88 U/L (UNL <120 U/L); lactate dehydrogenase (LDH) 631 U/L (UNL 248 U/L), aldolase 59 U/L (UNL 7.6 U/L); creatinine kinase 10.906 U/L (UNL 170 U/L); and C-reactive protein 6.17 mg/dL (UNL 0.5 mg/dL). Findings for HCV RNA, HBsAg and HBV-DNA were negative.

Findings for anti-nuclear antibodies (ANAs), anti-double-stranded-DNA, anti-U1RNP, anti-Sm, anti-SSA, anti-SSB, anti-Scl 70, anti-Jo1, anti-PCNA, anti-PM-Scl, anti-ribosomal-P-protein, anti-CENP-B, anti-fibrillarine, anti-RNA polymerase-III and anti-neutrophil cytoplasmic antibodies (ANCA) were negative. Of relevance, a comprehensive immunoblot assay (EUROLINE Autoimmune Inflammatory Myopathies DL 1530-5001-4 G; Euroimmun, Lübeck, Germany) for testing autoantibodies direct against a wide range of myositis-specific antigens (Mi-2 α , Mi-2 β , TIF1 γ , MDA5, NXP2, SAE1, Ku, PM-Scl100, PM-Scl75, JO-1, SRP, PL-7, PL-12, EJ, OJ, Ro-52, cN-1A) revealed anti-TIF1 γ antibody

positivity at high titer, while the findings for other myositis-related autoantibodies were all negative.

Skin biopsy showed thinned epidermis, vascular alteration at the dermo-epidermal junction, edema of papillar derma, perivascular lymphocytic infiltrate, and mucin deposition in the papillar and medium derma (Fig. 1). Electromyography revealed muscle-related features consistent with a myopathic pattern. According to the Bohan and Peter criteria (Table 2),²⁰ DM was diagnosed and treatment with prednisone (1 mg/Kg) was started. A gradual decrease of serum muscle enzyme levels was observed after steroid treatment (Fig. 2).

Re-testing for HCV RNA again produced negative results; to exclude a paraneoplastic origin of DM, a careful imaging workup was performed. In September 2020, a total body contrast-enhanced CT scan did not reveal cancer. In particular, no evidence of recurrent/residual HCC was detected.

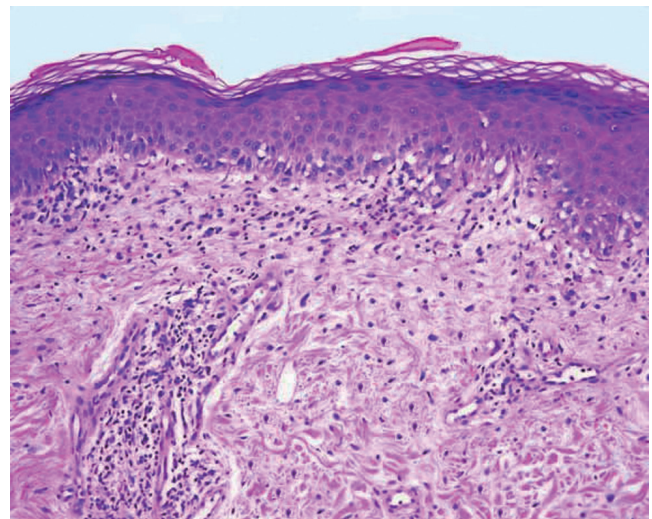


Fig. 1. Skin biopsy. Hematoxylin-eosin staining showing superficial and perivascular infiltrate predominantly of lymphocytes, vacuolar alteration at the dermo-epidermal junction, and papillary dermis edema. The basement membrane is thickened, and there is an increased connective-tissue mucin (magnification 200 \times).

Table 2. Presence of defined diagnostic criteria supporting the diagnosis of DM in the described patient

Diagnostic criteria	
1. Symmetric proximal muscle weakness	✓
2. Elevation of serum skeletal muscle enzymes*	✓
3. The electromyographic triad [^]	✓
4. Muscle biopsy abnormalities [§]	n.p.
5. Typical skin rash of DM [@]	✓

*Including creatine kinase, aldolase, serum glutamate oxaloacetate, and pyruvate transaminases, lactate dehydrogenase; [^]Short, small, polyphasic motor unit potentials; fibrillations, positive sharp waves, and insertional irritability; bizarre, high-frequency repetitive discharges; [§]Degeneration, regeneration, necrosis, phagocytosis, and an interstitial mononuclear infiltrate [@]including a heliotrope rash and Gottron's sign/papules. The diagnosis of DM is considered definite, probable, and possible when skin rash is associated with 3, 2, or 1 muscular criteria, respectively, according to Bohan and Peter's criteria.²⁰ n.p., not performed; DM, dermatomyositis.

The AFP serum level was within the normal range. Muscle strength and skin lesions' recovery was incomplete, and a few weeks later, the patient complained of dysphagia.

One month after the start of immunosuppressive therapy, he was admitted again to our Unit for aspiration pneumonia and ascites. He was treated with piperacillin/tazobactam, albumin infusion, and furosemide.

Fiberoptic Endoscopic Evaluation of Swallowing (FEES) showed complete dysphagia, so parenteral nutrition was started. For severe DM-related symptoms, immunosuppressive treatment with prednisone 1 mg/kg was continued, and treatment with intravenous immunoglobulin (IVIG) 0.4 g/kg/die for 5 days was begun.

In October 2020, a contrast-enhanced ultrasound (CEUS) of the abdomen showed a focal liver lesion of segment II (13x15 mm) characterized by arterial phase hyperenhancement and wash-out in portal phase [CEUS-Liver Imaging Reporting and Data System (LI-RADS) LR-5] (Fig. 3A, B) and hilar metastatic lymphadenopathy (20 mm x 35 mm; Fig. 3C). According to the American College of Radiology

and the international guidelines on diagnosis and management of HCC, a diagnosis of HCC was made.²¹⁻²⁴

According to the Barcelona Clinic Liver Cancer Staging System (BCLC), the patient had an advanced HCC stage (BCLC-C).²⁵ Treatment of HCC could not be performed because of the patient's poor physical conditions (Performance Status 3 according to The Eastern Cooperative Oncology Group score). We continued immunosuppressive treatment with prednisone, gradually tapered, and initiated azathioprine 50 mg/day as a steroid-sparing immunosuppressive agent, along with a monthly infusion of IVIG (2 g/kg).

At the last follow-up, after 12 months, the abdominal CT showed HCC intrahepatic (new lesions) and extrahepatic (enlargement of hepatic hilar lymph node and newly detected abdominal lymph nodes) disease progression (Fig. 4), with the patient's clinical conditions deteriorating rapidly.

Discussion

DM is an idiopathic inflammatory myopathy, featuring proximal skeletal muscle weakness and evidence of muscle inflammation associated with a characteristic rash. Cutaneous manifestations more commonly precede muscle weakness and may also develop in the absence of detectable muscle disease. DM is also associated with inflammatory arthritis, interstitial lung disease, the Raynaud phenomenon, and presence of autoantibodies.²⁶ Population-based cohort studies from several countries and metaanalyses have confirmed the increased risk of cancer among patients with inflammatory myopathies, mainly DM. In fact, up to one-third of cases are paraneoplastic.²⁷⁻³¹

Malignancy can be diagnosed before, simultaneously to, or after the diagnosis of DM, and adenocarcinomas of the cervix, lung, ovaries, pancreas, bladder, and stomach account for approximately 70% of the cancers associated with inflammatory myopathies.^{32,33} On the contrary, the association of DM with HCC is infrequent, and there are only very few case reports describing HCC-related DM (Table 1). In all described patients, DM partially improved under corticosteroid treatment. However, each patient's prognosis was

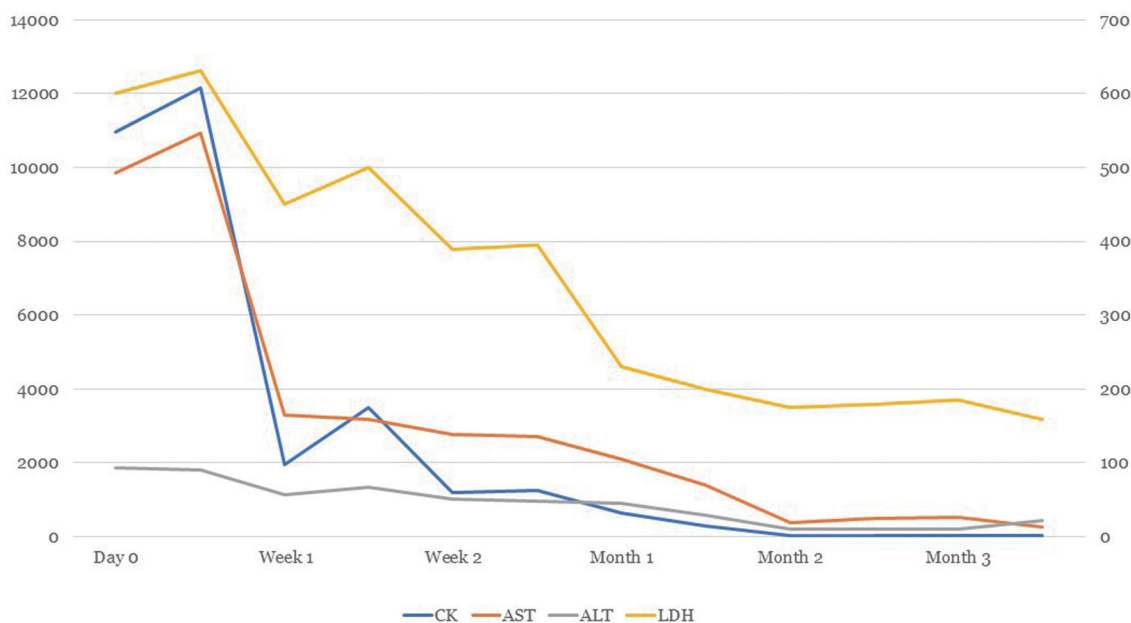


Fig. 2. Laboratory tests when under immunosuppressive therapy. Left axis represents creatine-kinase (U/L); right axis represents AST, ALT and LDH (U/L).

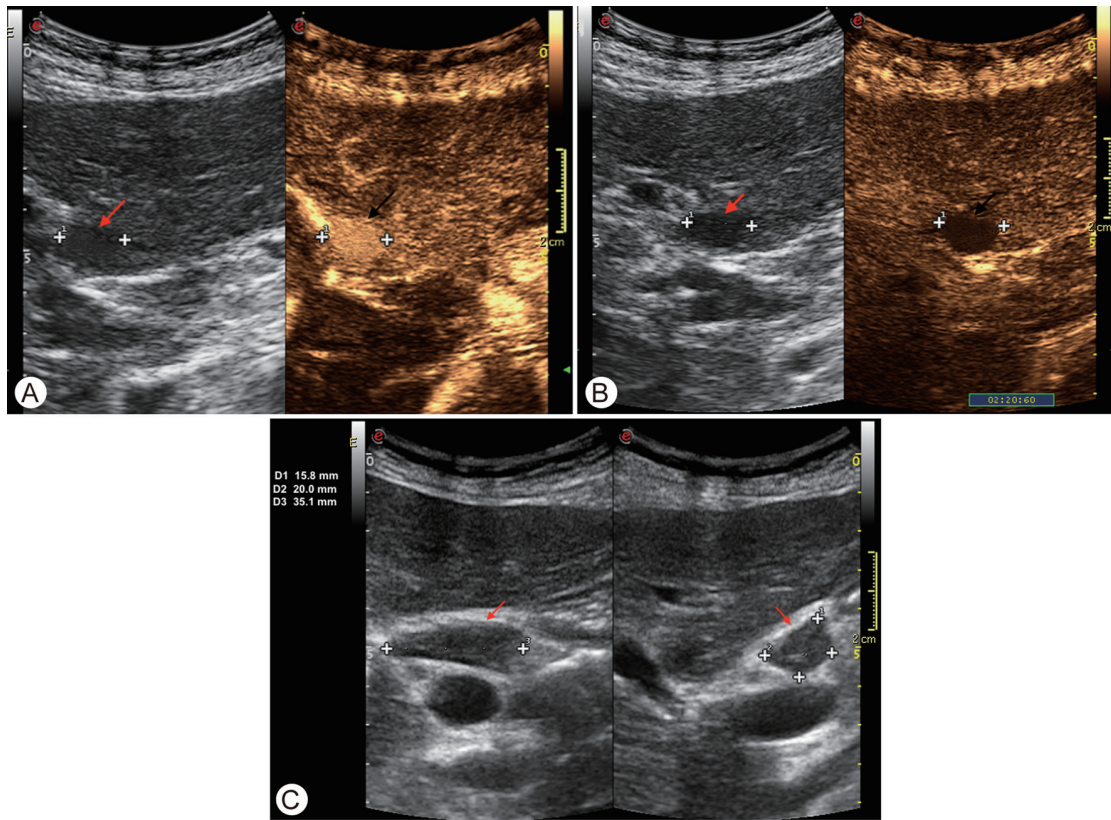


Fig. 3. CEUS features of the HCC nodule at segment II (CEUS LI-RADS LR5). (A) CEUS arterial phase showing hyperenhancement of the nodule. (B) CEUS late phase showing wash-out of the nodule. (C) Hilar metastatic lymphadenopathy (20 mm x 35 mm). CEUS, contrast-enhanced ultrasound; HCC, hepatocellular carcinoma.

poor due to tumor progression or recurrence. Of potential interest, in almost all cases of HCC-associated DM above-mentioned, patients had HBV and/or HCV as the etiology of underlying liver disease. According to this association, a DM

induction linked to viral infection has been speculated.^{5,13} In our case, there was no evidence of HCV recurrence after 5 years of successful antiviral therapy. Further, given that autoimmune extrahepatic HCV-related manifestations

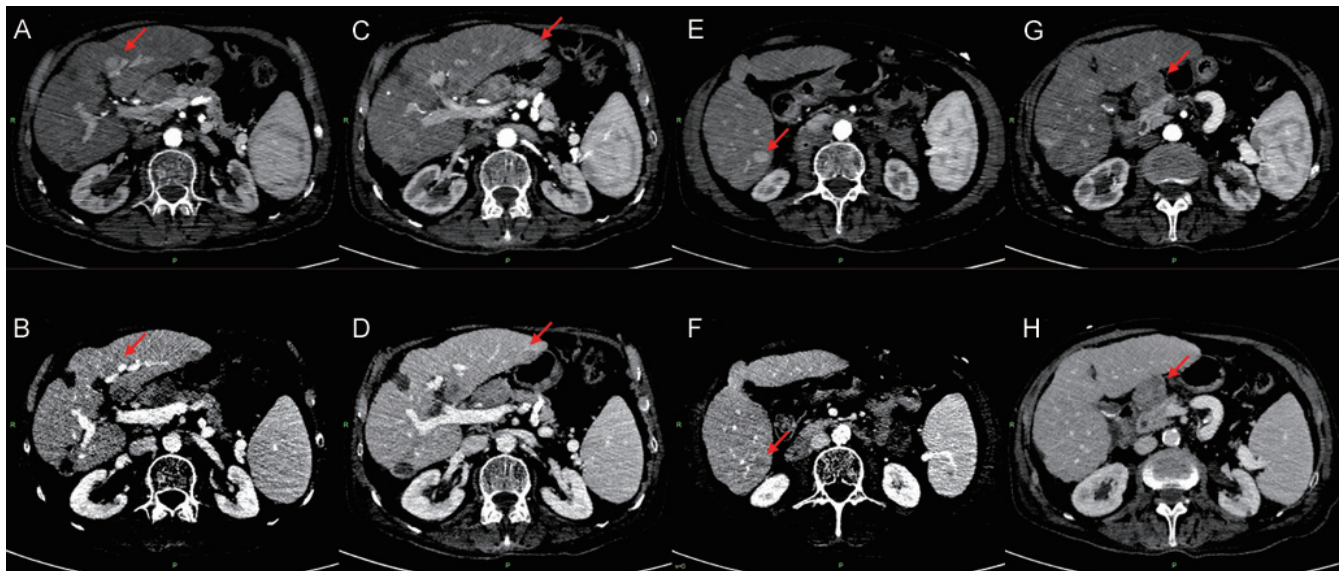


Fig. 4. Abdominal contrast-enhanced computed tomography. (A-B) Enlargement of segment II lesion (arrow). (B-C) New intrahepatic lesions at segment II (arrow). (D-E) Segment VI (arrow). (F-G) Extrahepatic HCC progression, characterized by enlargement of hepatic hilar lymph node (arrow). Arterial (A, C, E, G) and venous (B, D, F, H) phases are shown. HCC, hepatocellular carcinoma.

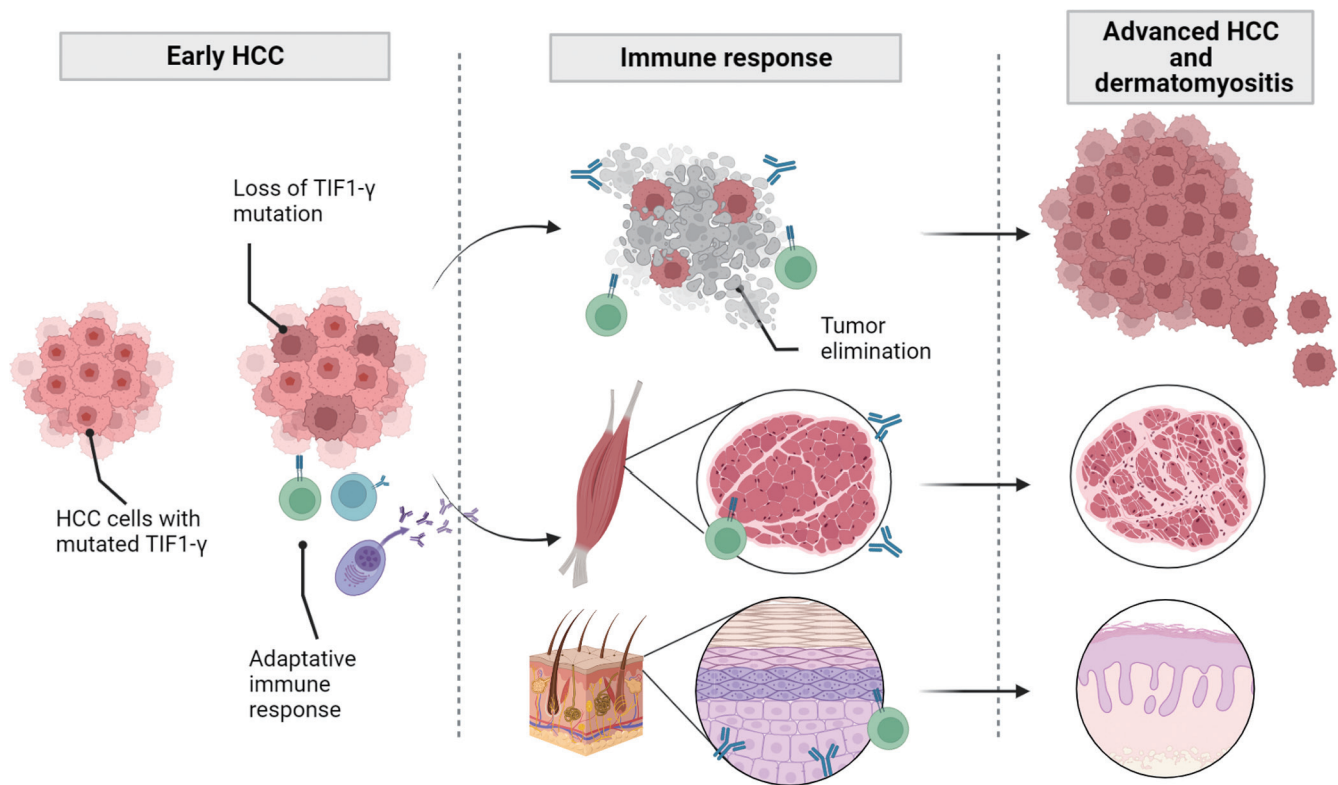


Fig. 5. Hypothetical mechanisms of the pathogenesis that underlie the association between HCC and TIF1- γ -positive DM. Mutations develop in the TIF1 genes of HCC cells which could elicit an immune response (anti-TIF1 γ antibodies) against the resulting mutated protein (tumor neoantigen). The cross-reactivity to the wild-type antigen could injure specific tissues, such as skin and muscle, leading to clinically overt DM. DM, dermatomyositis; HCC, hepatocellular carcinoma; TIF1- γ , transcriptional intermediary factor-1 gamma.

are generally mitigated by antiviral treatment, we believe that in our patient DM can be considered as a pure paraneoplastic manifestation, in line with other paraneoplastic DM reported in the literature.³⁴ Of interest, DM has never been previously immunologically characterized as anti-TIF1- γ antibody positive in HCC and, of clinical relevance, has never been described as the clinical presentation of tumor recurrence after prior proven curative treatment.

Serum autoantibodies that confer a positive risk of malignancy are the ones directed to anti-TIF1- γ (anti-p155, anti-p155/140) and to nuclear matrix protein (NXP)-2 (anti-MJ or anti-p140), as they are present in 83% of patients with cancer-associated DM.^{35,36} In DM patients with antibodies to TIF1- γ , those harboring a malignancy range from 42% to 100%, depending on the study.³⁶ Research into paraneoplastic syndromes has always been considered a good way to shed light on tumor development, maintenance, and proliferation.

Human TIF1- γ , also known as ectodermin or tripartite motif (TRIM) 33, is encoded by the TRIM33 gene, located on the p13 band of the short arm of chromosome 1. TIF1- γ has been shown to serve as a transcription regulator, a tumor suppressor, a mediator of DNA damage repair, and an E3 ligase that modulates TGF- β signaling. However, mechanisms leading to anti-TIF1- γ autoantibody appearance and the DM development in patients with cancer have not been firmly established.^{37,38}

Ding *et al.*³⁷ demonstrated the dual role of TIF1- γ in the HCC oncogenesis, which relies on the role of TGF- β under different cellular contexts; for example, in the early stage of HCC, TIF1- γ promotes cell growth by reducing the cytostatic effect of TGF- β , while in the advanced stage of HCC,

TIF1- γ acts as a tumor suppressor gene as it inhibits TGF- β -induced epithelial-mesenchymal transition and TGF- β /Smad downstream metastatic signaling. Importantly, HCC patients with low TIF1- γ expression had shorter overall survival and higher recurrence rates than those with high TIF1- γ expression. TIF1- γ down-regulation was correlated with loss of tumor encapsulation, vascular invasion, malignant differentiation, and a more advanced BCLC stage.³⁷

In TIF1- γ cancer-associated DM, it has been hypothesized that cancer is the underlying driver of DM and that TIF1- γ may function as a tumor autoantigen. Recent findings support the hypothesis that tumors from paraneoplastic anti-TIF1- γ -positive patients show increased genetic alterations, such as mutations and loss of heterozygosity in TIF1 genes. In the context of a high expression of TIF1- γ in the patients' tumor, muscle, and skin, these genetic alterations may be key to understanding the genesis of paraneoplastic myositis. Therefore, aberrant TIF1- γ in cancer cells might develop neoantigens targeted by the immune response, which cross-react with the wild-type skin and muscle antigens (Fig. 5).^{38,39} The latter can be effective by eradicating tumor cells without clinical symptoms or unsuccessful with tumor development. The anti-tumor immune response cross-reacts with wild-type TIF1- γ in muscle and skin cells. The high content of TIF1- γ antigens in muscle and skin might explain why the anti-tumor response leads to the clinical manifestation of DM.

However, a genetic predisposition could also explain why not all tumors with a dysregulated expression of TIF1- γ lead to DM. It has been previously reported that myositis is associated with specific HLA sequences (HLA-DRB1*0301 and HLA-DQA1*0501 in Caucasians), and TIF1- γ autoantibodies

have been associated with HLA-DQA1*0301. In addition, a significant HLA association was observed in patients with TIF1- γ autoantibodies with the HLA DQB1*02 allele group.³⁴

From an overall perspective, we can hypothesize a tumor-induced autoimmune pathophysiology of TIF1- γ paraneoplastic DM, as shown in Figure 5. It is therefore conceivable that at the time of first occurrence (April 2016) and recurrence (March 2020) of HCC, the TIF1 mutation was not yet present, whereas its later acquisition led to the clinical onset of DM (September 2020) with subsequent imaging evidence of tumor recurrence (October 2020). Of clinical relevance, a negative prognostic impact of paraneoplastic DM has been previously reported, as our case would confirm.^{2,3}

In conclusion, we describe for the first time a case of paraneoplastic anti-TIF1- γ antibody-positive DM as a clinical presentation of recurrent HCC. The development of tumor-induced autoantibodies further evidences the prominent pathogenic role and the complexity of immunological mechanisms of the tumor microenvironment driving tumor growth and spread.

Funding

None to declare.

Conflict of interest

AG has been an editorial board member of *Journal of Clinical and Translational Hepatology* since 2021. The other authors have no conflict of interests related to this publication.

Author contributions

Study conception and design (MF, AG), acquisition of data (MF, CL, CQ, MC, CR, AG, LM, ML), analysis and interpretation of data (MF, AG, LM), drafting of the manuscript (MF), and critical revision of the manuscript for important intellectual content (MF, AG, LM).

Ethical statement

Written informed consent was obtained from the patient for publication of this case report and the accompanying images.

References

- [1] Frankl L, Frenette C. Hepatocellular Carcinoma: Downstaging to Liver Transplantation as Curative Therapy. *J Clin Transl Hepatol* 2021;9(2):220–226. doi:10.14218/JCTH.2020.00037, PMID:34007804.
- [2] Luo JC, Hwang SJ, Wu JC, Lai CR, Li CP, Chang FY, et al. Clinical characteristics and prognosis of hepatocellular carcinoma patients with paraneoplastic syndromes. *Hepatogastroenterology* 2002;49(47):1315–1319. PMID:12239934.
- [3] Qu Q, Wang S, Chen S, Zhou L, Rui JA. Prognostic role and significance of paraneoplastic syndromes in hepatocellular carcinoma. *Am Surg* 2014; 80(2):191–196. PMID:24480222.
- [4] Huh UY, Kim JH, Kim BH, Nam KD, Jang JY, Kim NH, et al. [The incidence and clinical significance of paraneoplastic syndromes in patients with hepatocellular carcinoma]. *Korean J Hepatol* 2005;11(3):275–283. PMID:16177554.
- [5] Han J, Wang S, Kwong TNY, Liu J. Dermatomyositis as an extrahepatic manifestation of hepatitis B virus-related hepatocellular carcinoma: A case report and literature review. *Medicine (Baltimore)* 2018;97(33):e11586. doi:10.1097/MD.00000000000011586, PMID:30113453.
- [6] Nwokediuko SC, Uchenna I, Esther O, Okechukwu O, Augustine O, Charity A. Relatively Long Survival in Hepatocellular Carcinoma Presenting With Carcinoid Syndrome. *Gastroenterology Res* 2010;3(1):46–49. doi:10.4021/gr2010.02.171w, PMID:27956985.
- [7] Glinkov S, Krasnaliev I, Atanasova M, Arnaudov P, Kirov K, Glinkova V. Hepatocellular carcinoma associated with paraneoplastic erythema nodosum and polyarthritides. *J Hepatol* 2003;39(4):656–657. doi:10.1016/s0168-8278(03)00248-4, PMID:12971982.
- [8] Sancho MT, Martín JC, García J, Sierra FJ, Lavilla P, Gil Aguado A. [Hepatitis C virus infection in a patient with porphyria cutanea tarda and hepatocarcinoma]. *Rev Clin Esp* 1996;196(10):725–726. PMID:9005481.
- [9] Léaute-Labrèze C, Perel Y, Taieb A. Childhood dermatomyositis associated with hepatocarcinoma. *N Engl J Med* 1995;333(16):1083. doi:10.1056/NEJM199510193331615, PMID:7675068.
- [10] Gomez A, Solans R, Simeon CP, Selva A, Garcia F, Fonollosa V, Vilardell M. Dermatomyositis, hepatocarcinoma, and hepatitis C: comment on the article by Weidensaul et al. *Arthritis Rheum* 1997;40(2):394–395. doi:10.1002/art.1780400232, PMID:9041958.
- [11] Inuzuka M, Tomita K, Tokura Y, Takigawa M. Acquired ichthyosis associated with dermatomyositis in a patient with hepatocellular carcinoma. *Br J Dermatol* 2001;144(2):416–417. doi:10.1046/j.1365-2133.2001.04040.x, PMID:11251586.
- [12] Cheng TI, Tsou MH, Yang PS, Sung SM, Chuang VP, Sung JL. Dermatomyositis and erythrocytosis associated with hepatocellular carcinoma. *J Gastroenterol Hepatol* 2002;17(11):1239–1240. doi:10.1046/j.1440-1746.2002.t01-1-02851.x, PMID:12453288.
- [13] Kee KM, Wang JH, Lee CM, Changchien CS, Eng HL. Chronic hepatitis C virus infection associated with dermatomyositis and hepatocellular carcinoma. *Chang Gung Med J* 2004;27(11):834–839. PMID:15796260.
- [14] Toshikuni N, Torigoe R, Mitsunaga M, Omoto A, Nakashima K. Dermatomyositis associated with hepatocellular carcinoma in an elderly female patient with hepatitis C virus-related liver cirrhosis. *World J Gastroenterol* 2006; 12(10):1641–1644. doi:10.3748/wjg.v12.i10.1641, PMID:16570363.
- [15] Apostolidis L, Kahlert C, Siegmund A, Thom R, Horstmann S, Jäger D, Lordick F. Remission of paraneoplastic dermatomyositis associated with hepatocellular carcinoma under prednisolone and azathioprin, and concomitant sorafenib. *Onkologie* 2009;32(1-2):50–53. doi:10.1159/000183750, PMID:19209021.
- [16] Kee SJ, Kim TJ, Lee SJ, Cho YN, Park SC, Kim JS, Kim JC, Kang HS, Lee SS, Park YW. Dermatomyositis associated with hepatitis B virus-related hepatocellular carcinoma. *Rheumatol Int* 2009;29(5):595–599. doi:10.1007/s00296-008-0718-1, PMID:18802699.
- [17] Yang SY, Cha BK, Kim G, Lee HW, Kim JG, Chang SK, Kim HJ. Dermatomyositis associated with hepatitis B virus-related hepatocellular carcinoma. *Korean J Intern Med* 2014;29(2):231–235. doi:10.3904/kjim.2014.29.2.231, PMID:24648807.
- [18] Miyata N, Emoto K, Dei Y, Tomiyasu K, Ishiyama R, Horie T, Sakai G, Tahara T. Paraneoplastic Dermatomyositis in Hepatocellular Carcinoma with Colonic Perforation: A Case Report. *Case Rep Oncol* 2016;9(3):547–553. doi:10.1159/000449370, PMID:27790119.
- [19] Chou JW, Lin YL, Cheng KS, Wu PY, Reanne Ju T. Dermatomyositis Induced by Hepatitis B Virus-related Hepatocellular Carcinoma: A Case Report and Review of the Literature. *Intern Med* 2017;56(14):1831–1837. doi:10.2169/internalmedicine.56.7595, PMID:28717078.
- [20] Bohan A, Peter JB. Polymyositis and dermatomyositis (first of two parts). *N Engl J Med* 1975;292(7):344–347. doi:10.1056/NEJM197502132920706, PMID:1090839.
- [21] European Association for the Study of the Liver. EASL Clinical Practice Guidelines: Management of hepatocellular carcinoma. *J Hepatol* 2018;69(1):182–236. doi:10.1016/j.jhep.2018.03.019, PMID:29628281.
- [22] American College of Radiology. CEUS-LI-RADS version 2017. Available from: <https://www.acr.org/-/media/ACR/Files/RADS/LI-RADS/CEUS-LI-RADS-2017-Core.pdf>.
- [23] Omata M, Cheng AL, Kokudo N, Kudo M, Lee JM, Jia J, et al. Asia-Pacific clinical practice guidelines on the management of hepatocellular carcinoma: a 2017 update. *Hepatol Int* 2017;11(4):317–370. doi:10.1007/s12072-017-9799-9, PMID:28620797.
- [24] Piscaglia F, Wilson SR, Lyschchik A, Cosgrove D, Dietrich CF, Jang HJ, et al. American College of Radiology Contrast Enhanced Ultrasound Liver Imaging Reporting and Data System (CEUS LI-RADS) for the diagnosis of Hepatocellular Carcinoma: a pictorial essay. *Ultraschall Med* 2017;38(3):320–324. doi:10.1055/s-0042-124661, PMID:28329875.
- [25] Reig M, Forner A, Rimola J, Ferrer-Fàbrega J, Burrel M, Garcia-Criado Á, et al. BCLC strategy for prognosis prediction and treatment recommendation: The 2022 update. *J Hepatol* 2022;76(3):681–693. doi:10.1016/j.jhep.2021.11.018, PMID:34801630.
- [26] Dalakas MC, Hohlfield R. Polymyositis and dermatomyositis. *Lancet* 2003;362(9388):971–982. doi:10.1016/S0140-6736(03)14368-1, PMID:14511932.
- [27] Pelosof LC, Gerber DE. Paraneoplastic syndromes: an approach to diagnosis and treatment. *Mayo Clin Proc* 2010;85(9):838–854. doi:10.4065/mcp.2010.0099, PMID:20810794.
- [28] Barnes BE, Mawr B. Dermatomyositis and malignancy. A review of the literature. *Ann Intern Med* 1976;84(1):68–76. doi:10.7326/0003-4819-84-1-68, PMID:1106291.
- [29] Sigurgeirsson B, Lindelöf B, Edhag O, Allander E. Risk of cancer in patients with dermatomyositis or polymyositis. A population-based study. *N Engl J Med* 1992;326(6):363–367. doi:10.1056/NEJM199202063260602, PMID:1729618.
- [30] Chow WH, Gridley G, Mellemejaer L, McLaughlin JK, Olsen JH, Fraumeni JF Jr. Cancer risk following polymyositis and dermatomyositis: a national cohort study in Denmark. *Cancer Causes Control* 1995;6(1):9–13. doi:10.1007/BF00051675, PMID:7718740.

- [31] Yang Z, Lin F, Qin B, Liang Y, Zhong R. Polymyositis/dermatomyositis and malignancy risk: a metaanalysis study. *J Rheumatol* 2015;42(2):282–291. doi:10.3899/jrheum.140566, PMID:25448790.
- [32] Hill CL, Zhang Y, Sigurgeirsson B, Pukkala E, Mellemkjaer L, Airio A, *et al*. Frequency of specific cancer types in dermatomyositis and polymyositis: a population-based study. *Lancet* 2001;357(9250):96–100. doi:10.1016/S0140-6736(00)03540-6, PMID:11197446.
- [33] Harada Y, Tominaga M, Itoh E, Kaieda S, Koga T, Fujimoto K, *et al*. Clinical Characteristics of Anti-TIF1- γ Antibody-Positive Dermatomyositis Associated with Malignancy. *J Clin Med* 2022;11(7):1925. doi:10.3390/jcm11071925, PMID:35407533.
- [34] Callen JP. The value of malignancy evaluation in patients with dermatomyositis. *J Am Acad Dermatol* 1982;6(2):253–259. doi:10.1016/s0190-9622(82)70018-0, PMID:7037882.
- [35] Wolstencroft PW, Fiorentino DF. Dermatomyositis Clinical and Pathological Phenotypes Associated with Myositis-Specific Autoantibodies. *Curr Rheumatol Rep* 2018;20(5):28. doi:10.1007/s11926-018-0733-5, PMID:29637414.
- [36] Fiorentino DF, Chung LS, Christopher-Stine L, Zaba L, Li S, Mammen AL, *et al*. Most patients with cancer-associated dermatomyositis have antibodies to nuclear matrix protein NXP-2 or transcription intermediary factor 1 γ . *Arthritis Rheum* 2013;65(11):2954–2962. doi:10.1002/art.38093, PMID:24037894.
- [37] Ding ZY, Jin GN, Wang W, Chen WX, Wu YH, Ai X, *et al*. Reduced expression of transcriptional intermediary factor 1 gamma promotes metastasis and indicates poor prognosis of hepatocellular carcinoma. *Hepatology* 2014;60(5):1620–1636. doi:10.1002/hep.27273, PMID:24954480.
- [38] De Vooght J, Vulsteke JB, De Haes P, Bossuyt X, Lories R, De Langhe E. Anti-TIF1- γ autoantibodies: warning lights of a tumour autoantigen. *Rheumatology (Oxford)* 2020;59(3):469–477. doi:10.1093/rheumatology/kez572, PMID:31883334.
- [39] Pinal-Fernandez I, Ferrer-Fabregas B, Trallero-Araguas E, Balada E, Martínez MA, Millisenda JC, *et al*. Tumour TIF1 mutations and loss of heterozygosity related to cancer-associated myositis. *Rheumatology (Oxford)* 2018;57(2):388–396. doi:10.1093/rheumatology/kex413, PMID:29149307.