

University of Groningen

Changes in perfusion, and structure of hippocampal subfields related to cognitive impairment after ECT

Van der A, Julia; De Jager, Jesca E.; van Dellen, Edwin; Mandl, René C.W.; Somers, Metten; Boks, Marco P.M.; Sommer, Iris E.C.; Nuninga, Jasper O.

Published in:
Journal of Affective Disorders

DOI:
[10.1016/j.jad.2023.01.016](https://doi.org/10.1016/j.jad.2023.01.016)

IMPORTANT NOTE: You are advised to consult the publisher's version (publisher's PDF) if you wish to cite from it. Please check the document version below.

Document Version
Publisher's PDF, also known as Version of record

Publication date:
2023

[Link to publication in University of Groningen/UMCG research database](#)

Citation for published version (APA):

Van der A, J., De Jager, J. E., van Dellen, E., Mandl, R. C. W., Somers, M., Boks, M. P. M., Sommer, I. E. C., & Nuninga, J. O. (2023). Changes in perfusion, and structure of hippocampal subfields related to cognitive impairment after ECT: A pilot study using ultra high field MRI. *Journal of Affective Disorders*, 325, 321-328. <https://doi.org/10.1016/j.jad.2023.01.016>

Copyright

Other than for strictly personal use, it is not permitted to download or to forward/distribute the text or part of it without the consent of the author(s) and/or copyright holder(s), unless the work is under an open content license (like Creative Commons).

The publication may also be distributed here under the terms of Article 25fa of the Dutch Copyright Act, indicated by the "Taverne" license. More information can be found on the University of Groningen website: <https://www.rug.nl/library/open-access/self-archiving-pure/taverne-amendment>.

Take-down policy

If you believe that this document breaches copyright please contact us providing details, and we will remove access to the work immediately and investigate your claim.

Downloaded from the University of Groningen/UMCG research database (Pure): <http://www.rug.nl/research/portal>. For technical reasons the number of authors shown on this cover page is limited to 10 maximum.



Changes in perfusion, and structure of hippocampal subfields related to cognitive impairment after ECT: A pilot study using ultra high field MRI

Julia Van der A^{a,1}, Jesca E. De Jager^{b,1,*}, Edwin van Dellen^{a,c}, René C.W. Mandl^a, Metten Somers^a, Marco P.M. Boks^a, Iris E.C. Sommer^b, Jasper O. Nuninga^{a,b}

^a Department of Psychiatry, UMC Utrecht Brain Center, Utrecht University, Utrecht, the Netherlands

^b Department of Biomedical Sciences of Cells and Systems, Brain Center, University Medical Center, Groningen, the Netherlands

^c Department of Intensive Care Medicine, UMC Utrecht Brain Center, Utrecht University, Utrecht, the Netherlands

ARTICLE INFO

Keywords:

Electroconvulsive therapy
Depression
hippocampus
Diffusion
Perfusion
Cognition

ABSTRACT

Background: Electroconvulsive therapy (ECT) in patients with major depression is associated with volume changes and markers of neuroplasticity in the hippocampus, in particular in the dentate gyrus. It is unclear if these changes are associated with cognitive side effects.

Objectives: We investigated whether changes in cognitive functioning after ECT were associated with hippocampal structural changes. It was hypothesized that 1) volume increase of hippocampal subfields and 2) changes in perfusion and diffusion of the hippocampus correlated with cognitive decline.

Methods: Using ultra high field (7 T) MRI, intravoxel incoherent motion and volumetric data were acquired and neurocognitive functioning was assessed before and after ECT in 23 patients with major depression. Repeated measures correlation analysis was used to examine the relation between cognitive functioning and structural characteristics of the hippocampus.

Results: Left hippocampal volume, left and right dentate gyrus and right CA1 volume increase correlated with decreases in verbal memory functioning. In addition, a decrease of mean diffusivity in the left hippocampus correlated with a decrease in letter fluency.

Limitations: Due to methodological restrictions direct study of neuroplasticity is not possible. MRI is used as an indirect measure.

Conclusion: As both volume increase in the hippocampus and MD decrease can be interpreted as indirect markers for neuroplasticity that co-occur with a decrease in cognitive functioning, our results may indicate that neuroplastic processes are affecting cognitive processes after ECT.

1. Introduction

Major depression is a disabling mental disorder and currently the leading cause of disability worldwide (Friedrich, 2017). Electroconvulsive therapy (ECT) is considered the most effective therapy for major depression, with response rates ranging between 58 and 70 % (Dierckx et al., 2012; Fink, 2014; Haq et al., 2015; Pagnin et al., 2008) and response times superior to other available interventions (Fink, 2014; Husain et al., 2004). However, clinicians and patients may be reluctant to consider ECT, fearing associated cognitive impairments (Verwijk et al., 2017). These impairments are often – but not always- transient (Kolshus et al., 2017; Nuninga et al., 2018; Semkovska and McLoughlin,

2010; Vasavada et al., 2017); ECT thus comes with the risk of lasting side effects (Obbels et al., 2021). Cognitive impairments, especially memory deficits can be very distressing and limit the tolerability of ECT. Unfortunately, the underlying neurobiological mechanisms of these ECT-induced cognitive impairments remain poorly understood. A comprehensive understanding of these mechanisms is important as it might lead to new treatment options for reducing cognitive impairments, thereby enhancing acceptability and tolerability for patients and practitioners to use ECT.

Neuroimaging studies have consistently reported transient increases in hippocampal volume following ECT in patients with depression (Gbyl and Videbech, 2018; Nordanskog et al., 2010; Oltedal et al., 2018;

* Corresponding author at: University Medical Center Groningen, Cognitive Neuroscience Center, Antonius Deusinglaan 2, 9713 AW Groningen, The Netherlands.
E-mail address: j.e.de.jager@umcg.nl (J.E. De Jager).

¹ Shared first authorship.

<https://doi.org/10.1016/j.jad.2023.01.016>

Received 28 October 2022; Received in revised form 19 December 2022; Accepted 3 January 2023

Available online 6 January 2023

0165-0327/© 2023 The Authors. Published by Elsevier B.V. This is an open access article under the CC BY license (<http://creativecommons.org/licenses/by/4.0/>).

Wilkinson et al., 2017). Several studies suggest a relation between volume changes and clinical response in the hippocampus, most pronounced in the dentate gyrus (DG) (Cao et al., 2018; Nuninga et al., 2020a; Takamiya et al., 2019). Aside from the clinical relevance for the antidepressant outcome after ECT, volumetric changes might also be related to the cognitive side effects. Volume increase of the hippocampus co-occur with cognitive side effects and show a similar time course compared to the decrease in cognitive functioning (Argyelan et al., 2021; Bouckaert et al., 2016; Gbyl et al., 2021; Nuninga et al., 2018; Sackeim et al., 2007; Semkowska and McLoughlin, 2010; Takamiya et al., 2019; van Oostrom et al., 2018). We hypothesize that neuroplastic changes induced by ECT may also underly the cognitive deficits, as the extension and alteration of hippocampal neural circuits may disconnect memories that are not yet consolidated. Preclinical studies have shown that elevating neuroplasticity in adult mice was enough to induce forgetting of a recently stored memory (Akers et al., 2014). Thus, formation of new hippocampal connections interrupts the storage of new memories.

It is not possible to directly test this hypothesis in humans with major depression, but we can investigate associations between hippocampal structural changes and cognitive side-effects to test if there is indirect support for this theory. We therefore assessed clinical status, cognition and neuroanatomy of patients with major depression before and after ECT using ultra-high field magnetic resonance imaging (MRI). First, we examined the relationship between volume change of hippocampal subfields and cognitive impairment using a 7-T MRI sequence, which was designed for optimal measurement of hippocampal subfields. Second, we examined the relationship between changes in diffusion and perfusion characteristics of the hippocampus, and cognitive impairment using intravoxel incoherent motion (IVIM) data. IVIM imaging is a type of diffusion weighted imaging able to examine diffusion and perfusion characteristics of different types of tissue (Le Bihan, 2019; Le Bihan et al., 1988). Previous studies have shown that a decrease in diffusion and an increase in perfusion may reflect neuroplasticity by an increase in cell density and vascular density, respectively (Lee et al., 2014; Luo et al., 2020; Togao et al., 2018). In sum, we hypothesized that a decline in cognitive functioning is related to 1) an increase in volume of hippocampal subfields, and 2) increase in perfusion and decrease in diffusion characteristics of the hippocampi.

2. Material and methods

2.1. Sample

Patients eligible for ECT treatment, according to the Dutch Guidelines on Electroconvulsive therapy (van den Broek et al., 2010), were recruited at the Department of Psychiatry of the University Medical Centre Utrecht, the Netherlands. Patients were included if 1) they were 18 years and older and 2) had a diagnosis of unipolar or bipolar depression following the Diagnostic and Statistical Manual of Mental Disorders, Fourth Edition, Text Revision criteria (American Psychiatric Association, 2000). Exclusion criteria included: having received ECT treatment in six months prior to study inclusion, any major medical condition (e.g., coronary heart disease, chronic obstructive pulmonary disease), pregnancy and/or breastfeeding, brain pathology, history of stroke and MRI contraindications (e.g., claustrophobia, metallic implants).

The Medical Ethical Board of the University Medical Center Utrecht approved the study and all patients provided written informed consent. In total, 26 patients met the inclusion criteria. However, due to treatment with less than ten ECT sessions (one patient) and personal reasons (two patients), we included 23 patients in the study. Due to anxiety in the scanner (one patient, post ECT), scanning artifacts (six patients, two pre-ECT, four post-ECT) and not completing the IVIM scanning protocol (5 patients), we obtained 16 complete scan sets of the volumetric measurements and 11 complete scan sets for the IVIM measurements.

However, as the linear mixed model can handle missing data under the assumption that the data is missing at random, we were able to include patients with either a pre- or post-ECT scan as well.

2.2. ECT treatment procedure

ECT procedures were standardized as follows: treatments were administered twice a week for 5 consecutive weeks using a Thymatron System IV ECT device with bifrontotemporal electrode placing (900 mA current, stimulus intensity of 150 % of the titrated seizure threshold). To minimize variability, the post measurement was scheduled after the 10th ECT session. Prior to delivering the electrical current, an anesthetic agent (e.g. etomidate 1.5 mg/kg) and succinylcholine (1.0 mg/kg) as a muscle relaxant. A blood pressure cuff was placed on one of the arms to prevent the muscle relaxant from entering, allowing the length of the provoked seizure to be observed visually and by an electromyogram. A minimum motor seizure duration of 20 s had to be observed, following the Dutch Guidelines on Electroconvulsive Therapy (van den Broek et al., 2010). If the motor seizure duration was <20 s, a new stimulus was given with an energy increase of 5–10 %. No more than three attempts were made per session. None of the patients had seizures <20 s on an ECT treatment day.

2.3. Assessments

Patients were assessed prior to the first ECT treatment (pre-ECT) and after 10 ECT sessions (post-ECT; within 48 h following the 10th ECT session). We chose to scan our participants after 10 sessions to keep the dosage of the treatment equal between participants. This results in a lower response rate. If clinically indicated, patients received additional treatment after the post-ECT visit. Patients were allowed to continue their medications as prescribed by their treating clinician and dosage was kept stable during study participation.

2.3.1. Clinical assessment

The 17-item version of the Hamilton Depression Rating Scale (HAM-D) was used at both timepoints for the assessment of depression severity (Hamilton, 1960). The HAM-D is an instrument commonly used to assess changes in symptoms of depression.

2.3.2. Cognitive assessment

Patients were assessed on neurocognitive functioning by a trained clinician or researcher. To estimate premorbid IQ, the Dutch adaptation of the National Adult Reading Test was used (Schmand et al., 1992). Neurocognitive functioning was assessed using a large neurocognitive test battery, for an overview see Nuninga et al. (2018). However, based on our previous study using the same sample, we only included tests that showed a significant decrease in performance after ECT (Nuninga et al., 2018), as we were interested in the relation between cognitive decline and change in MRI parameters. Those included verbal and auditory memory, letter-, and semantic verbal fluency. Verbal and auditory memory was assessed using the Dutch adaptation of the Rey Auditory Verbal Learning Test (D-RAVLT; Van der Elst et al., 2005). This included three sub-tests: immediate recall (sum of 5 trials), delayed recall and recognition. Two versions were used to minimize learning effects. The Verbal Fluency Task was used to measure letter fluency (“N” and “A”) and semantic verbal fluency (“profession” and “animals”; Mulder et al., 2006).

2.4. Image acquisition

Participants were scanned on a 7 Tesla Philips MRI scanner (Philips Healthcare, Best, The Netherlands) using a 32-channel head coil (Nova Medical Wilmington, MA, USA). First, a 3D T1-weighted TFE scan was acquired (voxel size = 1 mm isotropic; TR/TE = 5.5/2.04 ms; flip angle = 6°; field of view (FOV) 256 × 256 × 190; number of slices 190;

acquisition time 125 s). Second, a 3D T2-weighted TSE scan was obtained (voxel size = 0.286 × 0.286 mm in plane resolution, 2 mm slice thickness; TR/TE = 3600/60 ms; flip angle = 90°; FOV 60 × 220 × 220; number of slices 30; acquisition time 494 s). To increase the accuracy and reliability of the repeated measures using this highly anisotropic scan, we ensured that the FOV was equal on both acquisition timepoints using SmartExam planning. This is a fully automated planning method to place the FOV on the brain based on several anatomic characteristics of the head, which are extracted from a T1-weighted scan acquired before each scan. Third, IVIM data was obtained (voxel size = 1.5 mm isotropic; FOV 160 × 160 × 30; echo-planar imaging factor = 55; TR/TE: 3605/60.25 ms; flip angle 90°; no gap; no cardiac gating) with 46 vol consisting of one b = 0 s/mm² volume and 15 b-weighted volumes scanned in three orthogonal directions per b-value: 2, 4, 6, 8, 10, 25, 50, 75, 100, 200, 300, 400, 600, 800, 1000 s/mm².

2.5. Data processing

MRI data, including volumetric data of the hippocampal subfields, were processed using FSL (5.0.9; Smith et al., 2004), MRtrix3 (Tournier et al., 2012), the Automated Segmentation of Hippocampal Subfields (ASHS) (Yushkevich et al., 2015) pipeline and ANTs tools (Avants et al., 2011). For a detailed description, see Nuninga et al. (2020a). Briefly, the T2-weighted scan is aligned to the T1-weighted scan using rigid registration. The T1-weighted scan is then co-registered to the atlas template available in ASHS to define hippocampal subfields. Subfields included in the atlas template were the Brodmann area 35 and 36, Cornu Ammonis 1–3 (CA 1–3), Collateral sulcus, DG, entorhinal cortex and subiculum. Volumetric data of all subfields were imported into R (version 3.6.2) for statistical analysis.

According to the IVIM theory, IVIM data is sensitive to both diffusion and blood microcirculation (i.e., perfusion; Le Bihan, 2019) and can be disentangled from each other using different b-values to calculate the parameter maps. IVIM imaging generally results in a diffusion parameter and two perfusion parameters. Mean diffusivity (MD) is the slow diffusion component, reflecting random motion of water molecules and is calculated using high b-values (600–1000 s/mm²). As diffusion is restricted by cell density, a decrease in MD would reflect increase of cell density, making it a valid proxy to study neuroplasticity in hippocampal subfields. At low b-values (0–200 s/mm²), perfusion measurements can be isolated, resulting in two perfusion parameters: perfusion fraction *f* and the pseudo diffusion component *D**. *f* reflects the fraction of intravascular microcirculation within the volume of interest within a voxel and *D** reflects the intravascular collective movement of microcirculation within a voxel (Neil et al., 1994). Previous studies have shown that both perfusion parameters correlate with vascular density (Lee et al., 2014; Togao et al., 2018). Therefore, if angiogenesis occurs in the hippocampus after ECT, *f* and *D** are expected to increase.

To acquire diffusion and perfusion data of the hippocampus, IVIM data were preprocessed using FSL (version 5.0.9; Smith et al., 2004), Mrtrix3 (Tournier et al., 2012) and MATLAB (2010). For a detailed description of preprocessing of IVIM datasets, see Nuninga et al. (2020a). In short, data was denoised, corrected for eddy current distortions, motion artifacts and bias field inhomogeneities. We fitted the IVIM model to the preprocessed data estimating *D* for all b > 120 s/mm². Using affine registration, the diffusion unweighted volume was extracted from the IVIM data and registered to the T2-weighted scan. This registration was then applied to the IVIM maps. The voxel size of the IVIM scans did not allow for precise segmentation of hippocampal subfields. Therefore, we used the left and right hippocampus as regions of interests in our initial analysis. As an exploratory analysis, we did segment the hippocampus to investigate IVIM data of hippocampal subfields in relation to cognitive functioning (Supplementary S1). The hippocampal segment available via the ASHS pipeline (see above) was used to extract the perfusion parameters *f* and *D** and diffusion parameter MD from the IVIM maps. Again, values were imported into R

for statistical analysis.

2.6. Statistical analysis

Statistical analysis was performed using the R software package, version 3.6.2 (R Foundation for Statistical Computing, Vienna, Austria). Differences in demographic and clinical characteristics between patients and dropouts were analyzed using independent *t*-tests for continuous variables and Chi-square (χ^2) for categorical variables. Statistical significance was determined using a threshold of *p* ≤ .05. Differences in performance on the five cognitive tests before and after ECT were analyzed using a linear mixed model for repeated measures with time (pre/post) as repeated measure, modeled as fixed factor with gender and age and subject as random factor (package lmerTest; Kuznetsova et al., 2017).

To examine whether a decrease in cognitive functioning is related to changes in structural characteristics of the hippocampus in individual patients, we used a repeated measures correlation analysis (package rmcrr; Bakdash and Marusich, 2017). The repeated measures correlation determines common within-individual association for paired measures (2 measures: pre- and post-ECT). Therefore, the repeated-measures correlation can be used to examine changes in cognitive performance and structural characteristics of the hippocampus before and after ECT within individuals.

First, we tested whether correlations were present between changes in performance on the five cognitive tests (see assessment) and volume changes of nine hippocampal subfields. Second, we tested whether correlations were present between changes in performance on the five cognitive tests and diffusion and perfusion changes of the left and right hippocampus (MD, *f*, *D**). To ensure that gender and age did not influence our results, we used percentile and raw scores as variables for the cognitive tests. Because of the explorative nature of our study, we here report correlation tests without multiple testing corrections.

3. Results

3.1. Sample

Demographic and clinical characteristics of the sample are displayed in Table 1. Participants that did not complete both assessments did not differ from those who did regarding age, gender, handedness, premorbid IQ, and HAM-D score at baseline (see Supplementary Table 1). The linear mixed models for the cognitive tests showed a significant effect of time, indicating that performance decreased significantly after ECT on all subtests of the D-RAVLT and letter fluency, but not on categorical fluency (Table 2).

3.2. Volume hippocampal subfields and cognition

A negative correlation was observed between performance on the

Table 1
Clinical and demographic information.

	Mean (SD)
Female/male	18/5
Age in years	50.3 (16.10)
Premorbid IQ ^a	105.04 (12.20)
Handedness (right/left)	21/2
Diagnosis (unipolar/bipolar)	22/1
Responders/non-responders ^b	6/17

Values are mean (standard deviation) unless otherwise mentioned; a Estimated using the Dutch version of the National Adult Reading Test; b Response after a series of 10 ECT sessions is classified as a 50 % decrease in Hamilton Depression Rating Scale score compared to baseline; IQ = intelligent quotient; Note that patients received additional ECT sessions when clinically indicated.

Table 2
Estimated marginal means (pre-ECT- post-ECT) of structural characteristics of hippocampus and cognitive performance.

	Pre-ECT	Post-ECT	df	EMM
Left hippocampus				
Volume	3420.97 (107.08)	3604.42 (112.26)	17.22	183.44 (102.69)
Mean diffusivity (MD)	995.27 (16.46)	935.14 (16.79)	15.14	60.14 (19.48) *
Perfusion fraction (f)	0.09 (0.01)	0.06 (0.01)	16.46	0.02 (0.01)*
Pseudo-diffusion (D*)	0.02 (0.00)	0.02 (0.00)	16.46	0.00 (0.00)
Right hippocampus				
Volume	3566.22 (145.44)	3792.46 (152.47)	17.22	226.24 (139.41)
Mean diffusivity (MD)	1009.20 (14.55)	969.73 (14.85)	15.49	39.47 (17.77) *
Perfusion fraction (f)	0.11 (0.01)	0.09 (0.01)	14.34	0.02 (0.01)
Pseudo-diffusion (D*)	0.02 (0.00)	0.02 (0.00)	16.46	0.00 (0.00)
Cognition				
D-RAVLT				
Immediate recall	38.28 (2.01)	33.38 (2.12)	23.00	4.90 (1.81)*
Delayed recall	7.82 (0.61)	5.40 (0.65)	22.99	2.42 (0.54)*
Recognition	0.93 (0.02)	0.87 (0.02)	22.89	0.06 (0.02)*
Letter fluency	22.64 (1.53)	18.68 (1.59)	22.65	3.96 (1.11)*
Categorical fluency	59.97 (4.00)	52.61 (4.13)	22.54	7.36 (2.63)

Estimated marginal means (EMM) based on the linear mixed model (see Nuninga et al., 2018, 2020a, 2020b); df = estimated degrees of freedom (Kenward-Roger approximation); Values are mean (standard deviation); D-RAVLT = Dutch adaptation of the Rey Auditory-Verbal Learning Test; *Significant at the $p < .05$ level after false discovery rate (FDR) correction by Benjamini and Hochberg (1995) for multiple testing.

Table 3
Repeated measures correlations between changes in hippocampal volume and scores on cognitive tests over time.

		D-RAVLT IR	D-RAVLT DR	D-RAVLT Rec	Cat. Fluency	Letter Fluency
<i>Left</i>	Hippocampus	-0.51*	-0.36	-0.27	0.02	0.01
	Brodmann area 35	-0.17	-0.09	-0.10	0.00	0.17
	Brodmann area 36	-0.47	-0.22	-0.40	0.01	-0.35
	Cornu Ammonis 1	-0.30	-0.20	0.24	-0.28	0.08
	Cornu Ammonis 2	-0.11	-0.16	0.07	0.15	0.17
	Cornu Ammonis 3	-0.41	-0.16	-0.36	0.03	0.12
	Collateral sulcus	-0.03	-0.04	-0.43	0.00	-0.40
	Dentate gyrus	-0.50*	-0.46	-0.51*	-0.20	-0.41
	Entorhinal cortex	-0.14	-0.06	-0.14	0.05	-0.23
	Subiculum	-0.15	-0.21	-0.15	0.01	-0.33
<i>Right</i>	Hippocampus	-0.46	-0.37	-0.08	-0.25	-0.07
	Brodmann area 35	0.03	-0.06	-0.13	0.18	0.06
	Brodmann area 36	-0.45	0.12	-0.19	-0.04	-0.24
	Cornu Ammonis 1	-0.64**	-0.32	-0.27	-0.16	-0.08
	Cornu Ammonis 2	-0.08	-0.22	0.11	0.13	0.04
	Cornu Ammonis 3	-0.36	-0.18	-0.08	-0.41	-0.06
	Collateral sulcus	-0.11	-0.12	0.25	-0.28	-0.02
	Dentate gyrus	-0.58*	-0.56*	-0.39	-0.25	-0.22
	Entorhinal cortex	-0.33	-0.41	0.30	-0.02	0.15
	Subiculum	-0.36	-0.45	-0.05	0.15	0.07

D-RAVLT = Dutch adaptation of the Rey Auditory-Verbal Learning Test; IR = Immediate recall; DR = Delayed recall; Rec = Recognition; Cat. Fluency = Categorical fluency; Colored cells show significant results; * Significant at the $p < .05$ level; ** Significant at the $p < .01$ level; non-corrected p -values.

immediate recall subtest of the D-RAVLT and volume of the left hippocampus ($r = -0.51, p = .035$; Table 3, Fig. 1) indicating that the left hippocampal volume increase correlates with a decrease in immediate verbal memory performance. No correlations were found between right hippocampal volume increase and a decrease in test scores on cognitive tasks. When looking at specific hippocampal subfields, a negative correlation was observed between left DG volume increase and the immediate recall ($r = -0.50, p = .041$) and recognition subtests of the D-RAVLT ($r = -0.51, p = .035$). Further, negative correlations were observed between the right DG and performance on the immediate ($r = -0.58, p = .014$) and delayed recall ($r = -0.56, p = .020$) subtests of the D-RAVLT. In addition, a negative correlation was observed between right CA1 volume increase and performance on the immediate subtest of the D-RAVLT ($r = -0.64, p = .005$). No significant correlations were observed between volume changes of hippocampal subfields and fluency tasks.

3.3. IVIM MD, f and D* and cognition

A positive correlation is observed between MD of the left hippocampus and letter fluency ($r = 0.63, p = .027$; Table 4, Fig. 2). The positive correlation indicates that a decrease in MD is associated with a decrease in performance on a letter fluency task. No correlations were found between right hippocampus MD decrease and a decrease in test scores on cognitive tasks. Further, no correlations were observed between performance on cognitive tests and changes in perfusion parameters (f nor D*) of the left or right hippocampus (all $p > .05$, Table 4) which indicates that a decrease in perfusion is not associated with changes in performance on cognitive tests. In an exploratory analysis on the hippocampal subfields, correlations were observed between performance on cognitive tests and MD and f of several hippocampal subfields, but not with pseudo-diffusion (see Supplementary Table 2 and Supplementary Fig. 1).

4. Discussion

Using ultra high-field MRI, we investigated if cognitive functioning was associated with effects of ECT on hippocampal structural changes in patients with major depression. Our results suggest that volume increase in the left hippocampus and in left and right hippocampal subfields occurs with a decrease in verbal memory functioning. We provide preliminary evidence that the decrease in MD of the left hippocampus occurs with a worsening in letter fluency. The current sample has previously been examined for volumetric brain changes and perfusion and diffusion characteristics of the hippocampus after ECT. It was shown that baseline volume of the DG and DG volume change after ECT related to clinical response. In addition, it was shown that diffusion and perfusion in the hippocampus decreased after ECT (Nuninga et al., 2020a, 2020b).

Our observations regarding the relationship between volume change of hippocampal subfields and cognition is consistent with three previous studies showing a correlation between change in hippocampal volume and performance on tasks that assess cognitive functioning and memory (Argyelan et al., 2021; Gbyl et al., 2021; van Oostrom et al., 2018). Of note is that a recent study demonstrated that the correlation between volume increase and cognitive impairment is hippocampal-specific as volume changes in other brain regions had no, or significantly lower correlations with cognitive impairment (Argyelan et al., 2021). In contrast, two studies investigating the relationship between hippocampal volume and cognition do not report such correlations (Abbott et al., 2014; Nordanskog et al., 2014). One of these studies assessed cognition 8–11 days after the final ECT session (Nordanskog et al., 2014), while it is reported that the acute effect on cognition is mainly limited to the first three days after the final ECT session, and cognitive functioning returns to baseline within 14 days after ECT (Porter et al., 2020; Semkovska and McLoughlin, 2010). Therefore, the acute effect on cognition may have

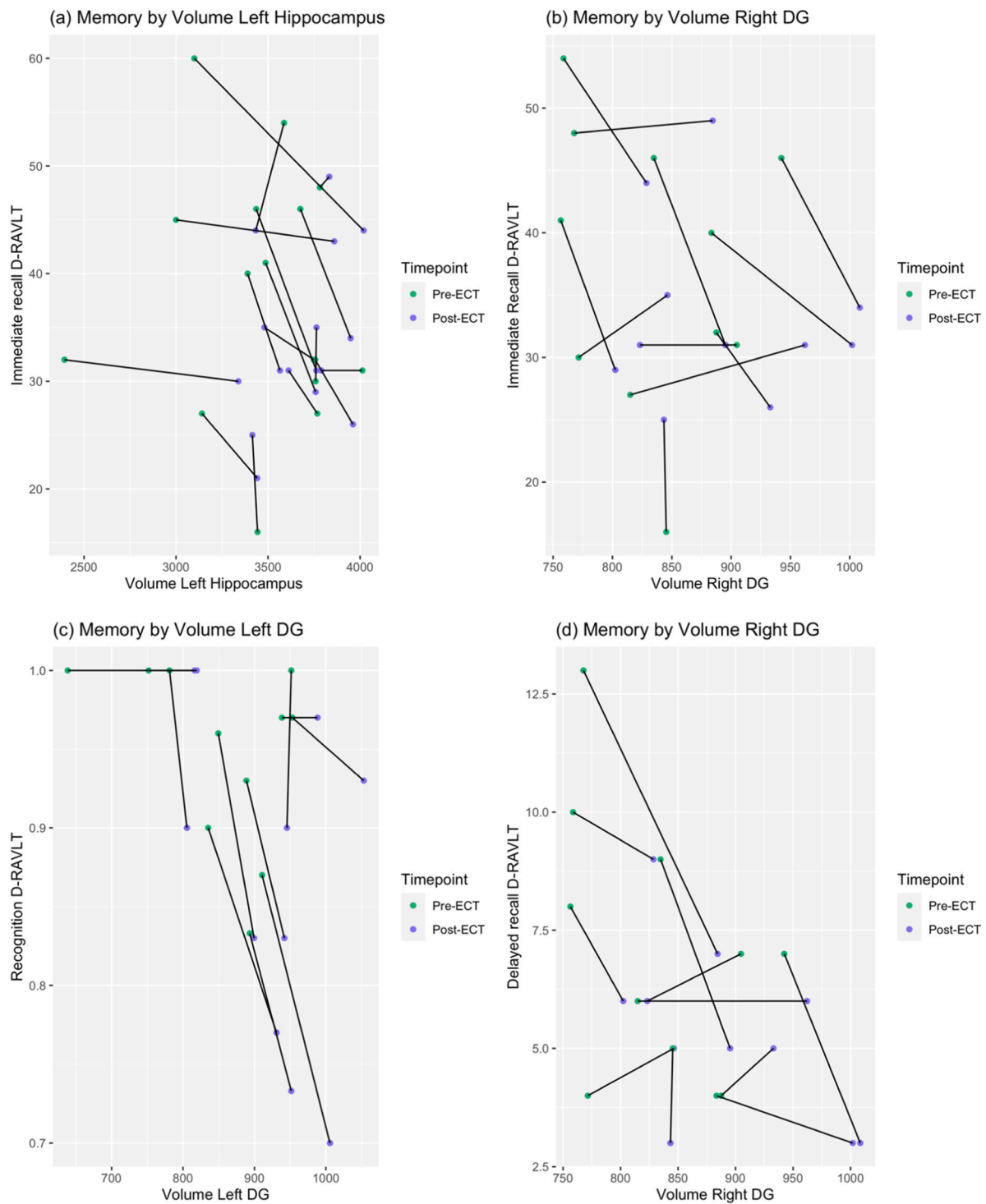


Fig. 1. Relationship between changes in memory performance and volume of the hippocampus following ECT; a) Immediate recall performance (sum of 5 trials) measured by Dutch adaptation of the Rey Auditory Verbal Learning Test (D-RAVLT) in relation to volume changes of left hippocampus; b) Immediate recall D-RAVLT in relation to volume changes of right dentate gyrus volume (DG); c) Recognition trial of D-RAVLT in relation to changes of left DG volume; d) Delayed recall D-RAVLT in relation to volume changes of right DG volume; The baseline measurement is indicated with a green dot, and the purple dot indicates the exit measurement; Each line represents an individual participant. (For interpretation of the references to colour in this figure legend, the reader is referred to the web version of this article.)

been resolved, explaining the negative findings.

A possible explanation of hippocampal volume increase might be that ECT enhances neuroplasticity. Preclinical work has shown that electroconvulsive shock (ECS), the animal analogue of ECT, is able to induce neuroplastic processes, such as neurogenesis in the DG (Madsen et al., 2000; Olesen et al., 2017; Perera et al., 2007), synaptogenesis in

the CA1 (Chen et al., 2009; Smitha et al., 2014), increase in mossy fiber sprouting in the DG and CA3 (Gombos et al., 1999) and increased spine density in mature granule cells in the DG (Zhao et al., 2012). Induced neurogenesis creates newborn excitatory granule cells in the DG that have higher excitatory properties than matured granule cells (Eriksson et al., 1998). This discrepancy in excitatory properties may affect

Table 4
Repeated measures correlations between changes in intravoxel incoherent motion (IVIM) measurements and scores on cognitive tests over time.



MD = Mean diffusivity; f = perfusion fraction; D^* = pseudo-diffusion coefficient; D-RAVLT = Dutch adaptation of the Rey Auditory-Verbal Learning Test; IR = Immediate recall; DR = Delayed recall; Rec = Recognition. Cat. Fluency = Categorical fluency; Colored cells show significant results; * Significant at the $p < .05$ level; non-corrected p -values are shown.

functionality within the entire hippocampal formation, thereby affecting cognitive functioning (van Oostrom et al., 2018). Mossy fiber sprouting is related to the degree of cognitive impairments in epilepsy which is in turn mediated by structural changes in hippocampus (Dabbs et al., 2009). Neuroplasticity, however, has not been studied extensively in context of ECT-associated cognitive impairments, warranting further investigation.

Changes in diffusion characteristics of the hippocampus may be indicative of neuroplasticity. For example, a decrease in diffusion is known to reflect an increase in cell density (Luo et al., 2020). Using IVIM data, we were able to separate diffusion and perfusion values via MD, f and D^* parameters, respectively. Previous studies show that ECT significantly decreased hippocampal MD, which was not present in healthy controls (Nuninga et al., 2020b; Yroni et al., 2019). Despite the explorative nature of the current study, we complement these findings showing that a decrease in MD in was associated with a decrease in performance on letter fluency. This adds to the idea that neuroplastic changes after ECT might disturb cognition. In addition, although the hippocampus is generally acknowledged for its key role in memory related processes, several studies have demonstrated that the hippocampus also plays a role in other cognitive functions, such as executive

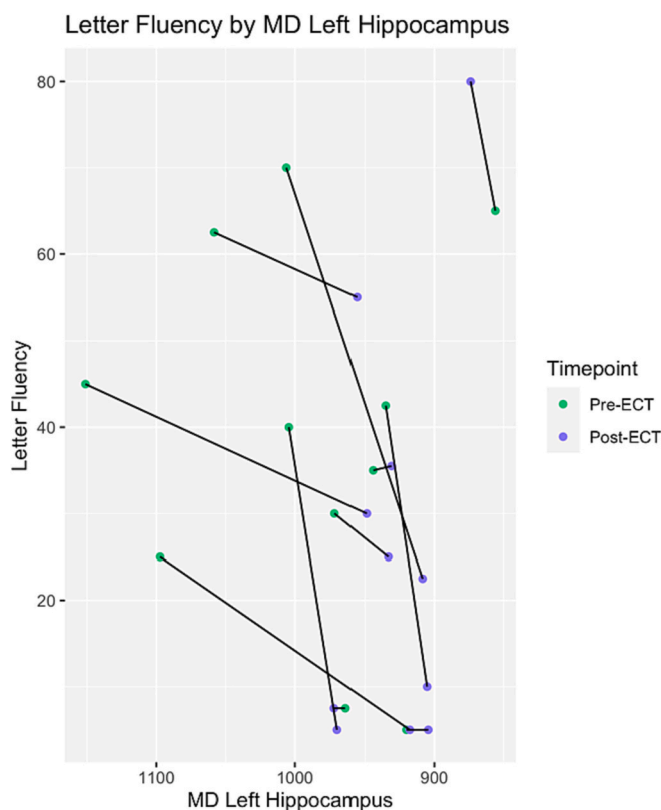


Fig. 2. Relationship between changes in letter fluency and mean diffusivity (MD) of the left hippocampus following electroconvulsive therapy (ECT); Note that the x-axis is inverted; The baseline measurement is indicated with a green dot, and the purple dot indicates the exit measurement; Each line represents an individual participant. (For interpretation of the references to colour in this figure legend, the reader is referred to the web version of this article.)

functioning (Frodl et al., 2006; van Oostrom et al., 2018). As letter fluency relies on several cognitive functions including both memory functioning and executive functioning, the observation that a decrease in MD relates to worsening performance on a letter fluency task is relevant. In contrast, we did not observe a relation between volume of the left hippocampus and performance on letter fluency as would be expected in light of ECT-induced neuroplasticity. However, for several regions within the left hippocampus, we did observe a trend that indicated a negative relation between volume change and performance on the letter fluency task. Studies with a larger sample are needed to further look into volume and MD changes after ECT.

Changes in angiogenesis may also reflect neuroplasticity after ECT. IVIM- f can be interpreted as microvessel density and thus may be indicative of angiogenesis (Lee et al., 2014). If ECT induces neuroplasticity, an increase in neuronal activity would be expected to increase metabolic demand, which would require angiogenesis. Here, we show preliminary results of the exploratory analysis on hippocampal subfields that may indicate a relationship between f in some hippocampal subfields and cognitive impairment after ECT. We report no significant correlations between the D^* and cognition. These findings should be further investigated.

Neuroplastic changes occurring after ECT can interfere with pre-existing synaptic connections. This could affect cognitive processes that rely on hippocampal functioning, thereby causing a (transient) decrease in cognitive functioning. An example of neuroplasticity interfering with cognitive functioning is resembled by infantile amnesia: the inability of recalling early episodic memories by adults (Alberini and Travaglia, 2017). One of the hypothesized mechanisms underlying infantile amnesia is that neurogenesis in the DG disrupts memory

representations, resulting in amnesia. Extended postnatal maturation of the DG has been observed in animal studies, implying that during this developmental period neuroplastic changes still occur and subsequently prevent the hippocampus to retrieve memories (Alberini and Travaglia, 2017). Evidence from animal work show that, similar to infantile amnesia, seizures induced retrograde amnesia through plasticity changes. (Naik et al., 2021). Thus, seizure induced neuroplasticity could disrupt memory representation in the hippocampus, which results in the (temporarily) forgetting of episodic memories.

This study has several limitations. Notably, the small sample size limits the power to detect small effects and the generalizability of our results. In addition, due to the explorative nature of this study using a small sample size combined multiple correlations, we decided not to correct for multiple testing reflecting type I error inflation. Future studies with sufficient power are needed to replicate and extend our results. Since we already observed effects of ECT on cognitive functioning and volumetric changes of the hippocampus, the non-significant correlations in this study may be overestimated due to double-dipping (Kriegeskorte et al., 2009). However, we found a relation between cognition and MD and f in some but not all hippocampal (sub)fields that showed an increased in the previous study (Nuninga et al., 2020a). Therefore, our results are useful in guiding future studies. Another limitation is that MRI is an indirect measure of neuroplasticity. Increased cell density may explain increased volume but various other explanations such as cytotoxic edema, may be possible. However, cytotoxic edema is unlikely as explanation as the fluid movement associated with the formation of cytotoxic edema does not result in changes in brain volume of other structures (Liang et al., 2007). Future studies could focus on quantifying changes in neuroplastic processes of hippocampal subfields after ECT (preferably on multiple timepoints), for example using positron emission tomography to quantify synaptic density (Finnema et al., 2016).

5. Conclusion

In conclusion, we examined multiple MRI parameters in association with cognitive impairments after ECT. Although explorative, we found evidence that structural changes in the hippocampus correlated with cognitive decline after ECT. We provided tentative evidence of a relation between hippocampal volume increase, diffusion decrease and cognitive impairment after ECT, supporting the idea of neuroplastic changes induced by ECT affect cognitive functioning. Additional research, both human and animal work, is warranted to investigate which neurobiological mechanisms underlie cognitive impairment following ECT, as a better understanding of these processes could be key to reduce these disabling side effects, while preserving therapeutic efficacy.

Supplementary data to this article can be found online at <https://doi.org/10.1016/j.jad.2023.01.016>.

Funding

The Netherlands Organization for Scientific Research (NWO) Aspasia Grant, Prof. Dr. I.E.C. Sommer, program “Goed Gebruik Geneesmiddelen” 2018, titled “Efficacy of rivastigmine to prevent side-effects of ECT”.

The Netherlands Organization for Health Research and Development (ZonMW) GGZ fellowship, Award ID: 60-63600-98-711, Dr. E. van Dellen.

University Medical Center Utrecht Clinical Research Talent Fellowship. Award ID: NA, Dr. E. van Dellen.

CRediT authorship contribution statement

Author Iris E.C. Sommer, René C.W. Mandl and Jasper O. Nuninga designed the study and Iris E.C. Sommer wrote the protocol. Author Julia van der A and Jesca E. de Jager managed the literature searches

and analyses. Authors Jasper O. Nuninga and Julia van der A undertook the statistical analysis, and authors Julia van der A and Jesca E. de Jager wrote the first draft of the paper. Jasper O. Nuninga supervised the project. Edwin van Dellen, Marco P. Boks, Metten Somers and Iris E.C. Sommer reviewed and edited the drafts of the paper. All authors contributed to and have approved the final manuscript.

Conflict of interest

None.

References

- Abbott, C.C., Jones, T., Lemke, N.T., Gallegos, P., McClintock, S.M., Mayer, A.R., Bustillo, J., Calhoun, V.D., 2014. Hippocampal structural and functional changes associated with electroconvulsive therapy response. *Transl. Psychiatry* 4. <https://doi.org/10.1038/tp.2014.124>.
- Akers, K.G., Martinez-Canabal, A., Restivo, L., Yiu, A.P., De Cristofaro, A., Hsiang, H.-L., Wheeler, A.L., Guskjolen, A., Niibori, Y., Shoji, H., Ohira, K., Richards, B.A., Miyakawa, T., Josselyn, S.A., Frankland, P.W., 2014. Hippocampal neurogenesis regulates forgetting during adulthood and infancy. *Science* (80-) 344. <https://doi.org/10.1126/science.1248903>.
- Alberini, C.M., Travaglia, A., 2017. Infantile amnesia: a critical period of learning to learn and remember. *J. Neurosci.* 37, 5783–5795. <https://doi.org/10.1523/jneurosci.0324-17.2017>.
- American Psychiatric Association, 2000. Diagnostic and statistical manual of mental disorders. In: Text Revision (DSM-IV-TR), Fourth edition. American Psychiatric Association, Arlington, VA. <https://doi.org/10.1176/appi.books.9780890423349>.
- Argyelan, M., Lencz, T., Kang, S., Ali, S., Masi, P.J., Moyett, E., Joanlanne, A., Watson, P., Sanghani, S., Petrides, G., Malhotra, A.K., 2021. ECT-induced cognitive side effects are associated with hippocampal enlargement. *Transl. Psychiatry* 11. <https://doi.org/10.1038/s41398-021-01641-y>.
- Avants, B.B., Tustison, N.J., Song, G., Cook, P.A., Klein, A., Gee, J.C., 2011. A reproducible evaluation of ANTs similarity metric performance in brain image registration. *NeuroImage* 54. <https://doi.org/10.1016/j.neuroimage.2010.09.025>.
- Bakdash, J.Z., Marusich, L.R., 2017. Repeated measures correlation. *Front. Psychol.* 8. <https://doi.org/10.3389/fpsyg.2017.00456>.
- Benjamini, Y., Hochberg, Y., 1995. Controlling the false discovery rate: a practical and powerful approach to multiple testing. *J. R. Stat. Soc. Ser. B Methodol.* 57, 289–300. <https://doi.org/10.1111/j.2517-6161.1995.tb02031.x>.
- Bouckaert, F., Dols, A., Emsell, L., De Winter, F.-L., Vansteelandt, K., Claes, L., Sunaert, S., Stek, M., Sienaert, P., Vandenbulcke, M., 2016. Relationship between hippocampal volume, serum BDNF, and depression severity following electroconvulsive therapy in late-life depression. *Neuropsychopharmacology* 41, 2741–2748. <https://doi.org/10.1038/npp.2016.86>.
- Cao, B., Luo, Q., Fu, Y., Du, L., Qiu, T., Yang, X., Chen, X., Chen, Q., Soares, J.C., Cho, R. Y., Zhang, X.Y., Qiu, H., 2018. Predicting individual responses to the electroconvulsive therapy with hippocampal subfield volumes in major depression disorder. *Sci. Rep.* 8, 5434. <https://doi.org/10.1038/s41598-018-23685-9>.
- Chen, F., Madsen, T.M., Wegener, G., Nyengaard, J.R., 2009. Repeated electroconvulsive seizures increase the total number of synapses in adult male rat hippocampus. *Eur. Neuropsychopharmacol.* 19, 329–338. <https://doi.org/10.1016/j.euroneuro.2008.12.007>.
- Dabbs, K., Jones, J., Seidenberg, M., Hermann, B., 2009. Neuroanatomical correlates of cognitive phenotypes in temporal lobe epilepsy. *Epilepsy Behav.* 15, 445–451. <https://doi.org/10.1016/j.yebeh.2009.05.012>.
- Dierckx, B., Heijnen, W.T., van den Broek, W.W., Birkenhäger, T.K., 2012. Efficacy of electroconvulsive therapy in bipolar versus unipolar major depression: a meta-analysis. *Bipolar Disord.* 14. <https://doi.org/10.1111/j.1399-5618.2012.00997.x>.
- Eriksson, P.S., Perfilieva, E., Björk-Eriksson, T., Alborn, A.-M., Nordborg, C., Peterson, D. A., Gage, F.H., 1998. Neurogenesis in the adult human hippocampus. *Nat. Med.* 4, 1313–1317. <https://doi.org/10.1038/3305>.
- Fink, M., 2014. What was learned: studies by the consortium for research in ECT (CORE) 1997–2011. *Acta Psychiatr. Scand.* 129. <https://doi.org/10.1111/acps.12251>.
- Finnema, S.J., Nabulsi, N.B., Eid, T., Detynecki, K., Lin, S., Chen, M.-K., Dhaher, R., Matuskey, D., Baum, E., Holden, D., Spencer, D.D., Mercier, J., Hannestad, J., Huang, Y., Carson, R.E., 2016. Imaging synaptic density in the living human brain. *Sci. Transl. Med.* 8. <https://doi.org/10.1126/scitranslmed.aaf6667>.
- Friedrich, M.J., 2017. Depression is the leading cause of disability around the world. *JAMA* 317. <https://doi.org/10.1001/jama.2017.3826>.
- Frodl, T., Schaub, A., Banac, S., Charypar, M., Jäger, M., Kümmler, P., Bottlender, R., Zetsche, T., Born, C., Leinsinger, G., Reiser, M., Möller, H.-J., Meisenzahl, E.M., 2006. Reduced hippocampal volume correlates with executive dysfunctioning in major depression. *J. Psychiatry Neurosci.* 31, 316–323.
- Gbyl, K., Videbech, P., 2018. Electroconvulsive therapy increases brain volume in major depression: a systematic review and meta-analysis. *Acta Psychiatr. Scand.* 138, 180–195. <https://doi.org/10.1111/acps.12884>.
- Gbyl, K., Støttrup, M.M., Mitta Raghava, J., Xue Jie, S., Videbech, P., 2021. Hippocampal volume and memory impairment after electroconvulsive therapy in patients with depression. *Acta Psychiatr. Scand.* 143. <https://doi.org/10.1111/acps.13259>.

- Gombos, Z., Spiller, A., Cottrell, G.A., Racine, R.J., McIntyre Burnham, W., 1999. Mossy fiber sprouting induced by repeated electroconvulsive shock seizures. *Brain Res.* 844 [https://doi.org/10.1016/S0006-8993\(99\)01924-1](https://doi.org/10.1016/S0006-8993(99)01924-1).
- Hamilton, M., 1960. A rating scale for depression. *J. Neurol. Neurosurg. Psychiatry* 23. <https://doi.org/10.1136/jnnp.23.1.56>.
- Hag, A.U., Sitzmann, A.F., Goldman, M.L., Maixner, D.F., Mickey, B.J., 2015. Response of depression to electroconvulsive therapy: a meta-analysis of clinical predictors. *J. Clin. Psychiatry* 76, 1374–1384. <https://doi.org/10.4088/jcp.14r09528>.
- Husain, M.M., Rush, A.J., Fink, M., Knapp, R., Petrides, G., Rummans, T., Biggs, M.M., O'Connor, K., Rasmussen, K., Little, M., Zhao, W., Bernstein, H.J., Smith, G., Mueller, M., McClintock, S.M., Bailine, S.H., Kellner, C.H., 2004. Speed of response and remission in major depressive disorder with acute electroconvulsive therapy (ECT). *J. Clin. Psychiatry* 65. <https://doi.org/10.4088/JCP.v65n0406>.
- Kolshus, E., Jelovac, A., McLoughlin, D.M., 2017. Bitemporal v. High-dose right unilateral electroconvulsive therapy for depression: a systematic review and meta-analysis of randomized controlled trials. *Psychol. Med.* 47 <https://doi.org/10.1017/S0033291716002737>.
- Kriegeskorte, N., Simmons, W.K., Bellgowan, P.S.F., Baker, C.I., 2009. Circular analysis in systems neuroscience: the dangers of double dipping. *Nat. Neurosci.* 12, 535–540. <https://doi.org/10.1038/nn.2303>.
- Kuznetsova, A., Brockhoff, P.B., Christensen, R.H.B., 2017. lmerTest package: tests in linear mixed effects models. *J. Stat. Softw.* 82 <https://doi.org/10.18637/jss.v082.i13>.
- Le Bihan, D., 2019. What can we see with IVIM MRI? *NeuroImage* 187. <https://doi.org/10.1016/j.neuroimage.2017.12.062>.
- Le Bihan, D., Breton, E., Lallemand, D., Aubin, M.L., Vignaud, J., Laval-Jeantet, M., 1988. Separation of diffusion and perfusion in intravoxel incoherent motion MR imaging. *Radiology* 168. <https://doi.org/10.1148/radiology.168.2.3393671>.
- Lee, H.-J., Rha, S.Y., Chung, Y.E., Shim, H.S., Kim, Y.J., Hur, J., Hong, Y.J., Choi, B.W., 2014. Tumor perfusion-related parameter of diffusion-weighted magnetic resonance imaging: correlation with histological microvessel density. *Magn. Reson. Med.* 71 <https://doi.org/10.1002/mrm.24810>.
- Liang, D., Bhatta, S., Gerzanich, V., Simard, J.M., 2007. Cytotoxic edema: mechanisms of pathological cell swelling. *Neurosurv. Focus.* 22 <https://doi.org/10.3171/foc.2007.22.5.3>.
- Luo, J., Zhou, K., Zhang, B., Luo, N., Bian, J., 2020. Intravoxel incoherent motion diffusion-weighted imaging for evaluation of the cell density and angiogenesis of cirrhosis-related nodules in an experimental rat model: comparison and correlation with dynamic contrast-enhanced MRI. *J. Magn. Reson. Imaging* 51. <https://doi.org/10.1002/jmri.26845>.
- Madsen, T.M., Treschow, A., Bengzon, J., Bolwig, T.G., Lindvall, O., Tingström, A., 2000. Increased neurogenesis in a model of electroconvulsive therapy. *Biol. Psychiatry* 47. [https://doi.org/10.1016/S0006-3223\(00\)00228-6](https://doi.org/10.1016/S0006-3223(00)00228-6).
- MATLAB, 2010. Version 7.10.0 (R2010a).
- Mulder, J.L., Dekker, P.H., Dekker, R., 2006. *Handleiding Woord-fluency Test/Figuur-fluency Test*. PITS, Nederland, Leiden.
- Naik, A.A., Sun, H., Williams, C.L., Weller, D.S., Julius Zhu, J., Kapur, J., 2021. Mechanism of seizure-induced retrograde amnesia. *Prog. Neurobiol.* 200, 101984 <https://doi.org/10.1016/j.pneurobio.2020.101984>.
- Neil, Jeffrey J., Bosch, Coleen S., JHHA, 1994. An evaluation of the sensitivity of the intravoxel incoherent motion (IVIM) method of blood flow measurement to changes in cerebral blood flow. *Magn. Reson. Med.* 60–65.
- Nordanskog, P., Dahlstrand, U., Larsson, M.R., Larsson, E.-M., Knutsson, L., Johanson, A., 2010. Increase in hippocampal volume after electroconvulsive therapy in patients with depression. *J. ECT* 26, 62–67. <https://doi.org/10.1097/YCT.0b013e3181a95da8>.
- Nordanskog, P., Larsson, M.R., Larsson, E.-M., Johanson, A., 2014. Hippocampal volume in relation to clinical and cognitive outcome after electroconvulsive therapy in depression. *Acta Psychiatr. Scand.* 129 <https://doi.org/10.1111/acps.12150>.
- Nuninga, J.O., Claessens, T.F.I., Somers, M., Mandl, R., Nieuwendorp, W., Boks, M.P., Bakker, S., Begemann, M.J.H., Heringa, S., Sommer, I.E.C., 2018. Immediate and long-term effects of bilateral electroconvulsive therapy on cognitive functioning in patients with a depressive disorder. *J. Affect. Disord.* 238, 659–665. <https://doi.org/10.1016/j.jad.2018.06.040>.
- Nuninga, J.O., Mandl, R.C.W., Boks, M.P., Bakker, S., Somers, M., Heringa, S.M., Nieuwendorp, W., Hoogduin, H., Kahn, R.S., Luijten, P., Sommer, I.E.C., 2020a. Volume increase in the dentate gyrus after electroconvulsive therapy in depressed patients as measured with 7T. *Mol. Psychiatry* 25. <https://doi.org/10.1038/s41380-019-0392-6>.
- Nuninga, J.O., Mandl, R.C.W., Froeling, M., Siero, J.C.W., Somers, M., Boks, M.P., Nieuwendorp, W., Heringa, S., Sommer, I.E.C., 2020b. Vasogenic edema versus neuroplasticity as neural correlates of hippocampal volume increase following electroconvulsive therapy. *Brain Stimul.* 13, 1080–1086. <https://doi.org/10.1016/j.brs.2020.04.017>.
- Obbels, J., Vansteelandt, K., Bouckaert, F., Dols, A., Stek, M., Verwijk, E., Sienaert, P., 2021. Neurocognitive functioning after electroconvulsive therapy in late-life depression: a 4-year prospective study. *Acta Psychiatr. Scand.* 143, 141–150.
- Olesen, M.V., Wörtwein, G., Folke, J., Pakkenberg, B., 2017. Electroconvulsive stimulation results in long-term survival of newly generated hippocampal neurons in rats. *Hippocampus* 27. <https://doi.org/10.1002/hipo.22670>.
- Oltedal, L., Narr, K.L., Abbott, C., Anand, A., Argyelan, M., Bartsch, H., Dannlowski, U., Dols, A., van Eijndhoven, P., Emsell, L., Erchinger, V.J., Espinoza, R., Hahn, T., Hanson, L.G., Hellemann, G., Jorgensen, M.B., Kessler, U., Oudega, M.L., Paulson, O. B., Redlich, R., Sienaert, P., Stek, M.L., Tendolkar, I., Vandenbulcke, M., Oedegaard, K.J., Dale, A.M., 2018. Volume of the human hippocampus and clinical response following electroconvulsive therapy. *Biol. Psychiatry* 84, 574–581. <https://doi.org/10.1016/j.biopsych.2018.05.017>.
- Pagnin, D., de Queiroz, V., Pini, S., Cassano, G.B., 2008. Efficacy of ECT in depression: a meta-analytic review. *Focus (Madison)* 6. <https://doi.org/10.1176/foc.6.1.foc155>.
- Perera, T.D., Coplan, J.D., Lisanby, S.H., Lipira, C.M., Arif, M., Carpio, C., Spitzer, G., Santarelli, L., Scharf, B., Hen, R., Rosoklija, G., Sackeim, H.A., Dwork, A.J., 2007. Antidepressant-induced neurogenesis in the hippocampus of adult nonhuman primates. *J. Neurosci.* 27 <https://doi.org/10.1523/JNEUROSCI.0237-07.2007>.
- Porter, R.J., Baune, B.T., Morris, G., Hamilton, A., Bassett, D., Boyce, P., Hopwood, M.J., Mulder, R., Parker, G., Singh, A.B., Outhred, T., Das, P., Malhi, G.S., 2020. Cognitive side-effects of electroconvulsive therapy: what are they, how to monitor them and what to tell patients. *BJPsych Open* 6. <https://doi.org/10.1192/bjo.2020.17>.
- Sackeim, H.A., Prudic, J., Fuller, R., Keilp, J., Lavori, P.W., Olfson, M., 2007. The cognitive effects of electroconvulsive therapy in community settings. *Neuropsychopharmacology* 32, 244–254. <https://doi.org/10.1038/sj.npp.1301180>.
- Schmand, B., Lindeboom, J., Van Harskamp, F., 1992. *De nederlandse leestest Voor volwassenen*. Swets & Zeitlinger, Lisse.
- Semkowska, M., McLoughlin, D.M., 2010. Objective cognitive performance associated with electroconvulsive therapy for depression: a systematic review and meta-analysis. *Biol. Psychiatry* 68. <https://doi.org/10.1016/j.biopsych.2010.06.009>.
- Smith, S.M., Jenkinson, M., Woolrich, M.W., Beckmann, C.F., Behrens, T.E.J., Johansen-Berg, H., Bannister, P.R., De Luca, M., Drobnjak, I., Flitney, D.E., Niazey, R.K., Saunders, J., Vickers, J., Zhang, Y., De Stefano, N., Brady, J.M., Matthews, P.M., 2004. Advances in functional and structural MR image analysis and implementation as FSL. *NeuroImage* 23. <https://doi.org/10.1016/j.neuroimage.2004.07.051>.
- Smitha, J.S.M., Roopa, R., Khaleel, N., Kutty, B.M., Andrade, C., 2014. Images in electroconvulsive therapy. *J. ECT* 30. <https://doi.org/10.1097/YCT.0000000000000077>.
- Takamiya, A., Plitman, E., Chung, J.K., Chakravarty, M., Graff-Guerrero, A., Mimura, M., Kishimoto, T., 2019. Acute and long-term effects of electroconvulsive therapy on human dentate gyrus. *Neuropsychopharmacology* 44, 1805–1811. <https://doi.org/10.1038/s41386-019-0312-0>.
- Togao, O., Hiwatashi, A., Yamashita, K., Kikuchi, K., Momosaka, D., Yoshimoto, K., Kuga, D., Mizoguchi, M., Suzuki, S.O., Iwaki, T., Van Cauteren, M., Iihara, K., Honda, H., 2018. Measurement of the perfusion fraction in brain tumors with intravoxel incoherent motion MR imaging: validation with histopathological vascular density in meningiomas. *Br. J. Radiol.* <https://doi.org/10.1259/bjr.20170912>.
- Tournier, J.-D., Calamante, F., Connelly, A., 2012. MRtrix: diffusion tractography in crossing fiber regions. *Int. J. Imaging Syst. Technol.* 22 <https://doi.org/10.1002/ima.22005>.
- van den Broek, W.W., Birkenhäger, T.K., de Boer, D., Burggraaf, J.P., van Gemert, B., Groenland, T.H.N., Kho, K.H., Stek, M.L., Verwey, B., van Vliet, I.M., van Waarde, J.A., Wijkstra, J., 2010. *Richtlijn Elektroconvulsietherapie*, 1st ed. Nederlandse Vereniging voor Psychiatrie.
- Van der Elst, W., Van Bostel, M.P.J., Van Breukelen, G.J.P., Jolles, J., 2005. Rey's verbal learning test: normative data for 1855 healthy participants aged 24–81 years and the influence of age, sex, education, and mode of presentation. *J. Int. Neuropsychol. Soc.* 11 <https://doi.org/10.1017/S1355617705050344>.
- van Oostrom, I., van Eijndhoven, P., Butterbrod, E., van Beek, M.H., Janzing, J., Donders, R., Schene, A., Tendolkar, I., 2018. Decreased cognitive functioning after electroconvulsive therapy is related to increased hippocampal volume. *J. ECT* 34. <https://doi.org/10.1097/YCT.0000000000000483>.
- Vasavada, M.M., Leaver, A.M., Njau, S., Joshi, S.H., Ercooli, L., Hellemann, G., Narr, K.L., Espinoza, R., 2017. Short- and long-term cognitive outcomes in patients with major depression treated with electroconvulsive therapy. *J. ECT* 33. <https://doi.org/10.1097/YCT.0000000000000426>.
- Verwijk, E., Obbels, J., Spaans, H.P., Sienaert, P., 2017. *Dokter, komt mijn geheugen terug? Elektroconvulsietherapie en cognitieve bijwerkingen in de praktijk*. Tijdschr. Psychiatr. 59, 632–637.
- Wilkinson, S.T., Sanacora, G., Bloch, M.H., 2017. Hippocampal volume changes following electroconvulsive therapy: a systematic review and meta-analysis. *Biol. Psychiatry Cogn. Neurosci. Neuroimaging* 2, 327–335. <https://doi.org/10.1016/j.bpsc.2017.01.011>.
- Yrondi, A., Nemmi, F., Billoux, S., Giron, A., Sporer, M., Taib, S., Salles, J., Pierre, D., Thalamos, C., Schmitt, L., Péran, P., Arbus, C., 2019. Significant decrease in hippocampus and amygdala mean diffusivity in treatment-resistant depression patients who respond to electroconvulsive therapy. *Front. Psychiatry* 10, 694. <https://doi.org/10.3389/fpsy.2019.00694>.
- Yushkevich, P.A., Pluta, J.B., Wang, H., Xie, L., Ding, S.-L., Gertje, E.C., Mancuso, L., Klit, D., Das, S.R., Wolk, D.A., 2015. Automated volumetry and regional thickness analysis of hippocampal subfields and medial temporal cortical structures in mild cognitive impairment. *Hum. Brain Mapp.* 36 <https://doi.org/10.1002/hbm.22627>.
- Zhao, C., Warner-Schmidt, J.S., Duman, R., Gage, F.H., 2012. Electroconvulsive seizure promotes spine maturation in newborn dentate granule cells in adult rat. *Dev. Neurobiol.* 72 <https://doi.org/10.1002/dneu.20986>.