



A SINGLE-SKIN INCISION EXTENDED ANTEROLATERAL APPROACH TO THE HIP FOR TREATMENT OF HIP PROBLEMS IN CEREBRAL PALSY PATIENTS

Tomislav Đapčić^{1,2} and Ozren Kubat^{1,2}

¹Department of Orthopaedic Surgery, University Hospital Centre Zagreb, Zagreb, Croatia

²School of Medicine, University of Zagreb, Zagreb, Croatia

SUMMARY – Cerebral palsy often carries a high risk of hip involvement, especially in patients with a higher degree of body involvement. Hip subluxations and dislocations are commonly seen in non-ambulatory patients. We report on a single skin incision anterolateral approach to the hip that provides excellent visualisation of all relevant anatomical structures and allows for a broad range of operative procedures needed to complete the San Diego operation. From 2005 to 2020, 50 patients (56 hips) were treated using the San Diego procedure. There were 22 male and 28 female patients, with 28 dislocated and 28 subluxated hips. The average patient age at the time of surgery was nine (range, 4 – 22 years). A San Diego or Dega pelvic osteotomy was done in 49 hips, and seven hips underwent a Brunner-type pelvic osteotomy. The mean follow-up was seven years (range, 2 – 13 years). The median preoperative AI measured at 40° (range, 35° – 50°). The median postoperative AI at the time of the most recent follow-up was 22,5° (range, 5° – 40°). The average head migration index at the last follow-up was 10% (range, 0% – 60%). Two infections, three recurring adduction contractures, four redislocations, one fracture, and one pseudarthrosis were encountered. All patients were eventually able to sit pain-free, with significantly better sitting balance.

Keywords: *cerebral palsy, hip joint, osteotomy*

Introduction

The prevalence of hip subluxation and dislocation in children and adolescents with cerebral palsy (CP) varies significantly in literature, ranging from 2,5% all the way to 28%¹. Hip dislocations are commonly encountered in non-ambulatory patients with a high degree of spasticity and whole-body involvement, usually graded III, IV or V in the Gross Motor Function Classification System (GMFCS)^{1,2,3,4}.

Patients with CP most often exhibit increased muscle tone in the iliopsoas, adductor, and hamstring muscles, while the abdominal muscles are usually weak. This brings about a classic clinical finding of a flexion and adduction hip contracture. As the femoral head moves posteriorly and superolaterally, the hip centre of rotation slowly migrates towards the lesser trochanter. The proximal femur maintains its infantile geometry with the accentuated anteversion angle, while the physiological derotation of the proximal femur is absent. The femoral neck-shaft angle also increases with time, resulting in a coxa valga. The absence of centrally located pressures inside the acetabulum leads to acetabular dysplasia, with the socket becoming shallow and elongated, mostly in its posterolateral part. The femoral head also deforms and eventually becomes triangular. All these changes result in early degeneration of joint cartilage, with an ear-

Correspondence to: *Ozren Kubat*
Department of Orthopaedic Surgery
University Hospital Centre Zagreb
Šalata 7, 10000 Zagreb
e-mail: ozren.kubat@gmail.com
phone: 01/2368911

ly onset secondary arthritis together with a pronounced inflammatory response of the synovial lining. The process of femoral head migration and synovitis very often cause pain^{1,4,5,6}. Joint pain contributes to the formation of contractures, and those, in turn, cause significant issues with seating and perineal hygiene^{1,4}.

A radiological follow-up is indispensable for an early diagnosis of hip subluxation and dislocation. Regular semi-annual anteroposterior hip radiographs are the norm in CP patients with a higher degree of involvement⁴. Following the status of the hips can also be performed by ultrasound, using the Terjesen method⁵. The radiographs are analysed for the degree of dislocation, which can be quantified by measuring the percentage of femoral head migration relative to the acetabulum, and other parameters such as the acetabular index (AI) and the normal continuation of the Shenton-Menard's arc. The AI provides us with a good measure of acetabular dysplasia, with a normal value for paediatric neuromuscular patients measuring up to 20°, and a pathological finding being >30°^{1,4}.

If the decision is to treat a subluxed or dislocated hip in a CP patient, the treatment is solely surgical. No conservative measures can achieve success in a decentered hip joint. The surgery aims to normalise the deranged anatomical relationships and balance the muscle forces acting on the joint. The type and scope of surgery depend on disease aetiology, patient age, the position and degree of hip decentration, and the condition of the femoral head cartilage cover. The balancing of the muscle forces is done by using tenotomies, myotomies as well as muscle transpositions, while the normalisation of anatomical relations in the hip is achieved by means of pelvic and proximal femoral osteotomy. The San Diego procedure has become the gold standard surgery in paediatric neuromuscular patients with hip subluxation or dislocation. It is used in children four years and older, with a large femoral head migration index (>60°) with increased femoral anteversion and neck-shaft angle and an acetabular index >25°. The procedure is multifaceted, including both a pelvic and proximal femoral osteotomy with femoral shortening, open reduction of the hip, adductor and iliopsoas tenotomy and a proximal hamstring tenotomy, if necessary^{7,8,9}.

Materials and Methods

In the period from 2005 until 2020, 50 paediatric and adolescent patients and 56 hips were treated sur-

gically using the San Diego procedure in our department.

The San Diego procedure has been utilised in the treatment of the neuromuscular hip in our department since 1998, most commonly in patients with CP, myelodysplasias, and muscle atrophies. In the case of adolescents or adult patients in whom the triradiate cartilage had already closed prior to treatment, the pelvic osteotomy was slightly modified to be an incomplete spheric osteotomy, still meeting the San Diego procedure criteria.

From the year 2005, we have been employing the single skin incision and an extended anterolateral approach. This enables better visualisation of posterolateral and lateral hip dislocations. The single „lazy S” skin incision is drawn from the iliac crest, dropping down to the greater trochanter and extending onto the upper leg (Figure 1). The fascia is open in line with the skin incision, with an additional cut directed posteriorly in the greater trochanteric region. The hip is approached

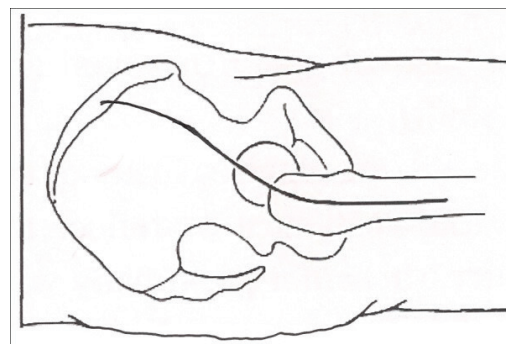


Figure 1. Drawing outlining the position of the single skin incision.

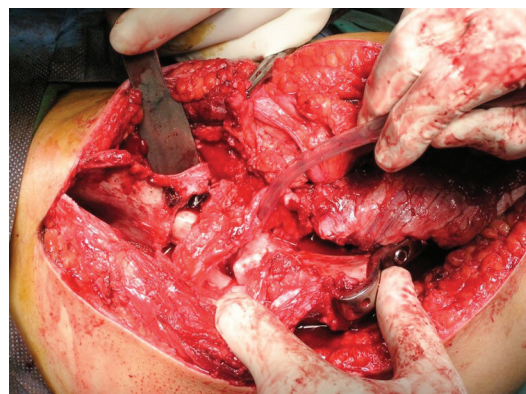


Figure 2. Intraoperative photograph depicting the extended anterolateral interval approach to the hip and proximal femur.

through the interval between the gluteus medius muscle and tensor fasciae latae (TFL). This interval is then carried all the way to the iliac crest, sacrificing the arterial branch for the TFL and the nerve branch supplying the TFL (Figures 2 and 3). In children and adolescent patients with apophyseal cartilage capping the iliac crest, that cartilage is opened in line with the

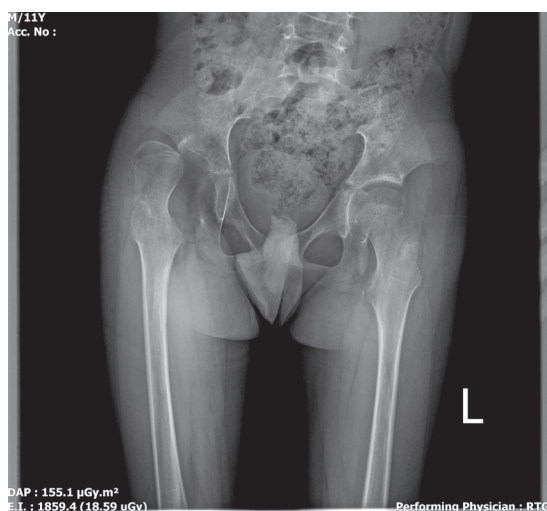


Figure 3. Preoperative radiograph of the pelvis showing right hip dislocation with a very deficient acetabulum.

crest and split. On the anterior and lateral surface of the iliac bone the gluteus medius and gluteus minimus muscles are separated from the gluteal surface of the iliac wing, TFL is detached from its proximal attachment point to the iliac crest, as are the sartorius muscle and both tendons of the rectus muscle. On the inside surface of the iliac wing, the iliacus muscle is subperiosteally elevated, and on the femoral part, the vastus lateralis muscle is detached from the capsule and proximal part of the femur using an „L“ shaped incision. The iliopsoas muscle is detached from its attachment to the lesser trochanter. The hip is entered through a straight capsular incision and the head is visualised. The elongated ligamentum teres is severed using strong scissors, as well as the transverse acetabular ligament. Any fatty tissue lining the acetabulum and obstructing subsequent reduction is removed. Once the acetabulum has been cleared, the varus derotational osteotomy of the proximal femur is performed. Often the situation necessitates femoral shortening, so a ring of bone, usually ranging in size from 1-2 centimetres,

is removed. We standardly utilise a blade plate to fix the osteotomy (Figure 4). After the femoral osteotomy is done, the attention is turned to the pelvis. In the case of patients with open triradiate cartilage, we common-

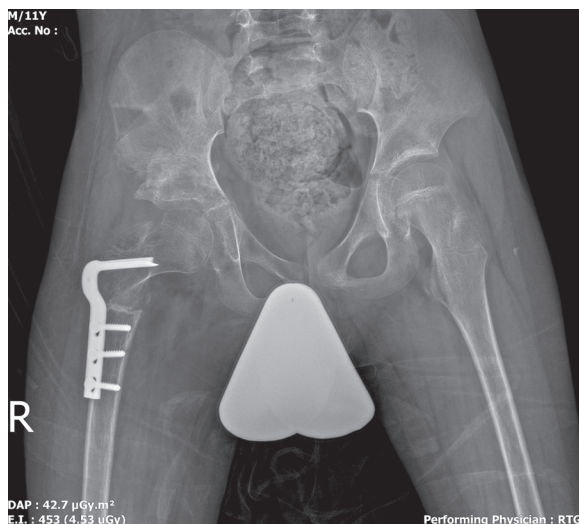


Figure 4. Postoperative right hip radiograph. Note the ring of femoral bone acquired during femoral shortening osteotomy used as bone graft at the site of the pelvic osteotomy.

ly use the Dega or the San Diego reshaping osteotomy, and once it has closed, we use the modified incomplete spheric osteotomy according to Brunner (Figure 5)^{10,11}. As the reshaping osteotomies consist of opening complex geometric structures in the pelvis itself, the resected part of the femur or resected parts of the iliac

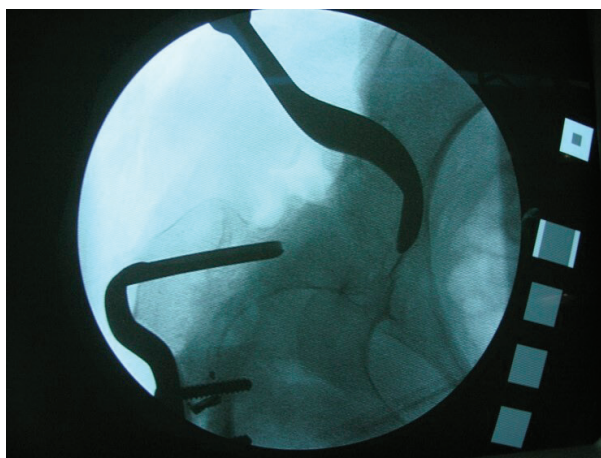


Figure 5. Intraoperative radiograph showing the semicircular chisel used for the semispheric periacetabular osteotomy.

crest were used as bone grafts. After reducing the hip, it is taken through a range of motion to ascertain the coverage, after which the joint capsule is reconstructed using non-resorbable sutures. The detached muscles are reattached to their respective attachment points on the pelvis and the wound is closed. No drainage is routinely used. The subcutaneous tissues are closed with interrupted resorbable sutures and the skin incision using a running subcuticular suture. A hip spica cast is placed and kept on for 6 weeks. After 6 weeks of immobilisation, the cast is taken off and physical therapy is started. Abduction orthotics are rarely used.

Results

There were 22 male and 28 female patients, 28 hips were dislocated and 28 subluxated, 25 right hips and 31 left hips were affected. The average patient age at the time of surgery was nine (range, 4 – 22 years). Thirty-six patients were GMFCS V, 11 patients GMFCS IV, and three patients GMFCS III.

A San Diego or Dega pelvic osteotomy was done in 49 hips, and seven hips underwent a Brunner-type pelvic osteotomy. The mean follow-up was seven years (range, 2 – 13 years). The median preoperative AI measured at 40° (range, 35° – 50°). The median postoperative AI at the time of the most recent follow-up was 22,5° (range, 5° – 40°). The average head migration index at the last follow-up was 10% (range, 0% – 60%).

In four hips, the migration index measured greater than 33%, which was evaluated as redislocation. There were two instances of infection in the hip adductor region, three patients had a recurrence of adductor contracture, one subtrochanteric fracture after hardware removal, and a case of pseudarthrosis of the femoral osteotomy resulting in a coxa vara deformity. All treated patients exhibited better sitting balance and could sit without pain for prolonged periods of time. Four patients later underwent posterior spinal fusion.

Discussion

In CP patients with whole body involvement, GMFCS classes III, IV, and V, hip subluxations and dislocations are relatively common. We treat every CP patient as if they have a hip issue until proven otherwise. These difficult hip problems significantly influence the activities of daily life in the case of the patients in question, such as sitting and taking care of hygiene, as well as cause pain. The only valid treat-

ment for neuromuscular hip subluxation and dislocation is surgery. The decision on the timing of surgery and the type of surgical procedure should be done by the team treating the child. Neuromuscular patients are well known to be prone to complications in the perioperative period, most often due to some degree of impaired intellectual and cognitive function, malnutrition, dehydration, epilepsy, gastro-esophageal reflux, and respiratory issues¹². Our results confirmed this propensity for various complications, with a rate of 20% in this patient series. A careful preoperative assessment by an anesthesiologist trained in paediatric anaesthesia is indispensable. Another common challenge in treating these patients is positioning them on the operating table, which can be difficult due to the presence of multiple contractures, pelvic obliquity, and additional spinal deformity¹³. A single incision anterior approach to the hip has been described in literature¹⁴. We describe the extended anterolateral approach that, in our opinion, provides excellent visualisation of the joint and enables practically any type of pelvic osteotomy to be performed. The anterolateral interval also reduces the chance of damaging the lateral femoral cutaneous nerve, so it does not need to be directly visualised as is the case in the anterior approach. It is very important to try and reduce the duration of surgery in these patients due to a higher risk of complications, so matters like this help keep the surgery time lower to a certain extent.

The limitations of this study come from its retrospective nature and the fact that we combined different GMFCS classes in one group. We believe that in future studies, the classes should be separated and expect the complication rates to be less pronounced in lower GMFCS class patients.

To conclude, hip reconstruction through a single incision utilising the anterolateral interval is a proven and valid option for all types of subluxations and dislocations in the CP patient with a higher degree of involvement. Using the one-incision technique provides better visualisation and a quicker and safer procedure. One could argue that this comes at the expense of the patient, due to a larger scar, a potential for more blood loss, and generally higher morbidity, but our complication rates are on par with other published studies^{1,7,8,9,10,11,12}. A well-thought-out surgical plan detailing the areas of the acetabulum that need to be augmented, calculating the necessary femoral shortening, and generous soft tissue release around the hip are

paramount in getting a good final result. We did not observe this surgery to improve the GMFCS class in our patient cohort.

Disclosure of conflict of interest

None.

References

1. Valencia FG. Management of hip deformities in cerebral palsy. *Orthop Clin North Am.* 2010;41(4):549-559. doi: 10.1016/j.ocl.2010.07.002.
2. Howard CB, McKibbin B, Williams LA, Mackie I. Factors affecting the incidence of hip dislocation in cerebral palsy. *J Bone Joint Surg Br.* 1985;67(4):530-532. doi: 10.1302/0301-620X.67B4.4030844.
3. Graham HK. Painful hip dislocation in cerebral palsy. *Lancet.* 2002;359:907-908. doi: 10.1016/S0140-6736(02)08015-7.
4. Đapić T, Čuti T, Antičević D, Šakić Š. Subluksacije i luksacije kukova u djece sa cerebralnom paralizom. *Pediatr Croat.* 2004;48:13-17.
5. Šmigovec I, Đapić T, Trkulja V. Ultrasound screening for decentered hips in children with severe cerebral palsy: a preliminary evaluation. *Pediatr Radiol.* 2014;44:1101-1109.
6. Larsen SM, Ramstad K, Terjesen T. Hip pain in adolescents with cerebral palsy: a population-based longitudinal study. *Dev Med Child Neurol.* 2021;63(5):601-607. doi: 10.1111/dmcn.14782.
7. Mubarak S, Valencia F, Wenger D. One-stage correction of the spastic dislocated hip. *J Bone Joint Surg Am.* 1992;9:1347-57.
8. McNerney NP, Mubarak SJ, Wenger DR. One-stage correction of the dysplastic hip in cerebral palsy with the San Diego acetabuloplasty: results and complications in 104 hips. *J Pediatr Orthop.* 2000;20(1):93-103.
9. Murar J, Dias LS, Swaroop VT. San Diego pelvic osteotomy in patients with closed triradiate cartilage. *J Child Orthop.* 2018;12(5):461-471. doi:10.1302/1863-2548.12.180046
10. and Czubak J, Kowalik K, Kawalec A, Kwiatkowska. Dega pelvic osteotomy: indications, results and complications. *J Child Orthop.* 2018;12(4):342-348. doi: 10.1302/1863-2548.12.180091.
11. Robb JE, Brunner R. A Dega-type osteotomy after closure of the triradiate cartilage in non-walking patients with severe cerebral palsy. *J Bone Joint Surg Br.* 2006;88(7):933-937. doi: 10.1302/0301-620X.88B7.17506.
12. Lee SY, Sohn HM, Chung CY, Do SH, Lee KM 3, Kwon SS, et al. Perioperative Complications of Orthopedic Surgery for Lower Extremity in Patients with Cerebral Palsy. *J Korean Med Sci.* 2015;30(4):489-494. doi: 10.3346/jkms.2015.30.4.489
13. Parry Prosser D, Sharma N. Cerebral palsy and anesthesia, Continuing Education in Anaesthesia Critical Care & Pain. *BJA.* 2010;10:72-76. doi: 10.1093/bjaceaccp/mkq013
14. Glorion C. Surgical reduction of congenital hip dislocation. *Orthop Traumatol Surg Res.* 2018;104(1S):S147-S157. doi: 10.1016/j.otsr.2017.04.021.

Sažetak

EKSTENDIRANI ANTEROLATERALNI PRISTUP KROZ JEDAN REZ ZA LIJEČENJE BOLESTI KUKA BOLESNIKA S CEREBRALNOM PARALIZOM

T. Đapić i O. Kubat

Cerebralna paraliza nosi sa sobom visok rizik od bolesti kuka, osobito u bolesnika s višim stupnjevima zahvaćenosti tijela. Subluksacije i dislokacije su učestale u bolesnika koji ne hodaju. Ovdje predstavljamo kohortu bolesnika liječenu kirurški upotrebom jednog reza i eksteniranog anterolateralnog pristupa na kuk. Ovaj rez i pristup na zglobov kuka omogućuju odličnu vizualizaciju svih važnih anatomskih struktura kao i izvođenje svih potrebnih zahvata unutar San Diego procedure. Od 2005. do 2018. godine 50 bolesnika (56 kukova) liječeno je San Diego operacijom. Bilo je 22 muških i 28 ženskih bolesnika, 28 dislokacija i 28 subluksacija. Prosječna dob bolesnika prilikom operacije bila je 9 godina (4 – 22 god.). San Diego, odnosno Dega osteotomija zdjelice učinjene su na 49 kukova, a na 7 osteotomija po Brunneru. Prosječno praćenje trajalo je 7 godina (2 – 13 god.). Srednja vrijednost preoperativno mjenjenog AI iznosila je 40° (35° - 50°), a postoperativno AI je mjerio 22,5° (5° – 40°). Prosječna vrijednost migracijskog indeksa glave na posljednjem pregledu iznosila je 10% (0% – 60%). Od komplikacija uočene su 4 redislokacije, 2 slučaja infekcije adduktorne regije, 3 povratne aduktorne kontrakture, 1 subtrohanterna fraktura te 1 slučaj pseudartroze femura. Svi bolesnici sun a posljednjoj kontroli pokazali bolji balans u sjedećem položaju te su sjedili bez bolova.

Ključne riječi: *cerebralna paraliza, kuk, osteotomija*