

Title	Orthodontic treatment in combination with Le Fort II bone distraction in patient with Apert syndrome.
Author(s)	Miyazaki, H; Katada, H; Ichinokawa, Y; Hirabayashi, S; Sueishi, K
Journal	Bulletin of Tokyo Dental College, 54(1): 9-17
URL	<a href="http://hdl.handle.net/10130/3287">http://hdl.handle.net/10130/3287</a>
Right	

## Case Report

# Orthodontic Treatment in Combination with Le Fort II Bone Distraction in Patient with Apert Syndrome

Haruyo Miyazaki, Hidenori Katada, Yoshimi Ichinokawa\*, Shinichi Hirabayashi\* and Kenji Sueishi\*\*

*Division of Orthodontics, Department of Clinical Oral Health Science, Tokyo Dental College,*

*2-9-18 Misaki-cho, Chiyoda-ku, Tokyo 101-0061, Japan*

*\* Department of Plastic, Oral and Maxillofacial Surgery, School of Medicine, Teikyo University,*

*2-11-1 Kaga, Itabashi-ku, Tokyo 173-8605, Japan*

*\*\* Department of Orthodontics, Tokyo Dental College, 1-2-2 Masago, Mihama-ku, Chiba 261-8502, Japan*

Received 13 August, 2012/Accepted for publication 2 November, 2012

## Abstract

We report a case of an 11-year-old girl presenting with Apert syndrome characterized by midface concavity, protrusion of the eyeballs, and ocular hypertelorism. She had class III anterior crossbite, narrow upper and lower arches, and marked crowding. Based on cephalometric analysis, anterior crossbite associated with marked midfacial hypoplasia was diagnosed. Orthodontic treatment in combination with Le Fort II maxillary distraction was scheduled. The dentition was laterally extended using a Rapid palatal expander in the upper jaw and a Bihelix in the lower jaw. Multi-bracket appliances were simultaneously applied for leveling. Next, Le Fort II maxillary osteotomy was performed to distract the midface bone 16mm anteroinferiorly using a rigid external distraction system. Orthodontic treatment was completed at 3.8 years after initiation. Bone distraction moved the upper jaw anteriorly downward, and the lower jaw subsequently rotated posteriorly downward, leading to a marked improvement in facial appearance and occlusion. Elongation of the dorsum of the nose, in particular, allowed esthetic improvement of the saddle nose. These improvements remain stable at 2 years after orthodontic treatment.

Key words: Apert syndrome — Orthodontics — Le Fort II — Distraction

## Introduction

Resulting from an autosomal dominant segregation pattern with a locus of a mutation at FGFR2 on chromosome 10q<sup>8</sup>, Apert syndrome is a congenital disease characterized

by craniosynostosis and syndactyly<sup>2)</sup>. Clinically, Apert syndrome is characterized by deformation of the skull, protrusion of the eyeballs, and midface hypoplasia<sup>1,2,5,6)</sup>, while in the oral cavity, narrowing and crowding of the dentition, open bite, and anterior crossbite can

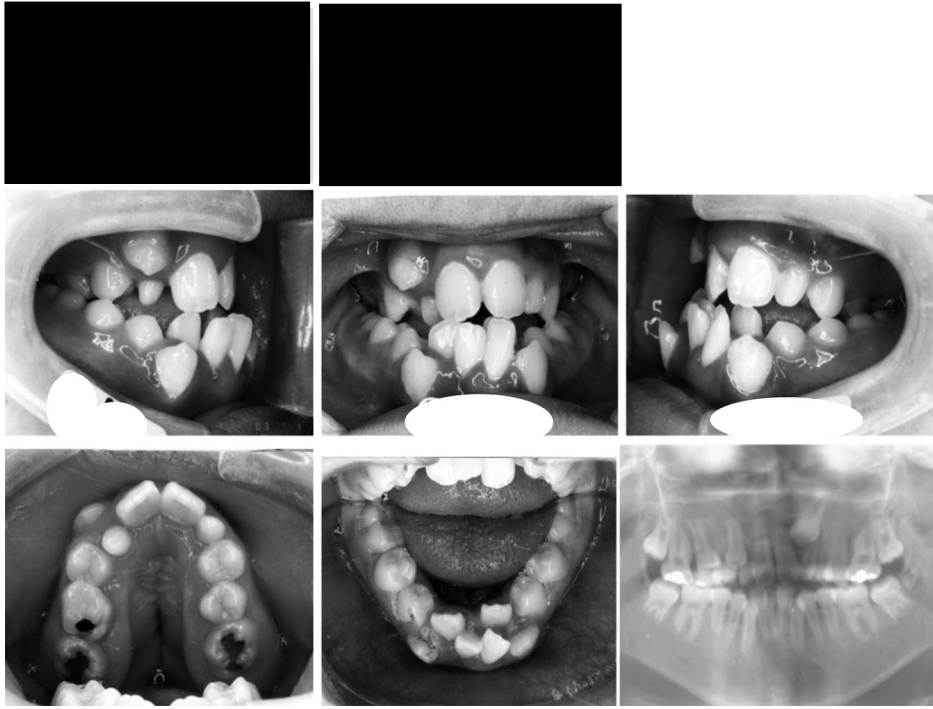


Fig. 1 Facial and intraoral photographs at pre-treatment

also be observed.

Distraction osteogenesis has been suggested as an alternative to traditional Le Fort III advancement in the treatment of Apert syndrome patients with severe midfacial hypoplasia<sup>12)</sup>.

In this report, we describe a rare case of orthodontic treatment in combination with Le Fort II distraction osteogenesis in an 11-year-old Apert syndrome patient who presented with severe maxillary hypoplasia and anterior crossbite, the outcome of which was favorable.

### Case

The patient was a girl with Apert syndrome aged 11 years and 3 months at the time of the first consultation. The patient visited our department with the chief complaints of crowding, open bite, and anterior crossbite. She had undergone anterior advancement of

the frontal bone, plastic surgery for polysyndactyly, and dacryocystorhinostomy. There was no familial medical history, and the patient was healthy and had no learning disabilities.

In profile, she had a class III skeletal relationship with midface concavity (Fig. 1). From the frontal view, she had protrusion of the eyeballs, ocular hypertelorism, and a short nose. Her tongue was positioned low in the oral cavity, making it necessary to breathe through her mouth.

She had class III total crossbite, narrowed dentition in the upper and lower jaws, and marked crowding in the front tooth region. Narrowing in the upper arch, in particular, was marked, and a pseudo cleft palate with a Byzantine-arch shape was noted. The dental age was III B, and the upper lateral incisors were dwarfed. A pantomogram showed that all the permanent teeth were present, but that the upper right canine overlapped the labial side of the lateral incisor, and the left canine was unerupted between the central

Table 1 Cephalometric measurements

	Pre-treatment 11y3m	Pre-surgery 12y7m	Post-surgery 13y0m	Post-treatment 15y7m	Retention (2y3m) 17y10m
SNA (°)	63.0	64.0	72.7	72.0	71.6
SNB (°)	76.0	70.6	67.9	66.8	67.0
ANB (°)	-13.0	-6.6	4.8	5.3	4.6
FX (°)	79.4	74.3	66.9	66.6	66.7
PP to FH (°)	-14.0	-12.0	5.5	6.6	7.1
FMA (°)	37.6	36.6	47.1	46.2	45.8
FMIA (°)	66.5	62.1	51.7	57.0	56.6
IMPA (°)	76.0	81.3	81.2	76.8	77.6
U1 to FH (°)	118.6	122.1	101.2	96.0	102.4
U1 to SN (°)	107.3	106.0	86.0	80.6	87.2
overjet (mm)	-4.8	-0.6	2.4	2.8	2.9
overbite (mm)	-1.2	-5.2	-0.3	1.7	0.3

SNA: Sella-Nasion-point A angle, SNB: Sella-Nasion-point B angle, ANB: Point A-Nasion-point B angle, FX: Facial Axis, PP to FH: Palatal plane to FH plane, FMA: Mandibular plane angle, FMIA: Frankfort Mandibular Incisor Angle, IMPA: Incisor Mandibular plane angle, U1 to FH: Upper incisor to FH plane, U1 to SN: Upper incisor to SN plane

and lateral incisors. In the lower dental arch, complete linguoversion of the left lateral incisor was observed.

A lateral cephalometric analysis indicated severe maxillary hypoplasia, a Class-III skeletal relationship, and a dolichofacial pattern with an SNA of 63.0°, ANB of -13.0°, FMA of 37.6°, and FX of 79.4° (Table 1). PP to FH was -14.0° oblique in the direction opposite to the normal direction. Labial inclination of the maxillary incisors and lingual inclination of the mandibular incisors yielded a U1 to FH of 118.6°, U1 to SN of 107.3°, and IMPA of 76.0°. Overjet was -4.8 mm and overbite was -1.2 mm, resulting in anterior crossbite with a shallow overlap. The treatment plan was as follows: (1) lateral expansion of upper and lower arch to resolve narrow arch; (2) attachment of multi-bracket appliance; (3) Le Fort II distraction osteogenesis using a rigid external distraction system (RED system, KLS Martin, Jacksonville, FL, USA) in order to correct midfacial hypoplasia; and (4) post-surgical orthodontic treatment with upper and lower lateral incisor extraction to resolve crowding.

Orthodontic treatment was initiated after the shedding of the right second primary

molar and eruption of the right second premolar. A rapid palatal expander was attached to the upper arch and a Bihelix expansion appliance to the lower arch for lateral expansion. Multi-bracket appliances were then attached after expansion (Fig. 2).

After pre-surgical orthodontic treatment, maxillary distraction osteogenesis with Le Fort II osteotomy was performed using the RED system and the maxilla extended forward and downward. Leibinger plates were fixed to the medial sides of the infraorbital foramina of the maxilla to allow it to be pulled outward *via* the nasal foramina. Halo bone distraction devices were attached to the bilateral sides of the skull. To rotate the maxilla clockwise, intermaxillary fixation screws were placed between the premolar roots. The wings of the nose were pliated to prevent widening.

At 7 days after surgery, bone distraction was started at a rate of 1 mm per day. Distraction was terminated at 16 mm as the esthetic results were considered satisfactory at this point by both the patient and the surgeon. The distraction devices were removed after 2 months. Bone distraction improved overjet and overbite, and the molar relation improved to mostly class I (Fig. 3).

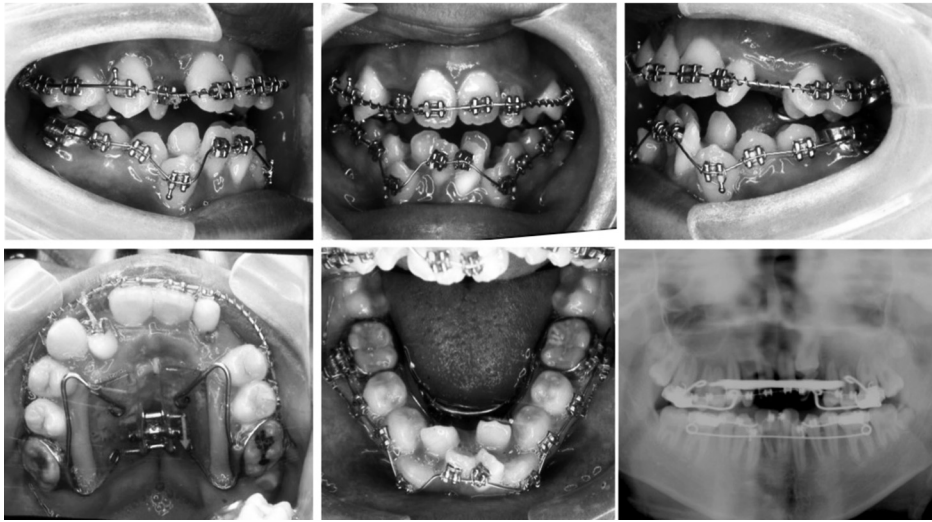


Fig. 2 Intraoral photographs at pre-surgery

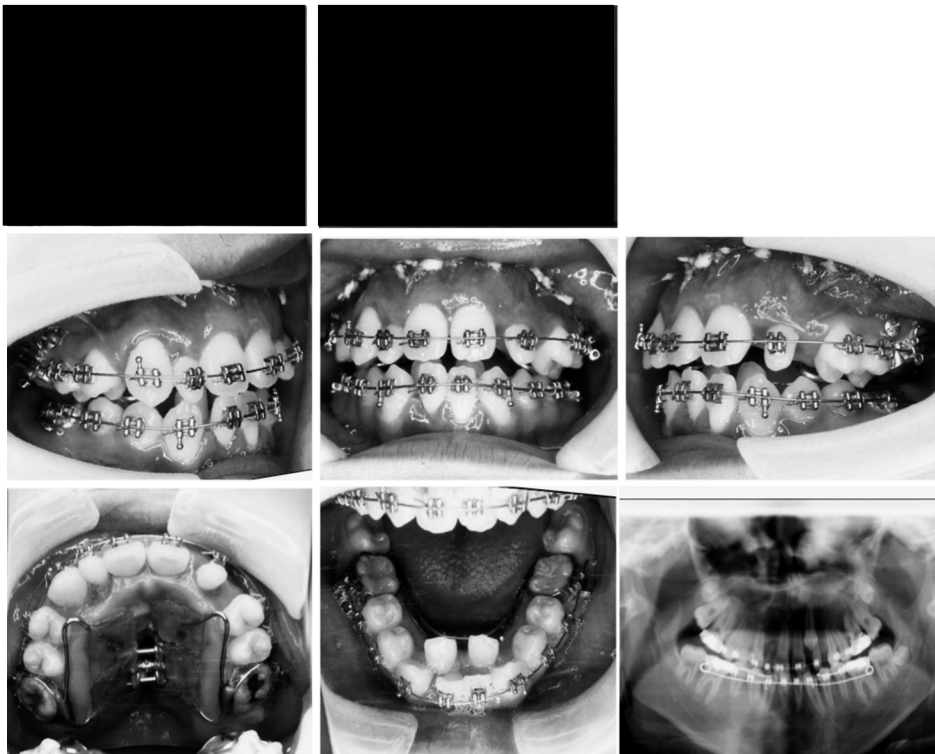


Fig. 3 Facial and intraoral photographs at post-surgery

Cephalometry revealed that the SNA increased from 64.0 to 72.7° and PP to FH increased from -12 to 5.5°. Thus, the mid-

face had been drawn clockwise in the anteroinferior direction (Fig. 4, Table 1). The FMA increased from 36.6 to 47.1°, the FX

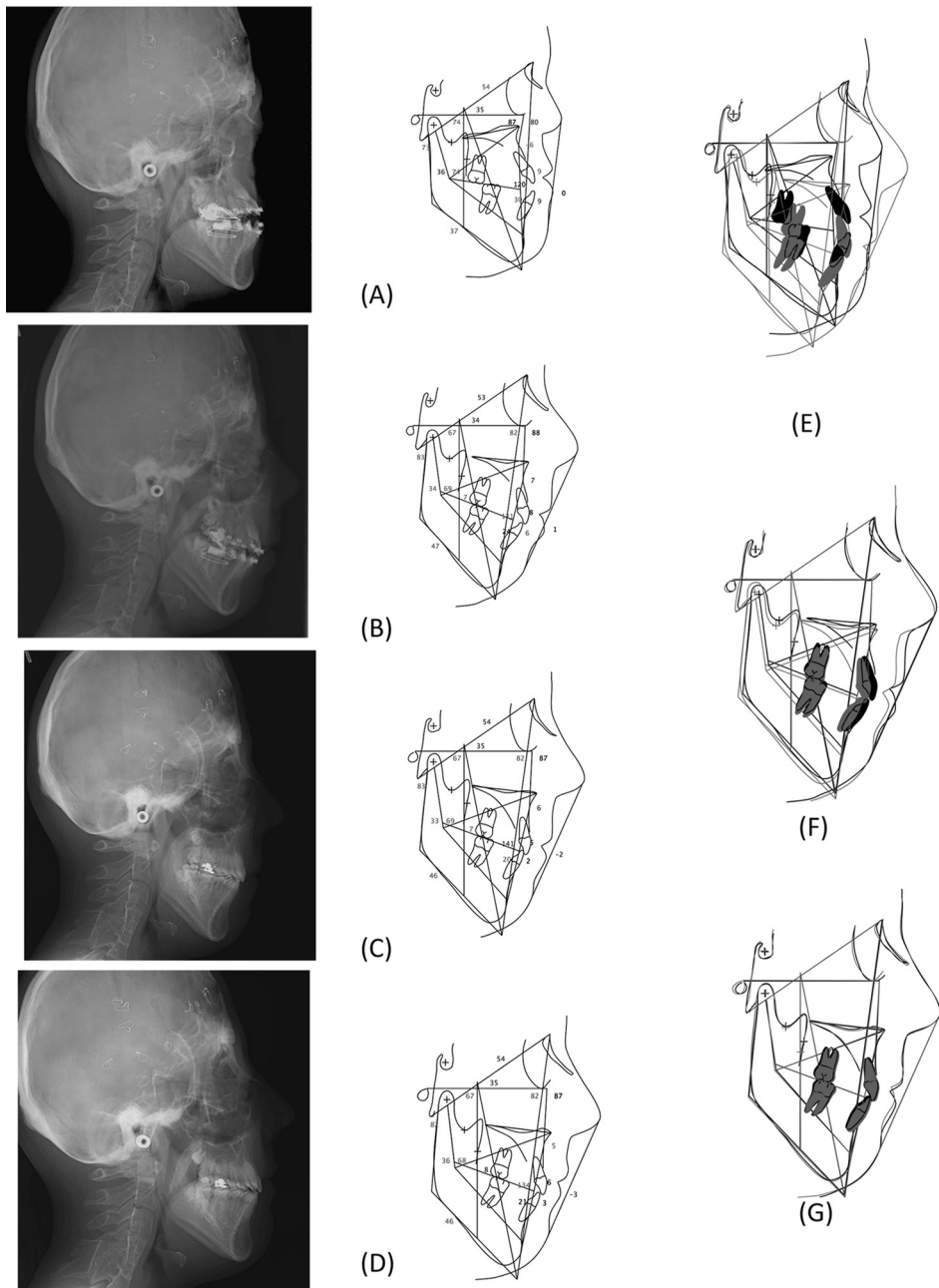


Fig. 4 Lateral cephalogram, cephalometric tracing and superimposition

(A) Pre-surgery, (B) Post-surgery, (C) Post-treatment, (D) 2 years retention, (E) Superimposition of pre-surgery and post-surgery, (F) Post-surgery and post-treatment, (G) Post-treatment and 2 years retention

decreased from  $74.3$  to  $66.9^\circ$ , and the SNB changed from  $70.6$  to  $67.9^\circ$ , indicating that the mandible had rotated in the posteroinfer-

rior direction. These changes resulted in a marked increase in ANB from  $-6.6$  to  $4.8^\circ$ . Regarding changes in the tooth axis, U1 to FH

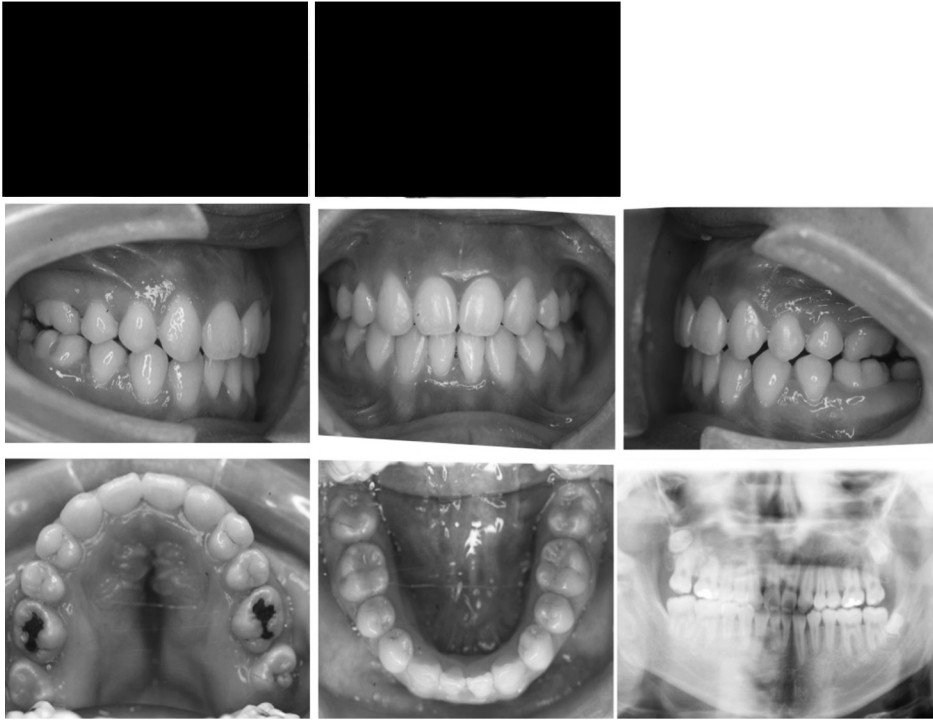

Fig. 5 Facial and intraoral photographs at post-treatment

changed from  $122.1$  to  $101.2^\circ$ , and U1 to SN changed from  $106.0$  to  $86.0^\circ$ , showing that the upper incisors had inclined toward the lingual side with clockwise rotation of midface.

Midface concavity and mandibular and eyeball protrusion were improved. Bone distraction-induced change in soft tissue elicited a particular improvement in the saddle-shape of the nose, elongating the nasal dorsum (Fig. 3). Reliance on mouth breathing was also alleviated.

Post-surgical orthodontic treatment was continued. At 6 months after surgery, the left upper canine erupted on the mesiolabial side of the lateral incisor. The upper and lower lateral incisors were extracted as the bilateral upper incisors were dwarfed and the lower bilateral incisors dislocated toward the lingual side.

Orthodontic treatment was completed at 3.8 years after initiation of treatment, by which time the patient was aged 15 years and 7 months (Fig. 5). After surgery to remove

the appliances, cephalometry revealed that the upper and lower incisors had inclined toward the lingual side, acquiring a normal overlap (Fig. 4).

Although facial elongation had occurred as a result of maxillary distraction in the antero-inferior direction and clockwise mandibular rotation, her upper and lower lips had moved to inside of the esthetic line and the patient was therefore satisfied with her facial condition and occlusion. The upper arch width markedly increased by 9 mm in the canine region and 14 mm in the molar region in comparison with at pretreatment.

At 17 years and 10 months of age, approximately 2 years after treatment, the patient was using a retainer and occlusion was stable (Fig. 6). No developmental change was noted, nor was there retrogression of the elongated region on cephalometric analysis (Fig. 4). The upper and lower central incisors were slightly inclined toward the labial side, and overbite became slightly shallower. A good facial pro-

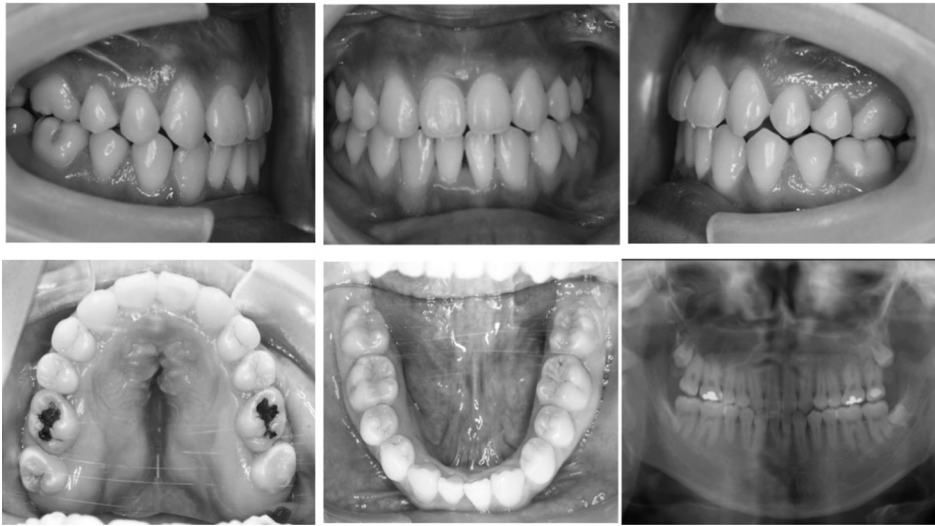


Fig. 6 Intraoral photographs at 2 years retention

file and occlusion were maintained.

### Discussion

Susami and Terashima<sup>15)</sup> reported that the characteristics of the maxillofacial morphology of Apert syndrome are an anterior position of the sphenothmoidal suture and shortened posterior base in the skull base region, vertical and horizontal hypoplasia in the maxillary region, ocular hypertelorism and posterior position in the orbital region, and increased mandibular ramus height in the lower jaw.

This disease results in a facial appearance characterized by deformation of the skull, protrusion of the eyeballs, and midface concavity. Le Fort I<sup>13,17)</sup>, II<sup>11)</sup>, and III<sup>3)</sup> midface advancements have been applied in such cases to improve occlusion, protect the eyeballs, and bring about airway and psychological improvements. Bone distraction has recently been applied as it allows marked skeletal changes to be obtained by minimally invasive surgery and elongation of soft tissue.

There are 2 methods of maxillary distraction to correct midfacial hypoplasia: elongation using an internal device<sup>7,9,18)</sup> for midface distraction and RED systems<sup>4,12,16,18)</sup>. The RED

system used in the present case was developed by Polley and Figueroa<sup>12)</sup> in 1997. This is a halo rigid external distraction system, in which the maxillary traction device is attached using the skull as an anchorage unit, setting the fulcrum to the skull, and the maxilla gradually lengthened.

Although RED systems are externally visible, they offer an advantage over internal devices in that they allow greater control over the direction of the distraction<sup>12)</sup>. This is why a RED system was selected in the present patient.

Distraction osteotomy has been reported with Le Fort I, II, and III. Le Fort I distraction<sup>4,9,14)</sup> does not allow advancement of the nasomaxillary complex or improvement of protrusion of the eyeballs or facial deformity. Le Fort III and II distraction<sup>7,10,16,18)</sup>, on the other hand, does allow advancement of the nasomaxillary complex, and Le Fort III is used when advancement of outside of orbit was required. Le Fort III distraction is a well-established method for nasal elongation. On the other hand, Le Fort II<sup>9,12)</sup> is often not selected as it requires an incision to be made into the skin at the root of the nose.

In the present patient, Le Fort II midfacial distraction osteogenesis allowed the medial



side of the orbits and anterior portion of the infraorbital borders to be moved antero-inferiorly, thus improving eyeball protrusion. The dacryocystorhinostomy scars were used for the skin incisions at the root of the nose. Traction was applied through the nasal foramina to avoid injuring soft tissue such as the upper lip with the traction wire. Elongation causes counter-clockwise rotation around the root of the nose, which can easily result in open bite in the front tooth region. To avoid this, Intermaxillary fixation screws were placed in the maxillary and mandibular alveolar bone and elastic bands hooked onto them to apply vertical distraction. This procedure moved the midface anteroinferiorly and rotated the lower jaw posteroinferiorly, leading to a favorable facial profile.

Only developmental and orthodontic changes in the tooth axes were observed after completion of bone distraction, with no change in the elongated midface position. Little change was noted at 2 years after treatment, and the outcome of orthodontic treatment in combination with Le Fort II bone distraction remains stable.

### Conclusion

Orthodontic treatment in combination with Le Fort II distraction osteogenesis allowed an improvement in facial features and occlusion in an Apert syndrome patient who had presented with severe maxillary hypoplasia and anterior crossbite.

### References

- 1) Cohen MM Jr, Kreiborg S (1996) A clinical study of the craniofacial features in Apert syndrome. *Int J Oral Maxillofac Surg* 25:45–53.
- 2) Cohen MM Jr, Kreiborg S (1993) An updated pediatric perspective on the Apert syndrome. *Am J Dis Child* 147:989–993.
- 3) Hitotsumachi J, Imajo K, Kawai S (2001) A case report of open bite with Apert's syndrome. *J Kin-To Orthod Soc* 36:67–73. (in Japanese)
- 4) Kitai N, Kawasaki K (2003) Rigid external distraction osteogenesis for a patient with maxillary hypoplasia and oligodontia. *Cleft Palate Craniofac J* 40:207–213.
- 5) Kreiborg S, Aduss H, Cohen MM Jr (1999) Cephalometric study of the Apert syndrome in adolescence and adulthood. *J Craniofac Genet Dev Biol* 19:1–11.
- 6) Kreiborg S, Cohen MM Jr. (1992) The oral manifestations of Apert syndrome. *J Craniofac Genet Dev Biol* 12:41–48.
- 7) Kurata K, Okafuji N (2006) Examination of the direction and quantity extension following distraction osteogenesis in Apert Syndrome. *Jpn Jaw Deform* 16:196–204. (in Japanese)
- 8) Matsumoto K, Urano Y, Kubo Y (1998) Mutation of the fibroblast growth factor receptor 2 gene in Japanese patients with Apert syndrome. *Plast Reconstr Surg* 101:307–311.
- 9) Mitsukawa N, Satoh K (2005) Clinical trial of Zurich Internal Distraction System for maxillary retrusion in cleft and palate patients. *J Jpn P R S* 25:431–438. (in Japanese)
- 10) Mitsukawa N, Satoh K, Hayashi T (2004) Salvaged Le Fort II halo distraction for an unfavorable outcome of midfacial distraction using an internal device in syndromic craniosynostosis. *Plast Reconstr Surg* 113:1219–1224.
- 11) Nakagawa K, Yamada K, Saito I (2007) A case report of Apert syndrome with mid-facial deficiency treated by surgical orthodontic treatment combined with Le Fort II osteotomy. *J Ko-Shin Orthod Soc* 15:20–25. (in Japanese)
- 12) Polley JW, Figueroa AA (1997) Management of severe maxillary deficiency in childhood and adolescence through distraction osteogenesis with an external, adjustable, rigid distraction device. *J Craniofac Surg* 8:181–185.
- 13) Rynearson RD (2000) Case report: orthodontic and dentofacial orthopedic considerations in Apert's syndrome. *Angle Orthod* 70:247–252.
- 14) Shinohara K, Baba Y (2008) A case report of Crouzon syndrome with anterior crossbite and maxillary lateral deviation treated with Le Fort I distraction osteogenesis using RED system. *Jpn J Jaw Deform* 18:39–48. (in Japanese)
- 15) Susami T, Terashima T (1986) Morphological evaluation on craniofacial dysmorphology of Apert's syndrome and Crouzon disease. *J Jpn Orthod Soc* 45:674–686. (in Japanese)
- 16) Takashima M, Kitai N, Murakami S (2006) Dual segmental distraction osteogenesis of the midface in a patient with Apert syndrome. *Cleft Palate Craniofac J* 43:499–506.
- 17) Verdonck A, Bertrand J, Carels C, Swinnen S, Schoenaers J (2010) Orthodontic and

- orthognathic management of a patient with Apert syndrome: a case report. *J Orthod* 37: 121–127.
- 18) Wakae H, Hanaoka K, Morishita T (2008) A clinical report on distraction osteogenesis applied for Apert syndrome. *Orthodontic Waves* 67:30–37.

*Reprint requests to:*

Dr. Haruyo Miyazaki  
Division of Orthodontics,  
Department of Clinical Oral  
Health Science,  
Tokyo Dental College,  
2-9-18 Misaki-cho, Chiyoda-ku,  
Tokyo 101-0061, Japan  
E-mail: miyazaki@tdc.ac.jp