

Title	Morphological evaluation of meibomian glands using noncontact infrared meibography
Author(s) Alternative	Ban, Y; Shimazaki-Den, S; Tsubota, K; Shimazaki, J
Journal	The ocular surface, 11(1): 47-53
URL	http://hdl.handle.net/10130/2973
Right	

**Morphological Evaluation of Meibomian Glands Using Noncontact Infrared
Meibography**

Yumiko Ban, MD, Ph.D., ^{1,2} Seika Shimazaki-Den, MD, Ph.D., ¹

Kazuo Tsubota, MD, Ph.D., ² Jun Shimazaki, MD, Ph.D. ^{1,2}

¹ Department of Ophthalmology, Tokyo Dental College, School of Dental Medicine, Chiba,
Japan

² Department of Ophthalmology, School of Medicine, Keio University, Tokyo, Japan

This work was presented at World Cornea Congress IV, Boston, MA, USA, April 7-9, 2010.

Grant support: This study was supported by grant #22791690 from the Japanese Ministry of
Education, Culture, Sports, Science and Technology (Tokyo, Japan).

Short running title: Morphological evaluation of meibomian glands

Keywords: Noncontact infrared meibography, Meibomian glands, Length of meibomian gland
duct, Percent area of meibomian gland acini, Meibomian gland dropout, Meibomian gland
morphology, Aging, Ocular surface

Correspondence and reprint requests to: Yumiko Ban, MD, Ph.D.

Department of Ophthalmology, Tokyo Dental College, School of Dental Medicine, Chiba,
Japan

5-11-13 Sugano, Ichikawa City, Chiba, Japan 272-8513

Tel: 81-47-322-0151, Fax: 81-47-322-6786

E-mail: yumiko-b@pk9.so-net.ne.jp

The authors have no proprietary or commercial interests in any concept or product discussed in this article.

ABSTRACT

Meibography is used to study morphological changes in the meibomian glands (MGs), and semiquantitative analysis has been used for MG assessment. Here, we conducted a detailed morphometric assessment of MGs using noncontact infrared meibography (NIM) and investigated the relationship between MG morphology and the ocular surface and MG morphology associated with aging and sex in 37 subjects. The MGs in the upper and lower eyelids showed significant correlations in their morphology, with the former having longer ducts than the latter. The mean length of the MG ducts, percent area of MG acini, and number of gland dropouts were significantly correlated with age. The mean length of the MG ducts in the upper and lower eyelids showed negative correlations with the meibum ($p=0.043$) and fluorescein staining score ($p=0.008$), respectively. The percent area of MG acini in the upper eyelid showed a positive correlation with tear film breakup time ($p=0.012$) and negative correlations with tear film lipid layer interferometry and meibum ($p=0.005$ and 0.002 , respectively). The mean length of the male's MG ducts in the lower eyelid was significantly longer than that of the females. ($p=0.03$) These results indicate that morphometric analysis using NIM may be useful for assessing ocular surface conditions.

I. INTRODUCTION

Meibomian glands (MGs) secrete lipids into tears, forming a superficial lipid layer that stabilizes the tear film layer. MG dysfunction (MGD) is a major cause of dry eye¹ and is often associated with symptoms of irritation, an unstable tear film, damage to the ocular surface epithelium, chronic blepharitis, contact lens intolerance, and giant papillary conjunctivitis.²⁻⁶

A quantitative evaluation of MG morphology and/or function is important to assess the severity of MGD and the effects of therapeutic interventions. Existing methods for assessing MG status and function include slit-lamp examination of the lid margins, meibometry,^{7,8} analysis of meibomian secretions,⁹ *in vivo* confocal microscopy,^{10,11} and meibography.¹²⁻¹⁷

Meibography is a technique that yields information on the morphological characteristics of MGs by observing their silhouette through retroillumination of the everted eyelids from the skin side.¹⁴⁻¹⁷ Recently, noncontact infrared meibography (NIM) was developed, which allows the noncontact observation of MG structure without causing any discomfort to the patient.¹³

While conventional meibography is difficult to apply to the upper eyelid, NIM allows observation over a wide area encompassing both the lower and upper eyelids.¹³ However, to date, only a semiquantitative assessment of MG destruction (i.e., MG dropout) has been made using conventional meibography and NIM. Although the degree of gland dropout has been shown to be correlated with ocular surface conditions, including the lid margin abnormality score,¹³ a detailed analysis of MG morphology using NIM may yield more information regarding the role of MGs in ocular surface health. Here, we conducted a morphometric assessment of the MG using NIM and investigated the relationship between MG morphology and condition of the tear film and ocular surface epithelium.

II. PATIENTS AND METHODS

A total of 37 eyes in 37 healthy subjects were enrolled in this prospective study. The subjects included 23 males and 14 females with a mean age of 46.5 ± 15.4 years (range 19-75 years). The number of subjects in each age group is shown in Table 1. The exclusion criteria included eyes with obvious eyelid or ocular surface disorders, contact lens wear, history of ocular surgery, and dry eye according to the Japanese Dry Eye Criteria.¹⁸ The Japanese Dry Eye Criteria is as follows: 1. dry eye symptoms, 2. tear abnormalities (Schirmer test without anesthesia ≤ 5 mm or a tear film breakup time [TBUT] of ≥ 5 s), and 3. ocular surface epithelial damage (fluorescein staining score ≥ 3 , rose-bengal staining score ≥ 3 , or lissamingreen staining score ≥ 3). The definition of dry eye is applied to all subjects (1-3).¹⁸ The data used in this study were obtained from the right eye of each subject. This study was performed in accordance with the tenets of the Declaration of Helsinki, and informed consent was obtained from all subjects. This study was approved by the institutional review board of Tokyo Dental College.

The examination was performed sequentially as follows: a slit-lamp examination (including fluorescein staining of the ocular surface), TBUT, expression of MG secretion (meibum), tear film lipid layer interferometry (TFLLI), NIM, and Schirmer test I. The fluorescein staining scores for the ocular surface ranged from 0 to 9 points. The ocular surface was divided into three zones: nasal conjunctival, corneal, and temporal conjunctival. A staining score between 0 and 3 points was employed in each zone, with the minimum and maximum total staining scores ranging from 0 to 9 points. The standard TBUT measurement was performed after instillation of 2 μ L of 1% fluorescein preservative-free solution into the conjunctival sac with a micropipette.¹⁹ The subjects were instructed to blink several times for a few seconds to ensure adequate mixing of the dye. The interval between the last complete blink and

appearance of the first corneal blink spot in the stained tear film was measured three times and the mean values were calculated. TFLLI (Kowa, Tokyo, Japan) was performed to evaluate the tear film; lipid layer grading classification was performed as reported previously.²⁰

The expression of meibum was graded as described by Shimazaki et al.⁹ Briefly, to assess obstruction of the MG orifices, digital pressure was applied to the upper tarsus and the expression of meibum was scored semiquantitatively as follows: grade 0, clear meibum, easily expressed; grade 1, cloudy meibum, expressed with mild pressure; grade 2, cloudy meibum, expressed with more than moderate pressure; and grade 3, no meibum expressed even under strong pressure. A single observer (YB) pressed gently on the upper eyelids to express the meibomian lipid.

The NIM apparatus consisted of a slit lamp (RO 5000; Rodenstock, Munich, Germany) with a magnifying power of 12 and an infrared charge-coupled device video camera (XC-EI50; Sony, Tokyo, Japan).¹³ The upper and lower eyelids were turned over and MG morphology observed. We also examined the meiboscore.¹³ The digital images obtained by meibography were recorded and analyzed using ImageJ software (Java software program developed by the National Institutes of Health; available at <http://rsb.info.nih.gov/ij/>). Dynamic images were captured as static images. For the static images, a central area 10 mm in length and 13 mm in width was selected (Figure 1). This measurement was selected based on a preliminary morphometric analysis, and we found that examination of the whole eyelid width was not possible in all cases. We measured and calculated the mean value for the length of the five selected central MG ducts. If five central MG ducts were not available for observation, three or four were analyzed. We defined a rectangle measuring 4 mm along the central lid margin and 5 mm along the upper eyelid and a square measuring 4 mm × 4 mm along the central lid margin and lower eyelid. White images of the lesions were converted to black images using

ImageJ software. We measured the percent area of MG acini contained within the rectangle selected. The number of gland dropouts contained in the image was also determined. For tear secretion measurement, the standard Schirmer test I was performed without topical anesthesia. Sterilized strips of filter paper (Showa Yakuhin Kako Co. Ltd., Tokyo, Japan) were placed in the lower conjunctival sac for 5 min.

All data are presented as means \pm standard deviation (SD). Comparisons were performed between the two groups using an unpaired *t*-test and the Mann-Whitney test. Pearson and Spearman rank-sum tests were performed to determine correlations between the MG morphological values and tear film or epithelia. Intergroup differences were evaluated by one-way ANOVA. GraphPad InStat 3 (GraphPad Software, San Diego, CA) was used for statistical analyses. $p < 0.05$ was taken to indicate significance.

III. RESULTS

A. Tear Function and Ocular Surface

The mean Schirmer test I results and TBUT were 11.4 ± 9.21 mm and 6.00 ± 2.87 s, respectively. The mean fluorescein staining score was 0.41 ± 0.76 points. The mean TFLLI and meibum scores were 2.16 ± 1.26 and 1.14 ± 1.03 , respectively.

B. MG Morphological Evaluation

The mean meiboscore was 1.56 ± 2.00 . Images for evaluating the length of the upper and lower MG ducts were obtained successfully in most cases (94.6 and 97.3%, respectively). The percent area of MG acini in the lower eyelid could be assessed in most cases (83.8%), but that in the upper eyelid could be evaluated in only 20 cases (54.1%). The mean length of the MG ducts in the upper eyelid was significantly longer than that in the lower eyelid (5.53 ± 1.27 vs. 2.97 ± 0.90 mm, $p < 0.0001$). No significant differences were observed in the mean percent

area of MG acini or number of gland dropouts between the upper and lower eyelids ($p=0.874$ and 0.135 , respectively) (Table 2).

The MG duct length in the upper and lower eyelids showed a positive correlation ($R=0.582$, $p=0.0003$). The percent areas of MG acini in the upper and lower eyelids were also positively correlated ($R=0.669$, $p=0.003$).

C. Correlation between MG Morphology and the Ocular Surface

Table 3 shows the correlations between the MG morphometric values and status on either tear film or ocular surface epithelium. The MG duct length in the upper eyelid showed a negative correlation with the meibum expression score ($R=-0.345$, $p=0.043$). The length of the MG ducts in the lower eyelid showed a negative correlation with the fluorescein staining score ($R=-0.438$, $p=0.008$). The percent area of MG acini in the upper eyelid showed a positive correlation with TBUT ($R=0.549$, $p=0.012$) and negative correlations with the TFLLI and meibum expression scores ($R=-0.601$, $p=0.005$ and $R=-0.641$, $p=0.002$, respectively). The number of gland dropouts in the upper eyelid showed positive correlations with the TFLLI and meibum expression scores ($R=0.457$, $p=0.006$ and $R=0.404$, $p=0.016$, respectively) and a negative correlation with TBUT ($R=-0.432$, $p=0.010$).

D. Relationship with Aging

The mean MG duct length and percent area of MG acini were negatively correlated with age. The number of gland dropouts showed a positive correlation with age (Table 3). Figures 2 and 3 show the changes in MG morphology in each age group. Both the length of the MG duct and percent area of MG acini decreased gradually with age, except for the percent area of MG acini in the lower eyelid (Table 4).

E. Relationship with Sex

Table 5 shows the relationship of sex with MG morphology. The mean length of the male's

MG ducts in the lower eyelid was significantly longer than that of the females. ($p=0.03$)

IV. DISCUSSION

MGD is a chronic, diffuse abnormality of the MG, commonly characterized by terminal duct obstruction and/or qualitative/quantitative changes in glandular secretion. This condition may result in alterations to the tear film, symptoms of eye irritation, clinically apparent inflammation, and ocular surface disease.²¹ To our knowledge, this is the first morphological assessment of MGs, including the length of the MG ducts and mean percent area of MG acini in both the upper and lower eyelids. Most previous studies using meibography assessed MGs according to the degree of gland dropout. In addition, many of these earlier studies examined only changes in the MG in the central lower eyelid as conventional meibography only allows the observation of a relatively small area of the MG.^{5,6,9,14,15,22} NIM enables observation of the MG over a wide area encompassing both the upper and lower eyelids, from the temporal to the nasal MGs, allowing a detailed morphological analysis to be carried out easily. In the present study, although an analysis of the upper lid was unsuccessful in some cases, morphometric analysis was available in the majority of the eyes. We did not examine the reproducibility and repeatability quantitatively. However, we analyzed the clearest image captured from the video image for the purpose of lessening the difference as much as possible. Future improvements in camera and video systems may improve the success rate of evaluation.

The observation of MG morphology in healthy subjects yielded several important findings in the present study. The upper MG ducts were significantly longer than the lower MG ducts. This was due to anatomical differences between the upper and lower tarsus, with the former being larger than the latter.²⁴ Although this anatomical difference has already been described in cadavers,²⁴ this is the first observation of this difference *in vivo*. We also found strong

correlations between the MG morphology in the upper and lower eyelids.

We investigated the relationship between MG morphology and the condition of either the tear film or ocular surface epithelium. Many previous studies using conventional meibography utilized the degree of gland dropout as a parameter of MGD, and extensive dropout was shown to be associated with increased tear evaporation.^{4,9,23} Arita et al.¹³ reported that the degree of gland dropout (meiboscore) assessed using NIM was related to various conditions, including aging and the lid margin abnormality score. In this study, we did not assess the scoring of lid margin abnormalities, however, we excluded eyes with an obvious eyelid margin change. The relationship with the clinical score of MGD must be examined. The results of the present study indicate that MG morphology (other than gland dropout) was also related to several ocular surface conditions. The MG duct length and percent area of MG acini were correlated with changes in the ocular surface and tear film, including TBUT, fluorescein staining score, TFLLI, or meibum. Our results indicate that a detailed MG morphological evaluation using NIM may yield additional information regarding ocular surface health. None of the morphometric parameters were significantly correlated with the results of the Schirmer test (Table 3). This is not surprising as the Schirmer test measures the tear secretion volume, which is only indirectly related to the MG. TFLLI is determined not only by the quantity and/or quality of the meibomian lipid but also by the aqueous tear volume. The mean tear film lipid layer interference was 2.16 ± 1.26 . Yokoi et al reported that normal eyes classified into grades 1 and 2, and dry eyes classified into grades 2, 3, 4 and 5 in the tear film lipid layer interference.²⁰ The subjects showed a more colorful interference pattern, this seems to be caused by the fact that some subjects had low tear volume and greater expression of meibomian lipid. The results of the present study indicate that the morphological parameters of the MG in the upper eyelid were more closely correlated with

the conditions of the tear film and epithelia than those in the lower eyelid. This may have been due to anatomical differences between the two eyelids, as the number and length of MGs in the upper eyelids were greater than those in the lower eyelids.²⁴ Therefore, it seems important to examine the MGs in the upper eyelids, which cannot be performed easily with conventional contact meibography.

One intriguing observation in the present study was that there was great variety in MG morphology, even in the healthy volunteers. We conclude that the wide variation in MG morphology may be similar to that in other ocular surface parameters such as TBUT or the Schirmer test. Minor alterations in MGs might be compensated for by other MGs. While we observed some correlation between MG morphology and tear function tests, they might not represent a cause-and-effect relationship. In other words, some mutual factors such as chronic inflammation might be attributable to both changes. We believe that the relationship between the morphological and functional changes in the MG is important and requires investigation.

Age was strongly correlated with MG duct length, percent area of MG acini, and number of gland dropouts. Several studies have indicated increased changes in the MGs with aging, and our results are in good agreement with these earlier reports.^{13,22}

Previous studies have revealed that the prevalence of dry eye is high in elderly women.²⁵⁻²⁸ However, to our knowledge, no report investigating sex and MGD has been published. In fact, Den et al reported that as to MG dropouts, men older than 70 years tended to show more changes in their MGs compared with women.²² The mean length of the male's MG ducts in the lower eyelid was significantly longer than those of the females. This may have been due to physical differences between the sexes. Further study is necessary to examine such differences.

Our study had drawbacks related to patient recruitment and the relatively small sample size.

As this study was conducted among healthy subjects, the subjects fell into a variety of categories. The exclusion criteria in the present study included obvious eyelid or ocular surface disorders, contact lens wear, eye surgery, and dry eye. However, we may have included patients with subclinical local or systemic abnormalities that may have interfered with the condition of the MG and/or ocular surface. Further study of the changes in subjects belonging to different categories (e.g., patients with dry eye) is needed.

In summary, morphometric assessment of the MGs using NIM indicated that MG morphology showed significant correlations with aging and the condition of the tear film or ocular surface epithelium. Evaluations of MG morphology should provide new and valuable information regarding ocular surface health.

REFERENCES

1. Lemp MA. Report of the National Eye Institute/Industry workshop on Clinical Trials in Dry Eyes. *CLAO J* 1995;21:221-32.
2. Henriquez AS, Korb DR. Meibomian glands and contact lens wear. *Br J Ophthalmol* 1981;65:108-11.
3. Zengin N, Tol H, Gunduz K, et al. Meibomian gland dysfunction and tear film abnormalities in rosacea. *Cornea* 1995;14:144-6.
4. Shimazaki J, Sakata M, Tsubota K. Ocular surface changes and discomfort in patients with meibomian gland dysfunction. *Arch Ophthalmol* 1995;113:1266-70.
5. Mathers WD, Shields WJ, Sachdev MS, et al. Meibomian gland dysfunction in chronic blepharitis. *Cornea* 1991;10:277-85.
6. Mathers WD, Billborough M. Meibomian gland function and giant papillary conjunctivitis. *Am J Ophthalmol* 1992;114:188-92.
7. Chew CK, Jansweijer C, Tiffany JM, et al. An instrument for quantifying meibomian lipid on the lid margin: the Meibometer. *Curr Eye Res* 1993;12:247-54.
8. Yokoi N, Mossa F, Tiffany JM, et al. Assessment of meibomian gland function in dry eye using meibometry. *Arch Ophthalmol* 1999;117:723-9.
9. Shimazaki J, Goto E, Ono M, et al. Meibomian gland dysfunction in patients with Sjögren syndrome. *Ophthalmology* 1998;105:1485-8.
10. Matsumoto Y, Sato EA, Ibrahim OM, et al. The application of *in vivo* laser confocal microscopy to the diagnosis and evaluation of meibomian gland dysfunction. *Mol Vis* 2008;14:1263-71.
11. Ibrahim OM, Matsumoto Y, Dogru M, et al. The efficacy, sensitivity, and specificity

of *in vivo* laser confocal microscopy in the diagnosis of meibomian gland dysfunction.

Ophthalmology 2010;117:665-72.

12. Tapie R. Biomicroscopical study of Meibomian glands [in French]. *Ann Ocul (Paris)*

Tear Film Epithelia 1977;210:637-48.

13. Arita R, Itoh K, Inoue K, et al. Noncontact infrared meibography to document age-related changes of the meibomian glands in a normal population. *Ophthalmology*

2008;115:911-5.

14. Nichols JJ, Berntsen DA, Mitchell GL, et al. An assessment of grading scales for meibography images. *Cornea* 2005;24:382-8.

15. Mathers WD, Daley T, Verdick R. Video imaging of the meibomian gland. *Arch Ophthalmol* 1994;112:448-9.

16. Robin JB, Jester JV, Nobe J, et al. *In vivo* transillumination biomicroscopy and photography of meibomian gland dysfunction. A clinical study. *Ophthalmology* 1985;92:1423-6.

17. Yokoi N, Komuro A, Yamada H, et al. A newly developed video-meibography system featuring a newly designed probe. *Jpn J Ophthalmol* 2007;51:53-6.

18. Shimazaki J (Dry Eye Workshop). Definition and diagnosis of dry eye 2006. *Atarashiiganka* 2007;24:181-4 [In Japanese].

19. Toda I, Tsubota K. Practical double vital staining for ocular surface evaluation. *Cornea* 1993;12:366-7.

20. Yokoi N, Takehisa Y, Kinoshita S. Correlation of tear lipid layer interference patterns with the diagnosis and severity of dry eye. *Am J Ophthalmol* 1996;122:818-24.

21. Nelson JD, Shimazaki J, Benitez-del-Castillo JM, et al. The International Workshop on Meibomian Gland Dysfunction: report of the definition and classification subcommittee.

Invest Ophthalmol Vis Sci 2011;52:1930-7.

22. Den S, Shimizu K, Ikeda T, et al. Association between meibomian gland changes and aging, sex, or tear function. *Cornea* 2006;25:651-5.

23. Mathers WD. Ocular evaporation in meibomian gland dysfunction and dry eye. *Ophthalmology* 1993;100:347-51.

24. Wolff E. The anatomy of the eye and orbit (Ed. Warwick, R). 1976, ed. 7, London: H.K. Lewis & Co.

25. Moss SE, Klein R, Klein BE. Prevalence of and risk factors for dry eye syndrome. *Arch Ophthalmol* 2000;118:1264-8.

26. Schaumberg DA, Sullivan DA, Buring JE, et al. Prevalence of dry eye syndrome among an US women. *Am J Ophthalmol* 2003;136:318-26.

27. Lin PY, Tsai SY, Cheng CY, et al. Prevalence of dry eye among an elderly Chinese population in Taiwan. The Shihpai Eye Study. *Ophthalmology* 2003;110:1096-101.

28. Schein OD, Munoz B, Tielsch JM, et al. Prevalence of dry eye among the elderly. *Am J Ophthalmol* 1997;124:723-8.

Legends for figures

Figure 1.

The static image was 10 mm long and 13 mm wide.

Digital meibography images were analyzed using ImageJ software.

Figure 2.

Mean length of the MG duct in each age group.

White and colored bars denote the MG duct lengths in the upper and lower eyelids, respectively.

Figure 3.

Mean percent area of the MG in each age group.

White and colored bars denote the MG duct lengths in the upper and lower eyelids, respectively.

Figure1




Figure 2

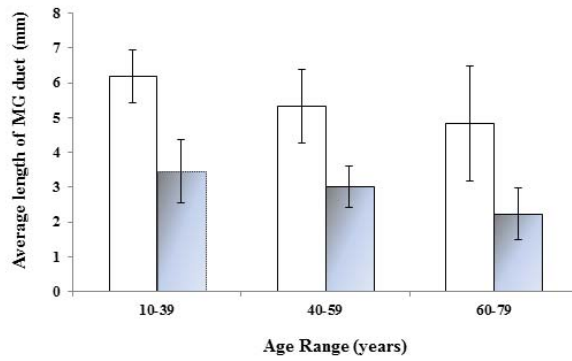


Figure 3

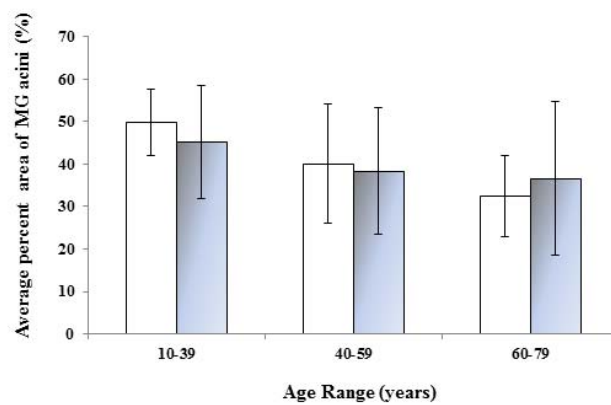


Table 1

Number of subjects in each age group

	Age (years)						
	10-19	20-29	30-39	40-49	50-59	60-69	70-79
Men	0	3	9	3	3	3	2
Women	1	0	2	4	2	4	1
Total	1	3	11	7	5	7	3

Table 2

Results of morphometric analysis on upper and lower eyelids and their success rate

	Upper eyelid	Lower eyelid	p value
Length of MG duct (mm)	5.53 ± 1.27 **	2.97 ± 0.90	< 0.0001
Number of eyes with successful evaluation (%)	35 (94.6%)	36 (97.3%)	
Percent area of MG acini (%)	41.6 ± 12.4	41.0 ± 15.1	0.874
Number of eyes with successful evaluation (%)	20 (54.1%)	31 (83.8%)	
Number of gland drop-outs			0.135
0	27	22	
1	2	2	
2	0	4	
≥ 3	6	9	
Unsuccessful rate	2 (5.41%)	0 (0%)	

MG = Meibomian gland

** = p < 0.0001

Table 3

Correlation between morphometric values of meibomian glands and tear film or ocular surface epithelia

		age	Schirmer	TBUT	FS	TFLLI	meibum
Length of MG	Upper	-0.485*	0.087	0.246	-0.223	-0.116	-0.345 [#]
duct	Lower	-0.533**	-0.080	0.211	-0.438 [#]	-0.241	-0.312
Percent area of	Upper	-0.592*	0.0475	0.549*	-0.367	-0.601 [#]	-0.641 [#]
MG acini	Lower	-0.357*	-0.352	0.208	-0.069	-0.032	-0.207
Number of	Upper	0.518 [#]	-0.254	-0.432 [#]	0.212	0.457 [#]	0.404 [#]
gland drop-outs	Lower	0.399 [#]	-0.018	-0.199	0.253	0.250	0.189

MG = Meibomian gland

TBUT = Tear film break up time

FS = Fluorescein staining score

TFLLI = Tear film lipid layer interferometry

* = $p < 0.05$, ** = $p < 0.001$, Pearson r

[#] = $p < 0.05$, Spearman r

Table 4

Association of the mean length of the meibomian gland ducts and the percent area of meibomian gland acini with aging

Age group (year)		≤39	40-59	≥60	p
Length of MG duct (mm)	Upper	6.19 ± 0.77	5.33 ± 1.07	4.83 ± 1.64	.0238 *
	Lower	3.46 ± 0.90	3.02 ± 0.59	2.23 ± 0.74	.0019 *
Percent area of MG acini (%)	Upper	49.8 ± 7.82	40.1 ± 14.0	32.4 ± 9.60	.022 *
	Lower	45.2 ± 13.3	38.3 ± 14.9	36.6 ± 18.0	.366

MG = Meibomian gland

*= p<0.05

Table 5

Association of the mean length of the meibomian gland ducts and the percent area of meibomian gland acini with sex

sex		Men	Women	p
Mean age (years)		44.5 ± 15.5	49.7 ± 15.2	.32
Length of MG duct (mm)	Upper	5.65 ± 1.31	5.36 ± 1.23	.52
	Lower	3.23 ± 0.93	2.57 ± 0.69	.03 *
Percent area of MG acini (%)	Upper	44.6 ± 12.1	36.2 ± 12.0	.16
	Lower	43.2 ± 14.8	37.0 ± 15.5	.28
Number of gland drop outs	Upper	0.41 ± 1.05	0.85 ± 1.28	.14
	Lower	1.0 ± 1.28	1.0 ± 1.41	.90

MG = Meibomian gland

*= p< .05