



Title	Magnetoencephalographic study of the starting point of voluntary swallowing
Author(s)	Abe, S; Wantanabe, Y; Shintani, M; Tazaki, M; Takahashi, M; Yamane, GY; Ide, Y; Yamada, Y; Shimono, M; Ishikawa, T
Journal	Cranio : the journal of craniomandibular practice, 21(1): 46-49
URL	<a href="http://hdl.handle.net/10130/1101">http://hdl.handle.net/10130/1101</a>
Right	

## Magnetoencephalographic Study of the Starting Point of Voluntary Swallowing

Shinichi Abe, D.D.S., Ph.D.; Yutaka Wantanabe, D.D.S.; Masuro Shintani, D.D.S.; Masakazu Tazaki, D.D.S.; Masanori Takahashi, D.D.S.; Gen-yuki Yamane, D.D.S.; Yoshinobu Ide, D.D.S.; Yoshiaki Yamada, D.D.S.; Masaki Shimono, D.D.S.; Tatsuya Ishikawa, D.D.S.

**ABSTRACT:** Clear findings relative to where in the brain the starting point of voluntary swallowing is controlled were obtained in the present magnetoencephalographic study. Namely, the cerebral activity was observed in the cingulate gyrus and supplementary motor area for about 80 ms between 1,000 and 1,500 ms before swallowing in all test subjects. Thus, it is clear that this type of central control mechanism also plays an important role in complicated swallowing movements.

0886-9634/2101-046\$05.00/0, THE JOURNAL OF CRANIOMANDIBULAR PRACTICE, Copyright © 2003 by CHROMA, Inc.

Manuscript received January 16, 2002; revised manuscript received September 19, 2002; accepted September 19, 2002.

Address for reprint requests:

Dr. Shinichi Abe  
Tokyo Dental College  
Dept. of Anatomy  
1-2-2 Masago, Mihama-ku  
Chiba-shi, Chiba 261-8502  
Japan  
e-mail: shinabe@tdc.ac.jp

---

**Dr. Shinichi Abe** received his D.D.S. degree from Tokyo Dental College in 1989. He graduated from post-doctoral school with a Ph.D. degree in 1993. Currently, he is an associate professor in the Department of Anatomy at Tokyo Dental College.

---

**Dr. Yutaka Wantanabe** received his D.D.S. degree from Tokyo Dental College in 1989. Currently, he is an assistant fellow in the Department of Oral Medicine at Tokyo Dental College.

---

**Dr. Masuro Shintani** received his D.D.S. degree from Tokyo Dental College in 1983. He is an assistant fellow in the Laboratory of Brain Research at Tokyo Dental College.

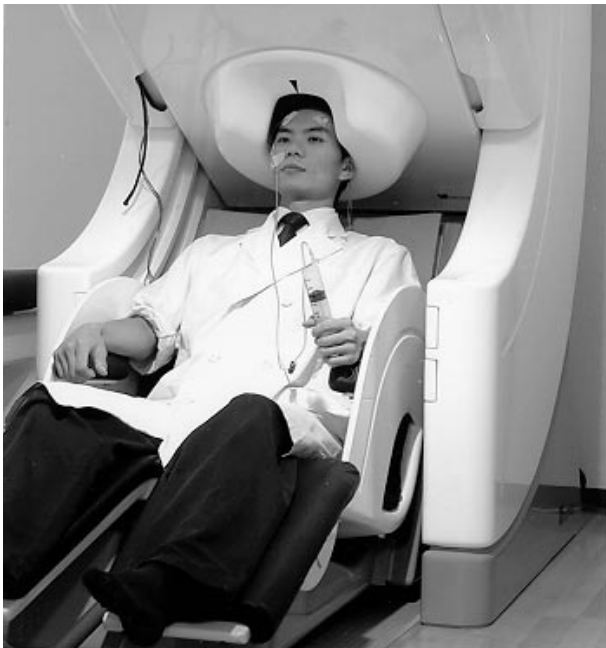---

It is reported that physiological swallowing movement starts voluntarily from swallowing in the oral phase prior to pharyngeal swallowing, and it has been demonstrated that pharyngeal swallowing is also influenced by the higher central nervous system.<sup>1,2</sup> However, because the subjects in those reports were animals, the experimental data cannot be applied to humans with higher cerebral functions. Recently, positron emission tomography (PET),<sup>3,4</sup> functional magnetic resonance imaging (f-MRI),<sup>5-7</sup> and electroencephalography (EEG)<sup>8</sup> have been frequently used to study human cerebral functions. Furthermore, due to the development of magnetoencephalography (MEG),<sup>9</sup> in which electrical activities in the human cerebral cortex can be measured noninvasively with high spatial and temporal resolutions, the estimation of the localization of the trigger functions in the cerebral cortex has become possible. This study investigates whether the decision to drink is made just before swallowing, using a 306-channel whole-head neuromagnetometer.

### Materials and Methods

The subjects were three right-handed healthy adults with no disorders of their oral functions. Each subject held a syringe containing mineral water, and a tube was extended and fixed into the oral cavity so that the subject

could control the transfer of the mineral water into the oral cavity. Using a 306-channel whole head SQUID (superconducting quantum interference device) neuro-magnetometer (Vectorview, Neuromag Inc., Helsinki, Finland), we obtained a whole magnetic field from 102 points on the skull and then determined the first derivatives of two directions (longitudinal and latitudinal) perpendicular to this magnetic field. The trigger was the electromyogram produced by stimulation of the venter anterior of the digastric muscle with a surface electrode, i.e., the rise of integral waveforms was considered the starting point of movements. All responses were digitized at a sampling rate of 601 Hz. Then, a small amount of mineral water (about one cc) was transferred from the syringe into the oral cavity, and after placing the water on the tongue for at least five seconds, each subject swallowed the water by consciously controlled drinking (Figure 1). MEG signals obtained during the period from minus 2,500 ms to plus 500 ms from the onset of the EMG signal were averaged. Each subject was asked to sit on a chair in a magnetically shielded room, close their eyes, and not move their eyeballs. The data were analyzed every five seconds to extract time periods with a GOF (goodness of fit) value greater than 80%. Next, we analyzed the cortical distribution and time course of the slow magnetic field accompanying swallowing, and determined the location of the equivalent current dipole on the MRI.



**Figure 1**  
Photograph showing how the experiment was done and the equipment used.

## Results

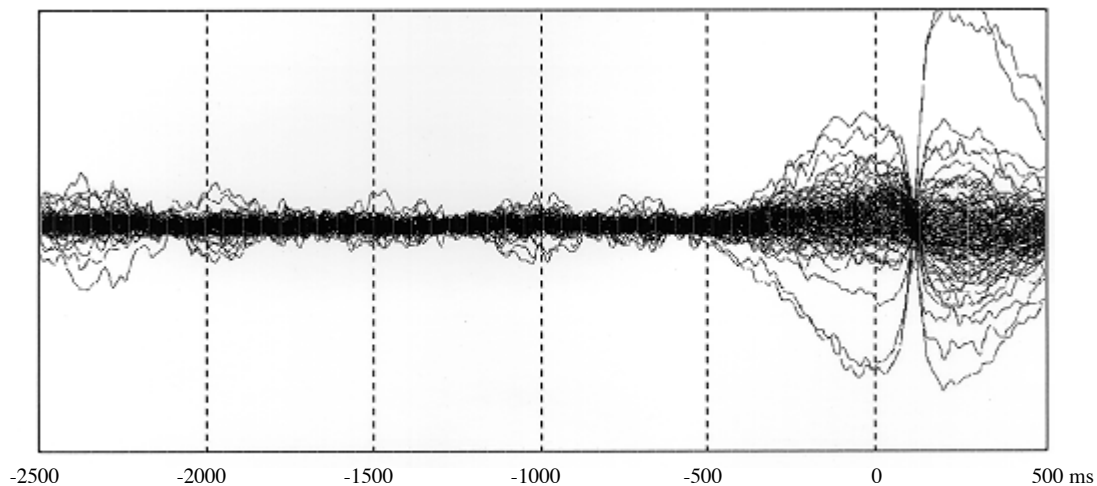
The above-mentioned water swallowing procedure was repeated 50 times, and the cerebral magnetic field from 2,500 ms before swallowing to 500 ms after swallowing was added to improve the S/N ratio (Figure 2). These data were analyzed every five ms to extract time periods with a GOF value of more than 80%.<sup>10,11</sup> GOF values greater than 80% indicated a fairly high probability of the presence of magnetic field sources. Based on an average of five measurements, the GOF values were greater than 80% at 1,405-1,479 ms before swallowing for the first subject; 1,335-1,419 ms before swallowing for the second subject; and 1,170-1125 ms before swallowing for the third subject.

We estimated the locations of magnetic field sources for the time periods with GOF values greater than 80% and compared these with MRI scans. It was estimated that dipoles were located in the cingulate gyrus and supplementary motor area. Also, it was estimated that dipoles were located in both the left and right hemispheres. This finding was the same in all three subjects (Figure 3).

## Discussion

In the present study, water was placed on the tongue of each test subject, then the subject was asked to wait at least five seconds, and lastly the subject consciously swallowed the water with a certain rhythm. There were some time differences in the swallowing rhythm (a series of movements from consciously thinking about drinking to actually starting to drink) among the test subjects, but these differences did not affect the outcome of the study. Our intention was to perform MEG to clearly ascertain where the conscious control of drinking is organized. Each test subject spent some time practicing the above-mentioned water swallowing procedure so that he/she could consciously swallow water with a certain rhythm. In a preliminary study, MEG was also recorded after swallowing, but we were mainly interested in estimating, with a high degree of probability, electrical activity sources in the cerebral cortex more than 1,000 ms before swallowing. This activity only lasted for a limited time, and thus the source could not be estimated before or after that time. Therefore, we analyzed magnetic field sources and electrical activity present in the cerebral cortex 1,000 ms before swallowing.

The results of animal studies have identified the area involved in the central control of swallowing movements. Narita, et al.<sup>12</sup> cooled the mastication area and the swallow cortex which overlaps the mastication area, and documented the following: decreases in masticating and

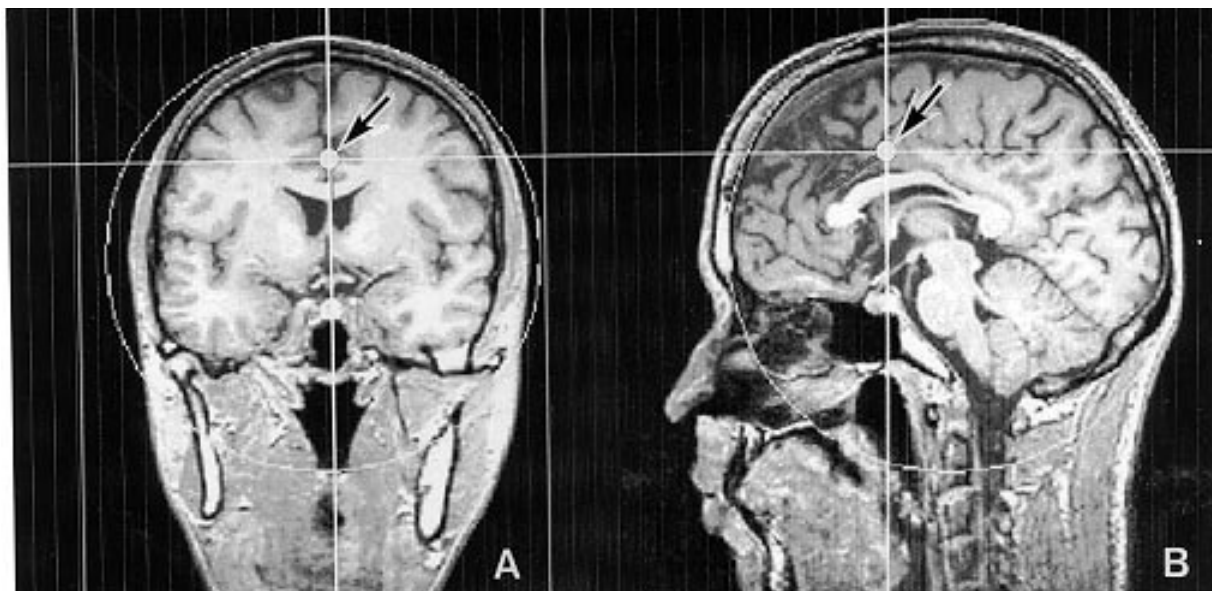


**Figure 2**

The swallowing trigger time was regarded as 0 ms, and all changes in the magnetic field in the cerebral cortex between 2,500 ms before swallowing and 500 ms after swallowing were overlapped. Slight changes (negative slope) started 500 ms before swallowing began. Greater changes in the magnetic field occurred during swallowing. The nerve activity sources were estimated at a high probability in the cingulate gyrus and supplementary motor area between 1,500 ms and 1,000 ms before swallowing (Subject 2).

swallowing movements; impairment of the masticating rhythm formation; and reduced masseter muscle activities. Also, the results of a study in which the left and right mastication areas of rabbits were excised showed that the transition from masticating to the early stage of swallowing was difficult. In these studies, the cortical area that is

directly involved in masticating and swallowing was identified.<sup>13</sup> However, the methodologies were not sufficient to identify the starting point of voluntary swallowing; i.e., conscious swallowing. Due to the recent advances in neuromagnetometers, their temporal resolution is as high as that of electroencephalographs, and when a signal



**Figure 3**

Overlapping of the nerve activity sources on MRI images. **A:** Frontal cross-section; **B:** Sagittal cross-section. A nerve activity source was estimated to be present at the position indicated by an arrow which may be in the cingulate gyrus. (Estimation on the MR image of the nerve activity sources 1,405 ms before swallowing in Subject 2.)

source is localized, spatial resolution is also high.<sup>14</sup> We utilized these properties of neuromagnetometers to identify the starting point of voluntary swallowing<sup>6</sup> and were able to show that intracerebral processes involved in swallowing activities, including those within the swallowing cortex, could be located using the present method. In the present study, it was estimated that a dipole was present in the cingulate gyrus 1,000-1,500 ms before swallowing. The cingulate gyrus belongs to the old cortex and forms a section of the limbic system.<sup>15</sup> It is reported that the cingulate gyrus differentiates from the hippocampus during embryological development, and thus develops into the supplementary motor area. Thus, based on memory from the hippocampus for swallowing and the item about to be swallowed, subsequent reaction sorting may be performed in the cingulate gyrus. At that point requests, in the form of recognition and movement, are transmitted to the supplementary motor area to prepare for swallowing.

**References**

1. Bieger D, Hockman CH: Suprabulbar modulation of reflex swallowing. *Exp Neurol* 1976; 52:311-324.
2. Weerasuriya A: Basal forebrain facilitation of reflex swallowing in the cat. *Brain Res* 1979; 174:119-133.
3. Hamdy S, Rothwell JC, Brooks DJ, Bailey D, Aziz Q, Thompson DG: Identification of the cerebral loci processing human swallowing with H2 150 PET activation. *J Neurophysiol* 1999; 81:1917-1926.
4. Shibasaki H, Sadato N, Lyshkow H: Both primary motor cortex and supplementary motor area play an important role in complex finger movement. *Brain* 1993; 116:1387-1398.
5. Boecker H, Kleinschmidt T, Requardt A: Functional cooperation of human cortical motor areas during self-paced simple finger movements: a high resolution MRI study. *Brain* 1994; 117:1231-1239.
6. Hamdy S, Mikulis DJ, Crawley A, Xue S, Lau H, Henry S, Diamant NE: Cortical activation during human volitional swallowing: an event-related f-MRI study. *Am J Physiol* 1999; 99:219-225.
7. Martin RE, Goodyear BG, Gati JS, Menon RS: Cerebral cortical representation of automatic and volitional swallowing in human. *Am J Physiol* 2001; 01:219-225.
8. Shibasaki H, Barret G, Halliday E: Components of the movement-related cortical potential and their scalp topography. *Electroenceph Clin Neurophysiol* 1980; 49:938-950.

9. Cheyne D, Weinberg H, Gaetz W, Jantzen KJ: Motor cortex activity and predicting side of movement: neural network and dipole analysis of pre-movement magnetic fields. *Neurosci Lett* 1995; 188:81-84.
10. Nakasato N: Cortical mapping using an MRI-linked whole head MEG system and presurgical decision making. *Electroencephalogr Clin Neurophysiol [Suppl]* 1996; 47:333-341.
11. Yumoto M: Recent advances of MEG. *Jpn J Clin Pathpl* 2000; 48:38-41.
12. Narita N: Effects of functional disruption of lateral pericentral cortex on primate swallowing. *Brain Res* 1999; 824:140-145.
13. Enomoto S: The effects of cortical ablation on mastication in the rabbit. *Neurosci Lett* 1987; 82:162-166.
14. Weinberg H: Electroencephalographic and magnetoencephalographic studies of motor function. *Adv Neurol* 1990; 54:193-205.
15. Goldberg G: Supplementary motor area structure and function: review and hypothesis. *Behav Brain Sci* 1985; 8:567-615.

---

**Dr. Masakazu Tazaki** received his D.D.S. degree from Tokyo Dental College in 1978. He is an associate professor in the Department of Physiology at Tokyo Dental College.

---

**Dr. Masanori Takashashi** received his D.D.S. degree from Keio University in 1972. He is currently a professor in the Department of Orthopaedic Surgery at Tokyo Dental College.

---

**Dr. Gen-yuki Yamane** received his D.D.S. degree from Tokyo Dental College in 1970. He is a professor in the Department of Oral Medicine at Tokyo Dental College.

---

**Dr. Yoshinobu Ide** received his D.D.S. degree from Tokyo Dental College in 1974. Currently, he is a professor in the Department of Anatomy at Tokyo Dental College.

---

**Dr. Yoshiaki Yamada** received his D.D.S. degree from Niigata University in 1974. He is a visiting professor in the Laboratory of Brain Research at Tokyo Dental College.

---

**Dr. Masaki Shimono** received his D.D.S. degree from Tokyo Dental College in 1970. He is a professor in the Department of Pathology at Tokyo Dental College.

---

**Dr. Tatsuya Ishikawa** received his D.D.S. from Tokyo Dental College in 1955. Currently, he is a professor in the Department of Operative Dentistry at Tokyo Dental College.

---