



Title	A potential reference point for assessment of condylar bone marrow of the temporomandibular joint on proton density weighted images
Author(s)	Yamamoto, A; Sano, T; Otonari-Yamamoto, M; Nishikawa, K; Kwok, E
Journal	Cranio : the journal of craniomandibular practice, 26(4): 246-252
URL	http://hdl.handle.net/10130/1100
Right	

A Potential Reference Point for Assessment of Condylar Bone Marrow of the Temporomandibular Joint On Proton Density Weighted Images

Aya Yamamoto, D.D.S.; Tsukasa Sano, D.D.S., Ph.D.; Mika Otonari-Yamamoto, D.D.S., Ph.D.; Keiichi Nishikawa, Ph.D.; Edmund Kwok, Ph.D.

0886-9634/2604-246\$05.00/0, THE JOURNAL OF CRANIOMANDIBULAR PRACTICE, Copyright © 2008 by CHROMA, Inc.

Manuscript received January 8, 2008; accepted June 3, 2008

Address for correspondence:

Dr. Aya Yamamoto
Department of Oral and Maxillofacial Radiology
Tokyo Dental College
1-2-2, Masago, Mihama-ku,
Chiba, 261-8502 Japan
E-mail:
yamamotoaya@tdc.ac.jp

ABSTRACT: The purpose of this research was to determine a potential reference point for measurement of signal intensity of bone marrow of the condyle on proton density-weighted images (PDW) prior to analysis of bone marrow abnormality related to symptomatic osteoarthritis of the temporomandibular joint (TMJ). The study was based on 79 joints in 41 patients. The regions of interest (ROI) were placed over the bone marrow of the condyle and four other structures. It was hypothesized that a correlation between signal intensity of ROI over bone marrow and that of another structure would provide a potential reference point for measurement of signal intensity of bone marrow. A significant positive linear correlation was found in the group for gray matter-1 and bone marrow. The correlation coefficient was 0.3 (Pearson correlation coefficient; $p < 0.05$). It was determined that gray matter is a potential reference point in evaluating the signal intensity of bone marrow in the mandibular condyle.

Dr. Aya Yamamoto received her D.D.S. degree from Tokyo Dental College, Chiba, Japan, in 2005. She is a graduate student of Oral and Maxillofacial Radiology, Tokyo Dental College, in Chiba, Japan.

There are several possible sources of temporomandibular joint (TMJ) pain, including alterations in the bone marrow of the mandibular condyle, osteoarthritis,¹⁻⁵ impingement and compression of the retrodiscal tissue,^{6,7} inflammatory changes in the retrodiscal tissue,^{8,9} inflammatory changes in the joint space resulting in joint effusion¹⁰ and capsulitis.¹¹⁻¹³ Osteoarthritis is suggested as a source of pain, but is also often seen in asymptomatic subjects.¹⁻⁵ Cortical bone abnormalities are probably the main reason associated with pain. However, pain sources related to osteoarthritis may be varied. Other factors should be considered to estimate symptomatology in patients with osteoarthritis of the TMJ. Zanetti, et al.¹⁴ demonstrated that in cases of osteoarthritis of the knee joint, ill-defined bone marrow abnormalities occur adjacent to the affected joint. Felson, et al.¹⁵ also reported that bone marrow edema is a potent risk factor for structural deterioration in knee osteoarthritis. There is, however, no report on such bone marrow changes in symptomatic osteoarthritis of the TMJ. The proton density weighted image (PDW) is widely used to determine the disk position, morphology, and osteoarthritis. According to Larheim, et al.¹⁶ signal intensity of bone

marrow abnormality of the mandibular condyle on PDW tends to be decreased. In the current clinical work, however, the PDW signal of symptomatic osteoarthritis likely shows various patterns. To resolve this contamination, it was necessary to clarify the bone marrow signal in osteoarthritis. There is no formula for evaluation of signal intensity in magnetic resonance (MR) imaging such as CT number because of the changing signal intensity in the position of the coil and the amplifier gain of the image reconstruction circuitry. To arrive at such a formula, a reference point for measurement of the signal intensity of bone marrow in osteoarthritis would be needed. The final purpose was to analyze bone marrow abnormality related to symptomatic osteoarthritis of the TMJ on PDW, which is often and routinely imaged in TMJ management. In this study, the purpose was to determine a potential refer-

hospital in advance of participation in the study.

MR imaging was performed with a 1.5 Tesla MR imager (Magnetom Symphony, Siemens, Erlangen, Germany), using a double loop array coil. Bilateral TMJ images were obtained in closed-mouth position (**Table 2**). A fast spin echo sequence was used. The axial scout view was obtained parallel to the occlusal plane. Views were selected according to the position on the long axis, where the widest area was available between the lateral and medial poles. Corrected sagittal images were obtained perpendicular to the long axis and axial view. The images were saved as Digital Imaging and Communications in Medicine (DICOM) files and read for measurement of signal intensity using a public domain software, ImageJ 1.32j (National Institutes of Health, USA) for image analysis. The region of interest (ROI) was selected only

Table 1
Criteria for Interpretation of the MR Images

Inclusion criteria for joints without osteoarthritis:

Osseous components with evidence of normal cortical bone and any of disc position criteria, as follows:

- Disk located with its posterior band superior to the condyle in the closed- and open-mouth positions (normal disk position).
- Posterior band of disk-located anterior, medial, or lateral to the normal position on top of the condyle in the closed-mouth position and normal condyle located between the anterior and posterior bands of the disk in the open-mouth images (disk displacement with reduction).
- Posterior band of disk-located anterior, medial, or lateral to the condyle during all mandibular movements (disk displacement without reduction).

Inclusion criteria for joints with osteoarthritis:

Osteoarthritis evident as osteophytes, erosions, or deformity of condyle and/or temporal component with evidence of disk displacement without reduction.

ence point for measurement of the signal intensity of bone marrow at a specific portion of the condyle, possibly related to osteoarthritis on PDW.

Materials and Methods

The study was based on 79 joints in 41 patients selected from a consecutive series of 206 joints in 103 patients referred to the hospital for MR imaging of the TMJ. The mean age of the participants in this study was 36.0 years. There were 13 males and 28 females. These 79 joints diagnosed had normal disk position with normal function on PDW according to **Table 1** adopted from Sano, et al.¹⁷

Informed consent was obtained from each patient in accordance with the Declaration of Helsinki and approval was obtained from an Institutional Review Board of the

Table 2
Magnetic Resonance (MR) Imaging Parameters

Time of repetition/	
time of echo (msec)	3300/14
Number of signal averages	1
Field of view (cm)	150x150
Slice thickness (mm)	3.0
Matrix	512x512
Scan time (sec)	171
Flip angle (degree)	180
Matrix	512x512
GAP thickness (mm)	0.6

Table 3
Signal Intensity of Each Structure On Proton Density-Weighted Images (PDW)

	Mean	Standard Deviation	Range
Bone marrow	3448.22	783.22	2023.46-4966.64
Gray matter-1	2905.07	782.36	1197.98-4266.99
Gray matter-2	3166.70	494.57	2036.28-3882.42
White matter-1	2187.09	611.89	1049.95-3026.52
White matter-2	2346.27	775.45	1022.22-3902.55
Lateral pterygoid muscle-1	1951.68	544.57	1008.77-2960.80
Lateral pterygoid muscle-2	2706.81	460.45	2000.73-3927.34
Parotid gland-1	3489.25	620.44	2123.73-4820.10
Parotid gland-2	3516.13	320.38	3000.07-3999.99

in images where the entire area between the mandibular condyle and the lower border of the mandible could be imaged. The location and size of ROI were consistent on all images from different joints to guarantee higher reliability.¹⁸ Selection of images suitable for ROI placement was decided by consensus of two oral and maxillofacial radiologists, where such images were judged to be *excellent*. In order to be judged *excellent*, each image had to clearly show the gray matter, the white matter, the lateral pterygoid muscle, the parotid gland, and the condyle. It was also necessary for all ROI to be located as closely as possible to the condyle. We placed the ROI over the bone marrow of the condyle, which was located as close as possible to the top. The ROI were also placed over four other structures: the gray matter, the white matter, the parotid gland, and the lateral pterygoid muscle. Two different ROI were placed over the four structures to cover a large area. The average area for each structure was calculated from a total of 20 images in order to determine the size of ROI. This resulted in a 4.5 mm² area for bone marrow of the condyle (**Figure 1, A**) and in a 5.9 mm² area for the gray matter, a 1.8 mm² area for the white matter, a 1.0 mm² area for the lateral pterygoid muscle and a 21.9 mm² area for the parotid gland (**Figure 1**). It was hypothesized that obtaining a correlation between signal intensity of ROI over bone marrow and that of other structures would provide a potential reference point for measurement of signal intensity of bone marrow. All procedures were carried out on PDW.

Statistical Analysis

Statistical analysis was carried out using the Pearson product-moment correlation coefficient. Level of statistical significance was set at $p < 0.05$. When the Pearson product-moment correlation coefficient indicated statisti-

cal significance, this was judged to be “presence of association” between the two groups selected.

Results

Mean value, range, and standard deviation of signal intensity from the gray matter, white matter, parotid gland, lateral pterygoid muscle, and bone marrow of the condyle are shown in **Table 3**. Of eight groups, a significant positive linear correlation ($p < 0.05$) was found in the group for gray matter-1 and bone marrow of the condyle on the PDW (**Figure 2**). The correlation coefficient was 0.3 (**Figure 2**).

Discussion

It was assumed that the acquisition of a correlation between signal intensity of ROI over bone marrow and that of other structures would give a potential reference point for bone marrow.

At first, an appropriate location of ROI for bone marrow of the mandibular condyle was considered. Osteoarthritis was described as the presence of cortical changes, such as erosion or osteophyte, quite frequently located at the top of the condyle.^{19,20} The ROI of the bone marrow was placed over as close as possible to the top of the mandibular condyle.

Some studies²¹⁻²⁸ on MR signal intensity of the TMJ have qualitatively evaluated sites. A few others have quantitatively evaluated sites^{29,30} using ROI. Quantitative evaluation of MR signal intensity, however, is still debated because of the difficulties of signal measurement. Otonari, et al.³¹ positioned a polyethylene tube containing distilled water at the external auditory foramen to determine the optimal sequence for diffusion-

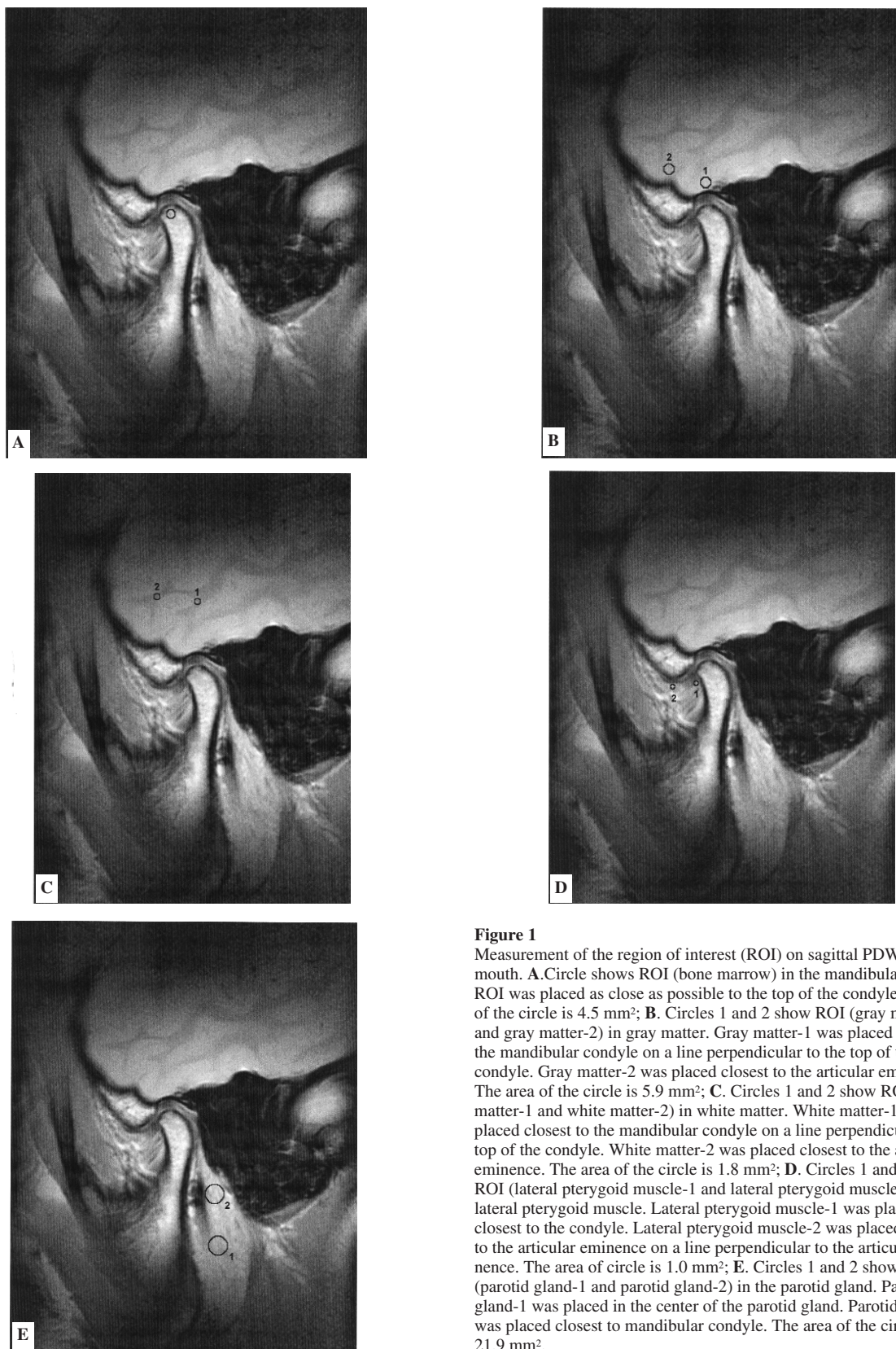


Figure 1

Measurement of the region of interest (ROI) on sagittal PDW in closed mouth. **A.** Circle shows ROI (bone marrow) in the mandibular condyle. ROI was placed as close as possible to the top of the condyle. The area of the circle is 4.5 mm²; **B.** Circles 1 and 2 show ROI (gray matter-1 and gray matter-2) in gray matter. Gray matter-1 was placed closest to the mandibular condyle on a line perpendicular to the top of the condyle. Gray matter-2 was placed closest to the articular eminence. The area of the circle is 5.9 mm²; **C.** Circles 1 and 2 show ROI (white matter-1 and white matter-2) in white matter. White matter-1 was placed closest to the mandibular condyle on a line perpendicular to the top of the condyle. White matter-2 was placed closest to the articular eminence. The area of the circle is 1.8 mm²; **D.** Circles 1 and 2 show ROI (lateral pterygoid muscle-1 and lateral pterygoid muscle-2) in the lateral pterygoid muscle. Lateral pterygoid muscle-1 was placed closest to the condyle. Lateral pterygoid muscle-2 was placed closest to the articular eminence on a line perpendicular to the articular eminence. The area of circle is 1.0 mm²; **E.** Circles 1 and 2 show ROI (parotid gland-1 and parotid gland-2) in the parotid gland. Parotid gland-1 was placed in the center of the parotid gland. Parotid gland-2 was placed closest to mandibular condyle. The area of the circle is 21.9 mm².

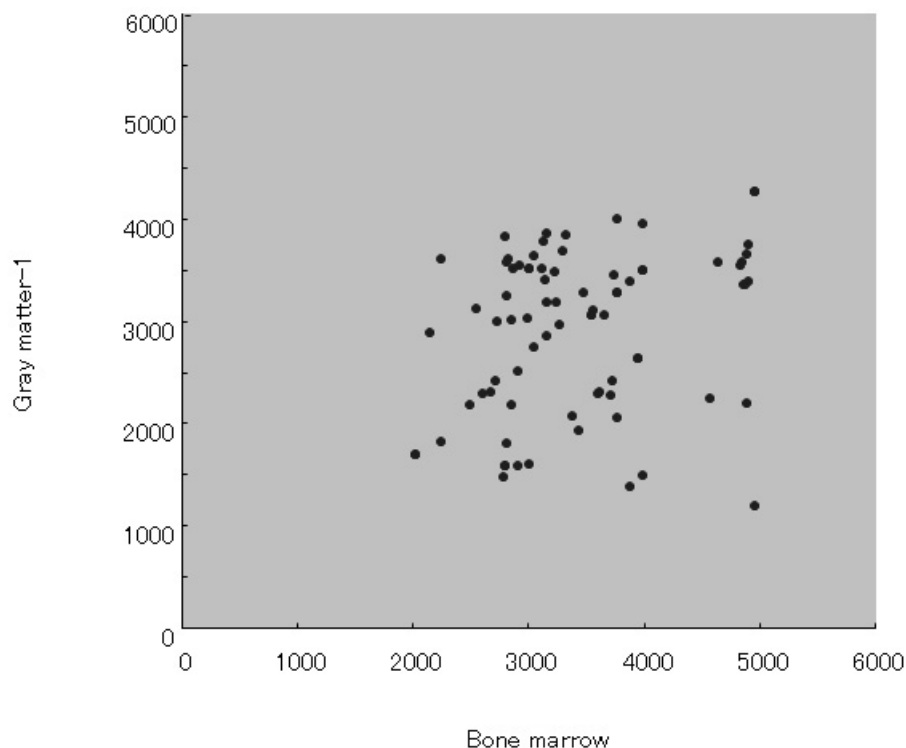


Figure 2
Plotting of gray matter-1 and bone marrow signal intensity on PDW. The correlation coefficient is 0.3.

weighted images adapted to the TMJ. However, patients with TMJ disorders often complain of vertigo, tinnitus, earache, and hearing loss,^{32,33} all of which are suspected disorders of the auditory canal, central nervous system, and brain, etc. Therefore, it is dangerous for dentists to undertake such a procedure. Crucially, signal intensity measurements are subject to variation depending on the position of the coil and the amplifier gain of the image reconstruction circuitry.

Kitagaki, et al.³⁴ reported the signal intensity of white matter in cases of dementia demonstrating that the correlation coefficient in the signal intensity ratio of the white matter-cerebrospinal fluid between the frontal and temporal lobes of normal healthy subjects was positive. Corrected sagittal MR images can clearly depict the external auditory foramen, disk, retrodiscal tissue, mandibular condyle, temporal lobe, parotid gland, and lateral pterygoid muscle. As the external auditory foramen is filled with air, it has no signal intensity. In an earlier study on the disk, Helms, et al.²¹ demonstrated that the disk yielded a high or intermediate signal intensity in normal joints, and a diminished intensity in osteoarthritic joints. Furthermore, Sener, et al.²² demonstrated that the

signal intensity in displaced disks can depend on reduction. A study on the retrodiscal tissue^{23,29} suggested a correlation between increased MR signals and increased vascularity as a cause of TMJ pain. Therefore, the disk and retrodiscal tissues should be excluded, as the signal intensity is likely to change depending on TMJ status in such cases. For these reasons, in this study, ROIs were defined and placed over the remaining structures: white and gray matter, lateral pterygoid muscle, and parotid gland.

Signal-to-noise ratio is highest at the center of the surface coil, so the ROI were placed as close as possible to the mandibular condyle in the center of the image. Iwasaki, et al.³⁵ reported that, as the gluteal muscle comes into contact with the iliac bone, it is barely influenced by artifacts resulting from lack of uniformity of the RF field in FOV. This finding supports the decision in this study to place a ROI over the lateral pterygoid muscle.

TMJ pain and swelling and/or tenderness of the muscle is also often seen in myositis. In cases of myofascial pain with a palpable trigger point in the muscle or fibromyalgia with body pain, muscle organs such as the lateral pterygoid muscle may be excluded from the list of refer-

ence points. The parotid gland consists of various tissues that show varied signal patterns on T1- or T2-weighted images. Signal intensities of adipose tissue also increase with age. Therefore, we can assume that the parotid gland is unstable as a reference point for signal intensity.

In the current study, only one group, for gray matter-1 and bone marrow of the condyle showed a significant correlation coefficient on PDW. The correlation coefficient was 0.3. Sano, et al.¹⁷ described no association between TMJ diagnosis or degree of TMJ pain and signal intensity of the temporal lobe. This is one reason gray matter and bone marrow offer a significant positive linear correlation.

The current study was focused on the analysis of bone marrow abnormalities that were most likely associated with osteoarthritis and indicated that gray matter is the most appropriate site. Gray matter may be another candidate as a reference point to analyze variations of signal intensities of the disk which depends on pathologic conditions^{36,37} because the disk is also located in the center on corrected sagittal images as is the top of the condyle. Further study is needed to clarify this hypothesis.

In conclusion, gray matter was identified as a potential reference point in evaluating the correlation between osteoarthritis and MR signal intensity of bone marrow in the mandibular condyle.

References

- Westesson P-L, Rohlin M: Internal derangement related to osteoarthritis in temporomandibular joint autopsy specimens. *Oral Surg Oral Med Oral Pathol* 1984; 57:17-22.
- Emshoff R, Brandlmaier I, Bertram S, Rudisch A: Risk factors for temporomandibular joint pain in patients with disk displacement without reduction. A magnetic resonance imaging study. *J Oral Rehab* 2003; 30:537-543.
- Sano T: Recent developments in understanding temporomandibular joint disorders. Part 1: bone marrow abnormalities of the mandibular condyle. *Dentomaxillofac Radiol* 2000; 29:7-10.
- Emshoff R, Innerhofer K, Rudisch A, Bertram S: The biological concept of "internal derangement and osteoarthritis": a diagnostic approach in patients with temporomandibular joint pain? *Oral Surg Oral Med Oral Pathol Oral Radiol Endod* 2002; 93:39-44.
- Wiberg B, Wanman A: Signs of osteoarthritis of the temporomandibular joints in young patients: a clinical and radiographic study. *Oral Surg Oral Med Oral Pathol Oral Radiol Endod* 1998; 86:158-164.
- Isberg A, Isacson G, Johansson A-S, Larson O: Hyperplastic soft tissue formation in the temporomandibular joint associated with internal derangement. *Oral Surg Oral Med Oral Pathol* 1986; 61:32-38.
- Isberg A, Isacson G: Tissue reactions associated with internal derangement of the temporomandibular joint. *Acta Odontol Scand* 1986; 44:159-164.
- Sano T, Westesson P-L: Magnetic resonance imaging of the temporomandibular joint: increased T2 signal in the retrodiskal tissue of painful joints. *Oral Surg Oral Med Oral Pathol Oral Radiol Endod* 1995; 79:511-516.
- Suenaga S, Sonoda S, Oku T, Abeyama K, Noikura T: MRI of the temporomandibular joint disk and posterior disk attachment before and after non-surgical treatment. *J Comput Assist Tomogr* 1997; 21:892-896.
- Westesson P-L, Brooks SL: Temporomandibular joint: relationship between MR evidence of effusion in the presence of pain and disc displacement. *Am J Roentgenol* 1992; 59:559-563.
- Farrar WB, McCarthy Jr WL: Inferior joint space arthrography and characteristics of condylar path in internal derangements of the TMJ. *J Prost Dent* 1979; 41:548-555.
- Farrar WB, McCarthy WL: The TMJ dilemma. *J Ala Dent Assoc* 1979; 63:19-24.
- Harms SE, Wilk RM, Wolford LM, Chiles DG, Milam SB: The temporomandibular joint: magnetic resonance imaging using surface coils. *Radiol* 1985; 157:133-136.
- Zanetti M, Bruder E, Romero J, Hodler J: Bone marrow edema pattern in osteoarthritic knees: correlation between MR imaging and histologic findings. *Radiol* 2000; 215:835-840.
- Felson DT, McLaughlin S, Goggins J, LaValley MP, Gale ME, Totterman S, Li W, Hill C, Gale D: Bone marrow edema and its relation to progression of knee osteoarthritis. *Ann Intern Med* 2003; 139:330-336.
- Larheim TA, Westesson P-L, Hicks DG, Eriksson L, Brown DA: Osteonecrosis of the temporomandibular joint: correlation of magnetic resonance imaging and histology. *J Oral Maxillofac Surg* 1999; 57:888-898.
- Sano T, Westesson P-L: Magnetic resonance imaging of the temporomandibular joint Increased T2 signal in the retrodiskal tissue of painful joints. *Oral Surg Oral Med Oral Pathol Oral Radiol Endod* 1995; 79:511-516.
- Ogura A, Maeda F, Miyai A, Hongoh T: Accuracy of contrast-to-noise ratio measurement for magnetic resonance clinical images. *Nippon Hoshasen Gijyutsu Gakkai Zasshi* 2004; 60:1543-1549.
- de Leeuw R, Boering G, Stegenga B, de Bont LG: Radiographic signs of temporomandibular joint osteoarthritis and internal derangement 30 years after nonsurgical treatment. *Oral Surg Oral Med Oral Pathol Radiol Endod* 1995; 79:382-392.
- Tasaki MM, Westesson P-L: Temporomandibular joint: diagnostic accuracy with sagittal and coronal MR imaging. *Radiol* 1993; 186:723-729.
- Helms CA, Kaban LB, McNeill C, Dodson T: Temporomandibular joint: morphology and signal intensity characteristics of the disk at MR imaging. *Radiol* 1989; 172:817-820.
- Sener S, Akgunlu F: Correlation of different MRI characteristics of anterior disk displacement with reduction and without reduction. *J Contemp Dent Pract* 2005; 6:1-10.
- Sano T: Recent developments in understanding temporomandibular joints disorders. Part 2: changes in the retrodiskal tissue. *Dentomaxillofac Radiol* 2000; 29:260-263.
- Katzberg RW: Temporomandibular joint imaging. *Radiol* 1989; 170:297-307.
- Okano T, Kawada MA, Seki K, Sano T, Kino K: MR imaging of the normal temporomandibular joint and the related structures. *Showa Shigakkai Zasshi* 1989; 9:6-12.
- Sakuma K, Sano T, Yamamoto M, Tachikawa T, Okano T: Dose decreased T1 signal intensity in the retrodiskal tissue of the temporomandibular joint reflect increased density of collagen fibers? *Dentomaxillofac Radiol* 2003; 32:222-228.
- Harms SE, Wilk RM, Wolford LM, Chiles DG, Milam SB: The temporomandibular joint: magnetic resonance imaging using surface coils. *Radiol* 1985; 157:133-136.
- Westesson P-L, Paesani D: MR imaging of the TMJ: decreased signal from the retrodiskal tissue. *Oral Surg Oral Med Oral Pathol* 1993; 76:631-635.
- Sano T, Westesson P-L: Magnetic resonance imaging of the temporomandibular joint, Increased T2 signal in the retrodiskal tissue of painful joints. *Oral Surg Oral Med Oral Pathol Oral Radiol Endod* 1995; 79:511-516.
- Suenaga S, Hamamoto S, Kawano K, Higashida Y, Noikura T: Dynamic MR imaging of the temporomandibular joint in patients with arthrosis: relationship between contrast enhancement of the posterior disk attachment and joint pain. *Am J Roentgenol* 1996; 166:1475-1481.
- Otonari T, Wakoh M, Sano T, Yamamoto M, Ohkubo M, Harada T: Parameters for diffusion weighted magnetic resonance imaging for temporomandibular joint. *Bull Tokyo Dent Coll* 2006; 47:5-12.
- Chole RA, Parker WS: Tinnitus and vertigo in patients with temporomandibular disorder. *Arch Otolaryngol Head Neck Surg* 1992; 118:817-821.
- Edward F: Referred craniofacial pain patterns in patients with temporomandibular disorder. *J Am Dent Assoc* 2000; 131:1307-1315.
- Kitagaki H, Mori E, Hirono N, Ikejiri Y, Ishii K, Imamura T, et al.: Alteration of white matter MR signal intensity in frontotemporal dementia. *Am J Neuroradiol* 1997; 18:367-378.
- Iwasaki T, Kawamura Y, Kimura H, Maeda M, Itou S, Matsuda T, et al.: Quantitative analysis of bone marrow MRI using STIR technique. *Nippon Jiki Igakkai Zasshi* 1991; 11:421-425.
- Helms CA, Kaban LB, McNeil C, Dodson T: Temporomandibular joint: morphology and signal intensity characteristics of the disk at MR imaging. *Radiol* 1989; 172:817-820.
- Sener S, Akgunlu F: Correlation of different MRI characteristics of anterior disk displacement with reduction and without reduction. *J Contemp Dent Pract* 2005; 15:26-36.

Dr. Tsukasa Sano received his D.D.S. degree from Showa University, Tokyo, Japan, in 1987 and his Ph.D. degree from the same university in 1991. He was a visiting assistant professor in the Department of Radiology, University of Rochester Medical Center, Rochester, New York, and currently is a professor and the chairman of Oral and Maxillofacial Radiology, Tokyo Dental College, Chiba, Japan.

Dr. Mika Otonari-Yamamoto received her D.D.S. degree from Nagasaki University, Nagasaki, Japan, in 1995 and her Ph.D. degree from Showa University, Tokyo, Japan, in 2003. She was a research fellow in the Department of Radiology, Massachusetts Eye and Ear Infirmary, Harvard Medical School, Boston, and is an assistant professor of Oral and Maxillofacial Radiology, Tokyo Dental College, Chiba, Japan.

Dr. Keiichi Nishikawa received his B.S. degree from Tokyo University of Science, Tokyo, in 1983 and his Ph.D. degree from Tokyo Dental College, Chiba, Japan, in 1997. He works as an assistant professor and a medical physicist at the Department of Oral and Maxillofacial Radiology of Tokyo Dental College, Chiba, Japan.

Dr. Edmund Kwok received his Ph.D. degree in Physics from Rensselaer Polytechnic Institute, Troy, NY, in 1990. He is an associate professor of Imaging Sciences at the University of Rochester.
