



Title	Cortical representation area of human dental pulp
Author(s) Alternative	Kubo, K; Shibukawa, Y; Shintani, M; Suzuki, T; Ichinohe, T; Kaneko, Y
Journal	Journal of dental research, 87(4): 358-362
URL	http://hdl.handle.net/10130/854
Right	

Journal of Dental Research

<http://jdr.sagepub.com>

Cortical Representation Area of Human Dental Pulp

K. Kubo, Y. Shibukawa, M. Shintani, T. Suzuki, T. Ichinohe and Y. Kaneko

J DENT RES 2008; 87; 358

DOI: 10.1177/154405910808700409

The online version of this article can be found at:
<http://jdr.sagepub.com/cgi/content/abstract/87/4/358>

Published by:



<http://www.sagepublications.com>

On behalf of:

International and American Associations for Dental Research

Additional services and information for *Journal of Dental Research* can be found at:

Email Alerts: <http://jdr.sagepub.com/cgi/alerts>

Subscriptions: <http://jdr.sagepub.com/subscriptions>

Reprints: <http://www.sagepub.com/journalsReprints.nav>

Permissions: <http://www.sagepub.com/journalsPermissions.nav>

K. Kubo^{1*}, Y. Shibukawa², M. Shintani,
T. Suzuki², T. Ichinohe¹, and Y. Kaneko¹

¹Department of Dental Anesthesiology and ²Department of Physiology, Oral Health Science Center, Laboratory of Brain Research, Tokyo Dental College, Chiba 261-8502, Japan; *corresponding author, kubo_sic@wm.pdx.ne.jp

J Dent Res 87(4):358-362, 2008

ABSTRACT

To elucidate the dental pulp-representing area in the human primary somatosensory cortex and the presence of A-beta fibers in dental pulp, we recorded somatosensory-evoked magnetic fields from the cortex in seven healthy persons using magnetoencephalography. Following non-painful electrical stimulation of the right maxillary first premolar dental pulp, short latency (27 ms) cortical responses on the magnetic waveforms were observed. However, no response was seen when stimulation was applied to pulpless teeth, such as devitalized teeth. The current source generating the early component of the magnetic fields was located anterior-inferiorly compared with the locations for the hand area in the primary somatosensory cortex. These results demonstrate the dental pulp representation area in the primary somatosensory cortex, and that it receives input from intradental A-beta neurons, providing a detailed organizational map of the orofacial area, by adding dental pulp to the classic "sensory homunculus".

KEY WORDS: magnetoencephalography, A-beta afferent, dental pulp, somatosensory-evoked field, primary somatosensory cortex.

Cortical Representation Area of Human Dental Pulp

INTRODUCTION

Somatosensory information is somatotopically represented in the primary somatosensory cortex. Neurons in the primary somatosensory cortex receive not only non-noxious cutaneous input, but also nociceptive input (Kanda *et al.*, 2000). Orofacial sensory inputs project to the lateral area of the primary somatosensory cortex (Penfield and Boldrey, 1937; Nakahara *et al.*, 2004; Suzuki *et al.*, 2004; Bessho *et al.*, 2007).

One human electroencephalographic study demonstrated cortical potentials in response to painful electrical stimulation of dental pulp with a first-peak latency of 84 ms, suggesting activation of the secondary somatosensory cortex by intradental A-delta neurons (Chatrian *et al.*, 1975). In a magnetoencephalographic study (Hari *et al.* 1983), the current source at a peak latency of 100 ms in somatosensory-evoked magnetic fields following noxious electrical dental pulp stimulation was also located at the secondary somatosensory cortex. In cat and monkey studies, the dental pulp representation area in the primary somatosensory cortex played an important role in sensory discrimination and recognition of localization and intensity of stimuli applied to dental pulp (Chudler *et al.*, 1985; Matsumoto *et al.*, 1987, 1989; Iwata *et al.*, 1990). However, no electroencephalographic or magnetoencephalographic human studies have investigated early neuronal cortical responses to dental pulp stimulation resulting in activation of the primary somatosensory cortex. Therefore, the precise location of the cortical representation area of dental pulp in the primary somatosensory cortex in humans remains unclear.

To elucidate the feasibility of precisely mapping the dental pulp-representing area in the human primary somatosensory cortex, we examined spatial and temporal cerebral activation patterns of short-latency responses reflecting fast-conducting sensory afferents following electrical stimulation of dental pulp. We recorded somatosensory-evoked magnetic fields using magnetoencephalography, a proven technique in identifying neuronal current sources in the primary somatosensory cortex, with excellent spatial and temporal resolution (Rossini and Traversa, 1990; Baumgartner *et al.*, 1991; Hämäläinen, 1992; Kawamura *et al.*, 1996; Tesche and Karhu, 1997).

MATERIALS & METHODS

Seven right-handed, healthy men (mean age, 28 yrs; range, 25-35 yrs) were studied, with prior written informed consent. The study was approved by the Ethics Committee of our institute and was in accordance with the Declaration of Helsinki.

To record cortical somatosensory-evoked magnetic fields, we electrically stimulated dental pulp through intact enamel by a pair of specialized silver electrodes on the occlusal surface of the right intact maxillary first premolar under rubber dam isolation (Fig. 1). The median nerve at the right wrist was also stimulated to obtain control responses. Electrical stimulation consisted of a constant current square pulse delivered at 1 Hz, lasting 0.5 ms for dental pulp and 0.2 ms for the median nerve, and approximately two times the sensory threshold strength. This intensity was confirmed to produce non-painful sensations in both the tooth (0.8-2.0 mA; Chatrian *et al.*, 1975; Condes-Lara *et al.*, 1981; Lekić and Cenić, 1992) and the wrist. Furthermore, we recorded somatosensory-evoked magnetic responses following electrical stimulation of a devitalized tooth (n = 2),

Received April 30, 2006; Last revision November 22, 2007;
Accepted December 17, 2007

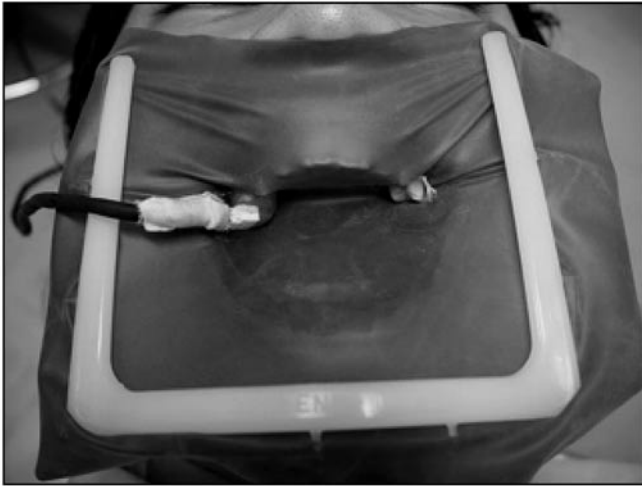


Figure 1. Photograph showing dental pulp electrical stimulation of intact maxillary first premolar on the right side with a pair of silver electrodes and a rubber dam. The rubber dam was fixed with a non-metal frame and dental floss instead of a clamp, since metal is unsuitable for magnetoencephalographic studies, because it creates huge magnetic artifacts that contaminate the neuromagnetic sensors. The right first premolar was stimulated, since it is located well away from the midline.

a tooth after root canal obturation following pulpectomy ($n = 2$), and a tooth during root canal treatment ($n = 1$). Stimulation intensity for the pulpless tooth was the same as that for magnetic recording from the intact tooth in each person.

We used a 306-channel neuromagnetometer (Vectorview, Elekta-Neuromag, Helsinki, Finland) to record magnetic fields from 102 points with a pair of gradiometers. One hundred trials were averaged according to the magnetic signals induced. To allow for alignment of magnetoencephalography and magnetic resonance imaging coordinate systems, we measured the positions of 4 head position indicator coils and 3 anatomical landmarks (the bilateral pre-auricular points and the nasion) with a three-dimensional digitizer (Isotrak, Polhemus, Colchester, VT, USA). At the beginning of each recording session, head position was redefined. All signals were digitized at 1 kHz and bandpass-filtered (0.1-100 Hz). We constructed isocontour maps from measured data at time-points showing peak amplitudes (*i.e.*, time-points with peak latencies of magnetic components), using minimum-norm estimates. Sources of magnetic fields were modeled as single equivalent current dipoles whose three-dimensional location, orientation, and strength were estimated in a spherical conductor model (Source Modeling; Elekta-Neuromag). Equivalent current dipoles were determined by least-squares search, based on signals from 20-30 channels over the response area. Only dipoles attaining a more than 90% goodness-of-fit were accepted for further analysis, where the entire time period and all channels were taken into account in computations of the parameters of a time-varying dipole model (Shibukawa *et al.*, 2004, 2006). In this model, the strength of the dipoles was allowed to change as a function of time. They were then superimposed on the brain magnetic resonance images (1.5-T Siemens Symphony system, Erlangen, Germany) to reveal source locations with respect to anatomical structure.

Results are expressed as mean \pm the standard error of the mean. We used the Student's *t* test to determine statistical significance. Values of $P < 0.05$ were considered significant.

Table. Peak Latencies

	Contralateral Hemisphere	Ipsilateral Hemisphere
Dental pulp stimulation		
Early component	27 \pm 1*	ND
Late component	71 \pm 5**	73 \pm 4***
Median nerve stimulation		
Early component	21 \pm 1*	ND
Late component	48 \pm 4**	88 \pm 4***

ND: not detected (ms, mean \pm SE; $n = 7$).

Each pair of asterisks (*, **, ***) indicates statistical value of $P < 0.05$.

RESULTS

Following non-painful dental pulp stimulation, prominent magnetic fields were observed bilaterally in the parietotemporal region in all participants (Fig. 2A). Early and late components were consistently identified within a 300-ms analysis period in the enlarged somatosensory-evoked magnetic waveforms (Fig. 2B), selected from both hemispheres (Fig. 2B), following stimulation of the right maxillary first premolar in all participants. Peak latencies were about 27 ms for the early component and about 71 ms for the late component in the contralateral hemisphere (Table). Magnetic amplitude in the contralateral hemisphere was about 4.4 fT/cm for the early component, and about 17.6 fT/cm for the late component. However, no other later components were observed following dental pulp stimulation. During electrical stimulation of the median nerve at the wrist, somatosensory-evoked magnetic fields with early and late components in the contralateral hemisphere were also observed (Table). Electrical stimulation of teeth with no vital dental pulp elicited no responses (Fig. 2B).

To estimate the location of cortical current source generating somatosensory-evoked magnetic responses, we constructed, from magnetic fields, isocontour maps at peak magnetic components. Estimated dipoles were superimposed on each individual magnetic resonance image to determine source location (Fig. 2C). Equivalent current dipoles of the early component following dental pulp stimulation were identified along the most inferior part of the posterior wall of the central sulcus, corresponding to the primary somatosensory cortex in the hemisphere contralateral to the stimulated site in all participants (Fig. 2C). Dipoles of early components with peak latencies of 21 ms following wrist stimulation were also located in the posterior wall of the central sulcus, in the hemisphere contralateral to the stimulated site. However, dipoles corresponding to the wrist site were located superior to dipoles corresponding to sites for dental pulp in all participants. The mean dipole moment (source strength) by dental pulp stimulation was significantly smaller (4.4 ± 2.5 nAm) than that by median nerve stimulation (22.3 ± 4.3 nAm). We compared the mean three-dimensional dipole locations of the early components of evoked magnetic fields between median nerve (open circles) and dental pulp (filled circles) stimulation (Fig. 3). Significant differences were observed between locations of dental pulp and median nerve equivalent current dipoles (Fig. 3A). Distances of dipole locations from dental pulp to median nerve (Fig. 3B) clearly indicated that the location of somatosensory representation of dental pulp in the primary somatosensory cortex was more anterior and inferior to that of the median nerve.

DISCUSSION

Stimulus intensity for dental pulp was set to 0.8-2.0 mA. This was high compared with that used in earlier studies (around 10 to 100 μ A; *e.g.*, Mumford and Stanley, 1981), where pain was

actually induced, even at considerably lower intensities. In the present study, however, only non-painful sensations were evoked, since the electrodes were placed on intact dried enamel without conductive paste, to avoid current leakage to other tissues (such as the periodontal membrane) and to obtain pure dental pulp stimulation. However, examples can be found of high-stimulus intensities with a sensory threshold level of 1 mA in recordings of somatosensory-evoked potentials reflecting cortical neuronal activities in humans (Chatrian *et al.*, 1975; Condes-Lara *et al.*, 1981; Lekić and Cenić, 1992). We did not examine cortical responses using painful stimulation, since this resulted not only in a large magnetic artifact, but also in head movement during neuromagnetic recordings. Magnetoencephalographic signals are susceptible to noise contamination by muscle activity, especially by head movement. In our preliminary study, painful dental pulp stimulation induced these "movement artifacts" during recordings, which prevented us from determining the precise location of equivalent current dipoles. When pulpless teeth were stimulated, the person felt no sensation, and we observed no cortical responses, demonstrating that the equipment used allowed for exclusive stimulation of dental pulp.

In the magnetic waveform analysis, early components showed peak latencies of 27 ms, and dipoles producing this were located on the primary somatosensory cortex. These results are in accord with those of monkey studies showing that dental pulp afferents projected to the primary somatosensory cortex with short latencies (24 ms with A-beta conduction velocity) following low-intensity dental pulp electrical stimulation inducing non-painful (indicated by its behavioral response) sensations (Chudler *et al.*, 1985). Although intradental A-beta nerve fibers were also identified in experimental animals (Cadden *et al.*, 1983; Byers, 1984; Chudler *et al.*, 1985; Närhi *et al.*, 1992; Dong *et al.*, 1993), no conclusive evidence has been obtained in human dental pulp (Condes-Lara *et al.*, 1981).

Early components of somatosensory-evoked magnetic fields following electrical stimulation of human orofacial skin have latencies of about 20-30 ms (Suzuki *et al.*, 2004; Murayama *et al.*, 2005), and those following painful orofacial

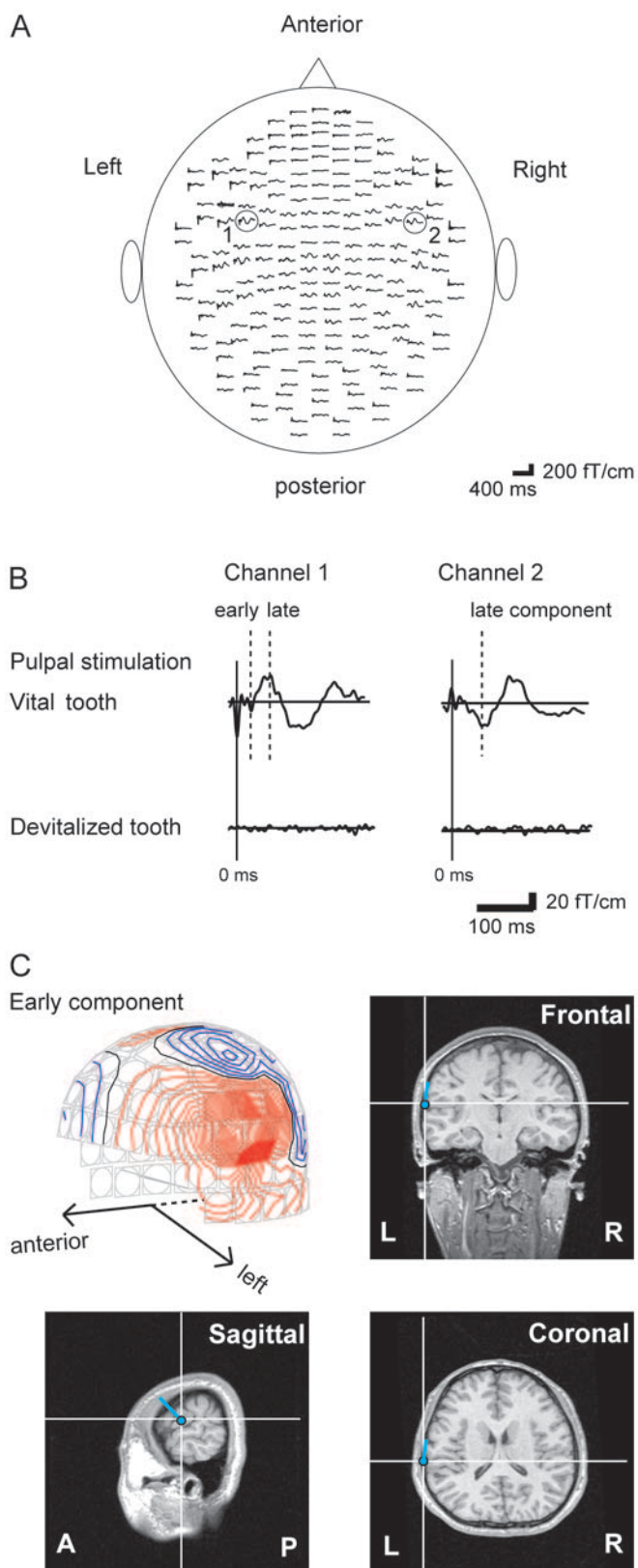


Figure 2. Magnetic waveforms during dental pulp stimulation. (A) Whole-scalp magnetic responses. Traces were plotted on the "flattened" head as viewed from above, with the nose pointed upward. Upper and lower traces of each pair represent latitudinal and longitudinal derivatives of radial magnetic fields. Each trace starts 15 ms preceding stimulation of tooth pulp and terminates 300 ms after. (B) Enlarged traces of magnetic signals from parietotemporal region in left (channel 1; contralateral) and right (channel 2; ipsilateral) hemispheres during electrical stimulation of dental pulp in vital (upper traces) and devitalized (lower traces) teeth. These traces in channels 1 and 2 were obtained from two selected channels in A (circles in A). Nomenclature is provided for 2 successive peak signal components: "early" and "late" (dashed lines). In enlarged traces, the analysis period was set to 315 ms, from 15 ms preceding to 300 ms following the onset of stimulation of tooth pulp. Vertical lines show the onset of stimulation, while horizontal lines show baseline. (C) Typical example of isocontour map (upper left) of dental-pulp-evoked magnetic responses was obtained from the same person as in A, showing a contralateral early response with a dipolar magnetic field pattern in the left hemisphere. In this Fig., isocontour maps are drawn at 10 fT steps; red and blue lines indicate outgoing and ingoing fluxes, respectively. Magnetic resonance images show locations of equivalent current dipoles producing contralateral cortical distribution at 1 M after stimulation of tooth pulp. Blue circle shows equivalent current dipole on magnetic resonance images; blue bar attached to circle indicates size and direction of equivalent current dipole (end of bar attached to circle represents positive pole).

stimulation have latencies of about 100 ms (Hari *et al.*, 1983; Matsuura *et al.*, 2004). In a study with microneurography in humans, the conduction velocity of A-delta fibers was 20 m/s (Adriaensen *et al.*, 1983). The conduction velocity of the spinothalamic tract was 8.0 m/s, determined by spinothalamic tract neurons with antidromic activation in the monkey thalamus (Dostrovsky and Craig, 1996). Conduction velocity of thalamocortical fibers was estimated to be 33 m/s, based on somatosensory-evoked potentials (Desmedt and Cheron, 1980). Therefore, the latency of cortical neuronal activities carried by A-delta neurons for the hand, as well as for the orofacial area, is estimated at around 100 ms. In contrast, the velocity of A-beta fibers is 2 to 5 times as fast as that of A-delta fibers. Human trigeminal A-beta fibers (inferior alveolar nerves) yielded conduction velocities of 65 m/s (Jääskeläinen *et al.*, 1995), while the velocity of the trigeminothalamic tract for A-beta neurons was found to be 14.0 m/s in monkeys (Price *et al.*, 1976). This suggests that, in this study, the cortical responses with a latency of around 20-30 ms reflect the conduction velocity of peripheral A-beta neuron activity.

However, it has been reported that the thresholds and conduction velocities of intradental A-beta and A-delta afferents overlap (Närhi *et al.*, 1992). In this study, no one felt pain on stimulation. Although non-painful sensations in dental pulp (pre-pain) can be evoked by low electrical stimulation (Mumford and Stanley, 1981), pain is the only conscious sensation elicited by physiological (such as thermal, chemical, or mechanical) stimulation in human dental pulp, with first (fast) and second (slow) pain (Edwall and Olgart, 1977; Ahlquist *et al.*, 1984; Cook *et al.*, 1997). The presence of non-nociceptive afferents in dental pulp is controversial. A-beta fibers did not respond to mechanical stimulation of the intact tooth crown, and both A-beta and A-delta fibers were similarly activated by different stimuli (Byers and Närhi, 1999). Accordingly, A-beta fibers in dental pulp have been proposed to serve a nociceptive function. However, from the results of this study, it is impossible to determine whether A-beta afferents in human dental pulp are nociceptive. In the present study, the early component of the magnetic signal reflected cortical activation by the intradental afferents with the fastest conduction velocity (also see above). Therefore, although our high temporal analysis showed that the early component of the magnetic signal following dental pulp stimulation provided evidence of intradental A-beta neurons in humans, further study is needed to clarify the functional characteristics of those neurons.

Peak latency for the early component following dental pulp stimulation was slower (27 ms) than that following median nerve stimulation (21 ms) (Table), although the distance from the wrist to the cortex is considerably longer than that from the tooth. Time of peak latency in the somatosensory-evoked magnetic field is explained by peripheral conduction time in first-order sensory neurons, central conduction time from the brainstem to the primary somatosensory cortex, and the central processing time within the cortical neurons. In this study, values for magnetic amplitude and dipole moment by dental pulp stimulation were significantly smaller than those by median nerve stimulation, suggesting that cortical neurons in the dental pulp-representing area produce only a small-amplitude excitatory post-synaptic potential after stimulation, which elicits delayed onset of spike discharge, due to the slow activation time-course of the potential. Thus, delayed central

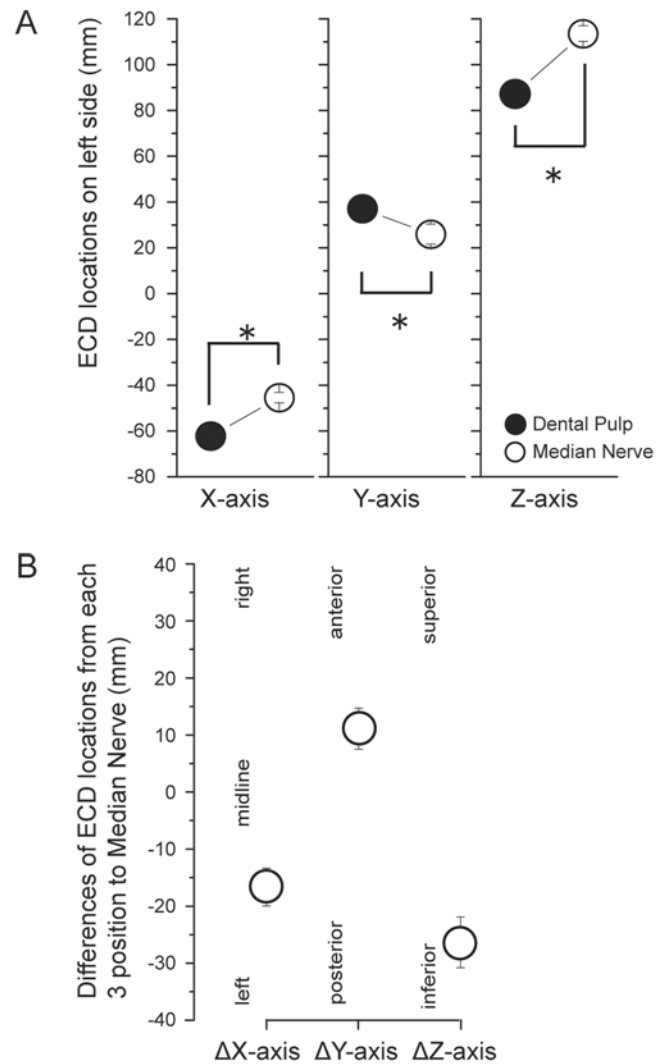


Figure 3. Averaged equivalent current dipole positions following dental pulp electrical stimulation and their differences between dental pulp and median nerve stimulation. **(A)** Comparison of three-dimensional equivalent current dipole locations for each X-, Y-, and Z-axis between dental pulp (filled circles) and median nerve stimulation (open circles). **(B)** Relative distances on X-, Y-, and Z-axes to equivalent current dipoles of early components for median nerve from those for dental pulp stimulation. Statistically significant differences are labeled with asterisks ($P < 0.05$). ECD: equivalent current dipole.

processing time may be responsible for slower peak latency of early components following dental pulp stimulation, compared with the 20-ms magnetic component following median nerve stimulation at the wrist.

The current sources evoked by dental pulp stimulation were located anterior and inferior to the sources evoked by median nerve stimulation. These results are in line with the somatotopy of the primary somatosensory cortex, showing that the area for the hand is superior to that for the orofacial area (Penfield and Boldrey, 1937; Nakahara *et al.*, 2004; Suzuki *et al.*, 2004; Murayama *et al.*, 2005; Bessho *et al.*, 2007). The first somatosensory-evoked magnetic response in the primary somatosensory cortex following trigeminal nerve stimulation had

anteriorly oriented currents with a peak latency of around 15 ms (Nagamatsu *et al.*, 2000). In the present study, we observed no magnetic component with a peak latency of around 15 ms, which requires higher stimulus intensity of 7 to 9 times the sensory threshold to be activated. However, we showed that dipoles producing the magnetic field following dental pulp stimulation were directed anteriorly (anterior-oriented current). This indicates that the tooth pulp A-beta afferents project to Brodmann area 3b in the primary somatosensory cortex, since the cortical neuron in 3b lies in an anatomically anterior-posterior orientation. Note that the equivalent current dipole of the "initial" cortical response generated by neurons in area 3b has anteriorly oriented currents (Nagamatsu *et al.*, 2000). Therefore, these observations, together with our results, clearly indicate that the early components of the magnetic signals reflect initial cortical response.

In conclusion, we demonstrated the precise location of the dental pulp-representation area in the human primary somatosensory cortex, and that it receives input from intradental A-beta afferents. These results provide a detailed organizational map of the orofacial area in the primary somatosensory cortex, by adding dental pulp to the classic "sensory homunculus".

ACKNOWLEDGMENTS

This study was supported by grants from the High-Tech Research Center Project (HRC6 for T.I. and Y.S.), and by a Grant-in-Aid (No. 18592050 for Y.S.) for Scientific Research from M.E.X.T. of Japan. We sincerely thank Dr. Hiroki Bessho for his academic advice on this work, and Associate Professor Jeremy Williams for his assistance with the English of this manuscript.

REFERENCES

- Adriaensen H, Gybels J, Handwerker HO, Van Hees J (1983). Response properties of thin myelinated (A-delta) fibers in human skin nerves. *J Neurophysiol* 49:111-122.
- Ahluquist ML, Edwall LG, Franzén OG, Haegerstam GA (1984). Perception of pulpal pain as a function of intradental nerve activity. *Pain* 19:353-366.
- Baumgartner C, Doppelbauer A, Deecke L, Barth DS, Zeithofer J, Lindinger G, *et al.* (1991). Neuromagnetic investigation of somatotopy of human hand somatosensory cortex. *Exp Brain Res* 87:641-648.
- Bessho H, Shibukawa Y, Shintani M, Yajima Y, Suzuki T, Shibahara T (2007). Localization of palate area in human somatosensory cortex. *J Dent Res* 86:265-270.
- Byers MR (1984). Dental sensory receptors. *Int Rev Neurobiol* 25:39-94.
- Byers MR, Närhi MV (1999). Dental injury models: experimental tools for understanding neuroinflammatory interactions and polymodal nociceptor functions. *Crit Rev Oral Biol Med* 10:4-39.
- Cadden SW, Lisney SJW, Matthews B (1983). Thresholds to electrical stimulation of nerves in cat canine tooth pulp with A-beta, A-delta, and C fiber conduction velocities. *Brain Res* 261:31-41.
- Chatrjian GE, Canfield RC, Knauss TA, Eeg EL (1975). Cerebral responses to electrical tooth pulp stimulation in man. *Neurology* 25:745-757.
- Chudler EH, Dong WK, Kawakami Y (1985). Tooth pulp-evoked potentials in the monkey: cortical surface and intracortical distribution. *Pain* 22:221-233.
- Condes-Lara M, Calvo JM, Fernandez-Guardiola A (1981). Habituation to bearable experimental pain elicited by tooth pulp electrical stimulation. *Pain* 11:185-200.
- Cook SP, Vulchanova L, Hargreaves KM, Elde R, McCleskey EW (1997). Distinct ATP receptor on pain-sensing and stretch-sensing neurons. *Nature* 387:505-508.
- Desmedt JE, Cheron G (1980). Central somatosensory conduction in man: neural generators and interpeak latencies of the far-field components recorded from neck and right or left scalp and earlobes. *Electroencephalogr Clin Neurophysiol* 50:382-403.
- Dong WK, Shiwaku T, Kawakami Y, Chudler EH (1993). Static and dynamic responses of periodontal ligament mechanoreceptors and intradental mechanoreceptors. *J Neurophysiol* 69:1567-1582.
- Dostrovsky JO, Craig AD (1996). Cooling-specific spinothalamic neurons in the monkey. *J Neurophysiol* 76:3656-3665.
- Edwall L, Olgart L (1977). A new technique for recording of intradental sensory nerve activity in man. *Pain* 3:121-125.
- Hämäläinen MS (1992). Magnetoencephalography: a tool for functional brain imaging. *Brain Topogr* 5:95-102.
- Hari R, Kaukoranta E, Reinikainen K, Huopaniemi T, Mauno J (1983). Neuromagnetic localization of cortical activity evoked by painful stimulation in man. *Neurosci Lett* 42:77-82.
- Iwata K, Tsuboi Y, Muramatsu H, Sumino R (1990). Distribution and response properties of cat SI neurons responsive to changes in tooth temperature. *J Neurophysiol* 64:822-834.
- Jääskeläinen SK, Peltola JK, Forssell K, Vähätalo K (1995). Evaluating function of the inferior alveolar nerve with repeated nerve conduction tests during mandibular sagittal split osteotomy. *J Oral Maxillofac Surg* 53:269-279.
- Kanda M, Nagamine T, Ikeda A, Ohara S, Kunieda T, Fujiwara N, *et al.* (2000). Primary somatosensory cortex is actively involved in pain processing in human. *Brain Res* 853:282-289.
- Kawamura T, Nakasato N, Seki K, Kanno A, Fujita S, Fujiwara S, *et al.* (1996). Neuromagnetic evidence of pre- and post-central sources of somatosensory evoked responses. *Electroencephalogr Clin Neurophysiol* 100:44-50.
- Lekić D, Cenić D (1992). Pain and tooth pulp evoked potentials. *Clin Electroencephalogr* 23:37-46.
- Matsumoto N, Sato T, Yahata F, Suzuki TA (1987). Physiological properties of tooth pulp-driven neurons in the first somatosensory cortex (SI) of the cat. *Pain* 31:249-262.
- Matsumoto N, Sato T, Suzuki TA (1989). Characteristics of the tooth pulp-driven neurons in a functional column of the cat's somatosensory cortex (SI). *Exp Brain Res* 74:263-271.
- Matsuura N, Shibukawa Y, Ichinohe T, Suzuki T, Kaneko Y (2004). Ketamine inhibits pain-SEFs following CO₂ laser stimulation on trigeminally innervated skin region: a magnetoencephalographic study. *International Congress Series* 1270:121-125.
- Mumford JM, Stanley SJ (1981). Sensations on stimulating the pulps of human teeth, thresholds and tolerance ratio. *Pain* 10:391-398.
- Murayama S, Nakasato N, Nakahara H, Kanno A, Itoh H (2005). Neuromagnetic evidence that gingival area is adjacent to tongue area in human primary somatosensory cortex. *Tohoku J Exp Med* 207:191-196.
- Nagamatsu K, Nakasato N, Hatanaka K, Kanno A, Iwasaki M, Yoshimoto T (2000). Neuromagnetic localization of N15, the initial cortical response to lip stimulus. *Neuroreport* 22:1-5.
- Nakahara H, Nakasato N, Kanno A, Murayama S, Hatanaka K, Itoh H, *et al.* (2004). Somatosensory-evoked fields for gingival, lip, and tongue. *J Dent Res* 83:307-311.
- Närhi M, Jyvasiavi E, Vitranen A, Huopniemi T, Nagassapa D, Hironen T (1992). Role of intradental A- and C-type nerve fibers in dental pain mechanisms. *Proc Finn Dent Soc* 88(Suppl 1):507-516.
- Penfield W, Boldrey E (1937). Somatic motor and sensory representation in the cerebral cortex of man as studied by electrical stimulation. *Brain* 60:389-443.
- Price DD, Dubner R, Hu JW (1976). Trigeminothalamic neurons in nucleus caudalis responsive to tactile, thermal, and nociceptive stimulation of monkey's face. *J Neurophysiol* 39:936-953.
- Rossini PM, Traversa R (1990). Somatosensory evoked fields in magnetoencephalography. Basic principles and applications. *Adv Neurol* 54:157-166.
- Shibukawa Y, Shintani M, Kumai T, Suzuki T, Nakamura Y (2004). Cortical neuromagnetic fields preceding voluntary jaw movements. *J Dent Res* 83:572-577.
- Shibukawa Y, Ishikawa T, Kato Y, Zhang ZK, Jiang T, Shintani M, *et al.* (2006). Cerebral cortical dysfunction in patients with temporomandibular disorders in association with jaw movement observation. *Pain* 128:180-188.
- Suzuki T, Shibukawa Y, Kumai T, Shintani M (2004). Face area representation of primary somatosensory cortex in humans identified by whole-head magnetoencephalography. *Jpn J Physiol* 54:161-169.
- Tesche CD, Karhu J (1997). Somatosensory evoked magnetic fields arising from sources in the human cerebellum. *Brain Res* 744:23-31.