

Title	Clinical/photographic evaluation of a single application of two sealants after eleven years
Author(s)	Sundfeld, RH; Mauro, SJ; Briso, AL; Sundfeld, ML
Journal	Bulletin of Tokyo Dental College, 45(2): 67-75
URL	http://hdl.handle.net/10130/288
Right	

Original Article

**CLINICAL/PHOTOGRAPHIC EVALUATION OF
A SINGLE APPLICATION OF TWO SEALANTS
AFTER ELEVEN YEARS**

RENATO HERMAN SUNDFELD, SILVIO JOSÉ MAURO, ANDRÉ LUIZ FRAGA BRISO
and MARIA LÚCIA MARÇAL MAZZA SUNDFELD*

*Department of Restorative Dentistry, Araçatuba School of Dentistry,
Paulista State University, UNESP,
Rua José Bonifácio 1193, CEP. 16015 050, Araçatuba, São Paulo, Brazil*

* *Department of Biostatistics, Araçatuba School of Dentistry,
Paulista State University, UNESP,
Rua José Bonifácio 1193, CEP. 16015 050, Araçatuba, São Paulo, Brazil*

Received 24 February, 2003/Accepted for Publication 9 April, 2004

Abstract

The clinical behavior of Concise and Prisma Shield sealants for pit and fissure was analyzed by clinical/photographic evaluation. A hematoxylin-based staining solution was applied to the occlusal surface 7 days, 18 months, 36 months, and 11 years after the occlusal sealing, thus allowing the sealant material on the surface to be checked. At each analysis time, each occlusal surface was photographed, and the photographs corresponding to each time were submitted to clinical/photographic evaluation. Although the sealant materials showed marginal alterations over time, they did not require reapplication because the region composed of the pit and fissure remained covered.

Key words: Pit and fissure sealants—Clinical/photographic study—
Hematoxylin solution

INTRODUCTION

The occlusal surface is highly susceptible to the development of caries lesions, because the peculiar anatomical shape of this region makes correct hygiene difficult. Therefore, a caries lesion can start at the pit and fissures right after tooth eruption, and may, when not prevented or treated, lead to dental injury over time.

Dental caries is a multifactorial disease; even with optimal use of all available resources,

it can differ from person to person, from tooth to tooth, and from surface to surface⁵⁾. For a long time, this disease has constituted a great challenge for preventive and social dentistry and has stimulated many researchers to develop preventive methods to control it.

The advent of the acid-etch technique in 1955¹⁾ and the versatility of adhesive materials have allowed the mechanical coverage of pits and fissures and of dental enamel defects. This avoids the onset and progress of the disease, making it possible to considerably

control the cariogenic activity in such regions. Since the first clinical report on the use of pit and fissure sealants by Cueto & Buonocore in 1967³⁾, this excellent preventive tool has been extensively employed.

In light of this history, it can be affirmed that the sealing of structural enamel defects is an effective management practice that prevents the onset of caries lesions in pits and fissures, by the employment of resinous sealants, tinted or not, with or without fluoride or load particles in their composition, or even of a resinous or conventional ionomer. However, long term clinical success is directly related to the employment of an extremely accurate technique, because material loss is attributed, almost exclusively, to the inadequacy of the technique adopted. Likewise, periodic analysis of the teeth that have received occlusal sealants is a factor of utmost importance for the control and maintenance of the material in the oral cavity over time^{11,12,18-26)}, a fact which led us to pursue this longitudinal research.

MATERIALS AND METHODS

Forty-two premolars of 10 patients ranging from 12 to 14 years old were sealed. In 21 specimens, Concise (3M) autopolymerizable pit and fissure sealant (S1) was used; the others were sealed with Prisma Shield (Caulk & Dentsply) photopolymerizable sealant (S2).

Occlusal sealing of the 36 pits that were considered sound began with dental prophylaxis with pumice and water, followed by absolute isolation of the operating field, by acid conditioning of the whole occlusal surface with 37% phosphoric acid solution for 2 minutes⁸⁾, and by washing and drying the dental crown. Concise autopolymerizable sealant (S1) was applied to the occlusal pits and fissures with a bristle brush. In the same way, Prisma Shield photopolymerizable sealant (S2) was applied with a brush and immediately polymerized by a halogen light source (Fibralux Dabi Atlante) for 40 seconds.

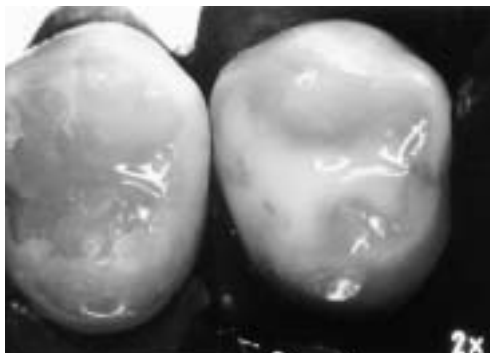


Fig. 1 Immediately after application of Concise sealant (S1), tooth 24, and Prisma Shield sealant (S2), tooth 25

At the same time, the other six specimens that had pits or fissures with minor located chromatic alterations, suggestive or not of the presence of incipient caries lesions, had these areas prepared with a smooth spherical carbide $\frac{1}{4}$ drill (K.G. Sorensen) to remove only the areas of chromatic alteration, keeping light pits and fissures intact. Following that, after dental prophylaxis, absolute isolation, acid conditioning of dental enamel of the whole occlusal surface including the conservative cavities, and careful washing and drying of the occlusal surface, the conservative cavities received a thin layer of adhesive material (Prisma Bond-Caulk/Dentsply), which was polymerized for 20 seconds. A single layer of composite resin (Full Fill-Caulk/Dentsply) was then immediately placed exclusively inside the conservative cavity with no overlap on the borders¹⁷⁾. The composite resin polymerization was carried out for 40 seconds. Posteriorly, all pits and fissures of the occlusal surface, as well as the surface of the composite resin that restored the conservative cavity, were brushed with either Concise autopolymerizable pit and fissure sealant (S1) or Prisma Shield (Caulk & Dentsply) photopolymerizable sealant (S2), in the same way that the process was carried out in the teeth without chromatic alterations (Fig. 1).

On the 7th day after sealant application, as well as after 18 months, 36 months and 11

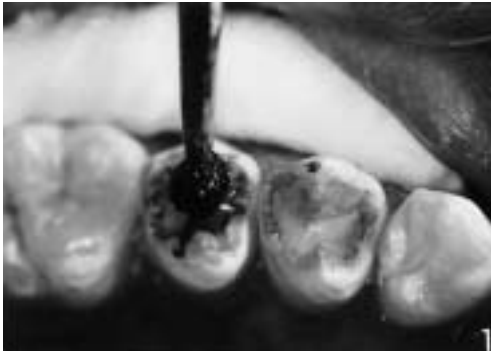

Fig. 2 Application of the staining solution

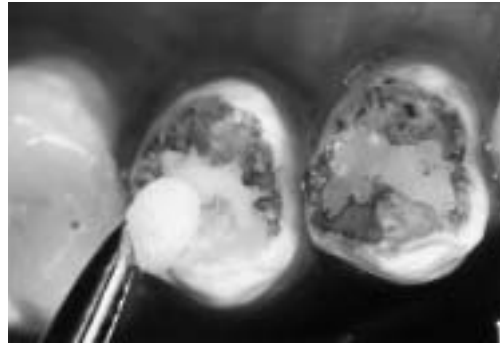


Fig. 3 Removal of the staining solution from occlusal surface

Table 1 Criteria for clinical/photographical analysis of sealing retention (sealing marginal loss)

R	FULL SEALING RETENTION (absolute absence of marginal loss)
PM	PARTIAL MARGINAL SEALING LOSS
PM1	SMALL EXTENSION
PM2	LARGE EXTENSION
PM3	WHOLE BORDER
T	FULL SEALING LOSS (total lack of sealant)

years, a staining solution, as proposed by Ohkubo *et al.*¹²⁾ in 1982, was applied to all the occlusal surfaces for 2–3 minutes (Fig. 2). It is interesting to note that this solution is characterized by its ability to stain only the enamel surface and not the sealant, thus highlighting its contour and making it easy to identify its limits.

At these times, all the occlusal surfaces of all specimens were frontally photographed so that the edge and body of the sealant could be clearly seen. A Nikon camera equipped with a 2× magnification medical lens was used. After the photo shooting session, the bluish coloring caused by the hematoxylin in the solution was immediately removed by the application of 1% sodium hypochlorite (Fig. 3).

The photographs of each specimen taken at the aforementioned evaluation times were analyzed and compared to one another to

analyze the marginal loss of sealant over time.

The comparative clinical/photographic analyses, carried out 7 days, 18 months, 36 months and 11 years after sealing, were performed by two properly calibrated examiners, using the criteria proposed by Tonn and Ryge in 1982,²⁸⁾ with a few modifications introduced by us (Table 1).

The results were statistically analyzed by Kappa⁹⁾ test to assess the degree of reproducibility between the examiners. The Mann-Whitney non-parametric statistical test at a 5% significance level¹⁶⁾ was applied afterwards to compare the behavior of the two sealing materials at the aforementioned times.

RESULTS

Thirty-eight occlusal sealing specimens,

Table 2 Summary of clinical/photographical evaluations of occlusal sealing with Concise (S1) and Prisma Shield (S2) sealants at the initial time of analysis (7 days) (T0), 18 months (T1), 36 months (T2), and 11 years (T3)

	INITIAL (7 DAYS) (T0)		18 MONTHS (T1)		36 MONTHS (T2)		11 YEARS (T3)	
	S1	S2	S1	S2	S1	S2	S1	S2
R	20	18	4	0	0	0	0	0
PM1	0	0	12	6	8	1	0	0
PM2	0	0	4	8	11	7	6	1
PM3	0	0	0	4	1	10	14	17
T	0	0	0	0	0	0	0	0

Table 3 Results of Mann-Whitney non-parametric test applied to the scores obtained in the clinical/photographical analysis

TIME OF ANALYSIS	AVERAGE OF POINTS		Z	P VALUE
	SEALANTS			
	CONCISE (S1)	PRISMA SHIELD (S2)		
18 months	14.30	25.28	-3.2778	0.0010*
36 months	13.82	25.81	-3.5849	0.0003*
11 years	17.30	21.94	-1.9151	0.0555

* Statistically significant at 5% for H0 rejection.

Tested hypotheses:

H0: The sealants presented the same behavior.

H1: The sealants presented different behavior.

corresponding to only those patients who were present for all evaluation times were analyzed for marginal alterations (Table 2). The specimens corresponding to the patients who were unable to be assessed after 11 years were discarded. According to the methodology proposed, the Kappa test⁹⁾ was applied to the results obtained in the clinical/photographic analysis to verify the degree of agreement between the two examiners. No statistically significant difference was detected, so it was decided to consider only the results collected by one of the examiners.

Based upon the results obtained, the Mann-

Whitney non-parametric statistical test significant at 5%¹⁶⁾ was applied to compare the behavior of the two sealants in terms of marginal loss at the aforementioned times according to the scores obtained (Table 3).

The application of the Mann-Whitney test detected a statistically significant difference between the two sealants at 18 months (T1) and 36 months (T2), Concise sealant (S1) showed less marginal material loss over these periods. However, the same finding was not seen for the 11-year clinical/photographic analysis (T3), according to which the two sealants showed statistically similar behavior,

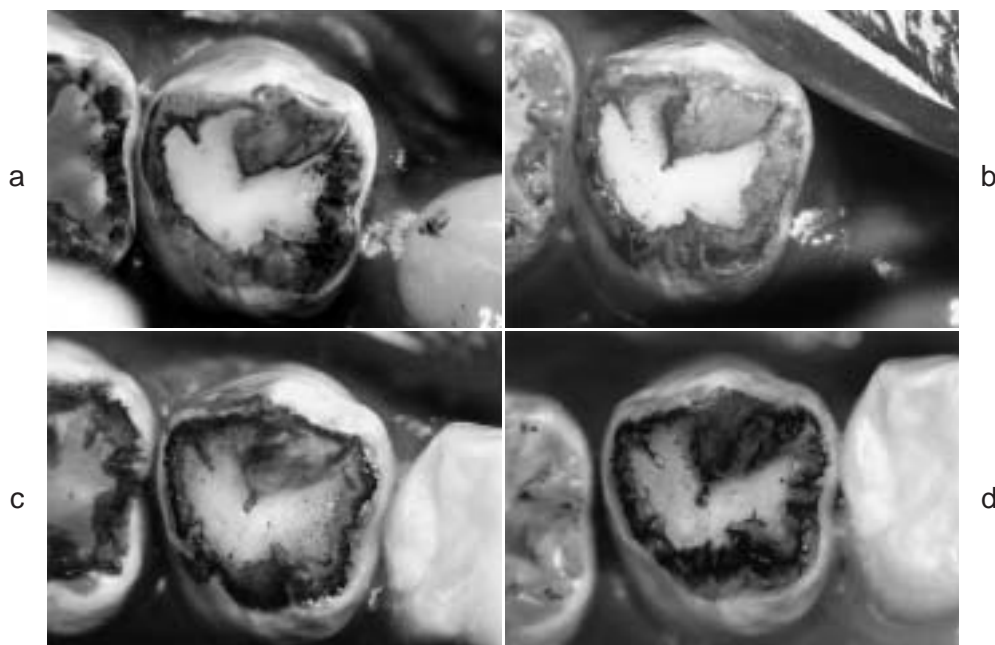


Fig. 4 Photos of specimen with Concise sealant (S1), tooth 24:

- a: 7 days after occlusal sealing and immediately after application of staining solution.
- b: 18 months after occlusal sealing and immediately after application of staining solution.
- c: 36 months after occlusal sealing and immediately after application of staining solution.
- d: 11 years after occlusal sealing and immediately after application of staining solution.

presenting the same level of marginal loss (Fig. 4a, b, c, d and 5a, b, c, d).

DISCUSSION

Caries lesions may start in pits and fissures soon after dental eruption¹⁵. If not prevented or treated, they may lead to dental loss. The use of pit and fissure sealants to cover these defects can hamper caries onset, and consequently, its development²¹⁻²⁶.

The clinical success of the application of sealants is directly related to the employment of an extremely accurate technique, because material loss is attributed almost exclusively to the ineffectiveness of the technique adopted²¹⁻²⁶. This fact is supported by what has been observed in this study and by Simonsen's reports in 1987¹⁸ and in 1991¹⁹, which affirmed, among other considerations,

that the occlusal sealants assessed 10 and 15 years after the applications presented excellent material retention rate, and, consequently, prevented dental caries. These reports also reaffirmed that the application technique is of fundamental importance for material longevity on the dental surface.

Therefore, we maintain that incorrect application of the principles of the sealing technique is the major and deciding factor in the failure of the sealing procedures, and we emphasize that if you are going to do it, "do it correctly, otherwise, don't do it!"

In this study, we find clear evidence of a greater sealed area on the occlusal surface of almost all the specimens that had received Prisma Shield sealing (S2). This clinical difference may have occurred by sheer chance at the moment of application of the material, but this finding could also be due to the fact that this sealant has 50% of inorganic load

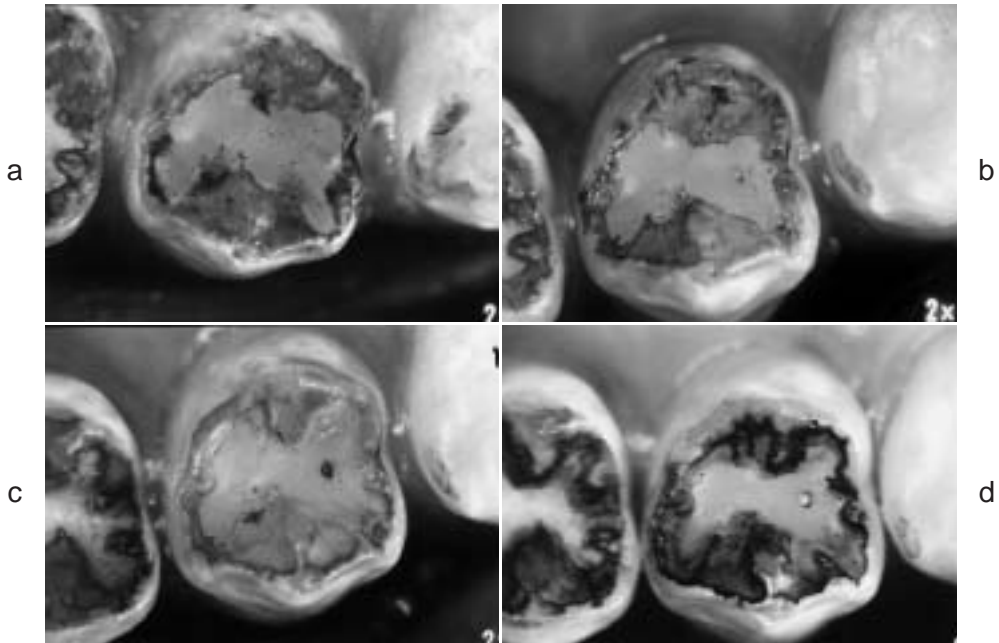


Fig. 5 Photos of specimen with Prisma Shield sealant (S2), tooth 14:

- a: 7 days after occlusal sealing and immediately after application of staining solution.
- b: 18 months after occlusal sealing and immediately after application of staining solution.
- c: 36 months after occlusal sealing and immediately after application of staining solution.
- d: 11 years after occlusal sealing and immediately after application of staining solution.

particles in its composition, making it more viscous and thus making proper drainage in the pit as well as on the surface where it was applied difficult. This could result in a larger sealed area. This pattern was not seen with Concise Sealant (S1), which does not have load particles in its composition.

However, the discrepancy between the two sealants in the marginal alterations that was verified in the initial period (T0) gradually diminished, and a similar sealed area was found after 11 years (T3).

The Concise Sealant (S1) has pigments in its composition, making it easier to visualize changes on the occlusal surface over time. However, the coloring on the occlusal dental enamel provided by hematoxylin provided clear evidence of marginal and superficial alterations that occurred in the sealing carried out with both sealants^{12,21,22}.

In addition to the marginal changes, overall

alteration of the sealing surfaces could be detected through the appearance or disappearance of superficial bubbles. This demonstrates the existence of occlusal wear suffered by both materials on the teeth positioned in the dental arch, which is caused by the movements of eruption and articular accommodation. We emphasize that the fact that Prisma Shield Sealant demonstrated a greater tendency to show these alterations at all evaluation times might be related to its greater viscosity, perhaps because the incorporation of load particles in its composition may hamper the proper draining and accommodation inside the pit, as well as on the surface to which it was applied. Considering this concept in 1994²³; 1996²⁵; and in 1999²⁶, Sundfeld *et al.*, in attempting to avoid the possible formation of bubbles within the sealant, proposed that the photopolymerizable sealing material with load particles be applied to occlusal pits and

fissures under vibration with the help of an exploratory probe and that it be polymerized for 10 seconds after application. Although we have verified that the presence of bubbles is not detrimental to the good clinical performance of the sealant, they may be detrimental when they are located on the borders of the sealant, *i.e.*, on the marginal sealant/enamel interface. This might, occasionally, lead to the onset of carious lesions due to a possible bacterial plaque and food residue buildup on this interface.

Although the results observed in this study can be interpreted to favor the employment of the chemically polymerizable sealant due to its lower material loss, the photopolymerizable sealant does offer some advantages. These include a reduction in work time, because it requires a polymerization time of about 40 seconds against 60 seconds for the chemically activated one, the elimination of the mixture of the two components⁷, and the option for the professional to choose his working time^{7,23,25,26}.

The excellent clinical performance of both sealants, Concise (S1) and Prisma Shield (S2), at 18 months, 36 months, and 11 years post occlusal sealing is determined mainly by the extremely accurate technique used, with emphasis on the fact that the material was applied to conditioned dental enamel that was thoroughly dried and not contaminated. This fact is certainly correlated with the considerable retention shown by the sealing materials employed, because the enamel was acid conditioned on all occlusal surfaces, so the sealant was never applied to unconditioned enamel. This fact clearly explains why we did not observe either total loss of sealing material or carious lesions around the sealants in this study, as well as in previous studies conducted by us²¹⁻²⁶, even when the material was solely resinous, with or without fluoride.

In considering sealing material wear over time, we should emphasize that, from the moment of wear of the sealing material on the slope, occlusal contacts occurred between teeth, and the remaining sealant was largely kept away from the occlusal contact, thereby

presenting less material wear after the articular accommodation. Thus, the sealant was subjected to less wear, only that caused by teeth brushing and by the attrition of food during mastication. It is interesting to note that, according to our results and to those of Tillis *et al.* in 1992²⁷, the sealant is susceptible to wear over time, because it is applied on the occlusal surface while permanent teeth are still in a stage of accommodation and articular positioning in the dental arch. We can therefore infer that the sealant wear over time will not interfere with its clinical purpose, provided that the remaining material covers the expected region of the pits and fissures.

Although this study presents a precise and subjective evaluation, we cannot forget the fact that, at the photo shooting sessions performed for control evaluation, it was not possible to frame the tooth in exactly the same position as in photographs taken previously, because of technical difficulties and/or because the tooth was not occupying exactly the same position and location in the dental arch at all assessed times. This fact is partially related to the slight dental movements that occur during occlusal stabilization, because the patients in this study were teenagers, and the evaluation time of 11 years was relatively long.

Likewise, other studies have reported that all sealings undergo a period of marginal loss^{6,10,12,18,19,21-26} and wear^{2,4,13,14}, which expose areas that had been previously covered by sealing material, and that these areas of material loss are intimately related to tooth anatomy and position in the arch.

It is noteworthy that the material wear could also be confirmed by the appearance, over time, of superficial bubbles in the sealings being analyzed, more specifically, on the teeth which had received Prisma Shield load sealing (S2). The clinical excellence shown by Concise sealing (S1) in this study is in accordance with Simonsen's findings in 1987¹⁸ and 1991¹⁹, which reported an optimum clinical behavior after 10 and 15 years of clinical analysis with a single application of this material.

Based upon the results obtained and the concepts discussed here, we conclude that the sealing materials underwent marginal alterations throughout time, with superior clinical behavior for Concise sealing (S1), at the 18-month and 36-month analyses. However, after 11 years, both materials showed the same level of marginal alteration. Neither sealing material required reapplication, because the region encompassing the pit and fissure remained covered at all aforementioned times of analysis.

Therefore, we emphasize that what is important is sealing the area necessary to protect and safely cover the critical anatomical region over time, effectively avoiding the onset of caries lesions in dental enamel structural defects.

ACKNOWLEDGEMENTS

The authors thank to the patients that have made this study possible.

REFERENCES

- 1) Buonocore, M.G. (1955). A simple method of increasing the adhesion of acrylic filling materials enamel surfaces. *J Dent Res* **34** (6), 849–853.
- 2) Conry, J.P., Pintado, M. and Douglas, W.H. (1990). Measurement of sealant surface area by computer. *Quintessence Int* **21**, 14–17.
- 3) Cueto, E.J. and Buonocore, M.G. (1967). Sealing of pits and fissures with an adhesive resin: Its use in caries prevention. *J Am Dent Assoc* **75** (1), 121–128.
- 4) DeLong, R., Pintado, M. and Douglas, W.H. (1985). Measurement of change in surface contour by computer graphics. *Dent Mater* **1**, 27–30.
- 5) Eklund, S.A. and Ismail, A.I. (1986). Time of development of occlusal and proximal lesions implications for fissure sealants. *J Public Health Dent* **46** (2), 114–121.
- 6) Going, R.E., Conti, A.J., Haugh, L.D. and Grainger, D.A. (1976). Two year clinical evaluation of a pit and fissure sealant. Part I: Retention and loss of substance. *J Am Dent Assoc* **92** (3), 388–397.
- 7) Hardison, J.R., Collier, D.R., Sprouse, L.W., Van Cleave, M.L. and Hogan, A.D. (1985). The clinical effectiveness of a visible light-polymerized sealant: 24 month results. *Compend Contin Educ Dent* **6**, 229–233.
- 8) Komatsu, J. and Russo, M. (1979). Restaurações estéticas em dentes anteriores sem preparo cavitário convencional: Estudo clínico. *Rev Assoc Paul Cir Dent* **9**, 386–392.
- 9) Landis, J.R. and Koch, G.G. (1977). The measurement of observer agreement for categorical data. *Biometrics* **33** (1), 159–174.
- 10) Mauro, S.J., Sundfeld, R.H., Komatsu, J. and Holland Junior, C. (1991). Análise clínica da retenção de restaurações confeccionadas com resina composta e selantes de fôssulas e fissuras: efeitos de materiais e tempos. *Rev Reg Assoc Paul Cir Dent Araçatuba* **12**, 14–17.
- 11) Mertz-Fairhurst, E.J., Fairhurst, C.W., Williams, J.E., Della-Giustina, V.E. and Brooks, J.D. (1982). A comparative clinical study of two pit and fissure sealants: Six-year results in Augusta, Ga. *J Am Dent Assoc* **105** (2), 237–239.
- 12) Ohkubo, N., Iwata, S., Chikada, K., Kuriyama, S., Narita, M., Ishikawa, T. and Yoshida, T. (1982). A retention comparison of two sealants. *Bull Tokyo dent Coll* **23** (4), 201–219.
- 13) Pintado, M., Conry, J.P. and Douglas, W.H. (1988). Measurement of sealant volume *in vivo* using image-processing technology. *Quintessence Int* **19** (9), 613–637.
- 14) Pintado, M., Conry, J.P. and Douglas, W.H. (1991). Fissure sealant wear at 30 months: New evaluation criteria. *J Dent* **19** (1), 33–38.
- 15) Reich, E., Luss, A. and Newbrun, E. (1999). Caries-risk assessment. *Int Dent J* **49** (1), 15–26.
- 16) Siegel, S. (1975). *Estatística Não-Paramétrica*. p.350, McGraw-Hill, São Paulo.
- 17) Simonsen, R.J., Thompson, V. and Barrack, G. (1985). *Restaurações Adesivas Técnicas: Clínica e Laboratorial*. Medicina Panamericana, São Paulo.
- 18) Simonsen, R.J. (1987). Retention and effectiveness of a single application of white sealant after 10 years. *J Am Dent Assoc* **115** (1), 31–36.
- 19) Simonsen, R.L. (1991). Retention and effectiveness of dental sealant after 15 years. *J Am Dent Assoc* **122** (11), 34–42.
- 20) Sundfeld, R.H. (1990). *Análise Microscópica da Penetração “in Vivo” de Selantes de Fôssulas e Fissuras: Efeitos de Tratamentos Superficiais e Materiais*. Araraquara. p.146, PhD Thesis—School of Dentistry, Paulista State University.
- 21) Sundfeld, R.H., Mauro, S.J., Komatsu, J. and Mestreneer, S.R. (1992). Retenção dos selantes: avaliação clínica fotográfica: 18 meses de análise. *RGO* **40** (6), 424–426.
- 22) Sundfeld, R.H., Mauro, S.J., Komatsu, J. and

- Mestrener, S.R. (1993). Análise clínica fotográfica da retenção de selantes de fósulas e fissuras: 36 meses de análise. *Âmbito Odontol* **3** (14), 334–339.
- 23) Sundfeld, R.H., Komatsu, J., Holland Junior, C. and Hoepfner, M.G. (1994). Análise da retenção e da penetração de um selante com flúor (Fluroshield): estudo clínico e microscópico. *Rev Assoc Paul Cir Dent* **48** (1), 1251–1255.
- 24) Sundfeld, R.H., Komatsu, J., Mauro, S.J., Holland Junior, C. and Hoepfner, M.G. (1994). Selamento oclusal com ionômero de vidro fotopolimerizável: uma proposta altamente eficaz na prevenção da cárie dental. *Âmbito Odontol* **3** (16), 3–7.
- 25) Sundfeld, R.H., Komatsu, J., Holland Junior, C., Mauro, S.J. and Hoepfner, M.G. (1996). Avaliação clínica da retenção de um selante com flúor (Fluroshield): 18 meses de análise. *Âmbito Odontol* **6** (20), 5–8.
- 26) Sundfeld, R.H., Mauro, S.J., Holland Junior, C., Mestrener, S.R., Sundfeld, M.L.M.M. and Briso, A.L.F. (1999). Aplicação de selantes: confirmação de um recurso eficaz na prevenção das lesões de cárie de fósulas e fissuras. *Rev Bras Odontol* **56** (2), 76–82.
- 27) Tillis, T.S., Stach, D.J., Hatch, R.A. and Cross-Poline, G.N. (1992). Occlusal discrepancies after sealant therapy. *J Prosthet Dent* **68** (2), 223–228.
- 28) Tonn, E.M. and Ryge, G. (1982). Three-year clinical evaluation of four sealants in Los Altos, California. In *General Session International Association For Dental Research*. New Orleans, Louisiana, USA, March.

Reprint requests to:

Dr. Renato Herman Sundfeld
Department of Restorative Dentistry,
Araçatuba School of Dentistry,
Paulista State University, UNESP,
Rua José Bonifácio 1193,
CEP. 16015 050, Araçatuba,
São Paulo, Brazil
Fax: (018) 6203332
E-mail: sundfeld@terra.com.br.