

Title	Model surgery technique for Le Fort I osteotomy-- alteration in occlusal plane associated with upward transposition of posterior maxilla
Author(s)	Yosano, A; Yamamoto, M; Shouno, T; Shiiki, S; Hamase, M; Kasahara, K; Takaki, T; Takano, N; Uchiyama, T; Shibahara, T
Journal	Bulletin of Tokyo Dental College, 46(3): 67-78
URL	http://hdl.handle.net/10130/240
Right	

Clinical Report

Model Surgery Technique for Le Fort I Osteotomy —Alteration in Occlusal Plane Associated with Upward Transposition of Posterior Maxilla—

Akira Yosano, Masae Yamamoto, Takahiro Shouno,
Sayaka Shiiki, Maki Hamase, Kiyohiro Kasahara, Takashi Takaki,
Nobuo Takano, Takeshi Uchiyama and Takahiko Shibahara

*Department of Oral and Maxillofacial Surgery, Tokyo Dental College,
1-2-2 Masago, Mihama-ku, Chiba 261-8502, Japan*

Received 15 July, 2005/Accepted for Publication 5 October, 2005

Abstract

It is difficult to translate analytical values into accurate model surgery by traditional methods, especially when moving the posterior maxilla. This is because cephalometric radiographic analysis generated information on movement of the posterior nasal spine (PNS) can not be recreated in model surgery.

Therefore, we propose a method that accurately reflects such analysis and simulation of movement using Quick Ceph® 2000 (Orthodontic Processing Corporation, USA). This will allow the enrichment of model surgery prior to actual surgery in cases where upward movement of the posterior maxilla is involved.

All patients who participated in this study had skeletal mandibular prognathism characterized by a small occlusal plane angle in respect to the S-N plane. Cephalometric radiographs were taken and analyzed with the Quick Ceph® 2000. Pre- and post-surgical evaluations were performed using Sassouni arc analysis and Ricketts analysis. Prior to transposition, we then prepared an anterior occlusal bite record on a model mounted on an articulator. This bite was then used as a reference when the molar parts were to be transposed upwards.

The use of a occlusal bite permitted an accurate translation of the preoperative computer simulation into model surgery, thus facilitating favorable surgical results.

Key words: Occlusal alteration—Model surgery—Bimaxillary surgery—
Computer simulation—Occlusal bite record

Introduction

In orthognathic surgery, performing an operation on the mandible alone does not allow satisfactory occlusal position of the maxilla and mandible. If there is an abnormality in the inclination of the maxillary occlusal

plane, it is difficult to achieve stability of functional occlusion. The necessity of achieving a harmony of functional and esthetic aspects in such cases requires bimaxillary surgery, as this allows abnormal inclination of the maxillary occlusal plane to be reformed and occlusion to be reconstructed^{4,5,8)}. For such complicated

transposition of the maxilla, it is essential to establish a plan of pre-surgery by modeling the procedure in advance with a two-dimensional recreation of the movement by paper surgery or a computer simulation. However, even when preoperative planning has been performed with the greatest accuracy, any discrepancy between the plan and the bite splint or based on model surgery will lead to inaccuracies in actual surgery. It is consequently of critical importance that model surgery should be based on an accurate translation of maxillary transposition data from the analysis stage to the model surgery stage. It is difficult, however, to translate analytical values into accurate model surgery by traditional methods, especially when movement of the posterior maxilla is involved. This is because cephalometric radiographic analysis generated information on movement on the posterior nasal spine (PNS) can not be recreated in model surgery. This is because it is impossible to reproduce transpositional information from a PNS cephalographic analysis into model surgery.

Therefore, we propose a method that accurately reflects such analysis and simulation of movement using Quick Ceph® 2000 (Orthodontic Processing Corporation, USA). This will allow the enrichment of model surgery prior to actual surgery in cases where upward movement of the posterior maxilla is involved.

Materials and Methods

1. Patients

The patients who participated in this study had skeletal mandibular prognathism characterized by a small angle of occlusal plane to the S-N plane. They required bimaxillary surgery for alteration of the occlusal plane by upward movement of the molar part of the maxilla.

2. Methods

1) Cephalometric analysis and interpretation

An operative plan for orthognathic surgery was established by using frontal and lateral

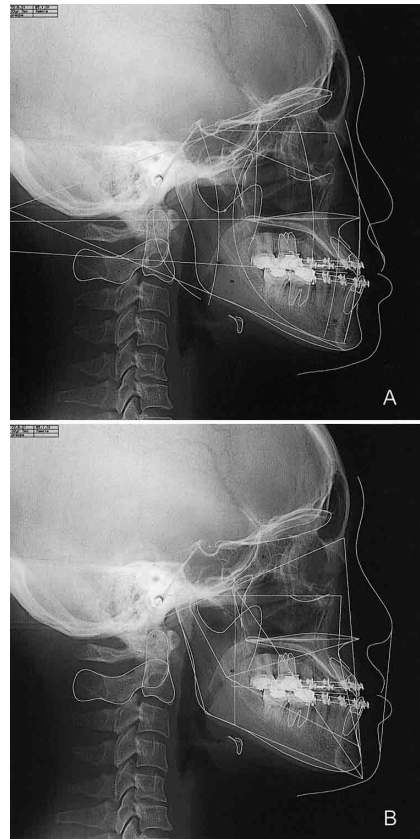


Fig. 1 Cephalometric analysis
A: Sassouni arc analysis
B: Ricketts analysis

cephalometric radiographs taken after pre-operative orthodontic procedure. To input measurements and analyze the data obtained from the cephalometric radiograph, we used the Quick Ceph® 2000. For pre- and post-operative evaluations, a Sassouni arc analysis and Ricketts analysis were used^{9,10)} (Fig. 1A, B). Based on the results of the analysis, a simulation of maxillary and mandibular movement was performed to determine the amount of movement required by using the Quick Ceph® 2000 (The amount of the movement of the posterior maxilla was determined by estimating from the movement distance of the first molars with the Quick Ceph® 2000, too.) (Fig. 2). On performing maxillary transposition simulation with the Quick Ceph® 2000, we rotated the occlusal plane clockwise,

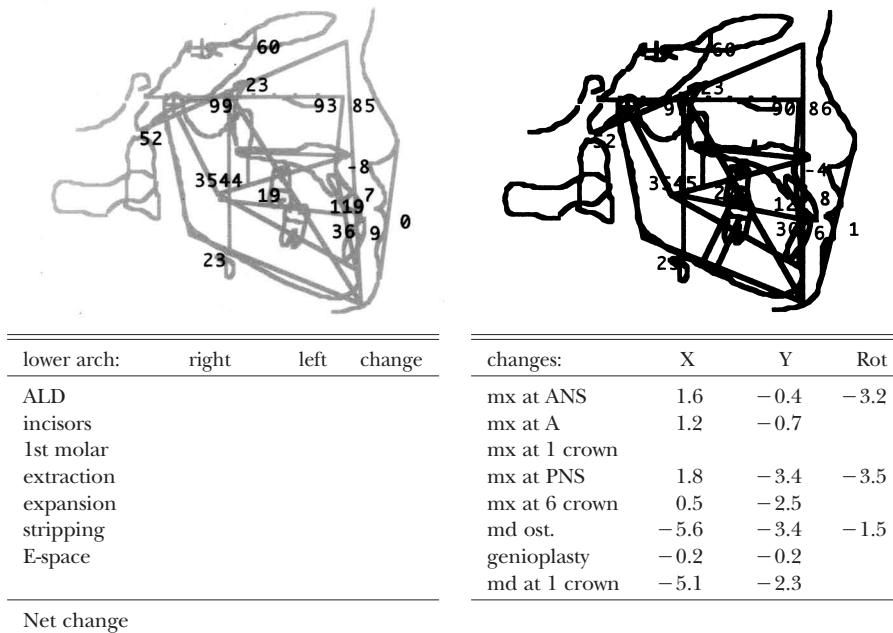


Fig. 2 Repositioning simulation

Quick Ceph® 2000 simulation of maxillary and mandibular movement to determine amount of movement. mx: maxilla, md: mandible

with the maxillary incisor as the center. One study reports that “the extension line of the occlusal plane in subjects with normal occlusion passes through a fourth of the length of the dens from the center at the base of the dens”¹¹). Based on these observations, we rotated the occlusal plane clockwise, with the maxillary incisor tip or the anterior nasal spine (ANS) as the center.

2) Measurement points and items

We used a total of 48 points of measurement in this study. These included the Corpus right, the topmost end-point of the dens, and the basal center of the dental process, in addition to the measurement points required from the Sassouni arc analysis of the profile. For the cephalometric porion, the anatomical porion was used (Fig. 3).

3) Model preparation and mount

After pre-surgical orthodontic surgery, impressions of the upper and lower teeth were taken and working models of each were made with plaster. The height of the base of each of the working models was then deter-

mined in the following manner: to determine the anterior base height of the maxillary model, the distance from the tip of the maxillary incisor to the ANS as determined by x-ray cephalometry was measured using a lateral cephalometric radiograph. The anterior base height was then brought into alignment with this distance from ANS to the incisor tip. The posterior base height of the maxillary model was determined by using the frontal cephalometric radiograph and determining the distance from the buccal cusp of the first maxillary molar on the left and right or the buccal bracket on the x-ray film to the zygomatico-maxillary suture (MX). The base height of each side of the model was then brought into alignment with these distances. After determining the height, this was then aligned with the plane formed by the ANS and the left and right MX. The base surface of the maxillary model was then trimmed and flattened accordingly. Next, to determine the antero-posterior distance of the base of the maxillary model, we measured the horizontal distance

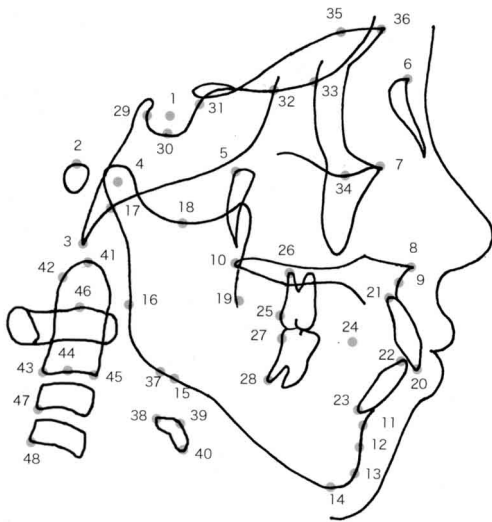


Fig. 3 Cephalometric landmarks

Total points: 48. 1. Sella, 2. Porion, 3. Basion, 4. Hinge Axis, 5. Pterygoid, 6. Nasion, 7. Orbitale, 8. ANS, 9. A point, 10. PNS, 11. B point, 12. PM, 13. Pogonion 14. Menton, 15. Corpus Left, 16. Ramus down, 17. Articulare, 18. R3, 19. R1, 20. mx1 crown, 21. mx1 root, 22. md1 crown, 23. md1 root, 24. mx4 crown, 25. mx6 crown, 26. mx6 root, 27. md6 crown, 28. md6 root, 29. Sella Posterior, 30. Sella Inferior, 31. Clinoidale, 32. Cilibiform, 33. Temporale, 34. Floor of the orbitale, 35. Roof of the orbitale, 36. Supraorbitale, 37. Corpus right, 38. Hyoid Bone top, 39. Hyoid Bone prominent, 40. Hyoid Bone bottom, 41. CV2apex, 42. CV2tg, 43. CV2ip, 44. CV2base, 45. CV2ia, 46. Dens Axis base, 47. CV3ip, 48. CV4ip

between the maxillary incisor and the ANS based on the lateral cephalometric radiograph. For the left-right distance of the base of the model we measured from the mid-sagittal reference plane (MSR) to the left and right MX based on the posterior-anterior cephalometric radiograph (Fig. 4A~D). We referenced a study by Motohashi *et al.* for selective of anatomical points (i.e. MX) for model preparation⁷⁾. The height of the base of the mandibular model was trimmed and flattened so that the base was parallel with the occlusal plane. The sides of the base of the mandible were then trimmed so that they were perpendicular to the base surface.

The maxillary model was mounted on an articulator by performing face-bow transfer as reported in the literature and achieving occlusion in the mandibular rest position by

means of paraffin wax (Fig. 5A~D). To mount the maxillo-mandibular model, we wound polyvinyl tape around the base so that the segment for the base of the model and the base of the mounting cast ran flush against each other. Baseline was applied to the base surface as a separating agent to facilitate separation of the base of the models and the base of the mounting cast. Furthermore, an incisal guide pin was placed in position in alignment with 0 line prior to mounting.

4) Transposition of the model

After the model was mounted onto the articulator, baselines were drawn on the base of the maxillo-mandibular model and on the base of the mounting cast. At least four baselines were drawn on both the maxilla and the mandible, namely, the front, rear, left, and right baselines. Anteriorly, a baseline (line A and A') was drawn perpendicular to the base surface in the median at the front of the maxillary and mandibular alignment of the teeth. At the left and right sides, baselines (lines B, B' and C, C') were drawn perpendicularly to the horizontal FH plane in the distal position of the bracket of the first molars. Posteriorly, a baseline (line D and D') was drawn perpendicular to the base surface in the median at the dental arch. These baselines were drawn by marking with a saw, and used for measuring amount of movement (Fig. 6A~D).

After the baselines were drawn, the occlusion of the maxillary and mandibular front teeth (the distance from at least one canine to the other canine of the maxilla has to be marked off) before movement was obtained on the model to prepare the bite of the front teeth (referred to as "Occlusal Alteration Bite (OA bite)" below). Such OA bites are best made from materials that show little deformation while being sufficiently flexible. In this study, we used an EXTRA EXAFINE PUTTY TYPE[®] (GC Corp.). The top surface of the OA bite (i.e., the side on which the maxillary dentition has been marked off) should be as thin and flat as possible to the extent that the cutting margin and heads of the front teeth are recorded (Fig. 7A~C).

After obtaining the bite, the base of the

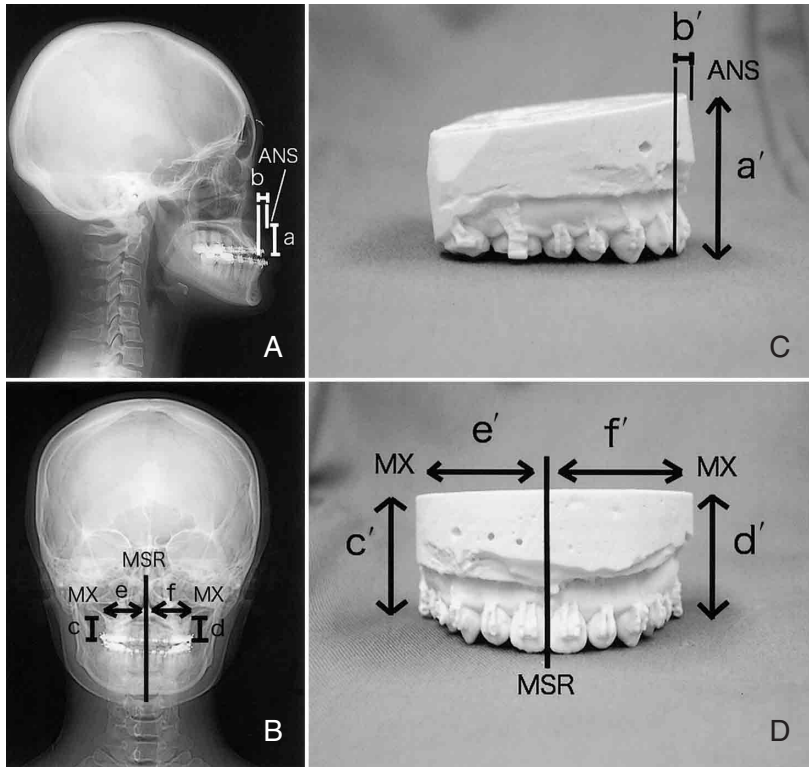


Fig. 4 Length of model base

a is vertical distance and b is horizontal distance from ANS to the tip of upper incisor. c and d are vertical distance from first molar of maxilla to MX. e and f are horizontal distance between MSR and MX. Length $a = a'$, $b = b'$, $c = c'$, $d = d'$, $e = e'$ and $f = f'$.

maxillary model and the base of the mounting cast were separated and the maxillary model displaced. Movement of the maxillary model was performed to reproduce the movement simulated previously with the Quick Ceph® 2000. First, the maxillary molar part was moved in the upward direction. The movement of the posterior part of the maxilla (i.e., the upward movement of the PNS) was determined by estimating the movement distance of the first molars on either side of the maxilla. This was because the PNS can not be reproduced on a model, and the movement distance of the PNS can not be measured in an actual operation. Thus, the computer-calculated distance of movement of the first maxillary molars was marked on the base of the mounting cast, and the base of the mount-

ing cast was then trimmed to this height in conjunction with the movement of the first maxillary molars (The base of the maxillary model must not be trimmed). This operation had to be performed in such a manner that the height of the front part (i.e., ANS part) did not change. The base of the mounting cast was imparted with a cant from the front to the rear. After this, the posterior part of the maxillary model was moved upwards to bring the base of the model into close contact with the base of the mounting cast. To do this, we used the OA bite of the front teeth obtained prior to movement. First, the OA bite was made to fit on the mandible, and then the maxillary front teeth were made to fit with the OA bite. The maxillary front teeth of the OA bite served as the fulcrum or support point




Fig. 5 Mount of model

A, B: The maxillary model is mounted by performing face-bow transfer.
 C: Wax bite record taken in mandibular rest position.
 D: The mandibular model is mounted by using paraffin wax bite.

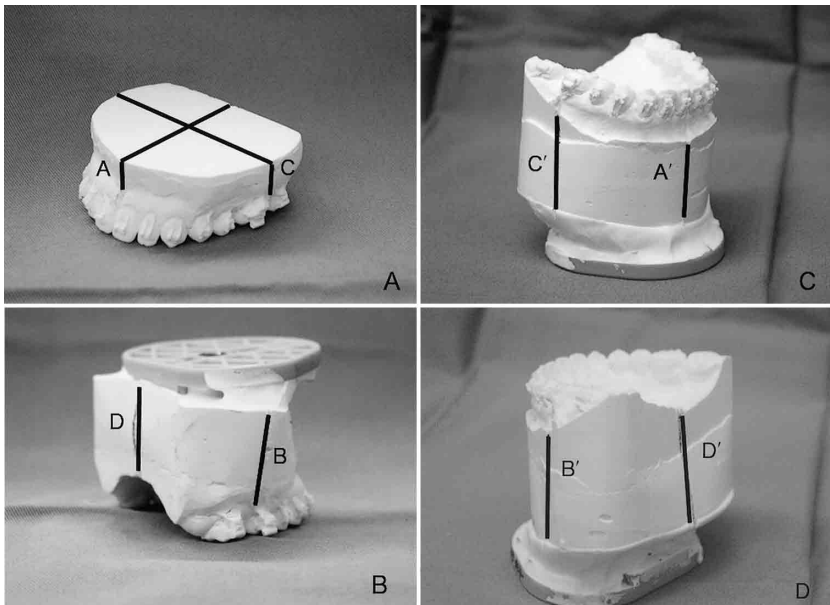


Fig. 6 Baselines on cast

Lines A and A' are drawn in median at front of maxillary and mandibular alignment of teeth.
 Lines B, B' and C, C' are drawn to horizontal surface FH in distal position of the bracket of first molars.
 Lines D and D' are drawn posteriorly in median at dental arch.

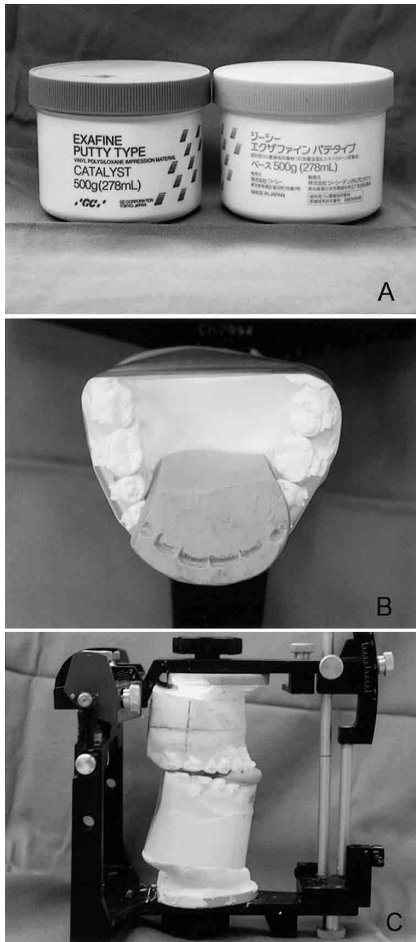


Fig. 7 The material and method for making occlusal alteration bite

- A: EXAFINE PUTTY TYPE[®] used to make bite.
- B, C: Occlusion of maxillary and mandibular front teeth is obtained on model. Area from at least one canine other canine of maxilla is marked off. (B: Occlusal view, C: Sagittal view)

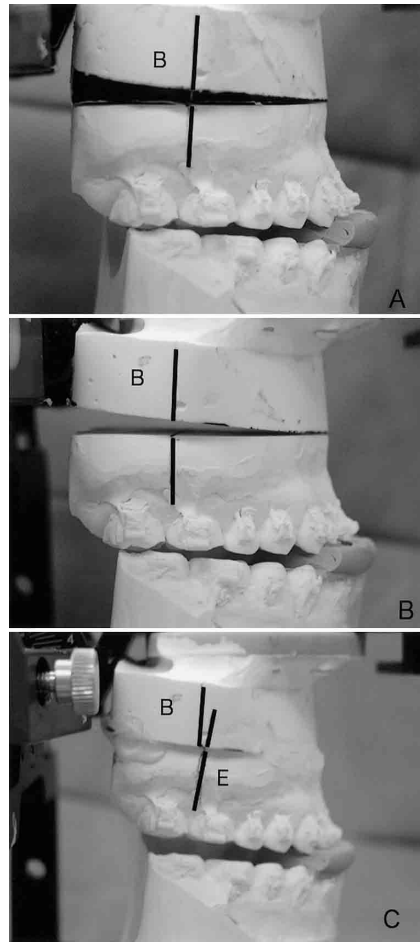


Fig. 8 Occlusal alteration

Posterior part of maxillary model is moved upwards to bring model base into close contact with mounting base by using OA bite. At same time, maxillary front teeth of OA bite serve as center of rotation. Amount of movement is computer-calculated movement distance of first maxillary molars.

(i.e., the center of rotation) for when the maxillary molars were raised upward (Fig. 8A~C). Since the maxillary incisors served as the center of rotation in this, the position of the ANS protruded forward. Baselines B and C moved forward in a similar manner as a result of the rotational movement. While this was being done, the position through which the baselines of the maxillary molar parts on the base of the model moved (i.e., baselines E and F) were recorded on the base of the

mounting cast. In this condition, the position of the maxillary incisors showed no change in the anterior-posterior or left-right directions (Fig. 9A~D). When there was not only movement in the perpendicular direction but also movement in the anterior-posterior direction, in other words, when anterior-posterior movement was required at the incisor tip position, the maxillary model had to be moved in the forward direction. This movement must be done keeping the separate faces of the canted

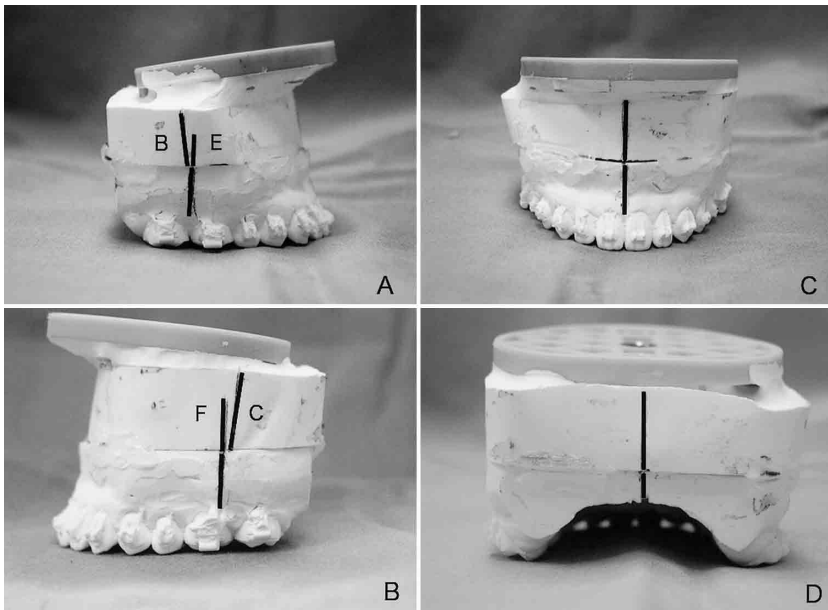


Fig. 9 Baseline after occlusal alteration

Lines E and F are recorded on mounting base when lines B and C moved after occlusal alteration. In this condition, position of maxillary incisors does not change in anterior-posterior or left-right directions.

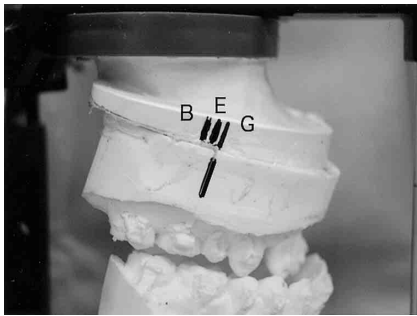


Fig. 10 Technique for movement in anterior-posterior direction I

Line G (and H) is position determined by measuring the amount of anterior-posterior movement from baseline E (and F). This distance was determined by computed simulation.

base of the mounting cast and the separate faces of the maxillary model in contact. To ensure accurate anterior-posterior movement, the movement distance estimated from baselines E and F was measured and the position recorded (lines G and H) before movement (Fig. 10). Next, the baseline on the base

of the model's molar part was moved to this position. In order to prevent movement to the left or right, it was necessary here to check that the baseline on the base of the model in the median at the front teeth was in register with the baseline on the base of the mounting cast. After movement, the arrangement was provisionally fixed, and the OA bite was used again for a final check. The amount of movement estimated from the position of the incised mark of the maxillary incisor tip was then inscribed as a line on the top surface of the OA bite. Next, the maxillo-mandibular model was made to bite on the OA bite intervened. Accurate movement was achieved by checking that the line marked off on the OA bite matched the central incisor tip of the maxillary model (Fig. 11A~C). After the model was moved to the appropriate position, the model was then fixed on the base of the mounting cast. Instantaneous adhesive and/or wax were used for fixing.

After movement of the maxillary model, a first (intermediate) splint was made. Follow-

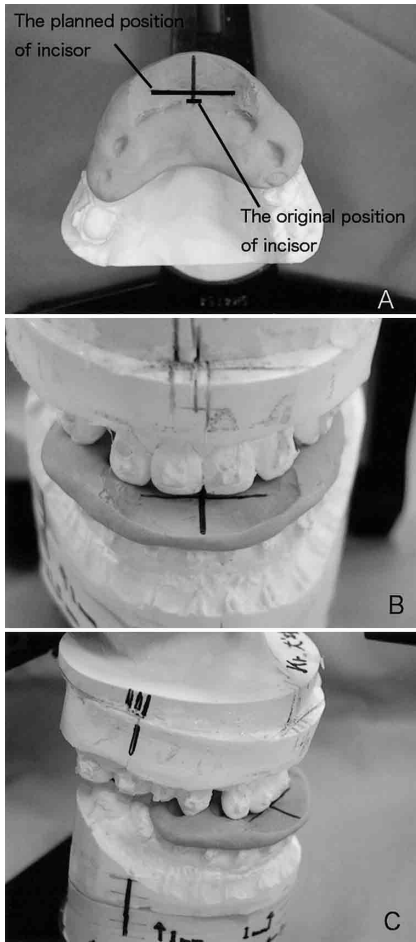


Fig. 11 Technique for movement in anterior-posterior direction 2

- A: Amount of movement from upper incisor tip to planned position is recorded on OA bite. When we decided the planned position line, the vertical line at the midline of upper incisor was used.
- B, C: To check accuracy of movement, we must check line marked off on OA bite matches upper incisor edge of maxillary model already moved in anterior-posterior direction.

ing this, the mandibular model was moved and fixed in the position previously determined by the orthodontist as the position providing stable occlusion with the maxillary model. When we received the maxillary and mandibular models from the orthodontist we had the orthodontist mark off the final occlusion position from the lingual side of the maxillo-mandibular model with the bite of

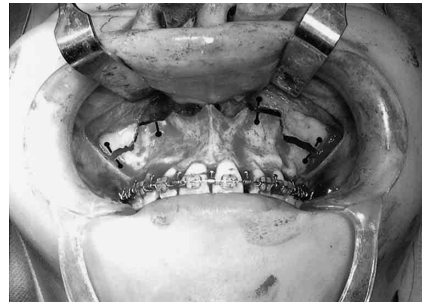


Fig. 12 Surgical technique

Perpendicular line is drawn across osteotomy line at left-right maxillary first molar parts and the margin of left and right piriform openings intraoperatively. We used these lines to accurately measure amounts of vertical and horizontal movement of maxilla. Furthermore, more accurate surgery is not possible with stepping osteotomy.

EXAFINE PUTTY TYPE®. After movement of the mandibular model, the second (final) splint was made.

5) Surgical procedure

Amount of movement was ultimately determined and the prepared bite splint was used to perform actual surgical procedure based on the model operation method described above. In addition, a perpendicular line was drawn intraoperatively across the osteotomy line with respect to the left-right maxillary first molar parts; also, perpendicular lines were drawn in the same manner on the margin of the left and right piriform openings. The length of these perpendicular lines was measured before separation, and with this the amounts of vertical and horizontal movement of maxilla were measured. Certain devices such as the provision of steps in the design of the separating line may also be useful to some extent in permitting accurate measurement of the amount of movement during an operation. This would make the transition from analysis to model operation and from there to actual surgery more accurate, leading to more satisfactory postoperative results (Fig. 12).

Results

The use of an OA bite permitted accurate

modeling of the operation as the direction and amount of movement could be transposed from the preoperative computer simulation to model surgery. By using the bite splint prepared from this during actual surgery, it was possible to reproduce a movement plan in an accurate manner. As a result, it was possible to achieve not only satisfactory functional occlusion but also an esthetically favorable outcome. Alteration in occlusal plane by rotation of the maxillo-mandibular complex caused the point of the chin to move backward and downward in relation to the lower incisor tips. Therefore, the postoperative profile view revealed the establishment of a better harmony between the chin, lips, cheeks and nose than in the case of operation on the mandible alone. The results have revealed stable in all patients more than 12 months following surgery.

Discussion

Surgery to correct deformities of the jaw begins with diagnostic procedure, which involves performing cephalometric and soft tissue analysis. After establishing a plan of surgery and after pre-surgical orthodontic correction, surgery is performed. For successful orthognathic correction to be achieved, operative accuracy is critical in the course of the above procedure. This procedure involves simulation of movement based on the analysis of cephalometric radiographs. Although such simulations will determine the amount of movement required, the accuracy of the movement by the estimated amount will depend, to a large extent, on the experience of the surgeon in taking measurements during the actual operation^{2,6)}. This often presents significant difficulties. For this reason, it is important to conduct a model operation prior to actual surgery. Errors in model operations will have a direct effect on surgical outcome, and therefore it is important to ensure the greatest possible accuracy in model surgery when making an actual splint. There are various approaches to model surgery such as the

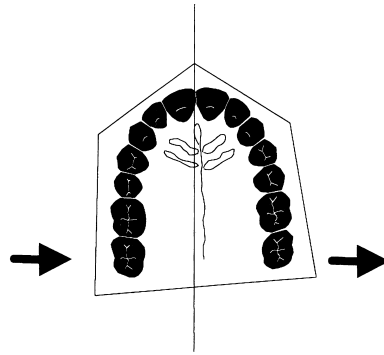


Fig. 13 Horizontal rotation of maxilla
Rotation to one side or other of posterior maxilla can easily occur, while maxillary dental midlines are coincident with facial midline.

inscription of baselines by suitably devised methods. Most new methods, however, are substantially the same as the classic methods, and when a model operation is performed by a classic method, there is the possibility of errors occurring in various areas. The areas most prone to error are the perpendicular position and horizontal position of the maxillary molar part. Perhaps the most common inaccuracy in performing maxillary model surgery in the cases of bimaxillary surgery is in the mediolateral positioning of the posterior maxilla. The perpendicular positioning of the maxilla is made difficult by the action of gravity. The horizontal positioning of the maxillary molar part presents difficulties, in that horizontal rotation toward the center can easily occur, even when the median of the maxilla is aligned³⁾ (Fig. 13). If the maxilla is skewed to one side to correct the posterior area and occlusion, the mandible will also be skewed in the same direction. This is the most important factor in a model operation. Therefore, in order to achieve greater accuracy in the perpendicular and horizontal positioning of the maxillary molar part, we have made some modifications to the classic model operation method. By inscribing the front teeth on the bite, it is possible to obtain perpendicular movement of the maxillary molars, rotating the maxilla with the edges of the upper incisors as the pivotal center, and

without that center itself undergoing any shift in position. In this manner it is also possible to prevent displacement in the horizontal direction. Even when it is necessary to move the front dentition in the anterior-posterior direction, precision can be achieved by checking against the baseline at the center of the front teeth using the marking on the OA bite.

On the posterior-anterior cephalometric radiograph, the occlusal plane connecting the first molars on the left and right of the maxilla was skewed, and our method can also be used for patients with this kind of maxillary asymmetry. This type of deformity arises from the perpendicular positions of the molar parts on either side of the maxilla being different. In such cases it is necessary to move the molar parts upwards, and the first step in achieving this is to correct the perpendicular positioning of the maxillary molar parts on both sides. In this manner, the upward or downward movement of the molar part on one side brings it in alignment with the height of the molar part on the opposite side. This must be accomplished in such a manner that the other parts will not move in the anterior-posterior or horizontal directions and that the ANS will not move in the perpendicular direction. Provisional fixation is made when the skew of the maxillary occlusal plane appears to be improved in the frontal view of the face. In our method, after improving maxillary asymmetry, the upper incisors are inscribed in the OA bite (Fig. 14A~C). Then, the OA bite is used to achieve upward movement of the maxillary molar parts and, if necessary, anterior-posterior movement also. Since the molars on one side have been moved perpendicularly in order to correct the asymmetry of the maxilla, however, it is necessary to subtract this amount of movement from the upward movement of the maxillary molar parts, and this will be planned for on the basis of the analysis.

To ensure accuracy in actual surgery, precise modeling of operations is vital. Such modeling can address the difficulties that arise from the three-dimensional positioning that is required by actual surgery. However,

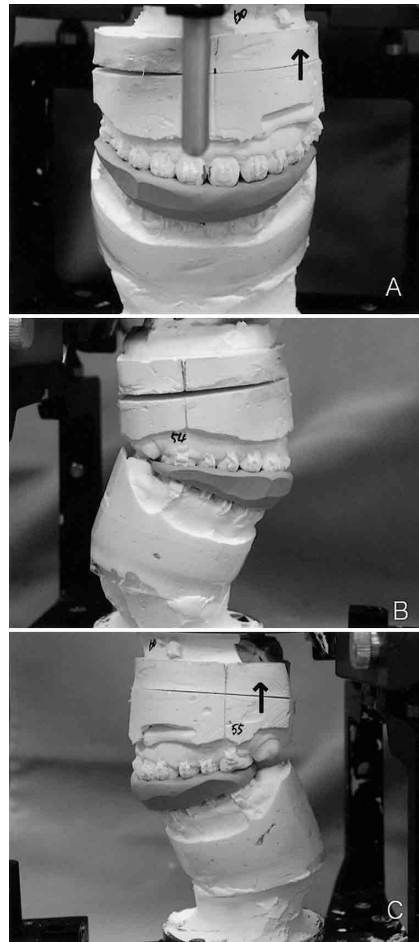


Fig. 14 Technique in case of maxillary asymmetry Upward or downward movement of molar part on one side brings it in alignment with height of molar part on opposite side. After maxillary asymmetry is improved, edges of upper incisors are inscribed in OA bite.

inaccuracies in modeling can lead to inaccurate maxillary-mandibular positioning. This is because of the complexity of modeling and the impossibility of accurately translating measurements derived from cephalometric images. It is, therefore, important to be able to simply and accurately translate the movements and positioning of the maxillary model into actual orthognathic surgery. In this study, we simulated movement using a computer. By making an OA bite on the model derived from this movement, and by using that OA bite, we were able to transpose the perpen-

dicular movement of the maxillary molar parts in a simple and accurate manner to achieve accurate positioning. This allowed surgery to be performed in an easy and accurate manner, making it possible to obtain favorable results. The proposed method uses cephalometric radiographs and the transposition of simulated two-dimensional movement in the modeling of operations. In the future, use of advanced diagnostic techniques such as CT will provide three-dimensional simulation data that can be transposed to model operations in order to achieve even greater accuracy.

References

- 1) Akimoto Y, Noma Y, Takaki T (2000) A study of relationship between the occlusal plane and the dens of the axis, by lateral cephalography, regarding individual-normal-occlusion persons and patients with jaw deformity. *Japanese Journal of Jaw Deformity* 10:80–98.
- 2) David AC, Larry MW (1994) Altered orthognathic surgical a modified approach to model surgery. *J Oral Maxillofac Surg* 52:1010–1020.
- 3) Edward E III (1990) Accuracy of model surgery: Evaluation of an old technique and introduction of a new one. *J Oral Maxillofac Surg* 48:1161–1167.
- 4) Johan PR, William GE (1990) Surgical manipulation of the occlusal plane. *The International Journal of Adult Orthodontics and Orthognathic Surgery* 5:99–110.
- 5) Larry MW, Peter DC, Frank H (1994) Occlusal plane alteration in orthognathic surgery—part I: Effect on function and esthetics. *American Journal of Orthodontics and Dentofacial Orthopedics* 106:304–316.
- 6) Mohammad A, Malcolm H (1990) Model surgery for orthognathic planning. *Br J Oral Maxillofac Surg* 28:393–397.
- 7) Motohashi K, Kameda A, Kondo E (1972) Some elementary facts to be considered in studying of posteroanterior cephalogram. *Journal of Japan Orthodontic Society* 31: 105–116.
- 8) Peter DC, Larry MW, Peter HB (1994) Occlusal plane alteration in orthognathic surgery—part II: Long-term stability of results. *Am J Orthod Dentofacial Orthop* 106:434–440.
- 9) Ricketts RM, Bench RW, Hilgers JJ, Schulhof R (1972) An overview of computerized cephalometrics. *Am J Orthod* 61:1– 28.
- 10) Sassouni V (1955) A roentgenographic cephalometric analysis of cephalo-faciocental relationships. *Am J Orthod* 41:735–764.

Reprint requests to:

Dr. Akira Yosano
Department of Oral and
Maxillofacial Surgery,
Tokyo Dental College,
1-2-2 Masago, Mihama-ku,
Chiba 261-8502, Japan
E-mail: yosano@tdc.ac.jp