

Title	Reliability of linear distance measurement for dental implant length with standardized periapical radiographs
Author(s)	Wakoh, M; Harada, T; Otonari, T; Otonari-Yamamoto, M; Ohkubo, M; Kousuge, Y; Kobayashi, N; Mizuta, S; Kitagawa, H; Sano, T
Journal	Bulletin of Tokyo Dental College, 47(3): 105-115
URL	http://hdl.handle.net/10130/225
Right	

Original Article

Reliability of Linear Distance Measurement for Dental Implant Length with Standardized Periapical Radiographs

Mamoru Wakoh, Takuya Harada, Takamichi Otonari, Mika Otonari-Yamamoto, Mai Ohkubo, Yuji Kousuge*, Norio Kobayashi*, Shigeru Mizuta, Hiromi Kitagawa*** and Tsukasa Sano**

*Department of Oral and Maxillofacial Radiology, Tokyo Dental College,
1-2-2 Masago, Mihama-ku, Chiba 261-8502, Japan*

** Department of Radiology, Tokyo Dental College, Chiba Hospital,
1-2-2 Masago, Mihama-ku, Chiba 261-8502, Japan*

*** Apple Dental Clinic,
2568-6 Anegasaki, Ichihara 299-0111, Japan*

**** Yakuendai Station Dental Clinic,
6-1-1-2E Yakuendai, Funabashi 274-0077, Japan*

Received 2 August, 2006/Accepted for publication 15 September, 2006

Abstract

The purpose of this study was to investigate the accuracy of distance measurements of implant length based on periapical radiographs compared with that of other modalities. We carried out an experimental trial to compare precision in distance measurement. Dental implant fixtures were buried in the canine and first molar regions. These were then subjected to periapical (PE) radiography, panoramic (PA) radiography, conventional (CV) and medical computed (CT) tomography. The length of the implant fixture on each film was measured by nine observers and degree of precision was statistically analyzed. The precision of both PE radiographs and CT tomograms was closest at the highest level. Standardized PE radiography, in particular, was superior to CT tomography in the first molar region. This suggests that standardized PE radiographs should be utilized as a reliable modality for longitudinal and linear distance measurement, depending on implant length at local implantation site.

Key words: Dental implant length—Radiography—Measurement accuracy—Mandible

Introduction

Radiographs are an important tool for assessment of bone architecture. Radiographs are used to evaluate bone support at the recipient site of a dental implant at each

of the three phases of implant treatment, evaluation, and maintenance. The first phase consists of pre-surgical assessment of bone amount at potential implant recipient sites during treatment planning. The second phase comprises pre- and intra-surgical assessment

of surrounding anatomical structures, which mainly include distance from alveolar crest to mandibular canal and mental foramen in mandible, and to the floor of the maxillary sinus, nasal cavity and the incisal canal in the maxilla^{3,13,14}. This measurement value is useful in selecting and estimating the length of implant fixtures. The final use of radiographs is in longitudinal assessment of bone loss, which is a characteristic of the success or failure of implant therapy. Unfortunately, no technique truly satisfies the ideal goal of supporting all assessments at each phase⁷. In an attempt to achieve such an ideal radiographic assessment, a clinician often combines multiple radiographic techniques. Beason *et al.*⁴ researched the types of radiographic modalities used for pre-operative implant site assessment, and the results showed that more than 95% of dentists took panoramic (PA) radiographs. Sakakura *et al.*²¹ also reported that over approximately 80% of dentists took PA radiographs, either as a single examination or in combination with periapical (PE) radiographs. Their results showed that only about 10% preferred the combination of computed (CT) or conventional (CV) tomography with other types of radiographic methods.

When pre- and intra-surgical assessment for dental implant performance is focused on the linear measurement of distance in bone, routine PA radiographs^{14,20,24}, cross-sectional radiographs reconstructed from routine PA radiographic data¹⁸, and CV^{9,14,25} or CT tomographs^{5,9,17,20,25} including reformatted cross-sectional images as the occasion arises have been used. Most previous research has compared precision of measurement, mainly involving the distance from the alveolar crest to adjacent anatomical structures, among these various modalities, together with cross-sectional images in which the information acquisition of not only mesio-distal but also bucco-lingual and superior-inferior direction of the jaw bone is possible. Few studies have evaluated precision on PE radiographs compared with that on other radiographs. It may be because cross-sectional images are not available for PE radiographs. Additionally,

periapical radiographs have the limitation that adjacent anatomical structures, such as mandibular canal and the floor of maxillary sinus, may not be visible on a film due to the smallness of the area involved. Meanwhile, for longitudinal assessment of bone loss after implantation, measurement is based on the implant length. The length of the natural tooth root is unknown, whereas the implant length is known before implantation. If the bone height relative to the implant fixture after implantation is expressed as a percentage of the implant length, it may be easily converted into a millimeter measurement of the bone loss present as the longitudinal assessment. In other words, the implant fixture itself acts as its own ruler to compensate for linear measurement of bone loss. Although digital subtraction technique^{8,11,12,27,28} with PE radiographs has recently become widely used for bone loss assessment, and most dentists in private clinics routinely use PE radiographs for implant site assessment, no studies have reported the accuracy of linear measurement of implant length based on PE radiographs compared with that on other radiographs.

The purpose of this paper is to compare precision of measurement of implant length among the current radiographic modalities used for implant performance, and to consequently demonstrate the reliability of PE radiographs for lateral and linear measurement of implant length.

Materials and Methods

A dried skull was prepared for the placing of dental implants in the mandible of which images using each imaging modality were to be taken. We used two dental implant fixtures: ultrathin-Hydroxyapatite (HA)-coated implants made by the thermal decomposition method (Platon Implant Japan, Tokyo), respectively measuring 17.37 mm and 13.56 mm in actual length. The former and the latter were respectively buried at the canine and the first molar tooth region in the right mandible (Fig. 1). They were then exposed to each

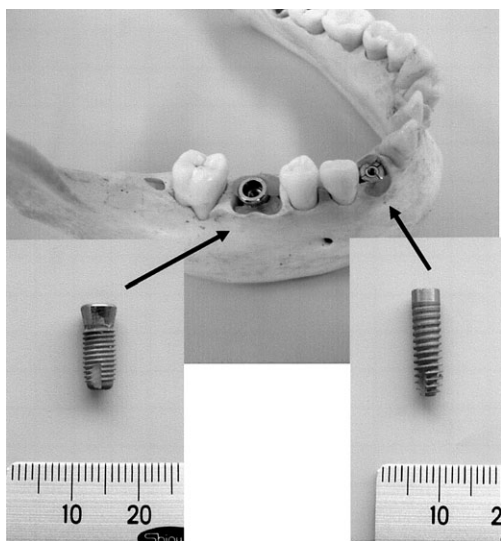


Fig. 1 Objects used to obtain sample images with each imaging modality

imaging modality, including PE and PA radiography, CV and medical CT tomography. In PE radiography, paralleling technique was used with the XCP instrument (Rinn, Elgin, USA) in order to maintain correct positioning of the dental film (Fig. 2A). The Xspot-TW (Asahi Roentgen, Kyoto, Japan) was used as the dental x-ray apparatus. The Veraviewepocs (Morita Corp., Kyoto, Japan) was used in PA radiography. The Frankfort plane (FP) or the occlusal plane (OP) of the dry skull were positioned parallel to a laser light beam, which was set to flow parallel to the floor. The laser was provided as part of the apparatus itself. Images were then taken in each of these positions (Fig. 2B). For CV tomography, an OPTIPLANIMAT unit (Siemens) was used. To obtain precise tomographic images of the implant fixture, the direction of the laser light beam was made aligned with the long axis of the implant fixture on each region (Fig. 2C). For medical CT tomography, SOMATOM Plus4 (Siemens) was used. First, the dried skull was fixed in the standard position using a head fixing bracket, positioning the occlusal plane perpendicular to the floor, after which, axial images were obtained. Successive cross-sectional images (CS1) of each region were

respectively reconstructed using the dental-CT software program, referring to the axial CT tomographic image obtained (Fig. 2D-a). Furthermore, another cross-sectional image (CS2) aligned with the long axis of the implant fixture in each region, taking into account the direction of the implantation of the implant fixture, was respectively reconstructed together with a parasagittal image (Fig. 2D-b).

Length of implant fixture was individually measured on each film by nine observers who were oral and maxillofacial radiologists. Each observer measured each film 3 times. The results were expressed as a mean rating \pm s.d. for each modality group, and subjected to the Kruskal-Wallis and Scheffe's multiple comparison non-parametric test. Additionally, intra- and inter-observer reproducibility was also calculated for each modality group using a one-way factorial ANOVA. A value of $p < 0.05$ was regarded as significant. The software for the statistical analysis was StatView J 4.02 (Brain Power Inc., Agoura Hills, USA).

Results

Figures 3A and 3B respectively show the mean rating ($R \pm$ s.d.) for measurement of implant fixture on each image in the canine and molar regions. The Kruskal-Wallis test showed that there was a significant difference between the mean ratings for each regional group (canine region, $p < 0.0001$; molar region, $p < 0.0001$). This significant difference in measurement accuracy among the various imaging modalities in each group was further clarified with the Scheffe's multiple comparison test. The statistical result is shown in Table 1. In the canine region, this test showed no significant difference between PE radiograph and CT tomogram as CT-CS1 ($p = 0.1847$) or CT-CS2 ($p = 0.1175$). In the molar region, this test showed no significant difference between PA radiographs positioned based on FP and OP ($p = 0.8010$), or between CT-CS1 and CT-CS2 images. Figures 4 and 5 respectively show the mean rating ($R \pm$ s.d.) of measurement

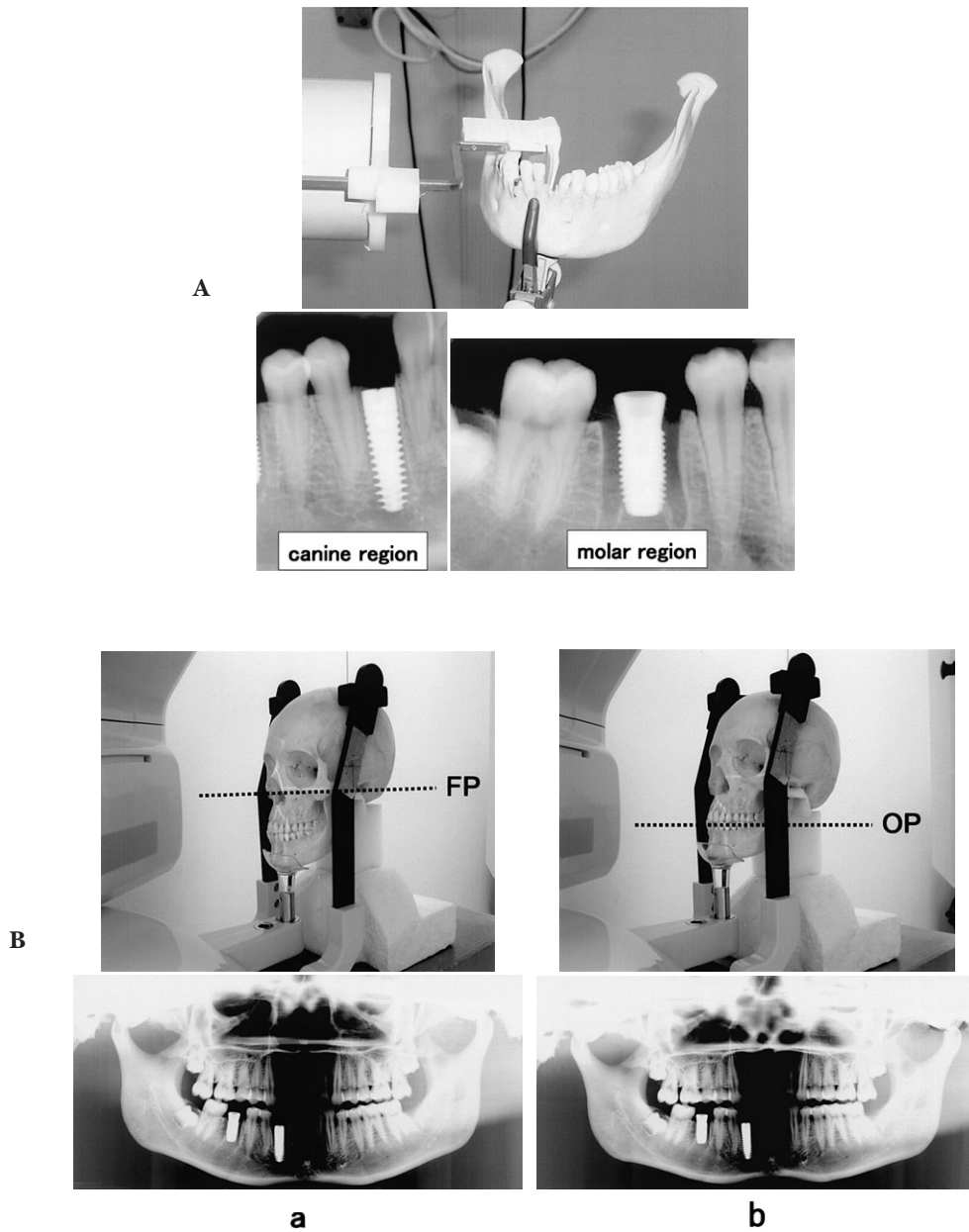


Fig. 2

by each observer group for each modality in the canine and molar regions. Table 2 shows the results for variance of measurement data between inter- and intra-observer for each modality, which were expressed as a mean square. In each modality group, variance for intra-observer was smaller than that for inter-

observer, except with PE radiographs. *F*-value was also extremely small for PE radiographs.

Discussion

A vast amount of radiographic imaging

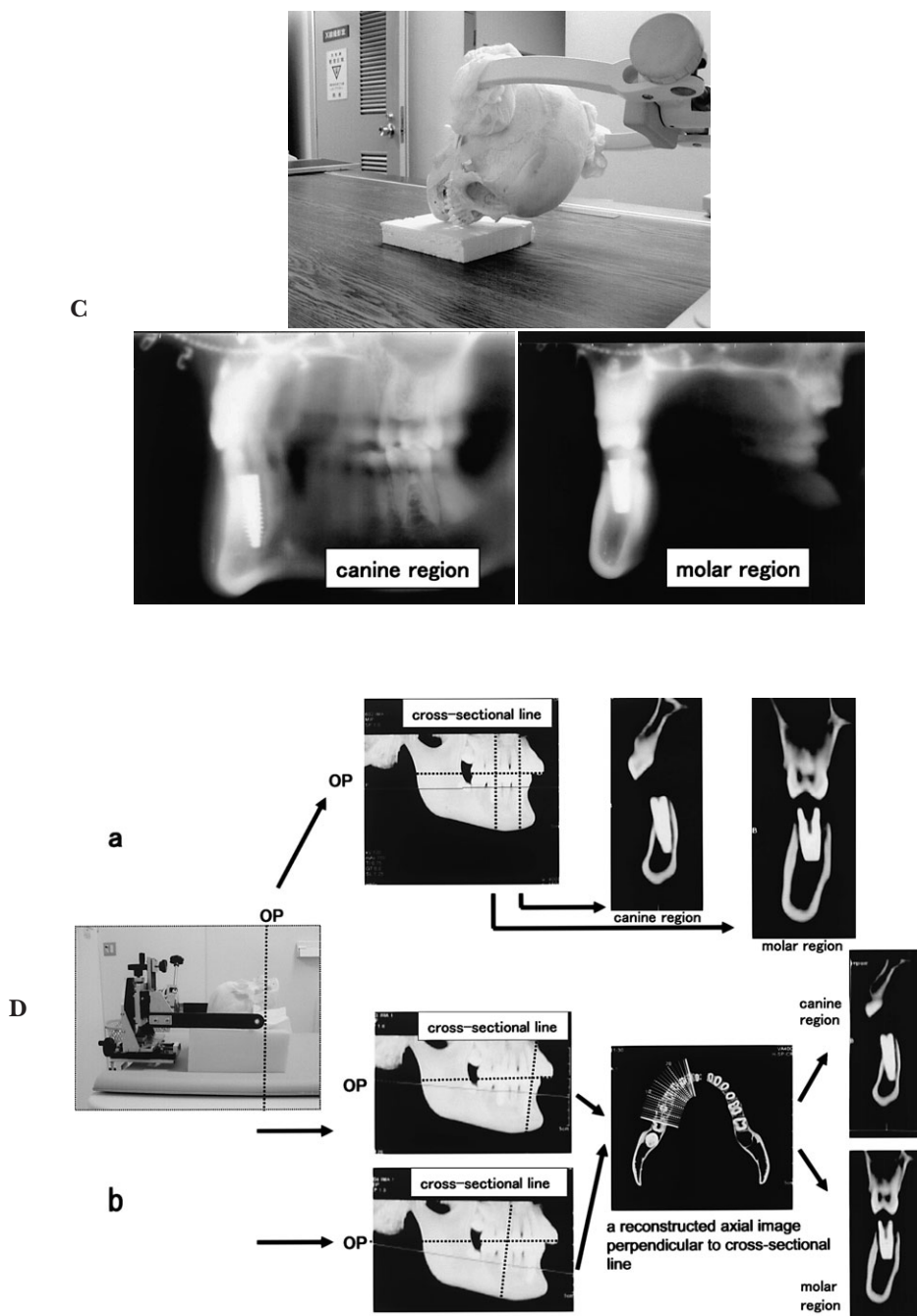


Fig. 2 Positioned landscapes of dried skull, and radiographs (inclusive of exposure process in CT) obtained for measuring in each modality
 A: PE, B: (a) PA-FP, (b) PA-OP, C: CV, D: (a) CT-CS1, (b) CT-CS2

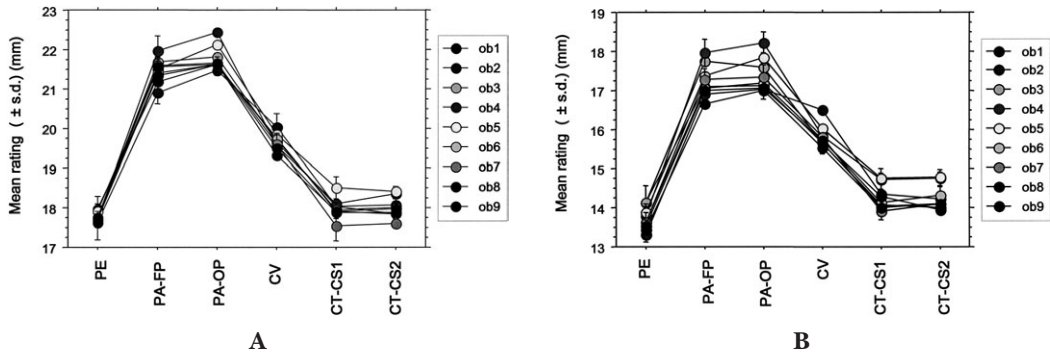


Fig. 3 Comparing measuring distance of implant fixture among imaging modality groups in canine (A) and molar (B) regions

Table 1 p-values obtained with Scheffe's multiple comparison test for each imaging modality

		PA-FP	PA-OP	CV	CT-CS1	CT-CS2
Canine	PE	<0.0001	<0.0001	<0.0001	0.1847	0.1175
	PA-FP	—	0.0053	<0.0001	<0.0001	<0.0001
	PA-OP	—	—	<0.0001	<0.0001	<0.0001
	CV	—	—	—	<0.0001	<0.0001
	CT-CS1	—	—	—	—	>0.9999
Molar	PE	<0.0001	<0.0001	<0.0001	<0.0001	<0.0001
	PA-FP	—	0.801	<0.0001	<0.0001	<0.0001
	PA-OP	—	—	<0.0001	<0.0001	<0.0001
	CV	—	—	—	<0.0001	<0.0001
	CT-CS1	—	—	—	—	>0.9999

In canine region, there were no significant differences between periapical radiography and CT, or between CT-CS1 and CT-CS2. In molar region, periapical radiography indicated significant differences for other imaging modalities.

associated with dental implants is used for diagnosis of the recipient site. Ideally, this will allow assessment in terms of quality and amount of bone, location of anatomical structures, and longitudinal morphological change through bone loss along the implant surface. Digital subtraction radiography was introduced into the field of periodontal research in the 1980s as one of the most versatile approaches to assessment of longitudinal bone change^{8,10,11,28}. Jeffcoat *et al.*¹² used a reference wedge calibrated to different thicknesses, which was incorporated into the periapical radiograph. The image of the wedge obtained was used to determine thickness of

wedge, which corresponded to the same gray level change as the bone loss area. Historically, there is another approach to the assessment of longitudinal bone change: that is, different criteria have been utilized to assess the success of implants based on radiographic appearance or measurement of distance. Schnitman and Shulman²² recommended that bone loss was not greater than 1/3 of the implant length. Albrektsson *et al.*¹ and Smith and Zarb²³ established a success criterion of 0.2mm of bone loss annually after the first year of implantation. Furthermore, the American Dental Association² established a radiographic criterion of 2mm of vertical bone loss at 5

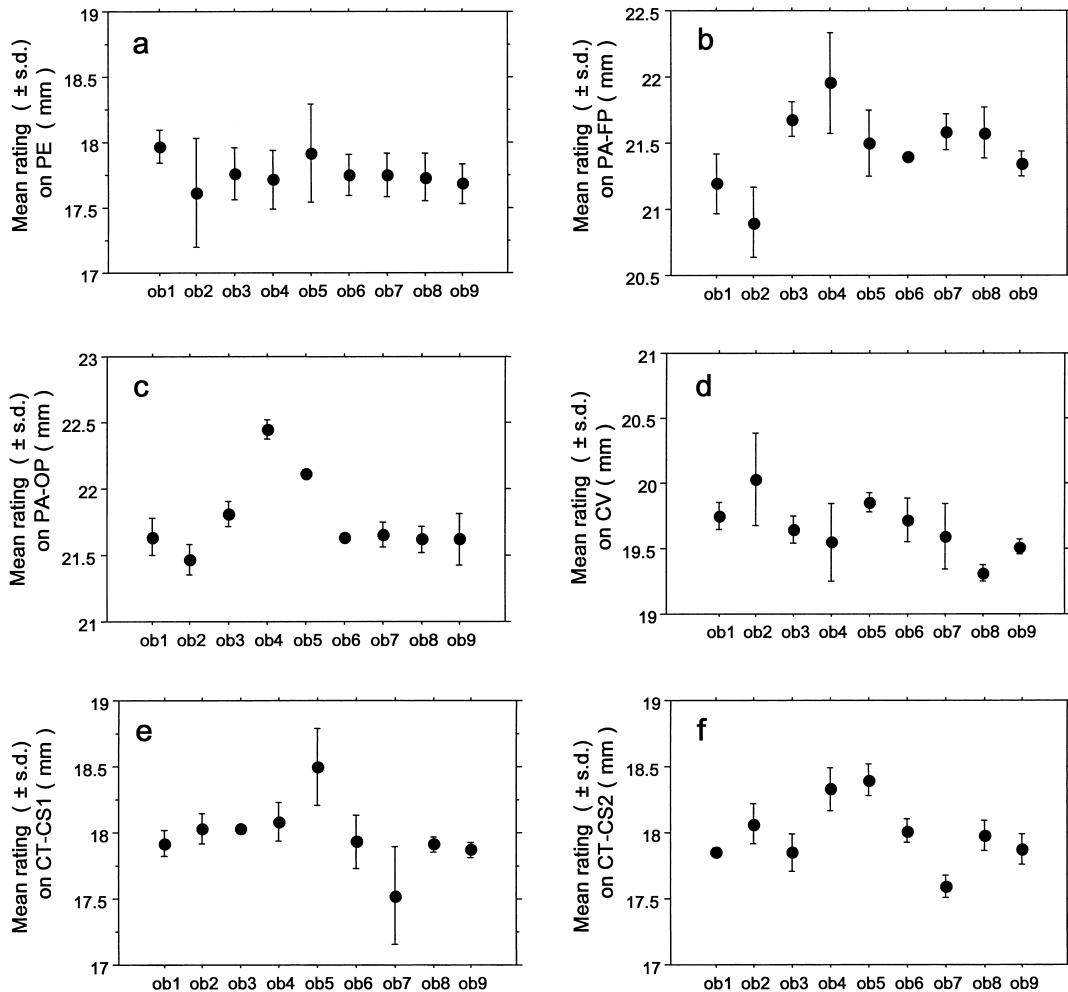


Fig. 4 Variance of measuring distance of implant fixture by each observer in canine region
 a: PE, b: PA-FP, c: PA-OP, d: CV, e: CT-CS1, f: CT-CS2

years. To use these criteria for the radiographic analysis of longitudinal implant bone loss in clinical trials, first it is necessary to obtain precise measurement of implant length itself prior to implantation if it is to be used effectively as an index of bone loss. However, these earlier studies did not specify the radiographic method to be used for actual measurement of bone loss, and they did not research the measurement precision of implant length in each radiographic modality. Therefore, this study focused on this point.

PE radiographs are utilized in pre-surgical

planning of implant treatment, intra-operatively, and for longitudinal assessment, especially for assessment of limited areas or individual implant sites. Adjacent anatomical structures may not be visible on the radiograph due to the limitation of the areas, while PE radiographs have minimal distortion when they are well-angulated applying the standardized projection geometry previously described by Duckworth *et al.*⁶⁾ Additionally, exposure dose of PE radiography is extremely low compared with that of other modalities. Therefore, PE radiographs are particularly well-suited for

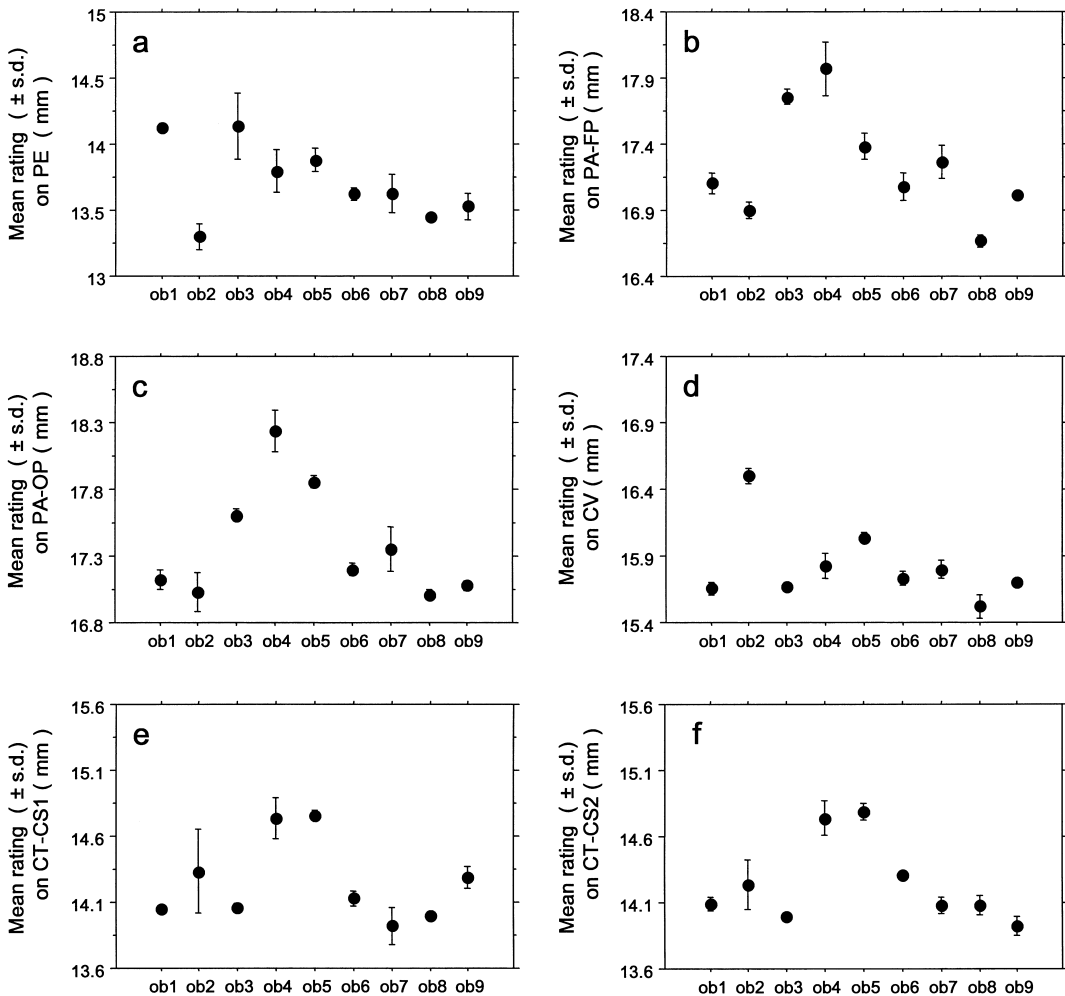


Fig. 5 Variance of measuring distance of implant fixture by each observer in molar region
a: PE, b: PA-FP, c: PA-OP, d: CV, e: CT-CS1, f: CT-CS2

longitudinal assessment of implant bone loss rather than for the planning of surgical procedure. The results of this study demonstrated that the measured distance on the PE radiograph was the closest to the actual length of the implant fixture without regard to implantation site, and measurement accuracy radiograph was almost the same as, or better than, that of CT-CS image. Inter-observer variance in the PE radiographs was smaller in both regions compared with that of other modalities. Although CT tomograms are commonly recommended for measurements²⁶⁾,

the inter-observer variance in the PE radiographs was smaller than that of the CT tomograms, especially, in the canine region. This suggests that the measurement value on PE radiographs is the most reliable, regardless of observers. This is probably due to the sharpness and resolution of images obtained with standardized PE radiography. Furthermore, the standardized PE radiograph probably provides the highest reliability and reproducibility in terms of linear measuring distance between the alveolar ridge and other anatomical structures in pre-surgical assess-

Table 2 Variance of measurement data between intra- and inter-observer for each imaging modality

Cases	Modalities	Mean square (Intra-observer)	Mean square (Inter-observer)	F-value	p-value
Canine	PE	0.059	0.037	0.63	0.7426
	PA-FP	0.045	0.271	5.999	0.0008
	PA-OP	0.012	0.286	24.509	<0.0001
	CV	0.037	0.131	3.54	0.0123
	CT-CS1	0.035	0.194	5.523	0.0013
	CT-CS2	0.014	0.187	13.202	<0.0001
Molar	PE	0.047	0.252	5.39	0.0015
	PA-FP	0.031	0.51	16.608	<0.0001
	PA-OP	0.03	0.545	18.463	<0.0001
	CV	0.01	0.251	24.325	<0.0001
	CT-CS1	0.053	0.289	5.395	0.0015
	CT-CS2	0.024	0.294	12.399	<0.0001

Variance of measurement data is indicated as mean square. Variance in inter-observer for periapical radiographs was smaller than that for other radiographic images.

ment, where anatomical structure is described on radiographs.

PA radiographs provide a global evaluation for multiple implant emplacement. The large area imaged with this technique is useful in the initial planning of treatment or screening, including for assessment of bone loss. However, this method has a number of limitations compared with PE radiography: lack of clarity due tomography, inconsistent magnification at each region, decreased resolution and lack of standardization of projection geometry. In this analysis also, PA radiographs showed the greatest measurement deviation to the actual length of implant fixture, and showed an extremely significant difference compared with PE radiographs. These disadvantages mean there is a risk of loss of measuring precision.

It has been suggested that cross-sectional views obtained using CV tomography are an effective technique for evaluation of bone width and bone height from one image of a prospective implant site¹⁵. In terms of measurement of distance, complicated manipulation is required to estimate the actual distance of the structure; and the measured distance on the film has to be converted using a conver-

sion chart. This technique also has limitations: availability of the machines themselves; the skill required to obtain reproducible images, which have to be tomographic images in the same plane as the axis of the implant fixture; image blurring caused by tomographic principle; and the popularization of CT tomography. In this study, measurement accuracy of implant length in CV tomograms using a conversion chart was higher than that for PA radiographs, but was obviously inferior to that for PE radiographs. Nowadays, CV tomograms also should not be utilized in longitudinal and precise measurement at local implantation sites, as well as PA radiographs.

Many authors believed that CT images were the most accurate technique for implantation site diagnosis for pre-surgical assessment^{9,16,19,20}. The American Academy of Oral and Maxillofacial Radiology (AAOMR)²⁶ also recommended CT tomography for implant site assessment, including precise measurement of distances in three dimensions. Our study also demonstrated that CT-CS images offered high accuracy in measuring distance of implant length. However, the measured value was similar or inferior to those obtained in PE radiographs, which was unexpected.

Medical CT is also not suitable for longitudinal bone loss assessment depending on implant length at local implantation sites because of the low spatial resolution and high exposure dose.

In conclusion, standardized PE radiographs should be utilized for longitudinal measurement depending on implant length at local sites, due to the highest linear measurement precision with dose limitation available.

References

- 1) Albrektsson T, Zarb G, Worthington P, Eriksson B (1986) Long-term efficacy of currently used dental implants: a review and proposed criteria of success. *Int J Oral Maxillofac Implants* 1: 11–25.
- 2) American Dental Association (1996) Dental endosseous implants; an update. ADA Council on Scientific Affairs. *J Am Dent Assoc* 127: 1238–1239.
- 3) Arcuri MR, Lang BR (1994) Diagnostics and treatment planning, *Osseointegration in Dentistry*, Worthington P, Lang BR, LaVelle WE eds., pp. 69–83, Quintessence, Chicago.
- 4) Beason RC, Brooks SL (2001) Preoperative implant site assessment in southeast Michigan. *J Dent Res* 80:137 (Abstr. 810).
- 5) Cavalcanti MG, Yang J, Ruprecht A, Vannier MW (1999) Accurate linear measurements in the anterior maxilla using orthoradially reformatted spiral computed tomography. *Dentomaxillofac Radiol* 28:137–140.
- 6) Duckworth JE, Judy PF, Goodson JM, Socransky SS (1983) A method for geometric and densitometric standardization of intraoral radiographs. *J Periodontol* 54:435–440.
- 7) Fritz ME (1996) Implant therapy II. *Ann Periodontol* 1:796–815.
- 8) Grondahl H-G, Grondahl K, Webber RL (1983) A digital subtraction technique for dental radiography. *Oral Surg* 1:96–102.
- 9) Hanazawa T, Sano T, Seki K, Okano T (2004) Radiologic measurements of the mandible: a comparison between CT-reformatted and conventional tomographic images. *Clin Oral Impl Res* 15:226–232.
- 10) Hausmann E, Christersson L, Dunford R, Wikesjo U, Phylo J, Genco RJ (1985) Usefulness of subtraction radiography in the evaluation of periodontal therapy. *J Periodontol* 56 (Suppl):4–7.
- 11) Jeffcoat MK, Reddy MS, Webber RL, Williams RC, Ruttimann UE (1987) Extraoral control of geometry for digital subtraction radiography. *J Periodont Res* 22:396–402.
- 12) Jeffcoat MK, Reddy MS, van den Berg HR, Bertens E (1992) Quantitative digital subtraction radiography for the assessment of peri-implant bone change. *Clin Oral Impl Res* 3: 22–27.
- 13) Lekholm U, Zarb GA (1985) Patient selection and preparation, *Tissue-Integrated Prostheses: Osseointegration in Clinical Dentistry*, Branemark P-I, Zarb GA, Albrektsson T eds., pp. 199–209, Quintessence, Chicago.
- 14) Lindh C, Peterson A (1989) Radiologic examination for location of the mandibular canal: a comparison between panoramic radiography and conventional tomography. *Int J Oral Maxillofac Implants* 4:249–253.
- 15) Miles DA, van Dis ML (1993) Implant radiology. *Dent Clin North Am* 37:645–668.
- 16) Miller C, Nummikoski PV, Barnett D (1990) Cross-sectional tomography. *Oral Surg Oral Med Oral Pathol* 70:791–797.
- 17) Naitoh M, Katsumata A, Nohara E, Ohsaki C, Arijji E (2004) Measurement accuracy of reconstructed 2-D images obtained by multislice helical computed tomography. *Clin Oral Impl Res* 15:570–574.
- 18) Peltola JS, Mattilla M (2004) Cross-sectional tomograms obtained with four panoramic radiographic units in the assessment of implant site measurements. *Dentomaxillofac Radiol* 33:295–300.
- 19) Petrikowski C, Pharoah M, Schmitt A (1989) Presurgical radiographic assessment for implants. *J Prosthet Dent* 61:59–64.
- 20) Reddy MS, Mayfield-Donahoo T, Vandervan FJJ, Jeffcoat MK (1994) A comparison of the diagnostic advantages of panoramic radiography and computed tomography scanning for placement of root form dental implants. *Clin Oral Impl Res* 5:229–238.
- 21) Sakakura CE, Morais JAND, Loffredo LCM, Scaf G (2003) A survey of radiographic prescription in dental implant assessment. *Dentomaxillofac Radiol* 32:397–400.
- 22) Schnitman PA, Shulman LB (1979) Recommendations of the consensus development conference on dental implant. *J Am Dent Assoc* 98:373–377.
- 23) Smith DE, Zarb GA (1989) Criteria for success of osseointegrated dental implants. *J Prosthet Dent* 62:67–72.
- 24) ten Bruggenkate CM, van der Linden LW, Oosterbeek HS (1989) Parallelism of implants visualized on the orthopantomogram. *Int J Oral Maxillofac Surg* 18:213–215.
- 25) Todd AD, Gher ME, Quintero G, Richardson

- AC (1993) Interpretation of linear and computed tomograms in the assessment of implant recipient sites. *J Periodontol* 12:1243–1249.
- 26) Tyndall DA, Brooks SL (2000) Selection criteria for dental implant site imaging: a position paper of the American Academy of Oral and Maxillofacial Radiology. *Oral Surg Oral Med Oral Pathol Oral Radiol Endod* 89:630–637.
- 27) Wakoh M, Nishikawa K, Otonari T, Yamamoto M, Harada T, Sano T, Yajima Y, Ooguro T (2006) Digital subtraction technique for evaluation of peri-implant bone change in digital dental imaging. *Bull Tokyo Dent Coll* 47:57–64.
- 28) Webber RL, Ruttimann UE, Grondahl H-G (1982) X-ray image subtraction as a basis for assessment of periodontal changes. *J Periodont Res* 17:509–511.

Reprint requests to:

Dr. Mamoru Wakoh,
Department of Oral and
Maxillofacial Radiology,
Tokyo Dental College,
1-2-2 Masago, Mihama-ku,
Chiba 261-8502, Japan