

Wernicke's Encephalopathy in Acute and Chronic Kidney Disease: A Systematic Review

Erik Oudman, PhD,^{*,†} Jan W. Wijnia, PhD,^{*,†} David Severs, MSc, MD,[‡] Misha J. Oey, MSc,^{*,†} Mirjam van Dam, MSc,^{*,†} Maaïke van Dorp, MSc,^{*,†} and Albert Postma, PhD^{*,†}

Thiamine (vitamin B1) deficiency is relatively common in patients with kidney disease. Wernicke's encephalopathy (WE) is caused by vitamin B1 deficiency. Our aim was to systematically review the signs and symptoms of WE in patients with kidney disease. We conducted a systematic literature review on WE in kidney disease and recorded clinical and radiographic characteristics, treatment and outcome. In total 323 manuscripts were reviewed, which yielded 46 cases diagnosed with acute and chronic kidney disease and WE published in 37 reports. Prodromal characteristics of WE were loss of appetite, vomiting, weight loss, abdominal pain, and diarrhea. Parenteral thiamine 500 mg 3 times per day often led to full recovery, while Korsakoff's syndrome was found in those receiving low doses. To prevent WE in kidney failure, we suggest administering high doses of parenteral thiamine in patients with kidney disease who present with severe malnutrition and (prodromal) signs of thiamine deficiency.

Keywords: Wernicke's encephalopathy; kidney failure; dialysis; hemodialysis; peritoneal dialysis; thiamine; clinical nutrition

© 2023 The Authors. Published by Elsevier Inc. on behalf of the National Kidney Foundation, Inc. This is an open access article under the CC BY license (<http://creativecommons.org/licenses/by/4.0/>).

Introduction

MALNUTRITION IS COMMON in patients with chronic kidney disease (CKD), especially in those undergoing dialysis.^{1,2} Poor intake, chronic diuretic therapy and an increased loss of water-soluble vitamins in the dialysate expose patients with kidney failure that require dialysis to the risk of severe thiamine deficiency.³⁻⁶ In addition, rat models suggest that CKD may lead to impaired gastrointestinal absorption of thiamine.⁴ Finally, loss of clearance in kidney disease leads to the accumulation of waste products from metabolism. These waste products become toxic when concentrations are high. As an uremic toxin, the antimetabolite of thiamine (oxythiamine) is not cleared

by the kidneys, leading to the inhibition of transketolase. In turn, this inhibition of transketolase leads to problems in the catalysis of thiamine to thiamine pyrophosphate. Therefore, patients with kidney disease may also have functional thiamine deficiency caused by oxythiamine accumulation.⁷

A severe neurological complication of thiamine deficiency is Wernicke's encephalopathy (WE). WE is an acute neuropsychiatric syndrome characterized by the classic triad of ataxia, eye movement disorders, and mental status change.⁸⁻¹² Current prevalence and incidence rates of WE are outdated.⁸ The European Federation of Neurological Societies and the Royal College of Physicians state that 500 mg of parenteral thiamine should be given 3 times daily until symptoms of acute WE resolve. The treatment is life-saving and has the potential to reverse this acute neuropsychiatric syndrome.¹³ Inadequate treatment of WE often results in additional characteristics of the classic symptomatology, and can later develop into chronic Korsakoff's syndrome, a cognitive disorder characterized by severe amnesia, executive problems, and confabulation, which leads to lifelong impairment.⁹⁻¹²

Recently, the number of reports on nonalcoholic WE has been rising.¹⁴ Inadequate management of complicated hyperemesis gravidarum,¹⁵ obesity surgery,¹⁶ and palliative treatment for cancer¹⁷ are some factors leading to WE. CKD has also been related to WE, but systematic reports are missing. The aim of this paper is to review the clinical characteristics of WE in kidney disease, to raise the clinician's index of suspicion about this neuropsychiatric diagnosis, and to review its treatment and preventability.

^{*}Experimental Psychology, Helmholtz Institute, Utrecht University, The Netherlands.

[†]Slingedael Center of Expertise for Korsakoff Syndrome, Lelie Care Group, Rotterdam, The Netherlands.

[‡]Division of Nephrology and Transplantation, Department of Internal Medicine, Erasmus MC, University Medical Center, Rotterdam, The Netherlands.

Financial Disclosure: The authors declare that they have no relevant financial interests.

Conflict of interests: Nothing to disclose.

Ethical Statement: Ethical statement is not applicable for this manuscript.

Address correspondence to Erik Oudman, PhD, Experimental Psychology, Helmholtz Institute, Utrecht University, Heidelberglaan 1, 3584CS Utrecht, The Netherlands. E-mail: E.oudman@leliezorggroep.nl

© 2023 The Authors. Published by Elsevier Inc. on behalf of the National Kidney Foundation, Inc. This is an open access article under the CC BY license (<http://creativecommons.org/licenses/by/4.0/>).

1051-2276

<https://doi.org/10.1053/j.jrn.2023.10.003>

Methods

We performed a systematic review of the literature, and only included reports that provided sufficient information about individual patients. Reports were considered for inclusion if kidney disease was confirmed by the treating physician based on blood levels indicative of kidney disease; and at least one of the following methods of diagnosing WE was reported and consistent with the findings reported in the case description: Caine's operational criteria for WE,¹⁸ Wernicke's classic triad, autopsy evidence of WE, or clinical response to thiamine. The defining signs and symptoms for WE were dietary deficiencies, oculomotor abnormalities, cerebellar dysfunction, or an altered mental state. All case studies published in various levels of English were included in the systematic review.

We searched MEDLINE, EMBASE, and Scopus, using keyword terms (nephropathy, renal, dialysis, Wernicke encephalopathy and Korsakoff's syndrome) from inception. The first author reviewed the title and abstracts of the search yield for eligibility, and screened potentially eligible papers in full text to further assess eligibility. We extracted data from eligible papers in full text. We extracted and indexed the following data: year of publication, age, sex, etiology of kidney disease, duration of kidney disease, presenting signs of WE, presence of ataxia in WE, presence of eye movement disorders in WE, presence of mental status change in WE, magnetic resonance imaging (MRI)/computed tomography (CT) findings in WE, treatment for WE and outcome. Suboptimal treatment of WE was defined as <500 mg of parenteral thiamine as the initial dose per day to treat WE. Cases were excluded if too little information was available to confirm a diagnosis of WE or no clinical characteristics regarding the patient or course of illness were available. We analyzed the data with SPSS (version 25.0). We calculated descriptive statistics (medians, ranges, standard deviation [SD], frequencies, and percentages) for article and patient demographics, symptoms, clinical features of WE, treatment dosing, and cognitive outcome. The total number of cases reporting on specific characteristics is reported in brackets. Finally, we calculated a Pearson's R correlation for the dose per day in milligrams of parenteral thiamine treatment with the year of publication.

Results

General Overview

We performed our search on 4th of May 2023. A flow chart is presented in Figure 1. All included studies were either case reports or case series, since information on the course of illness and symptomatology was lacking in all group studies. After full text screening, we identified 46

unique cases diagnosed with Wernicke encephalopathy (WE) in patients with kidney disease in 37 reports.¹⁹⁻⁵⁶ See Table 1 for an overview of characteristics.

Patient Characteristics

WE was reported in 28 male and 18 female patients with kidney disease. The mean age was 50.5 years (SD: 21.5 years; range: 6-93 years), and patients had an average duration of kidney disease of 3.2 years (SD: 5.0 years, reported in 36 cases). Duration of kidney disease was not present for 3 cases.^{34,47,56} For the available durations, kidney disease duration ranged from acute to 20 years. In total, 37/46 cases (80.4%) received dialysis treatment prior to the development of WE,^{19-30,32-35,37,39,41-44,47-51,53,56} and 9/46 (19.6%) (cases did not.^{31,36,38,40,45,46,52,54,55} 12 cases underwent peritoneal dialysis,^{20-22,24,34,35,39,44,47} 24 cases underwent hemodialysis,^{19,21,23,25-30,32-34,42,48-51,53,56} and for one case the method of dialysis was not clear.⁴¹

Presenting Signs of Wernicke's Encephalopathy in Kidney Disease

Loss of appetite (11/46 cases, 23.9%),^{23,26-28,30,33,35,45,51,53,56} decreased consciousness (10/46 cases, 21.7%),^{30,36,39,42,48-50,52,54,56} vomiting (9 cases, 19.6%),^{26,31,34,39,40,47,51,54,55} sepsis (5/46 cases, 10.9%),^{19,22} weight loss (5/46 cases, 10.9%),^{27,28,38,45,46,48} abdominal pain (3/46 cases, 6.5%),^{20,39,51} and diarrhea (3/46 cases, 6.5%) were reported before onset of WE.^{34,51,55}

Wernicke's Encephalopathy: Classic Triad

WE is characterized by the classic triad of ataxia, eye movement disorders, and mental status change.⁹ The most frequently observed characteristic of the classic WE triad in the reviewed kidney disease cases was mental status change (confusion/delirium), which was present in 41/46 cases (89.1%).^{19-36,38,39,41-45,47-56} Ataxia was present in 31/46 cases (67.4%), ranging from gait abnormalities to the inability to walk or move.^{20,21,23,25-30,32-34,36-38,41-45,47-49,51-55} Eye movement disorders were present in 27/46 cases (58.7%).^{20-22,24-26,31-36,38,40,45,47-49,51-54} In 14 cases nystagmus was reported,^{20,24,25,31,36,38,40,45,47,49,51-54} and in 11 cases ophthalmoplegia was reported.^{24,26,32,34-36,41,45,48,52} The full triad was present in 22/46 cases (47.8%). In two cases, additional chorea was reported.^{20,21,25,26,32-34,36,38,41,45,47-49,51-54}

ImaginEnhanced signal intensity on MRI in the mammillary bodies, medial thalamus, and the periaqueductal gray matter is associated with WE. On CT hypoattenuations in the same regions can be visible.^{9,57} Of the 46 cases, 24 underwent MRI (52.2%),^{26-35,38-40,42,44,45,47,49-56} and 2/46 patients underwent CT (4.3%).^{27,28,48} Radiological alterations consistent with WE were present in 20/24 patients (83.3%) that underwent MRI.^{26-31,33,35,38,39,44,45,47,49-56} One patient had a normal CT

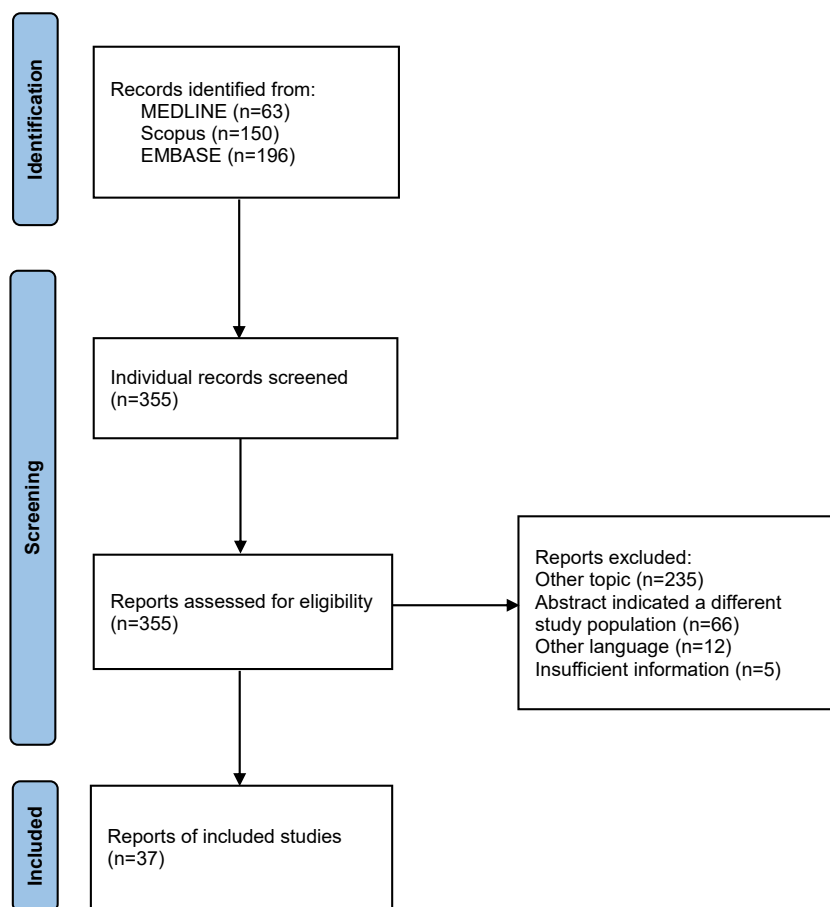


Figure 1. Flow chart for the systematic review.

scan,⁴⁸ and one patient had CT findings consistent with WE.^{27,28}

Treatment and Outcome

12/46 patients died following WE (26.1%).^{19–22,47} In 21/46 cases (45.7%) there was a full recovery.^{23–29, 31,32,34,38,40,41,43,46,49–51,54–56} In 3/46 cases (6.5%), chronic Korsakoff's syndrome was mentioned as an outcome.^{35,39,53} Of importance, all of these 3 cases did not receive an adequate dose of thiamine following diagnosis of WE (<500 mg IV/day). 7/46 cases (15.2%) report an adequate dose of thiamine (500 mg IV 3 times daily).^{35,38,44,45,48,54,55} There is a significant correlation between year of publication and dosing ($r(24) = .39$, $P = .005$), with better dosing regimens in the recent years.

Discussion

In this systematic review, we found 46 case descriptions of WE among patients with acute or CKD.^{19–56} A substantial group of patients did not survive WE, and some developed chronic Korsakoff syndrome. Many patients did not receive adequate treatment for WE, possibly complicating recovery. The large majority of

cases showed a transient increase of mental and motoric symptomatology over the course of WE, with prodromal signs followed by actual signs of WE. Of importance, vomiting, diarrhea, weight loss, abdominal pain, and a loss of appetite were frequently present before onset of WE as a sign of or precipitating factor for thiamine deficiency in kidney disease patients.

Patients with kidney failure who are treated with dialysis are at risk for thiamine deficiency due to alimentary reasons,^{4,58} potentially impaired gastrointestinal absorption,^{4,5,58} use of loop diuretics,⁵⁹ and a loss of thiamine via the dialysate.^{2,3} Moreover, accumulation of oxythiamine may lead to a functional thiamine deficiency.⁷ In theory, these risks could be particularly high around the time of dialysis initiation, when the nutritional status is at its worst.⁶⁰ Moreover, infections are a common presenting sign of WE in critically ill patients,⁶¹ and patients with sepsis are frequently thiamine deficient.⁶² Therefore, a high level of suspicion for WE is required in CKD patients, particularly when they require dialysis.

In other populations that are at risk for severe thiamine deficiency and WE the risk for WE is underestimated by clinicians,^{10,11,14,17} and a treatment delay for WE is

Table 1. Gender, Age, Primary Etiology, Duration of Kidney Disease, Presenting Signs of Wernicke's Encephalopathy, Ataxia in Wernicke's Encephalopathy, Eye Movement Disorders in Wernicke's Encephalopathy, Mental Status Change in Wernicke's Encephalopathy, CT/MRI Findings, Treatment, and Outcome of Wernicke-Korsakoff in Patients With Kidney Disease

Reference	Gender	Age	Primary Etiology	Duration of Kidney Failure	Presenting Sign	Ataxia	Nystagmus (+) or Ophthalmoplegia (+ +)	Mental Status Change	CT/MRI	Treatment	Outcome
Lopez et al., 1968 ¹⁹	F	12	HD	7 mo	Sepsis	-	-	Confusion	-	-	Deceased
Faris et al., 1972 ²⁰	F	40	PD	Acute	Lower abdominal pain, bleeding	+	+	Stupor/coma	Autopsy brain alterations in hypothalamus, thalamus, mammillary bodies	-	Deceased
Stratta et al., 1982 ²¹	M	36	Cholecystic empyema and pancreatic abscess. Acute kidney failure, HD, glucose infusion	Acute		+	+	+			Deceased
Stratta et al., 1982 ²¹	F	75	Acute appendicitis, acute kidney failure, PD, glucose infusion	Acute		+	+	+		400 mg/day	Deceased
Stratta et al., 1982 ²¹	F	71	Intestinal ischemic infarction, acute renal failure, HD, glucose infusion	Acute		+	+	+		400 mg/day	Deceased
Jaghadha et al., 1982 ²²	M	78	Intestinal neoplastic occlusion, HD, glucose infusion	Acute		+	+	+			Deceased
Jaghadha et al., 1987 ²²	M	66	Chronic nephritis, sepsis, PD	6 wk	Sepsis	-	-	+, confusion	-	-	Deceased, diagnosis postmortem
Jaghadha et al., 1987 ²²	M	26	Sepsis, PD	2 mo	Sepsis	-	-	+, confusion	-	-	Deceased, diagnosis postmortem
Jaghadha et al., 1987 ²²	F	53	Chronic glomerulonephritis, PD	3 ½ mo	Sepsis	-	-	+, confusion	-	-	Deceased, diagnosis postmortem
Jaghadha et al., 1987 ²²	M	63	Gangrenous cholecystitis, HD	3 wk		-	+	-	-	-	Deceased, diagnosis postmortem
Jaghadha et al., 1987 ²²	F	48	PD	10 mo	Sepsis	-	-	+	-	-	Deceased, diagnosis postmortem
Descombes et al., 1991 ²³	M	77	HD, cataract surgery	10 y	Nausea, loss of appetite after cataract surgery, character change	+, myoclonic jerks	-	+, confusion and memory problems	N.A.	300 mg/day IV	Recovery
Can et al., 1994 ²⁴	F	21	Pylophrenitis, PD, lung edema	6 y	Diplopia and droopy eyelid	-	++	+, drowsiness	N.A.	Unknown	Recovery
Kondo et al., 1996 ²⁵	F	28	Gastric carcinoma, intravenous hyperalimentation, HD and intubation	Acute	Inability to eat because of stenosis	+	+	+, confusion	N.A.	Thaimine	Unknown
Ihara et al., 1999 ²⁶	M	70	Infections, pitting edema, ileus, total parenteral nutrition without thiamine, HD	1.5 y	General malaise, nausea and vomiting	+	++	+, confusion	MRI: periaqueductal gray area	100 mg/day IV	Recovery, but remaining brain alterations
Ihara et al., 1999 ²⁶	M	69	DM, glucose administration without thiamine, HD	10 y	Loss of appetite	+, gait disturbance	++	+, confusion	N.A.	100 mg/day IV	Recovery

Hung et al., 2001a Hung et al., 2001b ²⁷	M	55	DM, HD	6 mo	Slurred speech, ataxia	+, and chorea	-	+, slurred speech	CT: basal ganglia	100 mg/day IV	Full recovery after prolonged "Korsakoff psychosis"
Hung et al., 2001a Hung et al., 2001b ²⁸	M	67	DM, HD, dyspnea, enlarged cardiac silhouette, 6 kg weight loss	9 mo	Loss of appetite, restlessness	-, bilateral chorea	-	+, restlessness	MRI: basal ganglia	100 mg/day IV	Recovered
Barbara et al., 2006 ²⁹	F	50	Breast cancer, HD	2 y	Nausea, anorexia, fatigue, abulia	+	-	+, speech impairment and mental clouding	MRI: basal ganglia, hypothalamus	100 mg/day IM	Recovered
Ueda et al., 2006 ³⁰	M	64	DM, glucose administration without thiamine, HD	4 y	Loss of appetite	+	-	+, disturbed consciousness	MRI: midbrain and thalamus	150 mg/day IV	Required ongoing assistance (cognitive problems)
Nishida et al., 2009 ³¹	M	6	Nephrotic syndrome	2 y	Nausea and vomiting	-	+	+, drowsiness	MRI: symmetrical, abnormal, highintensity signals in the bilateral head of caudate nuclei, putamen, and medial thalami	100 mg/day IV	Recovered
D'Ettore et al., 2012 ³²	M	62	Rectal cancer, renal tuberculosis, HD	20 y	Confusion	+, involuntary movements	+ and ++	+, cognitive impairment	MRI: normal	100 mg IV (once)	Recovered
Kimura et al., 2012 ³³	M	79	HD	Acute	Loss of appetite, fatigue	+	+	+	MRI: periaqueductal gray	N.A.	N.A.
Baracco et al., 2012 ³⁴	F	16	Systemic lupus erythematosus, PD	N.A.	Vomiting and diarrhea	+, movement disorders	++	+, unresponsive and altered behavior	MRI: no abnormalities	Thiamine and TPN	Recovered
Nakashima et al., 2013 ³⁵	M	43	Loss of appetite, Roux en Y gastrectomy after cancer, PD	8 y	Loss of appetite	-	++	+, delirium and depression	MRI: thalamus	50.0 mg/day T.I.D. 3 days; 100 mg/day for 23 days	Korsakoff syndrome
Shavit et al., 2013 ³⁶	M	48	DM, retinopathy, gastroparesis, hyperlipidemia, acute renal failure, infection on amputated leg	Acute	Loss of consciousness	+	++	+, confusion	N.A.	200 mg IV T.I.D.	Recovered
Kittamonkolchai et al., 2013 ³⁷	F	44	HD	2 y	Tingling sensation lower extremities, progressive weakness	+	-	-	N.A.	N.A.	N.A.
Kang et al., 2015 ³⁸	F	36	Hyperemesis gravidarum, 20 kg weight loss, acute kidney failure	Acute	Critically ill	+	+	+	MRI: medio-posterior thalami (arrow) and fornices (large arrowhead)	500 mg/day IV T.I.D.	Recovered
Kim et al., 2016 ³⁹	F	38	PD, systemic lupus, nephritis	16 y	Abdominal pain, vomiting, peritonitis	-	-	+, seizures; loss of consciousness	MRI: mammillary bodies, thalamus, midbrain	300 mg/day	Memory deficits/ Korsakoff syndrome
Sanchez-Larsen et al., 2016 ⁴⁰	M	51	Cyclic vomiting disorder, prerenal kidney failure	Acute	Vomiting, hypomagnesemia	-	+	-	MRI: no issues	High doses IV	Recovered
Sdrimas et al., 2016 ⁴¹	M	43	Aspergillosis, pneumonia, cachexia, dialysis	Acute	Not alert, critically ill	+	++	+, unable to follow commands	N.A.	High doses IV	Dramatic improvement
Nishimura et al., 2018 ⁴²	F	76	DM, HD, poor food intake	3 years	Aphasia, ataxia and loss of consciousness	+	-	+, aphasia	MRI: no abnormalities	1000 mg/day for 2 days IV	Could ambulate and was discharged

(Continued)

Table 1. Gender, Age, Primary Etiology, Duration of Kidney Disease, Presenting Signs of Wernicke's Encephalopathy, Ataxia in Wernicke's Encephalopathy, Eye Movement Disorders in Wernicke's Encephalopathy, Mental Status Change in Wernicke's Encephalopathy, CT/MRI Findings, Treatment, and Outcome of Wernicke-Korsakoff in Patients With Kidney Disease (*Continued*)

Reference	Gender	Age	Primary Etiology	Duration of Kidney Failure	Presenting Sign	Ataxia	Nystagmus (+) or Ophthalmoplegia (++)	Mental Status Change	CT/MRI	Treatment	Outcome
Harshman et al., 2018 ⁴³	M	13	Severe graft-versus-host disease, HD, total parenteral nutrition	Chronic	Tremor, disorientation, ataxia, and garbled speech	+	-	+, disorientation and speech problems	N.A.	High dose of parenteral thiamine	Recovered
Nicotera et al., 2018 ⁴⁴	M	51	DM, PD, amputation right foot	5 y	Agitation	+	-	+, altered speech	MRI: hyperintensities of back-medial thalami and periaqueductal membranes and white matter issues	500 mg IV T.I.D. for 5 days 250 mg IV T.I.D. for 7 days	Recovered
Tan et al., 2018 ⁴⁵	M	56	Hypertension, gout, starvation, acute kidney failure	Acute	Loss of weight and appetite, myopathy	+	+ and ++	+, lethargy	MRI: symmetrical signal abnormality and enhancement in the periaqueductal area	500 mg T.I.D.	Recovered
Onishi et al., 2019 ⁴⁶	M	74	Renal cell carcinoma, lung and liver metastasis, nephrectomy; nivolumab treatment	6 y	Loss of weight	-	-	-	NA	200 mg IV	Recovered
Duni et al., 2020 ⁴⁷	F	60	Vertebral osteomyelitis, PD	N.A.	Vomiting	+	+	+, speech problems and hallucinations	MRI: Mammillary bodies, thalamic area, cortical hyperintensities	IV, unknown dose	Deceased
De Oliveira et al., 2021 ⁴⁸	M	52	COVID-19, HD, septic shock, prior bariatric surgery, asthma	Acute	Psychomotor agitation and loss of consciousness	+, bedridden	++	+, torpor, uncooperative	CT: normal	500 mg IV T.I.D. for 5 days	Significant improvement 3 months: conscious, oriented, walking independently
Hor et al., 2021 ⁴⁹	F	64	Acute kidney injury caused by neuroleptic malignant syndrome (fluphenazine for bipolar disorder), HD	Acute	Found lying on the floor, poor intake	+	+	+, speech and disorientation	MRI: hyperintensities at the periaqueductal, medial thalami, mammillary bodies, tectal plate and dentate nucleus	300 mg IV T.I.D.	Recovered
Seto et al., 2021 ⁵⁰	M	79	HD	Chronic	Duodenal ulcer, diminished intake, disorientation, loss of eye contact, involuntary movements	-	-	+, disorientation	MRI: cerebral aqueduct, around the third ventricle, and inside the Thalamus	200 mg IV	Recovered
Kantariya et al., 2021 ⁵¹	M	19	Kidney transplantation, pancreatitis, HD	12 y	Loss of appetite, diffuse abdominal pain, vomiting, persistent diarrhea, low-grade fever, 8 kg weight loss	+	+	+	MRI: bilateral diffuse lesion of the midbrain, thalamus and cerebellum without volumetric effect on adjacent brain structures	300 mg/day parenteral	Recovered

Hernandez et al., 2022 ⁵²	F	43	Seizure disorder, pelvic inflammatory disease, alcoholic hepatitis, folic acid deficiency, and alcohol use dependence, Acute kidney disease	Acute	Altered mental status	+	+ and ++	+	MRI: Bilateral Posteromedial Thalami, Bilateral Mammillary Bodies, and in the Periaqueductal Gray Matter	100 mg IV, followed by dextrose. Later: 500 mg IV T.I.D.	Outpatient care for motoric issues. Cognition unknown
Hidaka et al., 2022 ⁵³	M	30	Dyspnea, leg edema, HD	4 y	Loss of appetite, memory issues	+	+	+, disorientation	MRI: hyperintensities bilateral striatum and mammillary bodies. Later also frontal	100 mg IV; 10 days later 500 mg T.I.D.	Korsakoff's syndrome
Lobao et al., 2022 ⁵⁴	M	32	Roux-en-y surgery, acute kidney disease	Acute	Lethargic, found unresponsive, vomiting	+	+	+, memory problems	MRI: dorso-medial thalami, tectal plate, periaqueductal and mammillary bodies	500 mg IV T.I.D.	No cognitive follow-up
Mittal et al., 2022 ⁵⁵	M	6	Nephrotic syndrome, ascites, hypertension	2 y	Vomiting and diarrhea for 3 weeks, vacant stare, shivering, irritability	+	-	+, irritability	MRI: bilateral thalamus involving pulvinar and ventro-medial thalami, bilateral hypothalamus, mammillary bodies	500 mg IV T.I.D.	Recovered
Aomura et al., 2022 ⁵⁶	F	93	Hypertension, HD	N.A.	Loss of appetite, muscle weakness, and falls, decreased consciousness	-	-	+	MRI: thalamus	High doses	Recovered

+, symptom is present; -, symptom is absent; BMI, body mass index in kg/m²; CT, computed tomography; DM, diabetes mellitus, F, female; HD, hemodialysis; M, male; MRI, magnetic resonance imaging; N.A., not available; PD, peritoneal dialysis; TPN, total parenteral nutrition.

relatively common,^{10,14,17} leading to more severe outcome of WE.¹⁴ To compensate for the loss of thiamine by dialysis, oral thiamine supplementation is part of routine care for patients with chronic kidney failure that require dialysis.⁶³ Preventive thiamine doses and durations of supplementation have not been established for WE.⁹ Because thiamine supplementation is well-tolerated, and parenteral thiamine supplementation can fully prevent WE, it is advocated that parenteral thiamine be given to all at-risk patients admitted to emergency departments.⁶⁴ Regarding patients that frequently vomit, prophylaxis of WE consists of 100 mg parenteral thiamine per day in hyperemesis gravidarum.⁶⁵ While evidence for this dosing regimen is lacking for kidney disease, this regimen could be expected to also show beneficial effects in inpatients with kidney failure who vomit.

The European Federation of Neurological Societies and the Royal College of Physicians state that 500 mg of parenteral thiamine should be given 3 times daily until symptoms of acute WE resolve. The treatment is lifesaving and has the potential to reverse this acute neuropsychiatric syndrome.¹³ In the present review dosing per day was correlated with the year of publication, suggesting higher doses in later publications. Because there is a clear dose-response relationship for parenteral thiamine treatment, doses lower than 500 mg are not suitable. Also in our review lower doses sometimes led to worse outcome.

While WE in kidney disease was present in all age groups, the majority of patients were in their forties and older, in congruence with higher incidence rates of kidney disease in older individuals.⁶⁶ Many had prolonged disease duration, up to 20 years postonset of kidney failure.³² Importantly, almost half of the included cases developed WE in acute kidney disease.^{19-22, 25,33,36,38,40,41,45,48,49,52,54} In both acute and chronic kidney failure additional complications, such as diabetes mellitus,^{26-28,30,36,42,44} cancer,^{29,32,35} sepsis,^{19,22} and infections of other etiology^{21,22,24,39,43,51,52} were relatively common contributive factors to the development of WE. Earlier research already pointed to the increased likelihood for the development of severe thiamine deficiency and WE in diabetes mellitus,^{67,68} cancer,^{9,17,68} and infections (including sepsis).^{61,68} Severe kidney disease complicated by one of these factors should, therefore, alarm clinicians for routine vitamin status checks and supplementation. In some patients with kidney disease reviewed in this systematic review, glucose administration without thiamine supplementation was the factor inducing WE.^{21,26,30} In other populations, such as inflammatory bowel disease or gastrointestinal oncology patients, glucose infusion and/or parenteral nutrition without thiamine supplementation has been reported to induce WE.^{69,70} Since the last case study reporting glucose administration leading to WE was published in 2006, it could be that glucose administration without thiamine supplementation is becoming obsolete.

In at-risk patients, such as CKD patients, thiamine supplementation prior to infusion is required.

Radiological alterations on MRI were present in 20/24 WE cases. Although the sensitivity of MRI in detecting WE was only 53% in a large population of WE patients, the specificity was 93%.⁷¹ While MRI could be used as a diagnostic tool for WE, diagnosis based on the acute triad is more beneficial.^{9,10}

One of the strengths of the present study is its comprehensiveness and inclusion of a relatively large number of cases of WE in kidney disease. Moreover, this is the first systematic review on this topic so far. Our study also has limitations. Case reports can be subject to various biases including reporting bias, publication bias, and detection bias. Moreover, the quality of the reported cases was variable, specifically regarding the timing and progress of the symptoms. Our presentation of symptoms was restricted and could have included additional information regarding other complications.

In conclusion, WE in kidney disease is a rare but severe and preventable consequence of either dialysis, extreme weight loss, vomiting, additional infections or diarrhea. It warrants immediate attention given its rapid onset and detrimental course. Early and late symptoms of WE are currently often missed, leading to worse outcome. Rapid treatment with high doses of thiamine is still a life-saving measure by directly ameliorating the core symptoms of WE, and reducing the chances for chronic adverse outcomes. Preventive thiamine supplementation in kidney disease patients is effective in reducing chances for the development of WE.

Practical Application

Patients diagnosed with acute or chronic kidney problems are at a higher risk to develop thiamine deficiency. Both complex disease mechanisms and dialysis make them more at risk than other patient groups. In this systematic review we highlighted the signs and symptoms of WE, an acute neurological disorder following thiamine deficiency, in kidney disease. The included studies suggest that kidney disease patients should receive thiamine supplementation as a part of routine vitamin treatment. When kidney disease progress is complicated leading to malnourishment, parenteral thiamine injections of 100 mg/day are recommended. In case of WE, injections of 500 mg 3 times per day are recommended to support good outcome.

References

1. Visser WJ, de Mik - van Egmond AME, Timman R, Severs D, Hoorn EJ. Risk factors for muscle loss in hemodialysis patients with high comorbidity. *Nutrients*. 2020;12:2494.
2. Aparicio M, Cano N, Chauveau P, et al. Nutritional status of hemodialysis patients: a French national cooperative study. French Study group for nutrition in dialysis. *Nephrol Dial Transplant*. 1999;14:1679-1686.

3. Jankowska M, Rudnicki-Velasquez P, Storoniak H, et al. Thiamine diphosphate status and dialysis-related losses in end-stage kidney disease patients treated with hemodialysis. *Blood Purif*. 2017;44:294-300.
4. Bukhari FJ, Moradi H, Gollapudi P, Kim HJ, Vaziri ND, Said HM. Effect of chronic kidney disease on the expression of thiamin and folic acid transporters. *Nephrol Dial Transplant*. 2011;26:2137-2144.
5. Seligmann H, Halkin H, Rauchfleisch S, et al. Thiamine deficiency in patients with congestive heart failure receiving long-term furosemide therapy: a pilot study. *Am J Med*. 1991;91:151-155.
6. Bossola M, Di Stasio E, Viola A, et al. Dietary intake of trace elements, minerals, and vitamins of patients on chronic hemodialysis. *Int Urol Nephrol*. 2014;46:809-815.
7. Zhang F, Masania J, Anwar A, et al. The uremic toxin oxythiamine causes functional thiamine deficiency in end-stage renal disease by inhibiting transketolase activity. *Kidney Int*. 2016;90:396-403.
8. Oudman E, Kessels RPC. Alcohol-related cognitive disorders. In: Kessels RPC, van den Berg E, Ponds R, Spikman J, van Zandvoort M, eds. *Clinical Neuropsychology*. 2nd ed Amsterdam: Boom; 2023:441-462.
9. Sechi G, Serra A. Wernicke's encephalopathy: new clinical settings and recent advances in diagnosis and management. *Lancet Neurol*. 2007;6:442-455.
10. Isenberg-Grzeda E, Kutner HE, Nicolson SE. Wernicke-Korsakoff syndrome: under-recognized and under-treated. *Psychosomatics*. 2012;53:507-516.
11. Wijnia JW. A clinician's view on Wernicke-Korsakoff syndrome. *J Clin Med*. 2023;11:6755.
12. Kopelman MD, Thomson AD, Guerrini I, Marshall EJ. The Korsakoff syndrome: clinical aspects, psychology and treatment. *Alcohol Alcohol*. 2009;44:148-154.
13. Thomson AD, Cook CH, Touquet R, Henry JA. The Royal College of Physicians report on alcohol: guidelines for managing Wernicke's encephalopathy in the accident and emergency department. *Alcohol Alcohol*. 2002;37:513-521.
14. Oudman E, Wijnia JW, Oey MJ, van Dam M, Postma A. Wernicke-Korsakoff syndrome despite no alcohol abuse: a summary of systematic reports. *J Neurol Sci*. 2021;426:117482.
15. Oudman E, Wijnia JW, Oey M, van Dam M, Painter RC, Postma A. Wernicke's encephalopathy in hyperemesis gravidarum: a systematic review. *Eur J Obstet Gynecol Reprod Biol*. 2019;236:84-93.
16. Oudman E, Wijnia JW, van Dam M, Biter LU, Postma A. Preventing Wernicke encephalopathy after bariatric surgery. *Obes Surg*. 2018;28:2060-2068.
17. Isenberg-Grzeda E, Rahane S, DeRosa AP, Ellis J, Nicolson SE. (2016) Wernicke-Korsakoff syndrome in patients with cancer: a systematic review. *Lancet Oncol*. 2016;17:e142-e148.
18. Caine D, Halliday GM, Kril JJ, Harper CG. Operational criteria for the classification of chronic alcoholics: identification of Wernicke's encephalopathy. *J Neurol Neurosurg Psychiatry*. 1997;62:51-60.
19. Lopez RI, Collins GH. Wernicke's encephalopathy. A complication of chronic hemodialysis. *Arch Neurol*. 1985;18:248-259.
20. Faris AA. Wernicke's encephalopathy in uremia. *Neurology*. 1972;22:1293-1297.
21. Stratta P, Canavese C, Robecchi A, et al. Pseudohypoglycaemia in acute renal failure with Wernicke-Korsakoff syndrome. *Nephron*. 1982;31:94-95.
22. Jagadha V, Deck JH, Halliday WC, Smyth HS. Wernicke's encephalopathy in patients on peritoneal dialysis or hemodialysis. *Ann Neurol*. 1987;21:78-84.
23. Descombes E, Dessibourg CA, Fellay G. Acute encephalopathy due to thiamine deficiency (Wernicke's encephalopathy) in a chronic hemodialyzed patient: a case report. *Clin Nephrol*. 1991;35:171-175.
24. Can U, Aydin P, Kansu T. Bilateral external ophthalmoplegia in uremia. *Nephron*. 1994;68:391.
25. Kondo K, Fujiwara M, Murase M, et al. Severe acute metabolic acidosis and Wernicke's encephalopathy following chemotherapy with 5-Fluorouracil and Cisplatin: case report and review of the literature. *Jpn J Clin Oncol*. 1996;26:234-236.
26. Ihara M, Ito T, Yanagihara C, Nishimura Y. Wernicke's encephalopathy associated with hemodialysis: report of two cases and review of the literature. *Clin Neurol Neurosurg*. 1999;101:118-121.
27. Hung SC, Hung SH, Targ DC, Huang TP, Yang WC. Chorea induced by thiamine deficiency in hemodialysis patients. *Am J Kidney Dis*. 2001a;37:427-430.
28. Hung SC, Hung SZ, Targ DC, Uang WC, Chen TW, Huang TP. Thiamine deficiency and unexplained encephalopathy in hemodialysis and peritoneal dialysis patients. *Am J Kidney Dis*. 2001b;38:941-947.
29. Barbara PG, Manuel B, Elisabetta M, et al. The suddenly speechless florist on chronic dialysis: the unexpected threats of a flower shop? *Nephrol Dial Transplant*. 2005;21:223-225.
30. Ueda K, Takada D, Mii A, et al. Severe thiamine deficiency resulted in Wernicke's encephalopathy in a chronic dialysis patient. *Clin Exp Nephrol*. 2006;10:290-293.
31. Nishida M, Sato H, Kobayashi N, Morimoto M, Hamaoka K. Wernicke's encephalopathy in a patient with nephrotic syndrome. *Eur J Pediatr*. 2009;168:731-734.
32. D'Ettorre M, Rosa F, Coppola A, Mele C, Alfieri S, Doglietto B. Post-operative suspected Wernicke's Encephalopathy in a rectal cancer patient: a case report. *J Palliat Care*. 2012;28:290-292.
33. Kimura H, Takeda K, Muto Y, et al. Development of Wernicke's encephalopathy during initiation of hemodialysis in an elderly non-alcoholic patient. *Clin Nephrol*. 2012;78:487-491.
34. Baracco R, Ku L, Adabala M, et al. An adolescent on peritoneal dialysis with acute encephalopathy: questions. *Pediatr Nephrol*. 2013;28:1221-1222.
35. Nakashima Y, Ito K, Nakashima H, et al. Wernicke's encephalopathy that developed during the introduction period of peritoneal dialysis. *Intern Med*. 2013;52:2093-2097.
36. Shavit I, Brown TM. Simultaneous scurvy and Wernicke's encephalopathy in a patient with an ascorbate-responsive dyskinesia. *Psychosomatics*. 2013;54:181-186.
37. Kittanamongkolchai W, Leeaphorn N, Srivali N, Cheungpasitporn W. Beriberi in a dialysis patient: do we need more thiamine? *Am J Emerg Med*. 2013;31:753.
38. Kang BJ, Kim MG, Kim JH, et al. (2015) A critical case of Wernicke's encephalopathy induced by hyperemesis gravidarum. *Korean J Crit Care Med*. 2015;30:128-131.
39. Kim CS, Bae EH, Ma SK, Kim SW. The case seizure, ophthalmoplegia, and amnesia in a peritoneal dialysis patient. *Kidney Int*. 2016;90:1389-1390.
40. Sánchez-Larsen A, Segura T, Garcia - Munozguren S, Peinado - Rodenas J, Zamarro J, Hernández - Fernández F. Cerebral vasospasm and wernicke encephalopathy secondary to adult cyclic vomiting syndrome: the role of magnesium. *BMC Neurol*. 2016;16:135.
41. Sdrimas K, Wongrakpanich A, Alvarez JB. Diuretics and malnutrition-induced Wernicke's encephalopathy in the critically ill patient. *Chest*. 2016;150:454A.
42. Nishimura Y. Wernicke's encephalopathy after cardiac surgery. *Asian Cardiovasc Thorac Ann*. 2018;26:302-304.
43. Harshman LA, Lee-Son K, Jetton JG. Vitamin and trace element deficiencies in the pediatric dialysis patient. *Pediatr Nephrol*. 2018;33:1133-1143.
44. Nicotera R, Leonardi G, Castagna A, Cernaro V, Coppolino G. Wernicke-Korsakoff syndrome in end-stage renal disease: a case report. *Ther Apher Dial*. 2018;22:676-678.
45. Tan TXZ, Lim KC, Chung CC, Aung T. Starvation-induced diplopia and weakness: a case of beriberi and Wernicke's encephalopathy. *BMJ Case Rep*. 2019;12:e227412.
46. Onishi H, Okabe T, Uchida N, et al. (2019) Thiamine deficiency in a patient with recurrent renal cell carcinoma who developed weight loss with a normal appetite and loss of energy soon after nivolumab treatment. *Pall Supp Care*. 2019;18:241-243.

47. Duni A, Ikonou M, Alekos J, Pappas C, Dounousi E. Wernicke encephalopathy: an unexpected cause of death in a peritoneal dialysis patient. *Perit Dial Int*. 2021;41:588-589.
48. de Oliveira MVB, Bernabé DG, Irikura S, Irikura RB, Fontanelli AM, Goncalves MVM. Wernicke Encephalopathy in COVID-19 Patients: report of three cases. *Front Neurol*. 2021;12:629273.
49. Hor ESL, Singh GP, Omar NA, Russell V. Atypical neuroleptic malignant syndrome and non-alcoholic Wernicke's encephalopathy. *BMJ Case Rep*. 2021;14:e244082.
50. Seto N, Hamano T, Onishi H, Uchida N. A case of Wernicke's encephalopathy arising in the early stage after the start of hemodialysis. *CEN Case Reports*. 2022;11:314-320.
51. Kantariya RO, Vetchinnikova ON, Vatazin AV, Sherman LA. Non-alcoholic Wernicke's Encephalopathy in a kidney transplant recipient. *Russ J of Transp and Arti Organ*. 2021;23:76-83.
52. Hernandez L, Brockman T, Mehta T. Identification of Wernicke encephalopathy in a patient presenting with altered mental status and dehydration. *Wis Med J*. 2022;121:e10-e14.
53. Hidaka M, Kumamoto M, Suenaga T, et al. Wernicke-Korsakoff syndrome in a young adult on dialysis who showed bilateral ganglia lesions: a case report. *Intern Med*. 2022;62:1-5.
54. Lobao M, Sampaio MB, Leite MS, Gomes F, Silva JM. Beri-beri and Wernicke encephalopathy in a thirty-year old male. *Cureus*. 2022;14:e24692.
55. Mittal A, Tiwari S, Sureka B, Singh K. Wernicke's encephalopathy - an oddball complication of nephrotic syndrome. *Saudi J Kidney Dis Transpl*. 2021;32:1456-1460.
56. Aomura D, Kurasawa Y, Harada M, Hashimoto K, Kamijo Y. Brain MRI detection of early Wernicke's encephalopathy in a hemodialysis patient. *Clin Case Rep*. 2022;10:e05539.
57. Cerase A, Rubenni E, Rufa A, et al. CT and MRI of Wernicke's encephalopathy. *Radiol Med*. 2011;116:319-333.
58. Moradi H, Said HM. Functional thiamine deficiency in end-stage renal disease: malnutrition despite ample nutrients. *Kidney Int*. 2016;90:252-254.
59. Hurtado-Torres GF. Thiamin deficiency secondary to loop diuretics, an overlooked cause of multiorgan failure. *Nutr Clin Pract*. 2021;36:1086-1087.
60. Saka Y, Naruse T, Kato A, et al. Thiamine status in end-stage chronic kidney disease patients: a single-center study. *Int Urol Nephrol*. 2018;50:1913-1918.
61. Wijnia JW, Oudman E, van Gool WA, et al. Severe infections are common in thiamine deficiency and may be related to cognitive outcomes: a cohort study of 68 patients with Wernicke-Korsakoff syndrome. *Psychosomatics*. 2016;57:624-633.
62. Attaluri P, Castillo A, Edriss H, Nugent K. Thiamine deficiency: an important consideration in critically ill patients. *Am J Med Sci*. 2018;356:382-390.
63. Allman MA, Truswell AS, Tiller DJ, et al. Vitamin supplementation of patients receiving haemodialysis. *Med J Aust*. 1989;150:130-133.
64. Galvin R, Bräthen G, Ivashynka A, Hillbom M, Tanasescu R, Leone MA. EFNS guidelines for diagnosis, therapy and prevention of Wernicke encephalopathy. *Eur J Neurol*. 2010;17:1408-1418.
65. Green-Top Guideline No. 69. *The Management of Nausea and Vomiting in Pregnancy and Hyperemesis Gravidarum*. London, UK: Royal College of Obstetricians & Gynaecologists; 2019:1-22.
66. Hill N, Fatoba ST, Oke JL, et al. Global prevalence of chronic kidney disease - a systematic review and meta-analysis. *PLoS One*. 2016;11:e0158765.
67. Wijnia JW, van de Wetering BJM, Zwart E, Nieuwenhuis KGA, Goossens MA. Evolution of Wernicke-Korsakoff syndrome in self-neglecting alcoholics: preliminary results of relation with Wernicke-delirium and diabetes mellitus. *Am J Addict*. 2012;21:104-110.
68. Rakotoambinina B, Hiffler L, Gomes F. Pediatric thiamine deficiency disorders in high-income countries between 2000 and 2020: a clinical reappraisal. *Ann N Y Acad Sci*. 2021;1498:57-76.
69. Oudman E, Wijnia JW, Oey MJ, van Dam M, Postma A. Wernicke's encephalopathy in Crohn's disease and ulcerative colitis. *Nutrition*. 2021;86:11112.
70. Fedeli P, Davies RJ, Cirocchi R, Popivanov G, Bruzzone P, Giustozzi M. Total parenteral nutrition-induced Wernicke's encephalopathy after oncologic gastrointestinal surgery. *Open Med*. 2020;15:709-713.
71. Antunez E, Estruch R, Cardenal C, Nicolas JM, Fernandez-Sola J, Urbano-Marquez A. Usefulness of CT and MR imaging in the diagnosis of acute Wernicke's encephalopathy. *AJR Am J Roentgenol*. 1998;171:1131-1137.