



## CLINICAL REPORT

# Needle-free electronically-controlled jet injector treatment with bleomycin and lidocaine is effective and well-tolerated in patients with recalcitrant keloids

Vazula Zulfra Bekkers MD<sup>1</sup>  | Fatima Khan BSc<sup>1</sup> | Pim Aarts MD<sup>1</sup> |  
 Katarzyna Zdunczyk MSc<sup>2,3</sup> | Errol Prospero Prens MD, PhD<sup>1</sup> |  
 Albert Wolkerstorfer MD, PhD<sup>4</sup> | Robert Rissmann PhD<sup>2,3,5</sup> |  
 Martijn Bastiaan Adriaan van Doorn MD, PhD<sup>1,2</sup> 

<sup>1</sup>Department of Dermatology, Erasmus University Medical Center Rotterdam, Rotterdam, The Netherlands

<sup>2</sup>Centre for Human Drug Research, Leiden, The Netherlands

<sup>3</sup>Division of BioTherapeutics, Leiden Academic Center for Human Drug Research, Leiden, The Netherlands

<sup>4</sup>Department of Dermatology, Amsterdam University Medical Centers, Amsterdam, The Netherlands

<sup>5</sup>Department of Dermatology, Leiden University Medical Center, Leiden, The Netherlands

## Correspondence

Martijn Bastiaan Adriaan van Doorn, MD, PhD, Erasmus Medisch Centrum—Dermatology, Doctor Molewaterplein 40, 3015 GD Rotterdam, The Netherlands.  
 Email: [m.b.a.vandoorn@erasmusmc.nl](mailto:m.b.a.vandoorn@erasmusmc.nl)

## Abstract

**Objectives:** The treatment of recalcitrant keloids is challenging. Although intralesional bleomycin using conventional needle injectors (CNI) is effective, it has important drawbacks, such as the need for repetitive and painful injections. Therefore, we aimed to evaluate the effectiveness, tolerability and patient satisfaction of intralesional bleomycin with lidocaine administered with a needle-free electronically-controlled pneumatic jet-injector (EPI) in recalcitrant keloids.

**Methods:** This retrospective study included patients with recalcitrant keloids who had received three intralesional EPI-assisted treatments with bleomycin and lidocaine. Effectiveness was assessed using the Patient and Observer Scar Assessment Scale (POSAS) at baseline and four to six weeks after the third treatment. Additionally, treatment related pain scores numeric rating scale, adverse effects, patient satisfaction and Global Aesthetic Improvement Scale (GAIS) were assessed.

**Results:** Fifteen patients with a total of >148 recalcitrant keloids were included. The median total POSAS physician- and patient-scores were respectively 40 and 41 at baseline, and reduced with respectively 7 and 6-points at follow-up ( $p < 0.001$ ;  $p < 0.001$ ). The median pain scores during EPI-assisted injections were significantly lower compared to CNI-assistant injections, (2.5 vs. 7.0, respectively ( $p < 0.001$ )). Adverse effects were mild. Overall, patients were “satisfied” or “very satisfied” with the treatments (14/15, 93.3%). The GAIS was “very improved” in one patient, “improved” in nine patients and “unaltered” in four patients.

**Conclusions:** EPI-assisted treatment with bleomycin and lidocaine is an effective, well tolerated, patient-friendly alternative for CNI in patients with recalcitrant keloid scars. Randomized controlled trials are warranted to confirm our findings and improve the clinical management of recalcitrant keloids.

## KEYWORDS

bleomycin, drug delivery, jet injector, keloid, needle-free, scar

## INTRODUCTION

Keloids are hyperproliferative scars that extend beyond the confines of the original wound or trauma and are caused by chronic localized dermal inflammation.<sup>1,2</sup> Keloids can cause both physical and psychosocial distress.<sup>3</sup> The Quality of Life (QoL) of patients can be severely affected by symptoms such as pain, pruritus, functional impairment and physical appearance.<sup>4</sup>

Keloidal scars are characterized by an overproduction of extracellular matrix components, including collagen, elastin, fibronectin, and proteoglycans.<sup>5</sup> The pathogenesis of keloid scars is not completely understood and entails a combination of genetic and environmental factors, with a higher incidence observed among individuals with darker skin tones.<sup>6–8</sup> Current hypotheses suggest that the reticular dermis plays a vital role in the development of these scars.<sup>9</sup> Trauma or inflammation of the skin can trigger a chronic low grade inflammatory response within this part of the dermis.<sup>2</sup> This inflammatory response involves activation of fibroblasts and a number of cytokines, including IL-6, IL-8, and IL-10, alongside several growth factors. Subsequently, the activation of fibroblasts induces neovascularization and increased deposition of collagen, ultimately leading to keloid formation.<sup>10</sup>

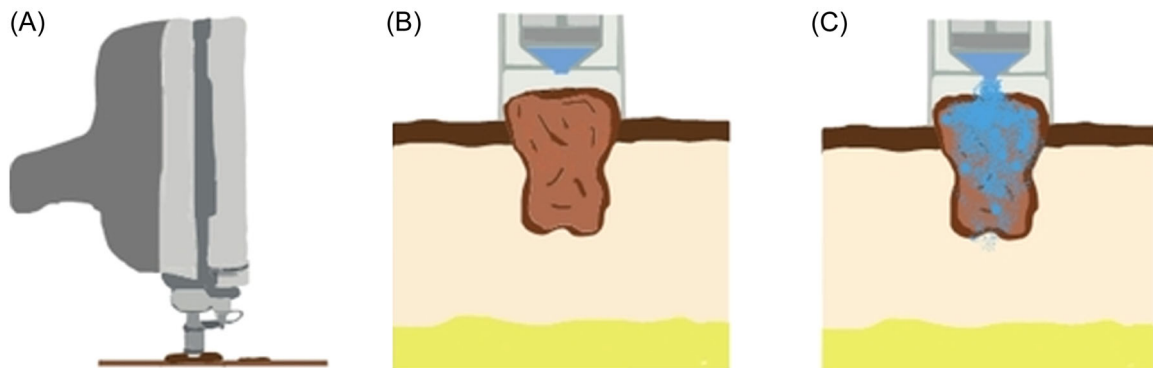
The first line treatment of keloids consists of intralesional needle injections with corticosteroids.<sup>11</sup> Unfortunately, these injections often cause significant procedure related pain and are unsuitable for patients with needle phobia, which occurs in up to 30% of young adults.<sup>9</sup> Furthermore, the firm consistency of the keloid can hamper the intralesional delivery of drugs and may lead to reduced effectiveness.<sup>12</sup> Although treatment with corticosteroids is effective in most patients, there is a high risk for recurrences, which are reported to occur in up to 50% of patients after 12 months.<sup>13</sup> Finally, some patients do not respond to intralesional corticosteroid

injections.<sup>14</sup> These limitations underline the need for more effective, safe, and patient-friendly treatment options with long-lasting benefit in this difficult to treat population.

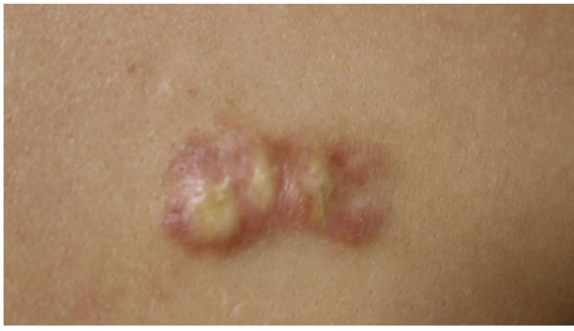
Needle-free electronically controlled pneumatic jet injectors (EPI) are an innovative and less painful alternative for intralesional injections with conventional needles.<sup>15</sup> These devices create a high-velocity fluid stream that penetrates the epidermis to inject drugs intralesionally (Figure 1). In contrast to needle-free spring-driven jet injectors, EPI allow the adjustment of settings such as volume and pressure.<sup>15</sup> A recent study demonstrated the high effectiveness, good tolerability, and patient satisfaction of intralesional EPI-assisted triamcinolone acetonide (TCA) treatment in keloids.<sup>16</sup>

Bleomycin could potentially be used as an alternative drug for the intralesional treatment of recalcitrant keloids. It is an antineoplastic antibiotic that has been used off-label for various dermatological indications (e.g., hemangiomas, hypertrophic scars, Kaposi sarcoma, and warts) with satisfactory results.<sup>17</sup> The therapeutic effect of bleomycin is attributed to its ability to induce DNA destruction, apoptosis of the cell and inhibition of the collagen synthesis by decreasing a.o. TGF- $\beta$ 1, an important cytokine in immunoregulation, wound healing, angiogenesis and cancer.<sup>18</sup> Previous studies have demonstrated that Intralesional bleomycin delivered with conventional needles is associated with a significantly lower risk of recurrence compared to intralesional corticosteroids in the treatment of keloids.<sup>19</sup> Lidocaine is usually added to intralesional bleomycin to reduce pain at the injection site and to increase the intracellular uptake of bleomycin.<sup>20</sup>

EPI-assisted intralesional administration of bleomycin with lidocaine, could be a suitable alternative treatment for patients with recalcitrant keloids that have previously failed or discontinued intralesional corticosteroid therapy or experienced a fast recurrence.



**FIGURE 1** Illustration of an electronically-controlled pneumatic jet injector-assisted treatment with bleomycin and lidocaine in a keloid scar. (A) Before administering treatment, the electronically-controlled pneumatic jet injector (EPI) hand piece with the injector tip is placed perpendicularly on the keloid scar. (B) A cross-sectioned illustration of the injector tip and nozzle of an EPI-device. The liquid container within the EPI contains a solution with the combination of bleomycin and lidocaine (depicted in blue). (C) Illustration during injection. The EPI device generates a high-velocity jet stream that punctures the epidermis of the keloid, disperses the combination of bleomycin and lidocaine in the mid-deep dermis and creates visible skin papule or blanching.



**FIGURE 2** Keloid of a 28-year-old patient, directly after EPI-assisted treatment with bleomycin and lidocaine, with blanching observed as clinical endpoint. The paler regions within the keloid indicate successful administration of medication. EPI, electronically controlled pneumatic jet injector.

Therefore, in this retrospective cohort study, we aimed to investigate the effectiveness, safety and patient satisfaction of EPI-assisted intralesional bleomycin with lidocaine in patients with recalcitrant keloids.

## MATERIALS AND METHODS

### Study design and population

This retrospective cohort study was performed at the Department of Dermatology at Erasmus University Medical Center (Erasmus MC) in Rotterdam, The Netherlands from November 2022 until May 2023. All adult patients with the presence of  $\geq 1$  recalcitrant keloid scar defined as a history of suboptimal treatments (resistance to multiple intralesional TCA injections with conventional needle injectors (CNI) or EPI, needle phobia or needle pain) were eligible for inclusion. The Medical Ethical Research Committee of Erasmus MC in Rotterdam approved the study (MEC-2021-0661). STROBE guidelines were followed. Written informed consent was obtained from all patients for the anonymous use of their clinical data and photographs.

### Data collection and outcome measures

Electronical medical records were used for data collection. The primary objective was to assess clinical effectiveness using the Patient and Observer Scar Assessment Scale (POSAS).<sup>21,22</sup> The POSAS score is a scar assessment tool that measures the quality of a scar.<sup>22</sup> A local standard operating procedure (SOP) for EPI-assisted bleomycin treatment in adult patients with keloids was followed. According to this SOP, the POSAS was used to evaluate the keloids by the treating physicians (V. B.; P. A.) and patients during treatment regular visits to the outpatient clinic at baseline and four

to six weeks after the third treatment. The POSAS score consists of six items concerning patient symptoms and clinical characteristics of the keloid. The patient and clinician can score the items from 1 (normal skin) to 10 (worst imaginable abnormality) points. The sum of these items gives the total POSAS score of minimum 6 and maximum of 60 points.

The secondary objectives included tolerability, patient satisfaction and aesthetic appearance. These objectives were evaluated using treatment-related pain scores (numeric rating scale [NRS] range 0–10), adverse effects which were recorded at each visit by the treating physician, a patient satisfaction questionnaire and the Global Aesthetic Improvement Score (GAIS), respectively. The GAIS measures the improvement of a scar compared to pretreatment, which consists of five degrees: exceptional improvement, very improved patient, improved patient, unaltered patient, and worsened patient.<sup>23</sup> An online questionnaire to measure patient satisfaction was conducted at follow-up and was created with LimeSurvey version 2.06 (LimeSurvey GmbH, Hamburg, Germany).<sup>24</sup>

### Treatment

During a regular outpatient visit, a test treatment with intralesional bleomycin combined with lidocaine was administered using respectively an EPI (Enerjet 2.0, Perfaction, Rehovot, Israel) and a CNI (27 gauge) in two similar keloids according to a local SOP. Treatment related pain scores on a numerical rating scale (NRS; range 0–10) during EPI and needle injections and patient preferences were recorded by the treating physician after the test treatment. Depending on pain scores and patient preferences, treatment with either EPI or CNI was chosen as delivery method for the consecutive treatments. All patients who received a test treatment with EPI and CNI, were included in this study.

Needle injections with 0.5–3 mL bleomycin mixed with lidocaine (1 USP/mL bleomycin in 5 mg/mL lidocaine and NaCl 0.9%) were used for the intradermal treatment. For EPI an injection volume of 100  $\mu$ L (device range: 50–130  $\mu$ L) and pressure level of 3.2 Bar (device range: 2–6 Bar) were pre-selected for each treatment. In firmer keloids, the pressure was increased with 10% per injection until a consistent papule or blanching (clinical endpoint) was visible after injection (Figure 2). Each EPI-assisted injection was administered in a 1 cm<sup>2</sup> surface area. Clinical photographs of all keloid scars were taken at each visit.

### Statistical analysis

All data were analyzed using SPSS 28.0 (IB). The Wilcoxon signed-rank test was employed to evaluate

the change in median POSAS scores at baseline and follow-up and procedure-related pain scores. Descriptive statistics were presented as median and IQR. A  $p$  Value of  $\leq 0.05$  was considered statistically significant.

## RESULTS

### Patient characteristics

A total of fifteen patients (eight female) with a median age of 28 (IQR 22–41) years and in total >148 keloids were included (Table 1). The majority of patients (73%, 11/15) had Fitzpatrick skin type three or four. All patients had an extensive treatment history, with at least multiple intralesional triamcinolone acetonide (TCA) treatments by CNIs.

### Treatment

Fourteen out of 15 patients (93%) completed the course of three consecutive intralesional EPI assisted treatments and visited the outpatient clinic at a four to six weeks follow-up. One patient (7%) discontinued after two treatments due to a pregnancy wish. Most patients (80%, 12/15) were treated with a pressure ranging from 3 to 4 bar. In the remaining patients (20%, 3/15), a firmer keloid structure required a higher pressure of 4–5 bar to reach the clinical endpoint and achieve dermal distribution. The median interval between treatment was 5 weeks (IQR: 4–6) (Table S1).

### Effectiveness

The POSAS observer scores and patient scores were significantly improved at follow-up compared to baseline (Table 2 and Figure 3). The median total POSAS observer score was 40 (IQR 29–51) at baseline, and the median paired difference at follow-up compared to baseline was  $-7$  ( $-18\%$ ; IQR  $-11$  to  $-3$ ) points ( $p < 0.001$ ). Similarly, the median total POSAS patient score was 41 (IQR 37–47) at baseline, and the median paired difference at follow-up compared to baseline was  $-6$  ( $-15\%$ ; IQR  $-13$  to  $-3$ ) points ( $p < 0.001$ ). The POSAS observer scale demonstrated a significant improvement in the subcategories “relief” and “overall opinion” ( $p = 0.002$ ;  $p = 0.019$ ), while the POSAS patient scale showed a significant improvement in the subcategories “itch,” “stiffness,” and “thickness” ( $p = 0.049$ ;  $p = 0.006$ ;  $p = 0.023$ ). The GAIS score showed that 10 out of 14 patients (71%) exhibited “improved” or “very improved” treatment outcomes, and four out of 14 patients (29%) showed “unaltered” results (Table S2 and Figure 4).

**TABLE 1** Baseline characteristics.

Characteristic	N (%) N = 15
Sex	
Female	8 (53.3%)
Age, median (Q1–Q3)	28 (22–41)
<i>Fitzpatrick skin type</i>	
1–2	1 (6.7%)
3–4	11 (73.3%)
5–6	3 (20.0%)
<i>Number of lesions</i>	
1–10	8 (53.3%)
10 $\geq$ 30	4 (26.7%)
>30	3 (20.0%)
<i>Anatomical location<sup>a</sup></i>	
Abdomen	1 (6.7%)
Shoulder(s)/back	13 (86.7%)
Thorax	7 (46.7%)
<i>Etiology<sup>a</sup></i>	
Acne	7 (46.7%)
Trauma/surgery	5 (33.3%)
Spontaneous/unknown	4 (26.7%)
<i>Previous treatments<sup>a</sup></i>	
Brachytherapy	3 (20.0%)
Cryotherapy	2 (13.3%)
Intralesional bleomycin treatments	6 (40.0%)
Intralesional TCA treatments	15 (100.0%)
Shave excision	5 (33.3%)
Silicon sheeting	4 (26.7%)
Vascular or ablative laser treatment	6 (40.0%)
<i>Pressure EPI</i>	
3–4 bar	12 (40.0%)
4–5 bar	3 (40.0%)
<i>Motivation for EPI + bleomycin treatment<sup>a</sup></i>	
Needle-phobia	5 (33.3%)
Recurrence after initial efficacy	6 (40.0%)
Severe pain during needle injections	7 (46.7%)
Suboptimal or no results after previous treatments	15 (100.0%)

Abbreviations: EPI, electronically-controlled pneumatic injector; Needle, needle-syringe injection; TCA, triamcinolone acetonide.

<sup>a</sup>Multiple combinations possible.

**TABLE 2** Clinical improvement assessment using POSAS.

Baseline, $n = 14^a$			
	Median (Q1–Q3)	Median in difference <sup>b</sup>	<i>p</i> Value
Vascularity	7 (5–8)	–2 (–2 to 0)	0.159
Pigmentation	6 (4–8)	1 (0–1)	0.380
Thickness	6 (4–8)	–2 (–2 to –1)	0.354
Relief	6 (5–8)	–1 (–2 to 0)	0.081
Pliability	7 (5–8)	–2 (–3 to –1)	0.002
Surface area	6 (4–8)	–1 (–1 to 0)	0.070
Overall assessment	7 (5–8)	–1 (–2 to –1)	0.019
Total POSAS observer scale	40 (29–51)	–7 (–11 to –3)	<0.001
Baseline, $n = 15$			
	Median (Q1–Q3)	Median in differences <sup>b</sup>	<i>p</i> Value
Pain	4 (2–5)	–1 (–2 to 0)	0.144
Itching	7 (5–8)	–2 (–3 to 0)	0.049
Color	8 (7–10)	0 (–2 to 1)	0.435
Stiffness	8 (6–8)	–1 (–2 to 0)	0.006
Thickness	8 (7–9)	–1 (–2 to 0)	0.023
Irregularity	8 (6–9)	–1 (–2 to 0)	0.205
Overall opinion	8 (7–10)	0 (0–1)	0.054
Total POSAS patient scale	41 (37–47)	–6 (–13 to –3)	<0.001

Abbreviation: POSAS, Patient and Observer Scar Assessment Scale.

<sup>a</sup>One patient ( $n = 1$ ) was missing due to the patient's pregnancy wish.

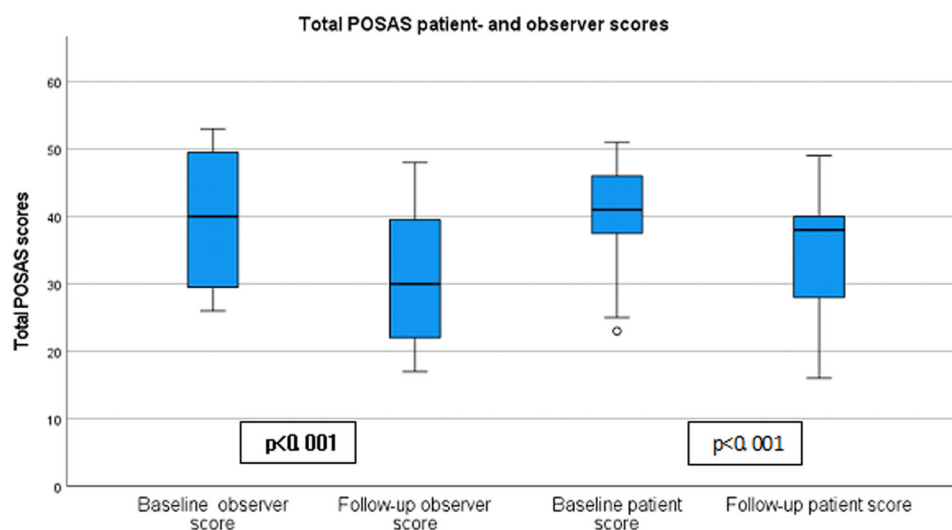
<sup>b</sup>Median in differences is the median change of paired observations before and after treatment.

## Tolerability

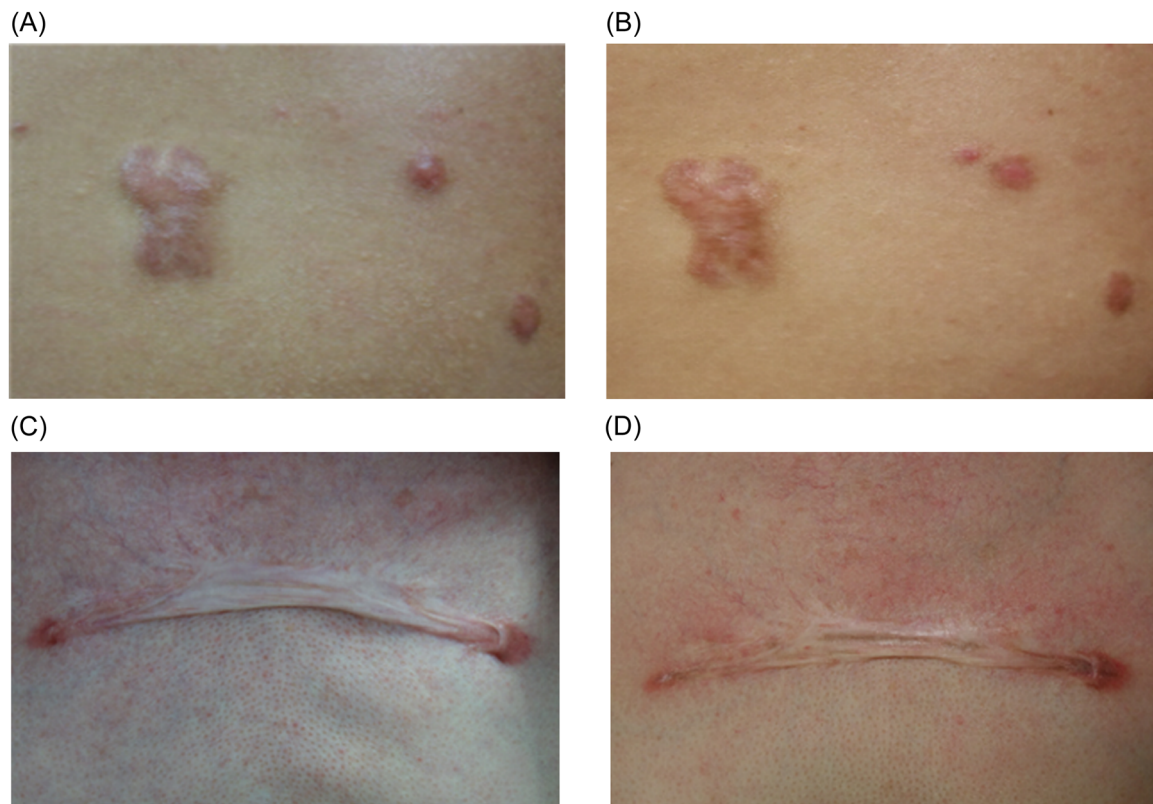
The median NRS pain score during the test treatment was significantly lower with the EPI compared to conventional needle injections (2.0 [IQR 1.5–2.5] vs. 7.0 [IQR 5.5–9.0],  $p < 0.001$ ) (Table S3). The median pain score for all consecutive EPI-assisted treatments was 3.0 (IQR 2.0–5.0). The most frequently (40%, 6/15) reported adverse event was local hyperpigmentation (Table S4). Other local and transient adverse effects after treatment included local pain and sensitivity (13%, 2/15), transient local itching (7%, 1/15), hematoma (20%, 3/15), scab formation (13%, 2/15) and acneiform inflammation of the keloid (7%, 1/15). No severe adverse reactions were reported.

## Patient satisfaction

All patients completed the patient satisfaction questionnaire. All patients recommended the EPI-assisted treatment with the combination of bleomycin and lidocaine to others, and preferred EPI treatment over treatment with hypodermic needles (Table S5). Less pain during treatment was the most frequently mentioned reason for this preference (87%, 13/15). Other reasons for EPI preference included better clinical results (67%, 10/15) and shorter treatment visits (33%, 5/15). Fourteen out of 15 patients (93%) were “satisfied” or “very satisfied” with the EPI-assisted treatments, while one patient rated her/his treatment satisfaction as “neutral” (7%). Eleven out of 15 patients (73%) stated that itching was reduced after treatment, and 12 out of 15 patients (80%) reported that the pain of the keloid was reduced after treatment.



**FIGURE 3** Clinical effectiveness assessed with Patient and Observer Scar Assessment Scale (POSAS) at baseline and after three consecutive treatments with bleomycin and lidocaine using an EPI. Based on the total POSAS scale, patients and physicians reported a significant improvement in the keloids at follow-up. EPI, electronically-controlled pneumatic jet-injector.



**FIGURE 4** Clinical images of keloids before and after EPI-assisted treatment with bleomycin and lidocaine. (A) Keloid lesions on the shoulder before treatment. (B) Keloid lesions on the shoulder after three EPI-assisted bleomycin treatments. The GAIS was assessed as “improved.” (C) Keloid lesion on the chest before treatment. (D) Keloid lesion on the chest after three EPI-assisted bleomycin treatments. The GAIS was assessed as “very improved.” EPI, electronically-controlled pneumatic jet-injector; GAIS, Global Aesthetic Improvement Scale

Postinjection hyperpigmentation was reported by three patients (20%), which was cosmetically disturbing in two patients (13%). One patient (7%) expressed discomfort due to the noise produced by the EPI device during injection.

## DISCUSSION

In this study we show that-EPI assisted treatment with bleomycin and lidocaine is effective in patients with recalcitrant keloids and yielded significantly lower NRS pain scores compared to conventional needle injections. Total POSAS scores after three consecutive treatments were statistically significantly reduced compared to baseline, from both patient and observer perspectives. The sub-categories “itch,” “stiffness” and “thickness” were significantly improved according to the patients, while “pliability” and “overall opinion” with regard to keloid quality were significantly improved according to treating physicians. Only minor adverse effects were observed, of which local hyperpigmentation was most common. Patients were highly satisfied with their treatment and would recommend the treatment to

others, presumably because of the reduced injection related pain.

Previously, Bik et al.<sup>16</sup> and Erlendson et al.<sup>25</sup> investigated the effectiveness, tolerability, and patient satisfaction of intralesional EPI-assisted TCA and 5-Fluorouracil, respectively. Notably, in the study by Bik et al., patients who received intralesional TCA with an EPI for their keloids reported an average pain score of 4.3 during the first treatment, which exceeds the median pain score of 2.0 (IQR 1.5–2.5) observed in our study. The lower pain scores in our patients may be attributed to the use of a mixture of bleomycin with lidocaine. The local anesthetic lidocaine, acting as an additional pain-reducing treatment in conjunction with the jet injector, could lead to a remarkable reduction in procedure-related pain (Table S3; NRS pain during needle-assisted bleomycin injection: 7.0). On the other hand, our findings with regard to pain scores show similarity to the findings of the randomized controlled study by Erlendson et al., in which also a median NRS pain score of 2.0 (IQR 2.0–2.0) was found, without the usage of lidocaine. However, in this study also patients with hypertrophic scars were included, which are usually less painful upon injection than (severe) keloids.<sup>26</sup>

In our study we observed a relatively modest decrease in total POSAS patient- and observer scores after three treatments with EPI-assisted bleomycin and lidocaine, with respectively 15% and 18%. This reduction was substantially smaller compared to EPI-assisted TCA in Bik et al. (POSAS reduction of resp. 27% and 34%) and spring loaded jet injector-assisted bleomycin in Saray et al. (complete flattening in 73.3%).<sup>16,27</sup> These discrepancies could be related to the characteristics of the keloids in our patient population. The patients analyzed in this retrospective study had recalcitrant keloids with a more extensive treatment history, and more severe pain and pruritus at baseline compared with the patients in the studies by Bik et al. and Saray et al. Importantly, some of the patients who were challenging to treat with EPI-assisted TCA, did show good clinical improvement in this study. Moreover, although there is no clear difference between the median total POSAS patient scores before and after treatment in our study, it is important to note the relevant shift in the spread of the interquartile range before and after treatment (Figure 3).

However, in our clinic, for safety reasons, patients are treated with a bleomycin and lidocaine solution of 1 USPE/mL, with a maximum dose of 3 mL. This concentration is lower than 1.5 IU/mL, the concentration that is commonly used in clinical studies with bleomycin, for example, in the study of Saray et al.<sup>27</sup> While increasing the bleomycin concentration could potentially improve efficacy, caution must be exercised due to the high rate of necrosis and ulceration associated with higher doses of bleomycin.<sup>28</sup> In addition, treating physicians regularly observed a considerable amount of spilled volume, noticeable as a residue of the medication on the treated skin. This unintended spill may have led to a lower administered dose than intended, potentially impacting treatment outcomes.

Remarkably, four out of 15 patients did not show any improvement post-treatment. In retrospect, these non-responders had considerably thicker, stiffer and larger keloids than the other patients. Furthermore, all of the non-responders had previously undergone a minimum of five different types of treatments. Presumably, larger and thicker keloids are more resistant to any type of treatment. However, this observation remains a hypothesis, and further research is necessary to investigate the effect of morphological features on treatment outcomes.

A common adverse effect of intralesional bleomycin injections is local hyperpigmentation at the injection site. This was also observed in our study; six out of 15 patients developed hyperpigmentation (Table S4). Interestingly, only three patients noticed the hyperpigmentation (Table S5). This may be due to the location of the keloids, as those on the shoulders or back may be harder to detect. Furthermore, physicians may be more aware of adverse effects than patients.

This study represents the first evaluation of the effectiveness of EPI-assisted intralesional bleomycin

combined with lidocaine treatment in recalcitrant keloid scars. The patients included in our analysis, represent a severely affected patient population who suffer from recalcitrant keloids and, although the sample size is limited, the study findings provide important insight into the effectiveness of this treatment approach in recalcitrant keloids.

A strength of our study is the real world setting and patient-oriented approach. As previously noted, patients with keloids often experience a reduced QoL due to the various symptoms that are associated with this disease.<sup>4,29</sup> By analyzing the patient's perspective on their treatment experiences and outcomes, optimal treatment modalities can be identified that align with the individual patient's needs and preferences.

Limitations of our study are the lack of a control group, and the short follow-up time which precluded the assessment of the recurrence rate of keloids after EPI-assisted bleomycin treatment. Furthermore, the limited sample size of 15 patients may restrict the generalizability of our findings. Although our results are promising, the administration of intralesional bleomycin might be limited in general practice because the off-label status with limited availability. Moreover, jet-injector assisted administration of chemotherapeutics such as bleomycin can cause the formation of potentially harmful aerosols. Therefore, adequate protective safety measures are required, including the use of goggles, gloves, and mechanical room ventilation with FFP-2/FFP-3/N95 masks or smoke evacuators which can adequately capture these aerosols.<sup>30</sup> Moreover, bleomycin should not be administered to pregnant or lactating women, and should also not be administered by healthcare workers that are pregnant or lactating. For this reason, it is important to inform patients and healthcare personal about the potential health hazards of chemotherapeutics such as bleomycin. In conclusion, we found that needle-free EPI assisted intralesional treatment with bleomycin and lidocaine is effective, well-tolerated and has a high treatment satisfaction in patients with recalcitrant keloids. Future high quality randomized controlled trials are warranted to confirm our results and improve the clinical management of patients with recalcitrant keloid scars.

## AUTHOR CONTRIBUTIONS

The authors confirm contribution to the paper as follows: *Study conception and design:* Vazula Zulfra Bekkers and Martijn Bastiaan Adriaan van Doorn. *Data collection:* Vazula Zulfra Bekkers, Fatima Khan and Pim Aarts. *Analysis:* Vazula Zulfra Bekkers. *Interpretation of results:* Vazula Zulfra Bekkers, Fatima Khan, Pim Aarts, Katarzyna Zdunczyk, Errol Prospero Prens, Albert Wolkerstorfer, Errol Prospero Prens, Robert Rissmann, and Martijn Bastiaan Adriaan van Doorn. *Draft manuscript preparation:* Vazula Zulfra Bekkers and Fatima Khan. All authors reviewed the results and approved the final version of the manuscript.

## ACKNOWLEDGMENTS


We would like to thank statistician R. Bohoslavsky (Center for Human Drug Research) for his valuable assistance with statistical inquiries.

## CONFLICT OF INTEREST STATEMENT

The EnerJet device was provided to Erasmus Medical Center and Amsterdam University Medical Centers by PerfAction as part of a research collaboration.

## ORCID

Vazula Zulfra Bekkers  <http://orcid.org/0000-0002-5554-6743>

Martijn Bastiaan Adriaan van Doorn  <http://orcid.org/0000-0003-1672-7899>

## REFERENCES

- Uitto J. IL-6 signaling pathway in keloids: a target for pharmacologic intervention? *J Invest Dermatol.* 2007;127(1):6–8. <https://doi.org/10.1038/sj.jid.5700604>
- Ogawa R. Keloid and hypertrophic scars are the result of chronic inflammation in the reticular dermis. *Int J Mol Sci.* 2017;18(3):606.
- Ogawa R, Akita S, Akaishi S, Aramaki-Hattori N, Dohi T, Hayashi T, et al. Diagnosis and treatment of keloids and hypertrophic Scars-Japan scar workshop consensus document 2018. *Burns Trauma.* 2019;7:39. <https://doi.org/10.1186/s41038-019-0175-y>
- Sitaniya S, Subramani D, Jadhav A, Sharma YK, Deora MS, Gupta A. Quality-of-life of people with keloids and its correlation with clinical severity and demographic profiles. *Wound Repair Regen.* 2022;30(3):409–16. <https://doi.org/10.1111/wrr.13015>
- Halim AS, Emami A, Salahshourifar I, Kannan TP. Keloid scarring: understanding the genetic basis, advances, and prospects. *Arch Plast Surg.* 2012;39(3):184–9. <https://doi.org/10.5999/aps.2012.39.3.184>
- Chike-Obi C, Cole P, Brissett A. Keloids: pathogenesis, clinical features, and management. *Semin Plast Surg.* 2009;23(3):178–84. <https://doi.org/10.1055/s-0029-1224797>
- Nakashima M, Chung S, Takahashi A, Kamatani N, Kawaguchi T, Tsunoda T, et al. A genome-wide association study identifies four susceptibility loci for keloid in the Japanese population. *Nature Genet.* 2010;42(9):768–71. <https://doi.org/10.1038/ng.645>
- Kiprono SK, Chaula BM, Masenga JE, Muchunu JW, Mavura DR, Moehrl M. Epidemiology of keloids in normally pigmented Africans and African people with albinism: population-based cross-sectional survey. *Br J Dermatol.* 2015;173(3):852–4. <https://doi.org/10.1111/bjd.13826>
- Amadeu T, Braune A, Mandarim-de-Lacerda C, Porto LC, Desmoulière A, Costa A. Vascularization pattern in hypertrophic scars and keloids: a stereological analysis. *Pathology - Research and Practice.* 2003;199(7):469–73. <https://doi.org/10.1078/0344-0338-00447>
- Berman B, Maderal A, Raphael B. Keloids and hypertrophic scars: pathophysiology, classification, and treatment. *Dermatol Surg.* 2017;43(Suppl 1):S3–S18. <https://doi.org/10.1097/DSS.0000000000000819>
- Morelli Coppola M, Salzillo R, Segreto F, Persichetti P. Triamcinolone acetonide intralesional injection for the treatment of keloid scars: patient selection and perspectives. *Clin Cosmet Investig Dermatol.* 2018;11:387–96. <https://doi.org/10.2147/CCID.S133672>
- Sproat JE, Dalcin A, Weitauer N, Roberts RS. Hypertrophic sternal scars: silicone gel sheet versus kenalog injection treatment. *Plast Reconstr Surg.* 1992;90(6):988–92.
- Ogawa R. The most current algorithms for the treatment and prevention of hypertrophic scars and keloids. *Plast Reconstr Surg.* 2010;125(2):557–68. <https://doi.org/10.1097/PRS.0b013e3181c82dd5>
- Ud-Din S, Bowring A, Derbyshire B, Morris J, Bayat A. Identification of steroid sensitive responders versus non-responders in the treatment of keloid disease. *Arch Dermatol Res.* 2013;305(5):423–32. <https://doi.org/10.1007/s00403-013-1328-7>
- Logomasini MA, Stout RR, Marcinkoski R. Jet injection devices for the needle-free administration of compounds, vaccines, and other agents. *Int J Pharm Compd.* 2013;17(4):270–80.
- Bik LEI, Wolkerstorfer A, Prens E, van Doorn MBA. Needle-free electronically-controlled jet injection with corticosteroids in recalcitrant keloid scars: a retrospective study and patient survey [Submitted]. 2022.
- Bik L, Sangers T, Greveling K, Prens E, Haedersdal M, van Doorn M. Efficacy and tolerability of intralesional bleomycin in dermatology: a systematic review. *J Am Acad Dermatol.* Sep 2020;83(3):888–903. <https://doi.org/10.1016/j.jaad.2020.02.018>
- Viera MH, Caperton CV, Berman B. Advances in the treatment of keloids. *J Drugs Dermatol.* 2011;10(5):468–80.
- Khan HA, Sahibzada MN, Paracha MM. Comparison of the efficacy of intralesional bleomycin versus intralesional triamcinolone acetonide in the treatment of keloids. *Dermatol Ther.* 2019;32(5):e13036. <https://doi.org/10.1111/dth.13036>
- Saitta P, Krishnamurthy K, Brown LH. Bleomycin in dermatology: a review of intralesional applications. *Dermatol Surg.* 2008;34(10):1299–313.
- Callan P, Halstead M, Rogers I, Goodman G, Liew S, Muzikants P, et al. Efficacy and safety of a hyaluronic acid filler in subjects treated for correction of midface volume deficiency: a 24 month study. *Clin Cosmet Investig Dermatol.* 2013;6:81–9. <https://doi.org/10.2147/CCID.S40581>
- van de Kar AL, Corion LUM, Smeulders MJC, Draaijers LJ, van der Horst CMAM, van Zuijlen PPM. Reliable and feasible evaluation of linear scars by the patient and observer scar assessment scale. *Plast Reconstr Surg.* 2005;116(2):514–22. <https://doi.org/10.1097/01.prs.0000172982.43599.d6>
- Dibernardo GA, DiBernardo BE. Prediction of treatment outcomes for neck rejuvenation utilizing a unique classification system of treatment approach using a 1440-nm Side-Firing laser. *Aesthet Surg J.* 2018;38:S43–51. <https://doi.org/10.1093/asj/sjy066>
- Limesurvey GmbH. LimeSurvey: an Open Source survey tool/ LimeSurvey GmbH, Hamburg, Germany. 2023. <http://www.limesurvey.org>
- Erlendsson AM, Rosenberg LK, Lerche CM, Togsverd-Bo K, Wiegell SR, Karmisholt K, et al. A one-time pneumatic jet-injection of 5-fluorouracil and triamcinolone acetonide for treatment of hypertrophic scars-A blinded randomized controlled trial. *Lasers Surg Med.* 2022;54(5):663–71. <https://doi.org/10.1002/lsm.23529>
- Ghazawi FM, Zargham R, Gilardino MS, Sasseville D, Jafarian F. Insights into the pathophysiology of hypertrophic scars and keloids: how do they differ? *Adv Skin Wound Care.* 2018;31(1):582–95. <https://doi.org/10.1097/01.ASW.0000527576.27489.0f>
- Saray Y, Güleç AT. Treatment of keloids and hypertrophic scars with dermojet injections of bleomycin: a preliminary study. *Int J Dermatol.* 2005;44(9):777–84. <https://doi.org/10.1111/j.1365-4632.2005.02633.x>
- Kim WI, Kim S, Cho SW, Cho MK. The efficacy of bleomycin for treating keloid and hypertrophic scar: a systematic review and meta-analysis. *J Cosmet Dermatol.* 2020;19(12):3357–66. <https://doi.org/10.1111/jocd.13390>
- Bijlard E, Kouwenberg C, Timman R, Hovius S, Busschbach J, Mureau M. Burden of keloid disease: a cross-sectional health-related quality of life assessment. *Acta Derm Venereol.* 2017;97(2):225–9. <https://doi.org/10.2340/00015555-2498>



30. Bik L, Wolkerstorfer A, Bekkers V, Prens EP, Haedersdal M, Bonn D, et al. Needle-free jet injection-induced small-droplet aerosol formation during intralesional bleomycin therapy. *Lasers Surg Med.* 2022;54(4):572–9. <https://doi.org/10.1002/lsm.23512>

### SUPPORTING INFORMATION

Additional supporting information can be found online in the Supporting Information section at the end of this article.

**How to cite this article:** Bekkers VZ, Khan F, Aarts P, Zdunczyk K, Prens EP, Wolkerstorfer A, et al. Needle-free electronically-controlled jet injector treatment with bleomycin and lidocaine is effective and well-tolerated in patients with recalcitrant keloids. *Lasers Surg Med.* 2023;1–9. <https://doi.org/10.1002/lsm.23737>