



Singh, M., Singh, B., Jha, J., Passi, D., Sharma, A., & Goyal, J. (2023). Efficacy of bioresorbable plating system in the treatment of pediatric maxillary fractures: A short clinical study. *National Journal of Maxillofacial Surgery*, 14(1).  
[https://doi.org/10.4103/njms.NJMS\\_342\\_21](https://doi.org/10.4103/njms.NJMS_342_21)

Publisher's PDF, also known as Version of record

License (if available):  
CC BY-NC-SA

Link to published version (if available):  
[10.4103/njms.NJMS\\_342\\_21](https://doi.org/10.4103/njms.NJMS_342_21)

[Link to publication record in Explore Bristol Research](#)  
PDF-document

This is the final published version of the article (version of record). It first appeared online via Wolters Kluwer at [https://doi.org/10.4103/njms.NJMS\\_342\\_21](https://doi.org/10.4103/njms.NJMS_342_21). Please refer to any applicable terms of use of the publisher.

## University of Bristol - Explore Bristol Research

### General rights

This document is made available in accordance with publisher policies. Please cite only the published version using the reference above. Full terms of use are available:  
<http://www.bristol.ac.uk/red/research-policy/pure/user-guides/ebr-terms/>

# Efficacy of bioresorbable plating system in the treatment of pediatric maxillary fractures: A short clinical study

## ABSTRACT

**Aim:** The aim of this study was to evaluate the efficacy, stability, and clinical outcomes of a bioresorbable plating system in the treatment of pediatric maxillary fractures.

**Materials and Methods:** Twenty pediatric patients with maxillary fractures (13 males and 7 females) were included in this study. The 1.5- and 2.0-mm resorbable plates were used and secured with monocortical resorbable screws 6 mm and 7 mm in length. All patients were followed up for 6 months. Clinical parameters, such as pain, swelling, soft-tissue infection, malocclusion, nerve injury, and bite force for stability, were prospectively assessed.

**Results:** Fall from height (50%) was the most common cause of etiology, followed by road traffic accidents (35%). Maxillary alveolar # (40) was the most common fracture site, followed by nasal complex # (25%) and zygomatic complex # (25%). Appropriate fixation and adequate primary bone healing was achieved in 100% of the cases. Few minor complications were observed: (1) soft-tissue infection (5%) and (2) paresthesia (10%). There was a significant increase in bite force in the incisor and molar regions. Observation in clinical parameters shows that there was a significant reduction in postoperative pain and swelling at different follow-up periods.

**Conclusion:** Bioresorbable plating system is used as a load-sharing plate in a semirigid fixation technique after anatomic fracture reduction. Although its high costs limit its feasibility for use low infection rates, minimized second surgery for implant removal attracts its use. 1.5- and 2-mm resorbable plating system along is a good treatment modality for moderately displaced maxillary fractures in pediatric patients. Larger sample size and longer follow-up studies are required for conclusive results.

**Keywords:** Bioresorbable plating system, osteosynthesis, polyglycolide, poly-L-lactide

## INTRODUCTION

As lifestyles are changing and faster modes of transportation are available, these have to lead to an increase in the number of pan facial injuries all over the world, thereby necessitating better methods and advancements in treatment modalities in maxillofacial fractures.

The basic principles of any fracture treatment are reduction, fixation, immobilization, and control of infection. Traditional open methods of fracture fixation included wire osteosynthesis and metal bone plates. Open reduction and internal fixation with mini plates provided a secure and accurate anatomic reduction of fractures.<sup>[1]</sup>

Pan facial fracture in children is common these days due to trauma, sports injury and fall as young people are more attracted

**MAHINDER SINGH, BARJINDER SINGH, JYOTSNA JHA, DEEPAK PASSI<sup>1</sup>, ABHIMANYU SHARMA<sup>2</sup>, JYOTI GOYAL<sup>3</sup>**

Department of Oral and Maxillofacial Surgery, Uttaranchal Dental and Medical Research Institute, Dehradun, Uttarakhand, <sup>1</sup>Department of Dentistry, CHC Mirzapur, Azamgarh, Uttar Pradesh, <sup>2</sup>Department of Oral and Maxillofacial Surgery, ESIC Dental College and Hospital, <sup>3</sup>Department of Pediatric Surgery, All India Institute of Medical Sciences, New Delhi, India


**Address for correspondence:** Dr. Deepak Passi, CHC Mirzapur, Azamgarh, Uttar Pradesh, India. E-mail: drdeepakpassi@gmail.com

**Received:** 23 March 2021, **Revised:** 15 July 2021  
**Accepted:** 11 September 2021, **Published:** 14 April 2023

This is an open access journal, and articles are distributed under the terms of the Creative Commons Attribution-NonCommercial-ShareAlike 4.0 License, which allows others to remix, tweak, and build upon the work non-commercially, as long as appropriate credit is given and the new creations are licensed under the identical terms.

**For reprints contact:** WKHLRPMedknow\_reprints@wolterskluwer.com

**How to cite this article:** Singh M, Singh B, Jha J, Passi D, Sharma A, Goyal J. Efficacy of bioresorbable plating system in the treatment of pediatric maxillary fractures: A short clinical study. *Natl J Maxillofac Surg* 2023;14:86-92.

Access this article online	
<b>Website:</b> www.njms.in	<b>Quick Response Code</b> 
<b>DOI:</b> 10.4103/njms.NJMS_342_21	

toward the fast life. Fracture in children should be taken into different prospective as a child is a growing patient and unique. There are different modalities to treat mandibular fractures in children, such as IMF, circummandibular wiring, splint, and open reduction and internal fixation with mini plates.<sup>[2]</sup>

Since the 1980s, various fixation devices have been developed to achieve adequate strength and biocompatibility. Bone plating systems manufactured from stainless steel, titanium, etc., are available as monocortical and bicortical plates. Titanium and steel plates currently used for fixation of mandibular fractures provide adequate strength and rigidity but several potential postoperative problems persist with these systems including visibility or palpability, hardware loosening with resulting extrusion, bone atrophy caused by stress shielding and intracranial migration in cranio orbital surgery. It also produces artifact in computed tomographic (CT) and magnetic resonance imaging (MRI) and possible growth restriction in pediatric patients.<sup>[3,4]</sup>

Recently, biodegradable osteosynthesis materials have been increasingly marketed for clinical applications in the field of oral and maxillofacial surgery. Biodegradable plates and screws eliminate the need for removal operations and do not cause any more problems after total biodegradation. Biodegradable materials have been used for the fixation of various facial fractures and osteotomies. One significant advantage of resorbable screws in pediatric patients is the avoidance of potential odontogenic injury. As the drill hole and the tapping of the screw threads penetrate only the outer cortex, injury to developing teeth is unlikely. The rationale of using bioresorbable plates provides the excellent handling properties, strength, and degradation characteristics that best support a more natural healing process.<sup>[5]</sup>

Internal fixation with various bioresorbable materials has recently been studied by pioneers in the field and reported very high success rates with bioresorbable plates and screws. Biocompatible and bioresorbable poly( $\alpha$ -hydroxy acid) derivatives, namely poly-L-lactide (PLLA), polyglycolide (PGA), DL-PLA, L-lactide, and TMC-trimethylene carbonate, have been proposed as potential orthopedic repair materials. A new technologic advancement in biomaterials research has provided a copolymer of poly-L-lactic acid and glycolic acid (PLLA-PGA) in the field of craniofacial surgery. The strength, malleability, and resorption profile can be further favorably tailored by the incorporation of caprolactone, dioxanone, or TMC. These materials have a long history of safe clinical use.<sup>[6]</sup>

In the present study, pan facial fractures were treated by using a bioresorbable monocortical bone plating system. The study

was aimed at clinically evaluating the use of a bioresorbable plating system on pediatric patients with maxillary fractures reporting to the hospital.

## MATERIALS AND METHODS

Twenty cases were selected for the present study from the patients with traumatic injuries with midface fractures and mandible who reported to the outpatient department of oral and maxillofacial surgery of the institute over a period of 1½ years. An ethical approval was taken from the institutional ethical committee prior to the start of the study. Ethical Clearance was obtained from Institutional Ethics Committee with Ref no IEC/PA-09/2021 dated 13/02/2021.

Preoperatively, detailed histories of the patients were recorded. Careful examination of the soft tissues and underlying skeleton of the facial region was carried out to exclude any other associated injuries. The patients participating in this study were thoroughly informed about the treatment, and their consent was documented in a consent form. All patients received prophylactic antibiotic coverage and analgesics at the time of initial presentation. The radiographs were used to make a clinical diagnosis, location, and displacement of fracture, along with routine blood investigation.

All patients were admitted to the hospital before surgery. In the case of children above 10 years of age, Erich's arch bar or eyelet wires were placed on upper and lower standing teeth to stabilize the fracture segment and to achieve occlusion before plating. In the case of children, <10 years of age, either a splint was made after an impression or interdental eyelet wiring was done before surgery.

The inclusion criteria included patients up to 15 years of age with maxillofacial fractures.

The exclusion criteria included grossly comminuted fractures of the midface, pathological fractures of midface, grossly comminuted fractures of the mandible, pathological fractures of the mandible, fractures which were infected, patients having systemic diseases, and uncooperative patients.

Various surgical approaches were used for midface fractures and mandibular fractures were opened through the incision either intraorally or extraorally.

The plates and screws were supplied by the manufacturer in sterile double packing where the plates and screws had been gamma sterilized to produce a controlled drop in molecular weight and enhance degradation characteristics.

The plates were needed to be activated in the water bath to be contoured and properly adapted at room temperature for several minutes. The plates took approximately 1 min to be fully activated in the water bath at 55°C. Plate contouring and adaptation were carried out with plate bending pliers. The plates could be reactivated anytime during the procedure by re-immersion for an additional 15–60 s.

The screws of the bioresorbable 1.5-, 2-, and 2.5-mm systems were supplied mounted in a convenient screw ring having a simple push-fit pickup design for a very secure hold. The screw with the screwdriver was inserted and tightened slowly and gently [Figure 1].

The postoperative assessment of the patients was done on all the cases. Statistical analysis was done utilizing SPSS Statistics v.18.0 (SPSS Inc., Chicago, IL, United States). Differences between groups were examined, and the significance value was set at  $P < 0.05$  level.

## RESULTS

The present study was carried out in the department of oral and maxillofacial surgery. A total number of twenty patients with fractures of the midface and mandible were included in this study. All the patients underwent osteosynthesis using 1.5- and 2.0-mm bioresorbable plates with 6- and 7-mm screws. The healing of fracture was assessed clinically, radiographically, and biomechanically.

In the present study, fall from height (50%) was the most common cause of etiology, followed by road traffic

accidents (35%) and sports injury (15%). In the present study, the most common age group was 6–10 years which underwent surgery and comprised 45% of patients of the total patients. Age groups of 1–5 years and 11–15 years contribute to 25% and 30%, respectively. The mean age was 8.25 years. The male: female ratio was 1.85:1.

In the present study, 40% of the fracture was of maxillary alveolar #, which was the most common fracture site, followed by nasal complex # (25%), zygomatic complex # (25%), orbital # (5%), and Le Fort # (5%) [Table 1].

In the present study, preoperatively deranged occlusion was present in 17 patients (85%) while 3 patients (15%) had normal occlusion. Seventy percent of patients received 1.5 mm monocortical plate fixation with 6 mm monocortical screws and 30% of patients received 2.0 mm monocortical plate fixation with 7 mm monocortical screws [Table 2]. In the present study, majority of patients were treated within a time lapse of 5–8 days (64%). The mean time lapse between injury and definite management was seen to be 8.35 days. Preoperatively, infection was present in nine patients. Infection was present in the 3rd month in 1 patient and thereafter 4th follow up no infection present [Table 3]. Paresthesia was found in 2 patients with zygomatic complex # which remained for 2 weeks, and no paresthesia was found after the 3rd follow up [Table 4]. Stability was present in 7 patients (35%) at the 2nd week. Sixty five percent of patients had mobility at the 2nd week. No mobility was seen from the 3rd month and the last follow up [Table 5]. There was a significant increase in bite force at incisor at 3 months and 6 months, from the 2nd week onward [Table 6].

There was a significant increase in bite force in the right molar at different follow ups. There was a significant increase in bite force in the left molar at different follow ups with time. [Tables 7 and 8].

### Clinical evaluation

There was a significant reduction in pain at different follow ups (2 weeks, 3 months, and 6 months) from the initial pain. No pain was observed after 2 weeks–3 months and later on in any of the patients. There was a significant reduction in pain from initial to the 1st follow up. No pain was observed in the 2<sup>nd</sup>, 3<sup>rd</sup>, and 4<sup>th</sup> follow ups in any of the patients [Tables 9 and 10]. Swelling decreased significantly at different follow ups till 6 months [Table 11].

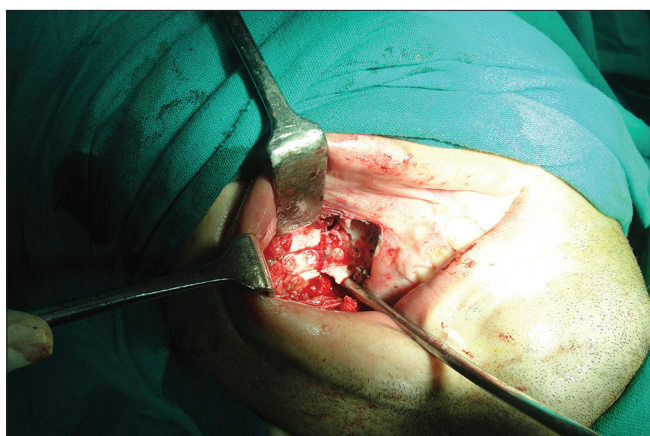


Figure 1: Intra-operative view of Bioresorbable plate fixed with screws

Table 1: Anatomical distribution of fracture site

	Fracture site #					Total
	Maxillary alveolar #	Nasal complex #	Zygomatic complex #	Orbital #	Le Fort #	
Number of patients (%)	8 (40)	5 (25)	5 (25)	1 (5)	1 (5)	20 (100)

**Table 2: Type of bioresorbable fixation and anatomical location of fractures**

Types of bioresorbable plate (mm)	Location of fractures (n=20)				
	Maxillary alveolar #	Nasal complex #	Zygomatic complex #	Orbital #	Le Fort #
1.5	8	5	0	1	0
2.0	0	0	5	0	1

**Table 3: Assessment of infection in study subjects**

	Preoperative		Postoperative	
	Present, n (%)	Absent, n (%)	Present, n (%)	Absent, n (%)
Initial	9 (45)	11 (55)	-	20 (100)
2 weeks	-	-	-	20 (100)
3 months	-	-	1 (5)	19 (95)
6 months	-	-	-	20 (100)

**Table 4: Assessment of paresthesia in study subjects (n=20) at different follow-ups**

	Preoperative Initial, n (%)	Postoperative		
		2 weeks, n (%)	3 months, n (%)	6 months, n (%)
Paresthesia	2 (10)	2 (10)	-	-
No paresthesia	18 (90)	18 (90)	-	-
Total	20 (100.0)	20 (100.0)	20 (100.0)	20 (100.0)

**Table 5: Postoperative assessment of stability of fracture site**

Time interval	Number of patients with fracture stability, n (%)	Mobility in vertical, n (%)	Mobility in horizontal, n (%)
2 week	7 (35)	9 (45)	4 (20)
3 months	20 (100)	-	-
6 months	20 (100)	-	-

**Table 6: Bite force in incisor region**

	Bite force mean±SD	Change in bite force from mean±SD	t	P
2 weeks	3.58±1.281	-	-	-
3 months	5.25±1.624	1.670±0.786	8.886	<0.0001
6 months	6.71±1.795	3.13±1.144	11.449	<0.0001

SD: Standard deviation

## DISCUSSION

Ever since the development of modern surgical techniques, the name of bioresorbable material has been in existence for 3–4 decades. The first bioresorbable material was used in the form of suture material by Kulkarni *et al.* They concluded that although the rate of infection associated with implantation is more, the implant material gradually resorbed.<sup>[7]</sup>

Biodegradable devices for fracture fixation have been under constant development; since then, several attempts

**Table 7: Bite force in right molar region**

	Bite force right molar mean±SD	Change in bite force right molar from mean±SD	t	P
2 weeks	6.11±1.846	-	-	-
3 months	11.385±1.934	7.245±2.038	14.880	<0.0001
6 months	17.14±2.443	12.030±3.076	18.373	<0.0001

SD: Standard deviation

**Table 8: Bite force in left molar region**

	Bite force left molar mean±SD	Change in bite force left molar from mean±SD	t	P
2 weeks	5.995±1.995	-	-	-
3 months	15.458±2.102	9.463±2.286	17.334	<0.0001
6 months	19.75±2.246	13.755±2.793	20.619	<0.0001

SD: Standard deviation

**Table 9: Comparison of pain at different follow-ups**

VAS scale	Initial (n=20), n (%)	2 weeks, n (%)	3 months, n (%)	6 months, n (%)
No pain (0)	-	15 (75)	20 (100)	20 (100)
Mild (1-4)	-	5 (25)	-	-
Moderate (5-7)	17 (85)	-	-	-
Severe (7-10)	3 (15)	-	-	-

VAS: Visual analogue scale

**Table 10: Comparison of pain at different follow-ups from initial**

Postoperative follow-up	Mean±SD		t	P
	Pain (in VAS)	Change in pain		
Initial	5.6±0.753	-	-	-
2 weeks	1.15±1.348	4.450±1.502	12.399	<0.0001
3 months	0.00±0.00	5.60±0.706	33.288	<0.0001
6 months	0.00±0.00	5.92±0.46	43.355	<0.0001

SD: Standard deviation, VAS: Visual analogue scale

**Table 11: Comparison of swelling at different follow-ups**

	Present, n (%)	Absent, n (%)
1 <sup>st</sup> day	16 (80)	4 (20)
2 weeks	9 (45)	11 (55)
3 months	0	20 (100)
6 months	0	20 (100)

have been made to produce an ideal device for fracture fixation.

A recent and significant advancement has been the development of bioresorbable fixation systems. Combining adequate strength and rigidity with bioresorption has appealed to both the patients and the health-care providers. Moreover, concerns about compatibility with future imaging needs, interference with radiation therapy, migration of the implant, growth restriction, long-term palpability, and thermal sensitivity have been reduced. Turvey *et al.*, 2002,



were the first investigator to report experimental results in international literature.<sup>[8]</sup>

The rationale of using a monocortical plate in the mandibular fracture is that synthesis by plate screwed on the outer cortical plate is solid enough to support the strain developed by masticatory muscle. The principle of osteosynthesis is to re-establish the mechanical qualities of the mandible, taking into account the anatomical conditions. Bell and Kindsfater used bioresorbable plates for the patient with mandibular and midface fracture and found uneventful healing. The same finding was reported in our study, where we found uneventful healing in the majority of cases.<sup>[9]</sup>

In the present study, twenty cases of mid face fractures were treated by Inion CPS plating system using 1.5, 2, and 2.5 mm (LPLA/DLPLA/TMC/PGA) bioresorbable bone plates and 6 and 8mm screws. This material have excellent handling properties, strength and degradation characteristics that support natural healing process.

An intraoral/extraoral approach was used to expose, reduce, and fix the fractured fragment under general/local anesthesia, and access to the maxilla and zygomaticomaxillary buttress was made through the linear buccal vestibular incision. Michelet *et al.* used the same approach for access to the zygomaticomaxillary buttress.<sup>[10]</sup> A minimum of two screws on each side of the segment was used to prevent rotational movement of fracture fragment which was in correlation with the study of Gillies *et al.*; they treated zygomatic fractures by temporal approach and cited that this approach had advantages of negligible scar and field free from important structures.<sup>[11]</sup>

Intermaxillary fixation was done in patients above 12 years of age. In patients with mixed dentition where IMF was not feasible, the occlusal splint is made to work with free-hand technique during fracture repair. All the patient has the stable occlusion which shows the postoperative stability of bioresorbable osteosynthesis. We aimed to restore the occlusion and obtain stable bony healing as done by Eppley 2005 who used IMF for 2 weeks to obtain functional occlusion.<sup>[12]</sup>

The present study was carried out in paediatric patients between the age group of 1–15 years of age out of which (6–10 years) are 45% and (11–15 years) are 30% and the mean age being (9.0 years). In the present study, the number of male patients and female patients was 1.85:1 in ratio. The study correlates with the study of Hashmi *et al.* in which the ratio obtained was 3.7:1 which infers that the ratio was reduced significantly due to modernization

and active outdoor activity of women.<sup>[13]</sup> The time-lapse between injury and definitive management seems to be important because delay in seeking treatment increases the possibility of infection. In our study, the majority of patients were treated within a time-lapse of 9–12 days. The mean time-lapse between injury and definite management was seen to be 8.35 days. Infection was present in half of the cases preoperatively and treated with suitable antibiotics and analgesics. Our study correlates with the finding of Suuronen who observed a mild inflammation reaction seen around the implant.<sup>[14,15]</sup>

In the present study, both road traffic accidents and falls were found to be responsible for the majority of fractures. 55% patients sustained fractures due to falls and (45%) results from road traffic accidents. Hashmi *et al.* studied etiological factors in maxillofacial trauma, in which road traffic accident (38 · 9%) was the major etiological factor, followed by fall (26 · 7%) in 90 cases.<sup>[13]</sup>

In the present study, we did not encounter any persistent swelling other than postoperative edema, postoperative infection and wound dehiscence. Only one patient developed plate exposure at 1 month follow up, which was fully covered without traces of any exposure by 3 follow up. These findings in our studies are following Suuronen who treated more than 200 patients with bioresorbable plates successfully and stated that the use of bioresorbable fixation can be considered routine and it will be state of art at the beginning of the millennium.<sup>[14]</sup>

Suuronen *et al.* stated that today, most maxillofacial fractures and osteotomies may be adequately fixed with bioresorbable materials as we did in our study.<sup>[15]</sup>

Our study correlates with the study of Laine *et al.*, 2004, who in their study did not report any postoperative complication due to PLLA plates and screws, and we also did not find report any postoperative complication due to PLLA plates.<sup>[16]</sup>

Thus, as a result of clinical experience, it can be inferred that the use of a tripolymer (Plla/Pdla/Pga/TMC) osteosynthesis system in the management of fractures involving the mandible and middle third of the facial skeleton gives excellent results in terms of function, esthetics, and acceptability.

In the present study, preoperative paresthesia was present in two cases and continued till 2 weeks and 1 month follow ups. Paresthesia gradually decreases with time. No paresthesia was seen after 1 month follow up which is statistically significant. Bhatt *et al.* (2010) in their study also reported a gradual decreased in paresthesia in consecutive follow up.<sup>[17]</sup>

In the present study, mobility of fracture was seen in all patients preoperatively. At 2 week and 1 month follow up, mobility was present in 8 and 2 patients respectively. No mobility was found after 3 and 4 follow ups. Assessment of the stability of fractures segment revealed that the mobility of fragment gradually decreases with time showing the result is statistically significant.

In the present study, deranged occlusion was present in 17 patients preoperatively (85%) and 3 patients have normal occlusion preoperatively (15%). 100% normal occlusion was observed postoperatively. This was in correlation with study of Wood (2006) who also observed marked improvement in the occlusion in postoperative period.<sup>[18]</sup>

The forces that must be countered in mandibular fracture have been derived from maximum voluntary bite force measurement, which in the healthy adult may ranges in the order of 0–20 KPa (average, 15.3 KPa) in the incisor and 0–60 KPa (average, 48.3 KPa) and 0–70 KPa (average, 49.3 KPa) in left and right molar regions, respectively. In our study, a statistically significant reduction in incisor bite force was found at the first follow-up after surgery when compared with the second follow-up. At first, follow-up incisor bite force was only 3.58 KPa compared with 5.25 KPa in the second follow-up after surgery. There is a significant increase in incisor bite force of 3.58 KPa in 2 weeks through 3.61 KPa in 3 months. There was no significant difference between the incisor bite force at the 2<sup>nd</sup> follow-up (5.25 KPa) and the 3<sup>rd</sup> follow-up (6.71 KPa).

A statistically significant reduction in left molar bite force was found at the 2<sup>nd</sup> week (follow-up I) after surgery when compared to the left molar bite force 3 months (follow-up II) after surgery. In the 2<sup>nd</sup> week (follow-up I), left molar bite force was only 5.995 KPa compared with 15.45 KPa at follow-up II (3 months) after surgery. These findings correlate with the findings of Ellis *et al.* who reported an average left molar bite force of 5.995 KPa in 2 weeks and 15.45 KPa after 3 months. There was no significant difference between bite forces at left molar region at the 3<sup>rd</sup> month (15.45 KPa) and the 6<sup>th</sup> month follow up (19.75 KPa). In our study, a statistically significant reduction in bite force at right molar region was found at the 2<sup>nd</sup> week (6.11Kpa) when compared to the right molar bite force at 3 month follow up (11.38Kpa). These findings correlate with the finding of Ellis *et al.* who reported an average right molar bite force of 6.88 KPa in 2 weeks through 11.385 KPa after 3 months. There was no significant difference between the right molar bite force at the 3<sup>rd</sup> month, i.e. follow-up III (11.385 KPa), and the 6<sup>th</sup> month, i.e. follow-up IV (17.14 KPa).<sup>[19]</sup>

From the foregoing discussion, we can conclude that the use of bioresorbable plate in the midface and the mandibular

fracture was efficacious enough to bear masticatory loads during the osteosynthesis of fracture. Bioresorbable plates can be shaped easily by digital pressure once it becomes malleable after immersion in the water bath. Care must be taken not to overtighten the screw to avoid fracturing the head. Should it happen, a replacement can be inserted easily by drilling through the fractured screw. The need to tap and then insert a screw requires great manual dexterity by the surgeon. These plates are radiolucent on radiological examination and do not interfere with CT or MRI, and they allow a clear postoperative view of the fracture site on a plain radiograph.<sup>[20]</sup>

The fractures have been sufficiently stable to allow bony healing clinically indistinguishable from those treated with metal mini plates. However, the high cost of the plate is the only limitation and of concern.<sup>[21,22]</sup>

## CONCLUSION

It can be concluded that the biodegradable osteosynthesis system exhibits adequate strength with negligible complications. The system is technique sensitive which shows satisfactory results in the management of mild to moderately displaced midface fractures. As per our observation, the most convincing advantage of this system is that there is no need for a second surgery for removal of the implant as the plates are degradable. No plates were broken during manipulation, and this result shows good handling properties. These plates have sufficient strength thus post operative intermaxillary fixation is not required. They have moldable quality which help in adaptation of plates in required anatomy intraoperatively. The bioresorbable plate has enough efficacy to bear masticatory force and can be used safely in pan facial fractures as bite force recordings showed increasing values at subsequent follow-up, corresponding to the healing of the fracture. The high cost of the material is the greatest deterrent to its wider use. Although the present study helps provide some level of reliable evidence for assisting the clinicians and patients for decision-making. However, a further comparative study with larger samples and longer follow-up is suggested to establish the definite conclusion.

## Financial support and sponsorship

Nil.

## Conflicts of interest

There are no conflicts of interest.

## REFERENCES

1. Champy M, Loddé JH, Must D, Jaeger JH, Muster D. Mandibular osteosynthesis by miniature screwed plates via buccal approach. *J Maxillofac Surg* 1978;6:14-21.

2. Krueger E. Fractures of the facial bones in children. In: Krueger E, Schilli W, editors. *Oral Maxillofac Trauma*. Vol. 2. Chicago: Quintessence; 1986. p. 259-92.
3. Rowe NL. Fractures of the facial skeleton in children. *J Oral Surg* 1968;26:505-15.
4. McCoy FJ, Chandler RA, Crow ML. Facial fractures in children. *Plast Reconstr Surg* 1966;37:209-15.
5. Bessho K, Iizuka T, Murakami K. A bioabsorbable poly-L-lactide miniplate and screw system for osteosynthesis in oral and maxillofacial surgery. *J Oral Maxillofac Surg* 1997;55:941-5.
6. Eppley BL, Sadove AM, Havlik RJ. Resorbable plate fixation in pediatric craniofacial surgery. *Plast Reconstr Surg* 1997;100:1-7.
7. Kulkarni RK, Pani KC, Neumann C, Leonard F. Polylactic acid for surgical implants. *Arch Surg* 1966;93:839-43.
8. Turvey TA, Bell RB, Tejera TJ, Proffit WR. The use of self-reinforced biodegradable bone plates and screws in orthognathic surgery. *J Oral Maxillofac Surg* 2002;60:59-65.
9. Bell RB, Kindsfater CS. The use of biodegradable plates and screws to stabilize facial fractures. *J Oral Maxillofac Surg* 2006;64:31-9.
10. Michelet FX, Deymes J, Dessus B. Osteosynthesis with miniaturized screwed plates in maxillo-facial surgery. *J Maxillofac Surg* 1973;1:79-84.
11. Gillies HD, Kilner TP, Stone D. Fractures of the malar-zygomatic compound: With a description of a new x-ray position. *Br J Surg* 1927;14:651-6.
12. Eppley BL. Use of resorbable plates and screws in pediatric facial fractures. *J Oral Maxillofac Surg* 2005;63:385-439.
13. Hashmi SH, Chawla TN, Pradhan R, Sharma VD. An analysis of maxillofacial injuries. *J Indian Dent Assoc* 1980;52:219-20.
14. Suuronen R. Biodegradable fracture-fixation devices in maxillofacial surgery. *Int J Oral Maxillofac Surg* 1993;22:50-7.
15. Suuronen R, Kallela I, Lindqvist C. Bioabsorbable plates and screws: Current state of the art in facial fracture repair. *J Craniomaxillofac Trauma* 2000;6:19-27.
16. Laine P, Kontio R, Lindqvist C, Suuronen R. Are there any complications with bioabsorbable fixation devices? A 10 year review in orthognathic surgery. *Int J Oral Maxillofac Surg* 2004;33:240-4.
17. Bhatt K, Roychoudhury A, Bhutia O, Trikha A, Seith A, Pandey RM. Equivalence randomized controlled trial of bioresorbable versus titanium miniplates in treatment of mandibular fracture: A pilot study. *J Oral Maxillofac Surg* 2010;68:1842-8.
18. Wood D. Geoffrey, inion biodegradable plates. The first century. *Br J Oral Maxillofac Surg* 2006;44:38-41.
19. Tate GS, Ellis E 3<sup>rd</sup>, Throckmorton G. Bite forces in patients treated for mandibular angle fractures: Implications for fixation recommendations. *J Oral Maxillofac Surg* 1994;52:734-6.
20. Eppley BL. Use of resorbable plates and screws in pediatric facial fractures. *J Oral Maxillofac Surg* 2005;63:385-91.
21. On SW, Cho SW, Byun SH, Yang BE. Bioabsorbable osteofixation materials for maxillofacial bone surgery: A review on polymers and magnesium-based materials. *Biomedicines* 2020;8:300.
22. Kanno T, Sukegawa S, Furuki Y, Nariai Y, Sekine J. Overview of innovative advances in bioresorbable plate systems for oral and maxillofacial surgery. *Jpn Dent Sci Rev* 2018;54:127-38.