



Contents lists available at ScienceDirect

## Indian Pacing and Electrophysiology Journal

journal homepage: [www.elsevier.com/locate/IPEJ](http://www.elsevier.com/locate/IPEJ)

## Multi-catheter cryotherapy for the treatment of resistant accessory pathways

Lisa WM. Leung, Banu Evranos, Hanney Gonna, Idris Harding, Giulia Domenichini, Mark M. Gallagher\*

Department of Cardiology, St. George's University Hospitals NHS Foundation Trust, UK

### ARTICLE INFO

#### Keywords:

Wolff Parkinson white syndrome  
Pre-excitation  
Accessory pathway  
Catheter ablation  
Cryoablation

### ABSTRACT

**Objective:** To investigate the utility of simultaneous multi-catheter cryotherapy for the treatment of APs that were previously resistant to standard radiofrequency (RF) catheter ablation.

**Background:** Catheter ablation is established in the treatment of accessory pathways (AP), with high rates of permanent procedural success with a single attempt. However, there are still instances of acute procedural failure and AP recurrences with standard RF and cryotherapy methods.

**Methods:** Seven consecutive cases of pre-excitation syndromes with prior failed RF catheter ablation had the novel treatment. Cryotherapy was delivered using two 8 mm tip focal cryoablation catheters (Freezor® Max, Medtronic, Minneapolis, Minnesota, USA).

**Results:** Accessory pathway localisation was septal in 5 cases, left posterolateral in 1, right lateral in 1. In all cases, ablation of the AP was acutely successful with no procedural complications. Median procedure and fluoroscopy durations were 199 and 35 min, sequentially. Median Procedure duration fell significantly in the second half of series (174 min) compared to the first half (233 min,  $P = 0.05$ ). One patient had evidence of a recurring AP conduction with pre-excitation at 5-week follow up. After a median follow up of  $66.8 \pm 6.5$  months, 6 out of 7 patients remained asymptomatic and free of pre-excitation.

**Conclusion:** Simultaneous multi-catheter cryotherapy is feasible, safe and can provide definitive cure of accessory pathways that were previously resistant to standard radiofrequency ablation. Further study is required in the assessment of this novel form of advanced cryotherapy to treat complex and resistant arrhythmias.

### 1. Introduction

Catheter ablation is the treatment of choice for symptomatic pre-excitation syndromes [1]. In general, radiofrequency (RF) ablation of accessory pathways (APs) has high acute procedural success rates, low complication and recurrence rates but the performance is dependent on the location of the AP. The acute procedural success rate for RF ablation of septal AP is lower and recurrence rate is higher compared to left free wall AP [2–4]. Ablation of the left posteroseptal and posterior regions has also been identified as being particularly difficult [5,6]. This difficulty may arise in part from the oblique and/or epicardial course of some pathways in this region requiring more extensive and sometimes epicardial ablation within the coronary sinus (CS) [7], a site where RF ablation is associated with additional risks including adherence of

catheter tip to CS wall [7], CS thrombosis [7,8] and collateral damage to the adjacent coronary artery [9]. The proximity of the conduction system also complicates ablation in septal sites.

Cryotherapy is routinely used for ablation of accessory pathways, particularly in paediatric practice and when pathways are located close to the cardiac conduction system where there is evidence that it minimises the risk of atrioventricular block [10]. It is suitable for use within the coronary venous system where it reduces the risk of coronary artery spasm associated with thermal injury from RF energy [11]. The Achilles' heel of cryoablation is the limited size of the lesions produced. A lengthier catheter tip and good duration of therapy delivery are established factors leading to production of larger lesions; this has been verified by experimental studies [12]. In the cryotherapy of hepatic metastases, lesion size limitations have been overcome by the enhanced

*Abbreviations:* AP, accessory pathway; CS, coronary sinus; RF, radiofrequency; WPW, Wolff Parkinson White syndrome.

Peer review under responsibility of Indian Heart Rhythm Society.

\* Corresponding author. St George's Hospital, Blackshaw Road, London, SW17 0QT, UK.

E-mail address: [Mark.Gallagher@stgeorges.nhs.uk](mailto:Mark.Gallagher@stgeorges.nhs.uk) (M.M. Gallagher).

<https://doi.org/10.1016/j.ipej.2023.11.002>

Received 27 August 2023; Received in revised form 25 October 2023; Accepted 2 November 2023

Available online 17 November 2023

0972-6292/© 2023 Indian Heart Rhythm Society. Published by Elsevier B.V. This is an open access article under the CC BY-NC-ND license (<http://creativecommons.org/licenses/by-nc-nd/4.0/>).

effect of 2 catheters acting simultaneously [13]. We have previously applied dual catheter cryotherapy to cardiac ablations [14,15] to improve efficiency by treating different locations simultaneously. In this initial experience, attempted to improve efficacy at sites of great difficulty, examining the safety and effectiveness of simultaneous multi-catheter cryotherapy for the treatment of APs previously resistant to standard RF.

## 2. Methods

### 2.1. Patient selection

From 2015, we used dual catheter cryotherapy for all patients who were referred for repeat ablation of accessory pathways that had proved unsuccessful at other centres or recurred after an apparently successful ablation using standard RF methods; 7 patients fulfilled these criteria. Institutional ethics committee approval was obtained. Written informed consent was obtained from patients prior to proceeding with the electrophysiology study and ablation.

### 2.2. Advanced cryotherapy: simultaneous multi-catheter cryoablation procedure

Diagnostic electrophysiology catheters were positioned in the coronary sinus and the His bundle position and in combination with data available from the surface ECG and from previous procedures, we determined the approximate pathway location. A large or medium-curve 8-mm-tip cryocatheter (Freezor® Max, Medtronic, Minneapolis, Minnesota, USA) was then advanced to this area. In those patients with manifest pre-excitation, the site of earliest ventricular activation in sinus rhythm or atrial pacing was identified. For those with concealed pathways, the earliest atrial activation was mapped and ablated during atrioventricular reciprocating tachycardia (Fig. 1) or ventricular pacing. CS angiography was performed in patients with left sided pathway to define the coronary venous anatomy (Fig. 1a and 2a).

Cryoablation was performed by cooling the cryocatheter tip to  $-80^{\circ}\text{C}$

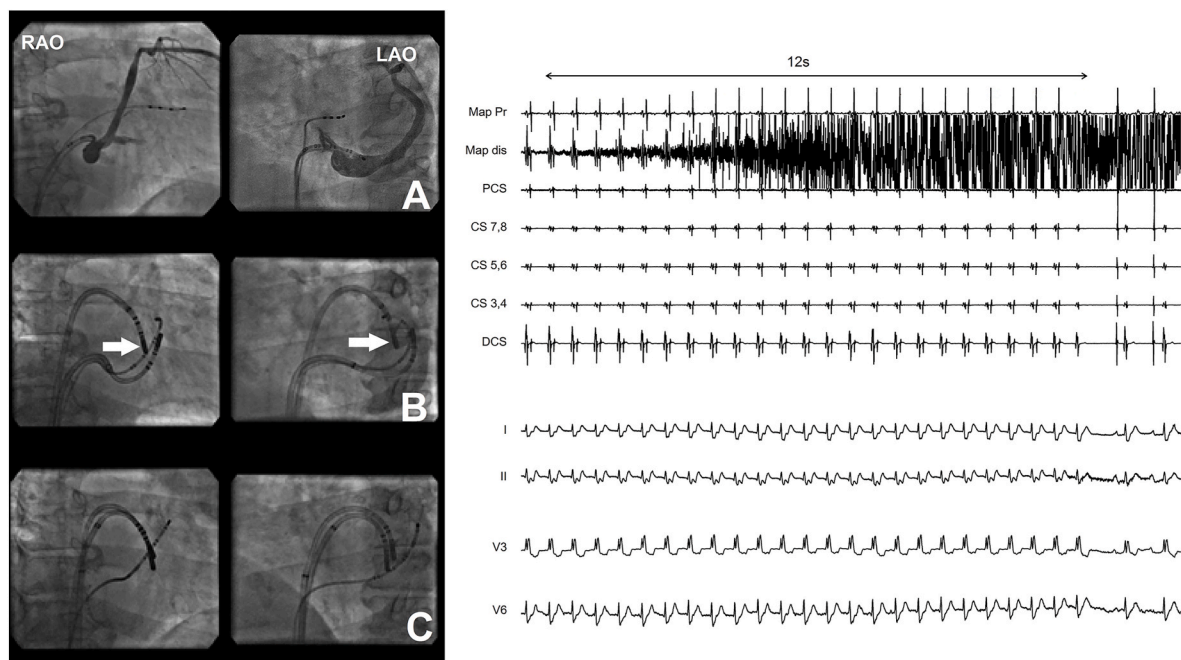
for periods of up to 25 s until pathway block was achieved. After obtaining block of the pathway during cryotherapy with the first ablation catheter, a second identical 8-mm-tip cryocatheter, connected to a second cryo-console was brought to an adjacent or opposite location. In cases in which block was obtained inside the CS, the second catheter was applied to the nearest available endocardial location (Fig. 1b and 2b). Therapy was delivered ( $-80^{\circ}\text{C}$ ) simultaneously with both catheters. At least 2 applications of cryotherapy of 4 or 5 min each were delivered with each catheter at this initial site. Consolidation lesions were then performed at sites adjacent to the site of pathway block with both catheters. For pathways in left lateral or right lateral locations, therapy was delivered with both cryocatheters in parallel endocardial locations (Fig. 1c and 3).

Procedural success was defined as the achievement of bidirectional block of the accessory pathway that persisted for more than 30 min after the end of the last application of cryotherapy. Clinical success was defined as the absence of pre-excitation on the surface ECG, the elimination of symptomatic tachycardias and the absence of documented arrhythmia to the last available follow-up and to at least 6 months after ablation.

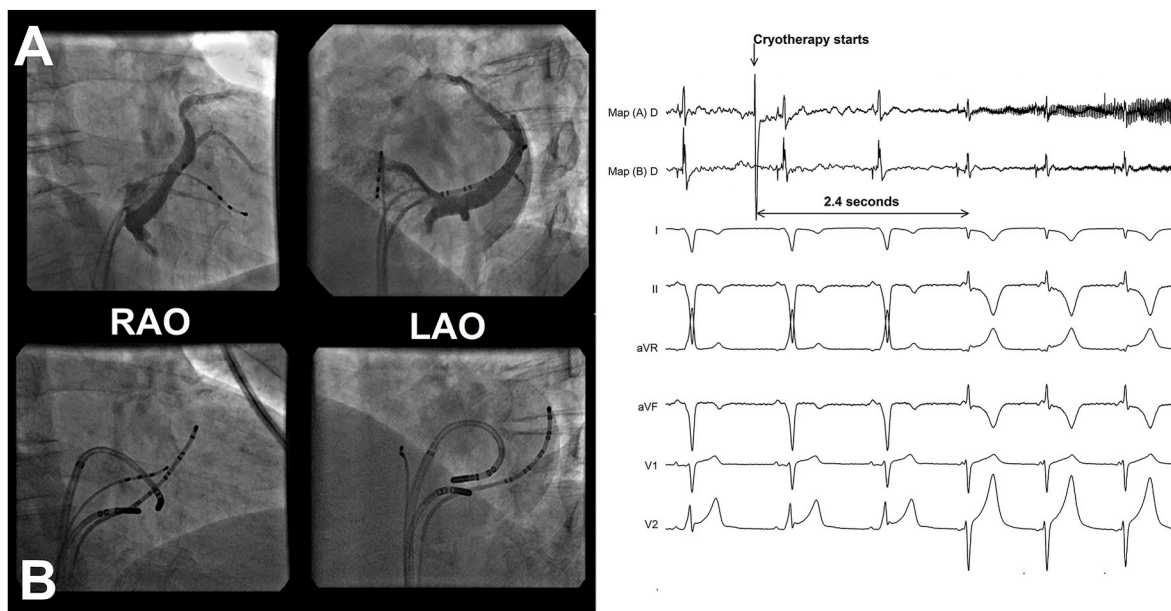
All procedures were performed under local anaesthesia except for patient 2 who requested general anaesthesia due to unpleasant recollections of the previous procedure, using RF. To decrease the discomfort of cooling, patients were actively warmed using a pneumatic warming blanket (Bair Hugger, 3 M, Maplewood, Minnesota).

### 2.3. Statistical analysis

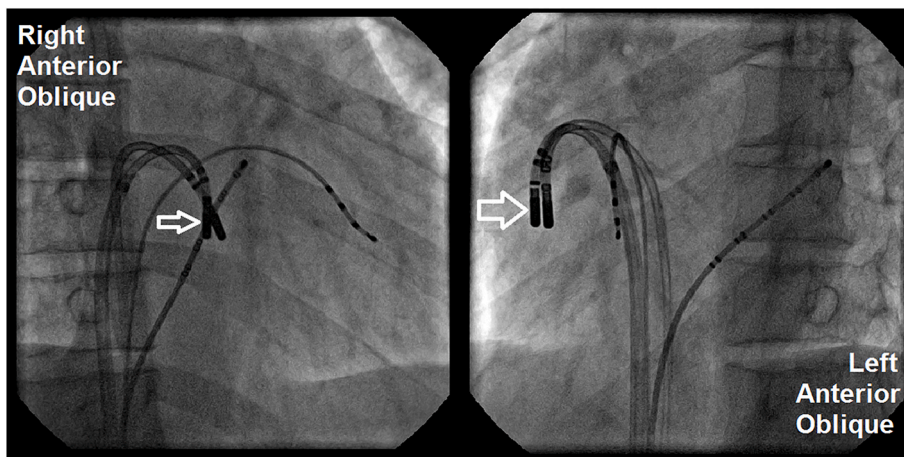
Continuous variables are presented as median, minimum and maximum values. Comparison of continuous variables was performed using Mann Whitney *U* Test and considered statistically significant where  $P < 0.05$ . Statistical analysis was performed using IBM SPSS Statistics 22.0 software (SPSS, Inc., Chicago, IL, USA).



**Fig. 1.** Dual catheter cryotherapy of a left lateral concealed accessory pathway (case 4). After a normal baseline coronary sinus (panel A), the site of earliest atrial activation in tachycardia was mapped via a transeptal approach (panel B, catheter arrowed). Pathway block was achieved at 12 s from the occurrence of a cryotherapy artefact (right hand panel). The second Freezor Max was brought close to the same site, within the coronary sinus and therapy was delivered simultaneously. Additional cryotherapy was delivered with the second catheter at different sites both within the coronary sinus and endocardially (panel C).



**Fig. 2.** Dual catheter cryotherapy of a left paraseptal pathway. A baseline coronary sinus showed no abnormality (panel A). Delivery of cryotherapy through the Freezor Max ablation catheter in the proximal coronary sinus resulted in an apparent loss of pre-excitation at 2.4 s from the start of cryotherapy artefact (right hand panel). The apparent loss of pre-excitation is due to a junctional rhythm, but when sinus rhythm re-emerged, it was without pre-excitation. The second cryocatheter was used to deliver simultaneous therapy endocardially close to the site of the first catheter (panel B), and then at adjacent sites in multiple subsequent deliveries.



**Fig. 3.** Dual catheter cryotherapy of a right free wall accessory pathway. This manifest pathway (case 6) was mapped to a right free wall location using a Freezor Max catheter (arrow) delivered via a 10F Arrive sheath (Medtronic). The second cryocatheter was brought to an adjacent position, using the first catheter for support; multiple deliveries were performed with both catheters simultaneously.

**Table 1**  
Patient characteristics.

Patient Number	Age (years)	Sex	Pathway Location	Pathway Conduction	Number of Prior Ablations	Details of Previous Ablation(s)
1	57	M	Right Posteroseptal	manifest	1	Irrigated RF – no anterograde pathway block
2	37	M	Left Posteroseptal	manifest	1	Irrigated RF – no anterograde pathway block
3	33	M	Left posterolateral	manifest	3	Irrigated RF Repeated recurrences – after 20 min on last occasion
4	67	M	Right Posteroseptal	manifest	3	Initial success with irrigated RF – subsequent recurrence
5	39	F	Left Posteroseptal	concealed	1	Initial success with non-irrigated RF – subsequent recurrence
6	22	M	Right Lateral	manifest	2	No details available
7	26	M	Left posteroseptal	manifest	1	Irrigated RF- no pathway block

### 3. Results

#### 3.1. Patient recruitment

In 5 years to the end of April 2020, we treated 7 patients with accessory pathways that had proven unsuccessful RF ablation or that had recurred after apparently successful RF ablation.

#### 3.2. Patient and pathway characteristics

Table 1 shows the clinical details of each of the patients. All patients had a structurally normal heart. The mean age at ablation was  $40.1 \pm 16$  SD. The pathway location was septal in 5 of the patients.

#### 3.3. Procedural parameters

No significant complication occurred. Procedural success was achieved in all patients. Median procedure and fluoroscopy durations were 208 and 41 min, respectively. Procedure duration fell significantly in the second half of series (174 min) compared to the first half (233 min,  $P = 0.05$ ), though fluoroscopy duration did not change significantly (45.2 min–28.5 min;  $P > 0.05$ ). The median total duration of cryotherapy on both catheters was 100.8 (78–267) minutes. All patients were discharged on the day of the procedure or after overnight observation.

#### 3.4. Follow-up

In the second patient treated, pre-excitation was absent at the time of discharge from hospital but was preexcitation was again found at a routine check at 5 weeks after the procedure. The patient had a subsequent ablation 4 years after the cryotherapy procedure with standard methods using irrigated radiofrequency and electro-anatomic mapping (Carto®, Biosense Webster, Johnson and Johnson, Diamond Bar CA). Mapping showed that the pathway responsible was not a recurrence of the previously ablated left postero-septal pathway but was a right antero-septal pathway that had not been detectable at the previous procedures. After a median of  $66.7 \pm 6.6$ SD months, the other 6 patients were asymptomatic and free of pre-excitation.

### 4. Discussion

In this consecutive case series, we demonstrated the feasibility, safety and medium-term efficacy of advanced concentrated cryotherapy, in the form of simultaneous multi-catheter applications. To our knowledge, this study is the first that investigates the feasibility and efficacy of delivering simultaneous cryotherapy from two cardiac catheters converging on a single site.

We report a 100 % technical success rate for our simultaneous multi-catheter cryotherapy approach. Importantly, no major procedural complications occurred. With this novel interventional technique, the results predictably show long procedural times due to the learning curve of the operator and lab team: there was a mean duration of over 3 h and the use of 2 expensive ablation catheters. The fall in procedure duration over the course of our experience would suggest that we improved our efficiency over the study period as we became accustomed to the methodology. This suggests that, if this method became established in practice, procedural efficiency would match standard catheter ablation techniques. Our procedures were the more challenging of WPW cases, with patients having already had a previous failed RF ablation attempt and this may have also contributed to the lengthier procedural times.

The operator often has a choice of approaches to an accessory pathway: a septal pathway may be approached from either side of the septum, left sided pathways can be approached either through the coronary venous system or from the endocardial surface of the left atrium or the ventricle. Multiple permutations can be considered when using two cryocatheters. We never placed catheters on the right atrial and left

atrial aspects of the septum simultaneously as none of the pathways was in the mid-septal region in which this placement might be effective. Cryotherapy across the septum in this manner would potentially create a higher risk of atrioventricular block. We did not encounter any atrioventricular block, though we encountered atrioventricular nodal automatic rhythm in one case (Fig. 2).

Advanced cryotherapy in the form of simultaneous multi-catheter applications is an attractive interventional approach compared to the established alternatives, to overcome complex and resistant arrhythmic substrates. The presence of multiple catheters in the intra-cardiac cavity is common in everyday practice and the current size and design of the cryocatheters mean that the presence of an additional catheter does not pose any mechanical problems to surrounding intra-cardiac structures.

The biophysics and biomechanics of standard single-catheter cryotherapy are well described, and the advantages with this technology include the stability of the catheters to the target ablative points, minimising collateral damage. The lesions are often considered to be more homogenous and well-demarcated. The biophysics of multi-catheter cryoablation in the heart has not been studied. Experience from treating hepatic metastases suggests the lesion produced may be greater than twice the size of the lesion produced by a single catheter, but this has not been proved in cardiac work. We hypothesise that the effect can be maximised by placing a catheter at either side of the pathway being targeted, for example one epicardially in the coronary sinus and one endocardially, rather than adjacent to each other.

Cryotherapy is less pro-thrombotic than RF ablation and maintains the tissue ultra-structural integrity better than RF [16]. It has been associated with coronary spasm. This and cases of atrioventricular block seem to resolve quickly when cryotherapy ceases, but it should not be assumed that the high level of safety experienced with single catheter cryotherapy can be extended to multi-catheter application.

With this advanced cryotherapy technique, we will be able to preserve these advantageous merits whilst at the same time enhance the ablative power to overcome more complex and resistant arrhythmic substrates. Simultaneous cryotherapy applications would create lesions of greater depth and depending on how the second catheter is applied, there is potential to widen the lesion size as well. Advanced RF applications to overcome similar challenging substrates, carries a risk of ‘steam pop’ or perforation, which is not a risk known with cryotherapy. The safety of this advanced cryotherapy technique of course requires further study but with the basic principles of cryotherapy intact and application of already tried and tested cryocatheters, it is expected that the safety profile will also be maintained. Another factor that favours cryotherapy for more challenging cases, with the patient under conscious sedation, is that cryotherapy is consistently better tolerated when compared to RF.

With regards to established alternatives for the treatment of resistant WPW cases, Scanavacca et al. [17] used an epicardial approach successfully in 28 % of a patient group similar to ours in its demographics, ablation history and distribution of pathway location. They had to use open cardiac surgery in 19 % of patients and resorted to long-term medical therapy in 9.5 %. The duration of the procedures that they describe at 200 min was very similar to our own. Although they achieved this without serious complication, the use of an epicardial approach, other than through the venous system, carries a risk of adverse effects that is greater than with purely endovascular procedures [18].

Dual catheter ablation using bipolar RF energy has been described [19,20], though only for atrial and ventricular arrhythmias and not yet for accessory pathways. In principle, it could be used in the same way as the dual catheter cryotherapy that we have described but it has the potential disadvantage of vascular injury when used within the coronary venous system [11]. The handling of multiple RF ablation catheters would also be more challenging due to the lack of catheter stability. Cryogenic anchoring ensures catheter stability throughout the delivery of therapy, minimising the risk of collateral damage as the operator is

distracted from one of the catheters.

Long-term outcomes at 5 years reveal that all 7 ablated using this technique remain well and free from any arrhythmia. Only 1 patient required another ablation to achieve this. The pathway, however, was not located at the previous located site at the left postero-septal region but this time at the right antero-septum. There was no evidence of the right antero-septal pathway at the 2 prior electrophysiology studies. A possible explanation of this may be due to higher levels of sedation required at those times or the pathway activity being masked by left postero-septal pathway activity until it was abolished.

Previous studies have shown that there is a higher incidence of atrial fibrillation in patients with WPW, that persists despite ablation treatment. The mean age at the time of advanced cryotherapy was  $40.1 \pm 16$  years, which is significantly older compared to the median age of the WPW cohort (at 19 years old) in the registry study investigated by Pappone et al. [21]. None of the patients in our case series had evidence of atrial fibrillation or other types of arrhythmias at 5-year follow up.

With further study, advanced cryotherapy in the form of simultaneous multi-catheter applications may become an established treatment option for a wider range of complex and resistant arrhythmic conditions that would otherwise have been treated with advanced RF or surgical procedures. This interventional approach may also be considered in paediatric age groups and/or in the context of structural heart disease. This will also encourage further advances in technological design to aid delivery of advanced cryotherapy.

## 5. Conclusion

Simultaneous multi-catheter cryoablation is a form of advanced cryotherapy that is effective in the treatment of accessory pathways that were previously resistant to RF ablation and represents a conceptually important and novel application of an existing technology.

## 6. Limitations

This was a single centre proof-of-concept study designed to demonstrate the feasibility of a novel strategy in ablation. A randomised trial would be required to clarify the relative effectiveness this approach compared to a repetition of RF ablation. The main technical limitation is the requirement for two cryo-generators, a requirement that would be difficult to meet in a smaller centre. The approach is more costly than a standard cryoablation because of the need for two ablation catheters and two generators.

The fluoroscopy duration in these cases was much greater than in simple pathway ablation procedures, a limitation that could be partially addressed by employing a mapping system, a method that has been improvised with single cryo catheters but not with multiple catheters. The mapping catheter used in these cases, the freezer max has a larger tip electrode than any RF ablation catheter, making the electrograms less sharp. This may have added to the time taken to map the pathway location. The procedures in this series were performed by an operator with a large prior experience of cryoablation [15,22] including non-standard applications.

## Declaration of competing interest

Dr Gallagher has received research funding from Attune medical and has acted as a consultant and paid speaker for Biosense Webster. No other author has any conflict of interest.

## References

- [1] Scheinman M, Calkins H, Gillette P, Klein R, Lerman BB, Morady F, et al. NASPE policy statement on catheter ablation: personnel, policy, procedures, and therapeutic recommendations. *Pacing Clin Electrophysiol* 2003;26:789–99.
- [2] Calkins H, Yong P, Miller JM, Olshansky B, Carlson M, Saul JP, et al. Catheter ablation of accessory pathways, atrioventricular nodal reentrant tachycardia, and the atrioventricular junction: final results of a prospective, multicenter clinical trial. The Atakr Multicenter Investigators Group. *Circulation* 1999;99:262–70.
- [3] Jackman WM, Wang XZ, Friday KJ, Roman CA, Moulton KP, Beckman KJ, et al. Catheter ablation of accessory atrioventricular pathways (Wolff-Parkinson-White syndrome) by radiofrequency current. *N Engl J Med* 1991;324:1605–11.
- [4] Dagues N, Clague JR, Breithardt G, Borggrefe M. Significant gender-related differences in radiofrequency catheter ablation therapy. *J Am Coll Cardiol* 2003;42:1103–7.
- [5] Kuck KH, Schlüter M, Geiger M, Siebels J, Duckeck W. Radiofrequency current catheter ablation of accessory atrioventricular pathways. *Lancet* 1991;337(8757):1557–61.
- [6] Schlüter M, Geiger M, Siebels J, Duckeck W, Kuck KH. Catheter ablation using radiofrequency current to cure symptomatic patients with tachyarrhythmias related to an accessory atrioventricular pathway. *Circulation* 1991;84:1644–61.
- [7] Haissaguerre M, Gaita F, Fischer B, Egloff P, Lemetayer P, Warin JF. Radiofrequency catheter ablation of left lateral accessory pathways via the coronary sinus. *Circulation* 1992;86:1464–8.
- [8] Langberg J, Griffin JC, Herre JM, Chin MC, Lev M, Bharati S, et al. Catheter ablation of accessory pathways using radiofrequency energy in the canine coronary sinus. *J Am Coll Cardiol* 1989;13:491–6.
- [9] Nakagawa H, Jackman WM. Catheter ablation of paroxysmal supraventricular tachycardia. Catheter ablation of paroxysmal supraventricular tachycardia. *Circulation* 2007;116:2465–78.
- [10] Insulander P, Bastani H, Braunschweig F, Drca N, Gudmundsson K, Kenneback G, et al. Cryoablation of substrates adjacent to the atrioventricular node: acute and long-term safety of 1303 ablation procedures. *Europace* 2014;16:271–6.
- [11] Stavakis S, Jackman WM, Nakagawa H, Sun Y, Xu Q, Beckman KJ, et al. Risk of coronary artery injury with radiofrequency ablation and cryoablation of epicardial posteroseptal accessory pathways within the coronary venous system. *Circ Arrhythm Electrophysiol* 2014;7:113–9.
- [12] Parvez B, Pathak V, Schubert CM, Wood M. Comparison of lesion sizes produced by cryoablation and open irrigation radiofrequency ablation catheters. *J Cardiovasc Electrophysiol* 2008;19:528–34.
- [13] Huang A, McCall JM, Weston MD, Mathur P, Quinn H, Henderson DC, et al. Phase I study of percutaneous cryotherapy for colorectal liver metastasis. *Br J Surg* 2002;89:303–10.
- [14] Dhillon PS, Domenichini G, Gonna H, Bastiaenen R, Norman M, Gallagher MM. Feasibility and efficacy of simultaneous pulmonary vein isolation and cavotricuspid isthmus ablation using cryotherapy. *J Cardiovasc Electrophysiol* 2014;25:714–8.
- [15] Gallagher MM, Y G, Gonna H, Leung LWM, Harding I, Evranos B, et al. Multi-catheter cryotherapy compared to radiofrequency ablation in long-standing persistent Atrial Fibrillation: a randomised trial. *Europace* 2021;23:370–9. <https://doi.org/10.1093/europace/eaab289>.
- [16] Andrade JG, Dubuc M, Guerra PG, Macle L, Mondésert B, Rivard L, et al. The biophysics and biomechanics of cryoballoon ablation. *Pace Clin Electrophysiol* 2012;35:1162–8.
- [17] Scanavacca MI, Sternick EB, Pisani C, Lara S, Hardy C, d'Ávila A, et al. Accessory atrioventricular pathways refractory to catheter ablation: role of percutaneous epicardial approach. *Circ Arrhythm Electrophysiol* 2015;8:128–36.
- [18] Gunda S, Reddy M, Pillarisetti J, Atoui M, Badhwar N Swarup V, et al. Differences in complication rates between large bore needle and a long micropuncture needle during epicardial access: time to change clinical practice? *Circ Arrhythm Electrophysiol* 2015;8:890–5.
- [19] Koruth JS, Dukkupati S, Miller MA, Neuzil P, d'Ávila A, Reddy VY. Bipolar irrigated radiofrequency ablation: a therapeutic option for refractory intramural atrial and ventricular tachycardia circuits. *Heart Rhythm* 2012;9:1932–41.
- [20] Teh AW, Reddy VY, Koruth JS, Miller MA, Choudry S, D'Ávila A, et al. Bipolar radiofrequency catheter ablation for refractory ventricular outflow tract arrhythmias. *J Cardiovasc Electrophysiol* 2014;25:1093–9.
- [21] Pappone C, Vicedomini G, Manguso F, Saviano M, Baldi M, Pappone A, et al. Wolff-Parkinson-White syndrome in the era of catheter ablation. Insights from a registry study of 2169 patients. *Circulation* 2014;130:811–9.
- [22] Gang Y, Gonna H, Domenichini G, Sampson M, Aryan N, Norman M, et al. Evaluation of the Achieve Mapping Catheter in cryoablation for atrial fibrillation: a prospective randomized trial. *J Intervent Card Electrophysiol* 2016;45:179–87.