Open Forum Infectious Diseases

BRIEF REPORT

Human Immunodeficiency Virus (HIV) 2 Superinfection in a Patient Receiving Antiretroviral Therapy With Longstanding HIV-1 Viral Load Suppression

F. Ceia,[1,2] A. Silva-Pinto,[1,2] A. C. Carvalho,[1,3] C. Piñeiro,[1,2] J. Soares,[1] R. Serrão,[1,2] and A. Sarmento[1,2,4]

[1]Infectious Diseases Department, Centro Hospitalar São João, Porto, [2]Faculty of Medicine, University of Porto, [3]Instituto de Saúde Pública da Universidade do Porto, and [4]Nephrology and Infectious Diseases R&D Group, Health Investigation and Innovation Institute, University of Porto, Portugal

Dual human immunodeficiency virus (HIV) 1 and HIV-2 superinfections are rare but challenging. A HIV-1–infected patient receiving effective antiretroviral therapy was investigated for a severe CD4$^+$ cell count decline. HIV-2 superinfection was diagnosed and genotypic test revealed mutations conferring resistance to most drug class, limiting options for treatment.

Keywords. HIV-1; HIV-2; human immunodeficiency virus; immunosuppression; pre-exposure prophylaxis.

Human immunodeficiency virus (HIV) 2 was identified in 1986 [1] and accounts for 0.3%–1% of HIV infections worldwide. Outside West Africa, Portugal is one of the countries where HIV-2 infection has a higher incidence [2]. Considered less virulent than HIV-1, HIV-2 usually has lower viremia, higher CD4$^+$ cells counts, and less efficient transmission [3, 4]. Moreover, some antiretrovirals are intrinsically ineffective, such as non-nucleoside reverse-transcriptase inhibitors [5]. We describe a patient receiving antiretroviral therapy (ART) for an HIV-1 infection, with immune recovery and virological suppression for more than a decade, who presented with a severe decline in the CD4$^+$ cell count secondary to HIV-2 superinfection.

CASE REPORT

A 46-year-old man had HIV-1 infection diagnosed in 2002, in Portugal. Screening was performed with a third-generation HIV-1 and HIV-2 enzyme-linked immunosorbent assay, and the line immunoassay (Inno-Lia) antibodies discrimination test had results positive for HIV-1. A resistance test for HIV-1 was not available in our hospital at that time. At presentation, the patient's HIV-1 viral load was 173 999 copies/mL, and his CD4$^+$ cell count 123/μL (10% of total lymphocytes). He had started ART in 2002, and from 6 months onward, a sustained undetectable viral load was documented. His CD4$^+$ lymphocyte count progressively increased, to a maximum of >1000/μL (37% of total lymphocytes) in 2011. From 2002 to 2011, no opportunistic infections were diagnosed although several comorbid conditions were identified and treated, namely, lipodystrophy, dyslipidaemia, chronic kidney disease, acute myocardial infarction, and type 2 diabetes mellitus, leading to several changes in ART regimen (Figure 1).

In 2013 (about 11 years after HIV-1 diagnosis) a significant decline in the patient's absolute and relative CD4$^+$ cell counts was noted, down to a nadir of 89/μL (6%). Apart from this CD4$^+$ cell count decline, no other analytical changes were present, and the patient remained asymptomatic (Figure 1). Diagnostic workup revealed no autoimmune or hematological cause, and infections such as leishmaniasis and syphilis were excluded.

In April 2016, the antibody HIV-1/HIV-2 discrimination test was performed again and was positive for both HIV-1 and HIV-2. The HIV-2 viral load (in-house method) was 5320 copies/μL. The patient then recalled an isolated unprotected sexual intercourse with a casual partner in late 2012 or early 2013 while he was abroad in Brazil (horizontally striped arrow in Figure 1). At the time of the likely transmission of HIV-2, the patient was undergoing HIV-1 treatment with emtricitabine/tenofovir disoproxil fumarate and ritonavir-boosted atazanavir.

The genotypic test of HIV-2, performed in 2016, revealed a subtype A with the following mutations: I50V, I54M, I82F (protease), N69K, K70T, V111I, Q151M (reverse-transcriptase), T97A and Y143R (integrase). The HIV-2EU 3.0 and Rega 8.0.2 interpretation algorithms revealed consistent susceptibility only to second-generation integrase inhibitors. In addition, HIV-2 was not R5 tropic.

The patient's ART regimen was then optimized to emtricitabine/tenofovir disoproxil fumarate, darunavir with ritonavir boosting (600/100 mg twice daily) and dolutegravir (50 mg twice daily). Over a 1-year period, his HIV-2 viral load became undetectable, and his CD4$^+$ cell count increased to 329/μL (12%) (Figure 1).

The patient provided informed written consent for the publication of this case report. Ethics committee approval was not required because no personal data are reported.

Received 17 October 2018; editorial decision 6 February 2019; accepted 9 February 2019.

Correspondence: F. Ceia, Infectious Diseases Department, Centro Hospitalar São João, Alameda Professor Hernani Monteiro, 4200 Porto, Portugal (fsfceia@gmail.com).

Open Forum Infectious Diseases®

© The Author(s) 2019. Published by Oxford University Press on behalf of Infectious Diseases Society of America. This is an Open Access article distributed under the terms of the Creative Commons Attribution-NonCommercial-NoDerivs licence (http://creativecommons.org/licenses/by-nc-nd/4.0/), which permits non-commercial reproduction and distribution of the work, in any medium, provided the original work is not altered or transformed in any way, and that the work is properly cited. For commercial re-use, please contact journals.permissions@oup.com

DOI: 10.1093/ofid/ofz063

Downloaded from https://academic.oup.com/ofid/article/6/4/ofz063/5316260 by guest on 14 September 2023

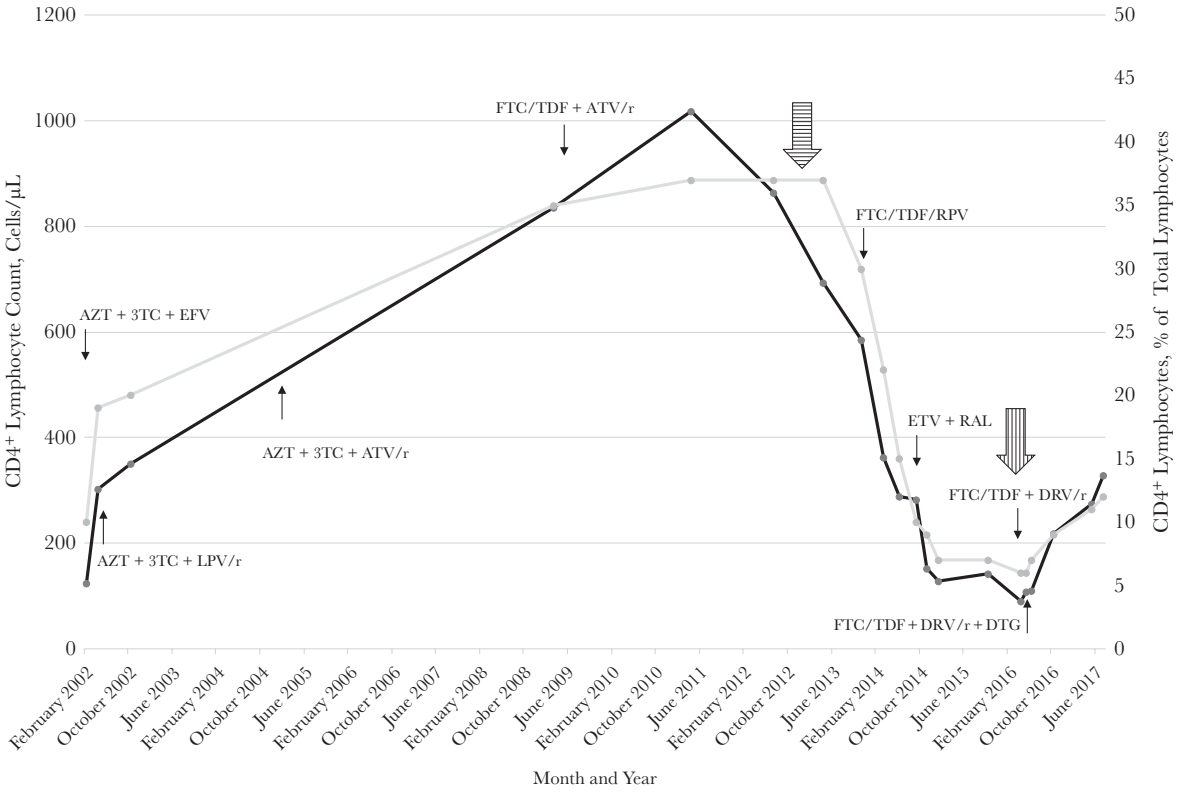

Figure 1. Absolute (*black*) and relative (*gray*) CD4+ lymphocyte counts graphed over time. Horizontally striped arrow represents probable transmission date of human immunodeficiency virus (HIV) 2 infection; vertically striped arrow, date of HIV-2 diagnosis. Abbreviations: 3TC, lamivudine; ATV, atazanavir; AZT, zidovudine; DRV, darunavir; DTG, dolutegravir; EFV, efavirenz; ETV, etravirine; FTC, emtricitabine; LPV, lopinavir; r, ritonavir; RAL, raltegravir; RPV, rilpivirine; TDF, tenofovir disoproxil fumarate.

DISCUSSION

Dual HIV-1 and HIV-2 infections are relatively common in West Africa [6], though they are scarce elsewhere [7]. In most cases, it is difficult to distinguish coinfection from superinfection because both infections are diagnosed simultaneously [6]. ART selection in these patients is sometimes complicated owing to overlapping resistance [8].

In our clinical case report, we document an HIV-2 superinfection in an ART-adherent patient with HIV-1 viral loads persistently below the level of detection. Although we neither cannot exclude HIV-2–transmitted drug-resistant virus nor be certain about the exact time of acquisition, we must consider the possibility that our patient acquired HIV-2 infection around 2012–2013 while adhering to a nucleoside reverse-transcriptase inhibitor backbone regimen. Until 2011, there was a sustained increase in the patient's CD4+ cell count, up to >1000/µL, which would have been unlikely had he already been infected by both HIV types. In 2014, we noted an impressive decline in the patient's CD4+ cell count, coincident with the change to a nonnucleoside reverse-transcriptase inhibitor regimen, leading to monotherapy for HIV-2 and subsequently to the accumulation of mutations conferring resistance to antiretrovirals.

In our patient, the selection of ART for dual infection had additional challenges besides HIV-2 resistance to most drug classes, including chronic kidney disease with an estimated glomerular filtration rate <70 mL/min and a high cardiovascular risk, which narrowed the safety margin for use of tenofovir disoproxil fumarate, abacavir, and darunavir.

In conclusion, HIV-2 superinfection should be considered in the presence of an unexplained and sustained decline in CD4+ cell count, even in a HIV-1–infected patient with viral load suppression. Furthermore, no data are currently available regarding emtricitabine/tenofovir disoproxil fumarate effectiveness as a pre-exposure prophylactic regimen for HIV-2, and patients should be informed accordingly.

Acknowledgment

Potential conflicts of interest. All authors: No reported conflicts of interest. All authors have submitted the ICMJE Form for Disclosure of Potential Conflicts of Interest. Conflicts that the editors consider relevant to the content of the manuscript have been disclosed.

References

1. Clavel F, Mansinho K, Chamaret S, et al. Human immunodeficiency virus type 2 infection associated with AIDS in West Africa. N Engl J Med **1987**; 316:1180–5.

Downloaded from https://academic.oup.com/ofid/article/6/4/ofz063/5316260 by guest on 14 September 2023

2. Carvalho AC, Valadas E, França L, et al. Population mobility and the changing epidemics of HIV-2 in Portugal. HIV Med **2012**; 13:219–25.
3. Cavaco-Silva P, Taveira NC, Lourenço MH, et al. Vertical transmission of HIV-2. Lancet **1997**; 349:177–8.
4. Kanki PJ, Travers KU, MBoup S, et al. Slower heterosexual spread of HIV-2 than HIV-1. Lancet **1994**; 343:943–6.
5. Smith NA, Shaw T, Berry N, et al. Antiretroviral therapy for HIV-2 infected patients. J Infect **2001**; 42:126–33.
6. Silva TId, Tienen Cv, Rowland-Jones S, Cotten M. Dual infection with HIV-1 and HIV-2: double trouble or destructive interference? HIV Ther **2010**; 4:305–23.
7. Günthard HF, Huber M, Kuster H, et al. HIV-1 superinfection in an HIV-2-infected woman with subsequent control of HIV-1 plasma viremia. Clin Infect Dis **2009**; 48:e117–20.
8. Rodés B, Toro C, Jiménez V, Soriano V. Viral response to antiretroviral therapy in a patient coinfected with HIV type 1 and type 2. Clin Infect Dis **2005**; 41:e19–21.

Downloaded from https://academic.oup.com/ofid/article/6/4/ofz063/5316260 by guest on 14 September 2023